

1800 180 1947
1947
help@uidai.gov.in
www.uidai.gov.in
P.O. Box No. 1947,
Bengaluru-560 001

www

पता: S/O मनीष कुमार झा, 698,
राजदशपुरी लाने नं-4, मुजफ्फर, बिहार, 842002
मिहानपुरा, रामना, मुजफ्फरपुर,
बिहार, 842002

एकलिंग प्रमाण प्रमाणिका
UNIQUE IDENTIFICATION AUTHORITY OF INDIA

ONEPLUS ULTRASOUND LAB
47, Harsh Vihar, Pitam Pura,
Delhi-110034
Ph. 011-42480101, 9599913051
E-mail: oneplusul@gmail.com

Handwritten signature

Handwritten signature

भारत सरकार
GOVERNMENT OF INDIA

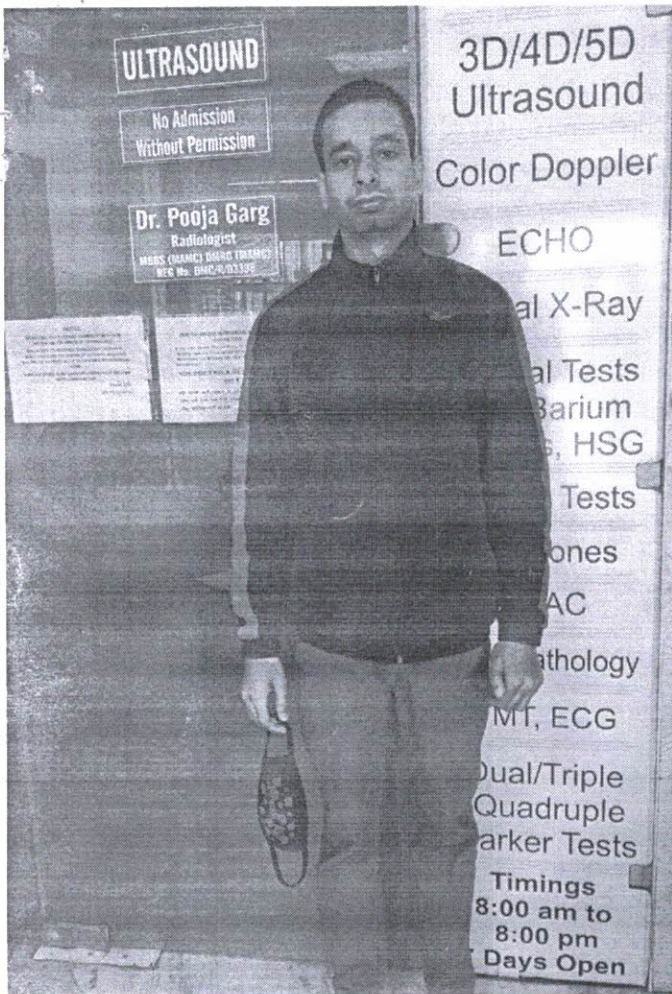
Dr. NITIN AGARWAL
— MBBS, MD
Regn. No. DMC-R-1436

सुमित कुमार
Sumit Kumar

जन्म वर्ष / Year of Birth: 1993
पुरुष / Male

7261 5824 0425

आधार — आम आदमी का अधिकार



Dr. NITIN AGARWAL
MBBS, MD
Regn. No. DMC-R-1436

ONEPLUS ULTRASOUND LAB
47, Harsh Vihar, Pusa, Delhi-110034
Ph. 011-42480101, 9599913051
E-mail: oneplusul@gmail.com

I, Sumit Kumar, hereby declare that ~~we~~ ^I do not want stool test for personal reasons.

Signature



Dr. NITIN AGARWAL
MBBS, MD
Regn. No. DMC-R-1436

ONEPLUS ULTRASOUND LAB
47, Harsh Vihar, Pitam Pura,
Delhi-110034
Ph. 011-42480101, 9599913051
E-mail: oneplusul@gmail.com

ONEPLUS ULTRASOUND LAB

47, HARSH VIHAR, PITAMPURA, DELHI- 110034

Mr. SUMIT KUMAR
 Age : 28M
 Ref. by : MEDWHEEL
 Indication1 :
 Indication2 :
 Indication3 :
 COMMENTS :

ID : 1886
 Ht/Wt : 174/63
 Recorded : 26-2-2022 10:57
 Medication1 :
 Medication2 :
 Medication3 :

BPM : 74
 BP : 138/86
 P Axis : 71 deg
 QRS Axis : 49 deg
 T Axis : -18 deg

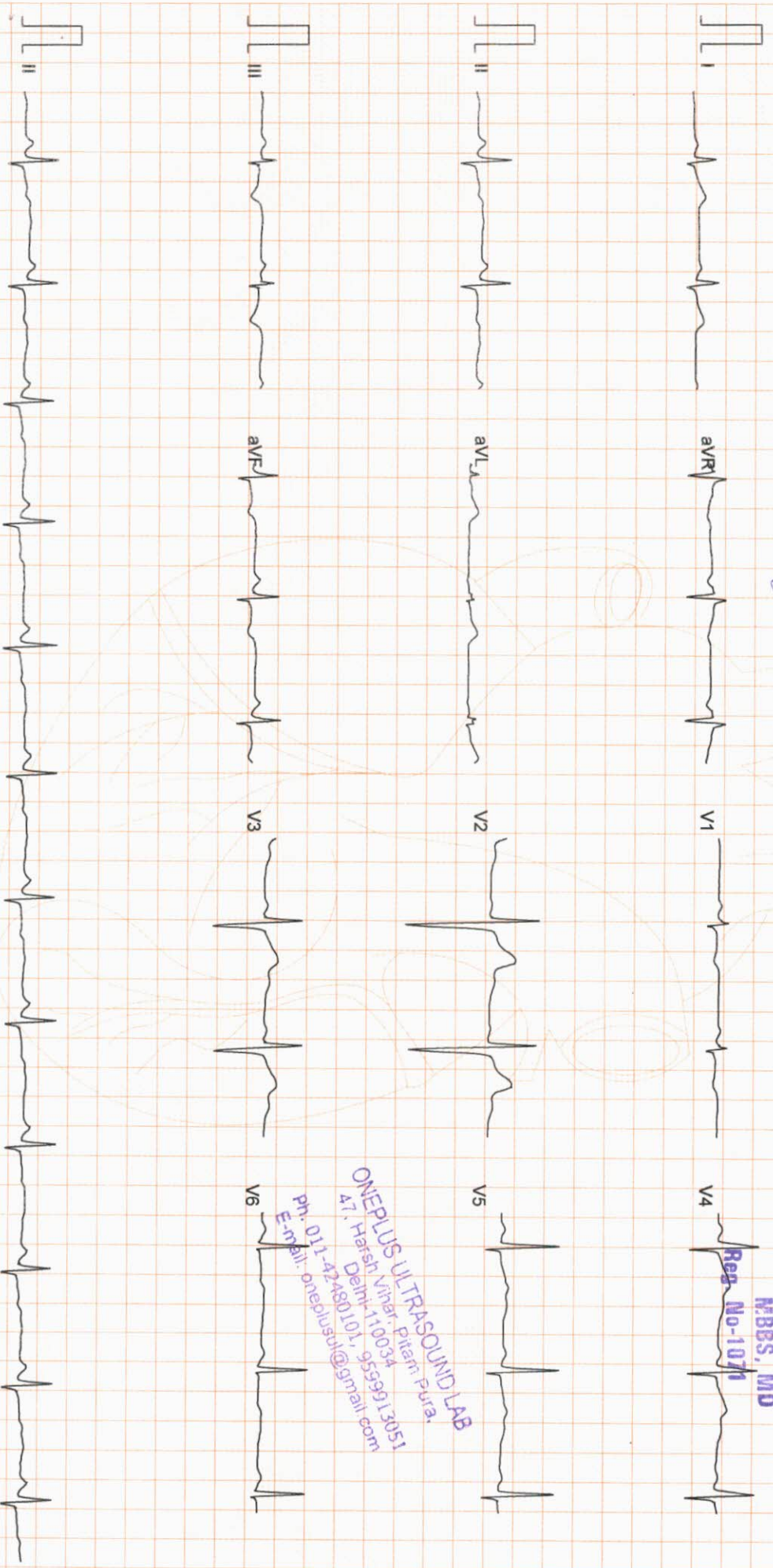
P duration : 90 msec
 PR duration : 126 msec
 QRS duration : 106 msec
 QT Interval : 336 msec
 QTc Interval : 360 msec
 Raw E.C.G. (Seq)

Signature

Unconfirmed Report Reviewed By: *Signature*
 Cardiologist

Signature
Dr. R.K. GUPTA
MBBS, MD
 Reg. No-1071

ONEPLUS ULTRASOUND LAB
 A-7, Harsh Vihar, Pitam Pura,
 Delhi-110034
 Ph. 011-42480101, 9559913051
 E-mail: oneplusul@gmail.com



Filtered

25mm/sec 10mm/mV

CardiCom, INDIA

ONEPLUS ULTRASOUND LAB

47, HARSH VIHAR PITAMPURA DELHI 110034

Mr. SUMIT KUMAR

Age/Sex : 28/M

Ref by : MEDIWHEEL

Indication1 :

Indication2 :

Indication3 :

ID : 988
 HWT : 174/63
 Recorded : 26-2-2022 11:00

TREADMILL TEST SUMMARY REPORT
 Protocol: BRUCE

History:

Medication1 :

Medication2 :

Medication3 :

PHASE	PHASE TIME	STAGE TIME	SPEED (Km./Hr.)	GRADE (%)	H.R. (BPM)	B.P. (mmHg)	RPP X100	II	ST LEVEL (mm) V2	V5	METS
SUPINE STANDING					73	138/86	100	0.3	1.5	0.5	
STAGE 1	2:59	2:59	2.70	10.00	116	138/86	160	-0.1	1.2	0.2	4.80
STAGE 2	5:59	2:59	4.00	12.00	129	150/90	193	-0.3	1.1	-0.2	7.10
STAGE 3	7:59	1:59	5.40	14.00	167	164/92	273	-0.3	1.4	-0.6	9.03
PEAK EXER	8:00	2:00			168	164/92	275	-0.3	1.4	-0.6	9.04
RECOVERY	2:59	2:59	0.00	0.00	105	138/88	144	0.4	2.5	0.5	

RESULTS

Exercise Duration

Max Heart Rate

Max Blood Pressure

Max Work Load

Reason of Termination

8:00 Minutes
 168 bpm 87 % of target heart rate 192 bpm
 164/92 mmHg
 9.04 METS

IMPRESSIONS

Negative for ischemic risk

Dr. P.K. GUPTA
 MBBS, MD
 Cardiologist
 Reg. No-1071

[Signature]

ONEPLUS ULTRASOUND LAB
 47, Harsh Vihar, Pitampura, Delhi-110034
 Ph: 011-24891011, 95599913151
 E-mail: onepplusul@oneplusul.com

ONEPLUS ULTRASOUND LAB

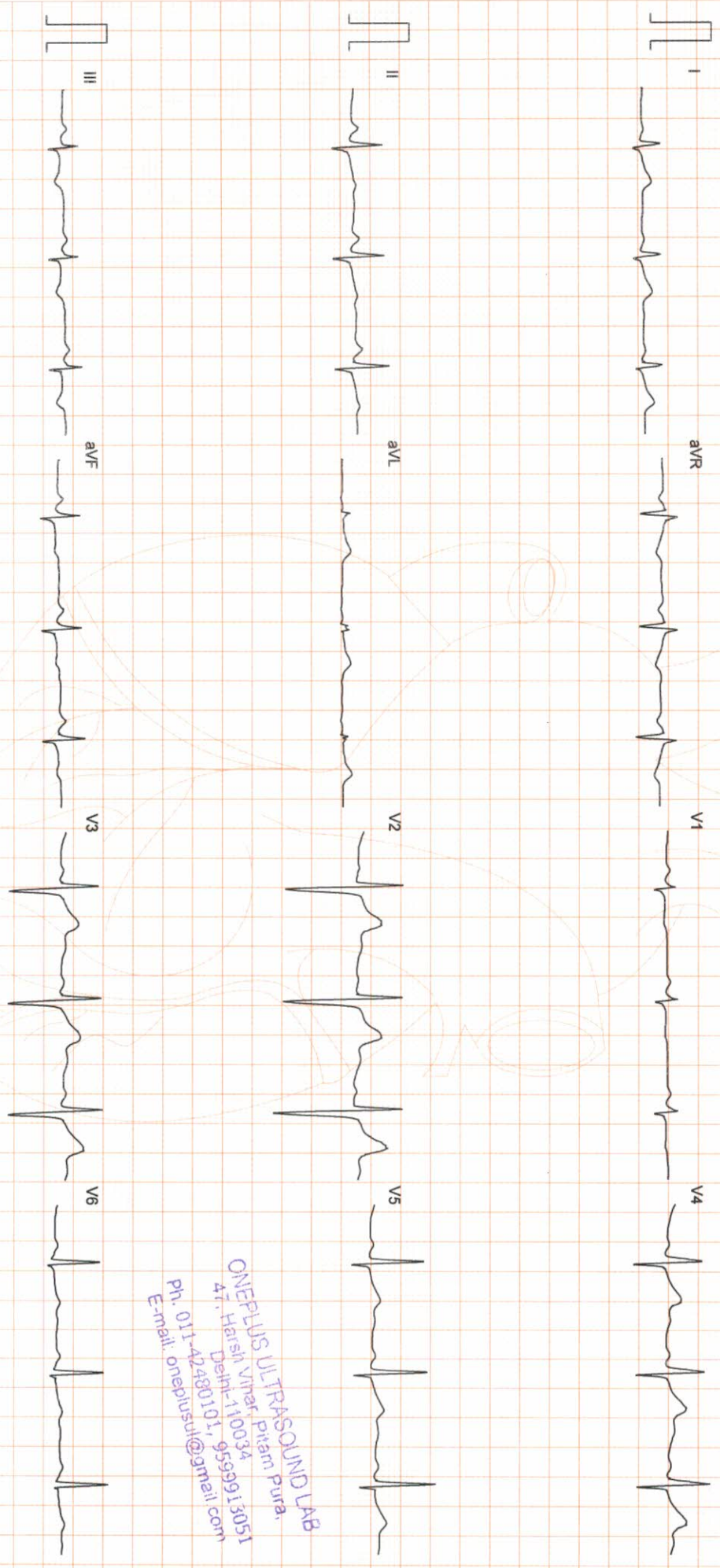
SUPINE
PRETEST

ST @ 10mm/mV
80ms PostJ

Mr. SUMIT KUMAR
I.D. : 988
AGE/SEX : 28M

RATE : 73 BPM
B.P. : 138/86 mmHg

RAW E.C.G.



ONEPLUS ULTRASOUND LAB
47, Harsh Vihar, Pitam Pura,
Delhi-110034
Ph. 011-42480101, 9599913051
E-mail: oneplusul@gmail.com

ONEPLUS ULTRASOUND LAB

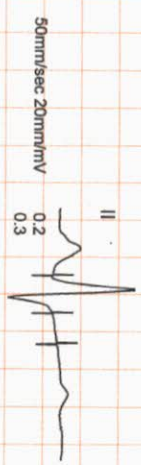
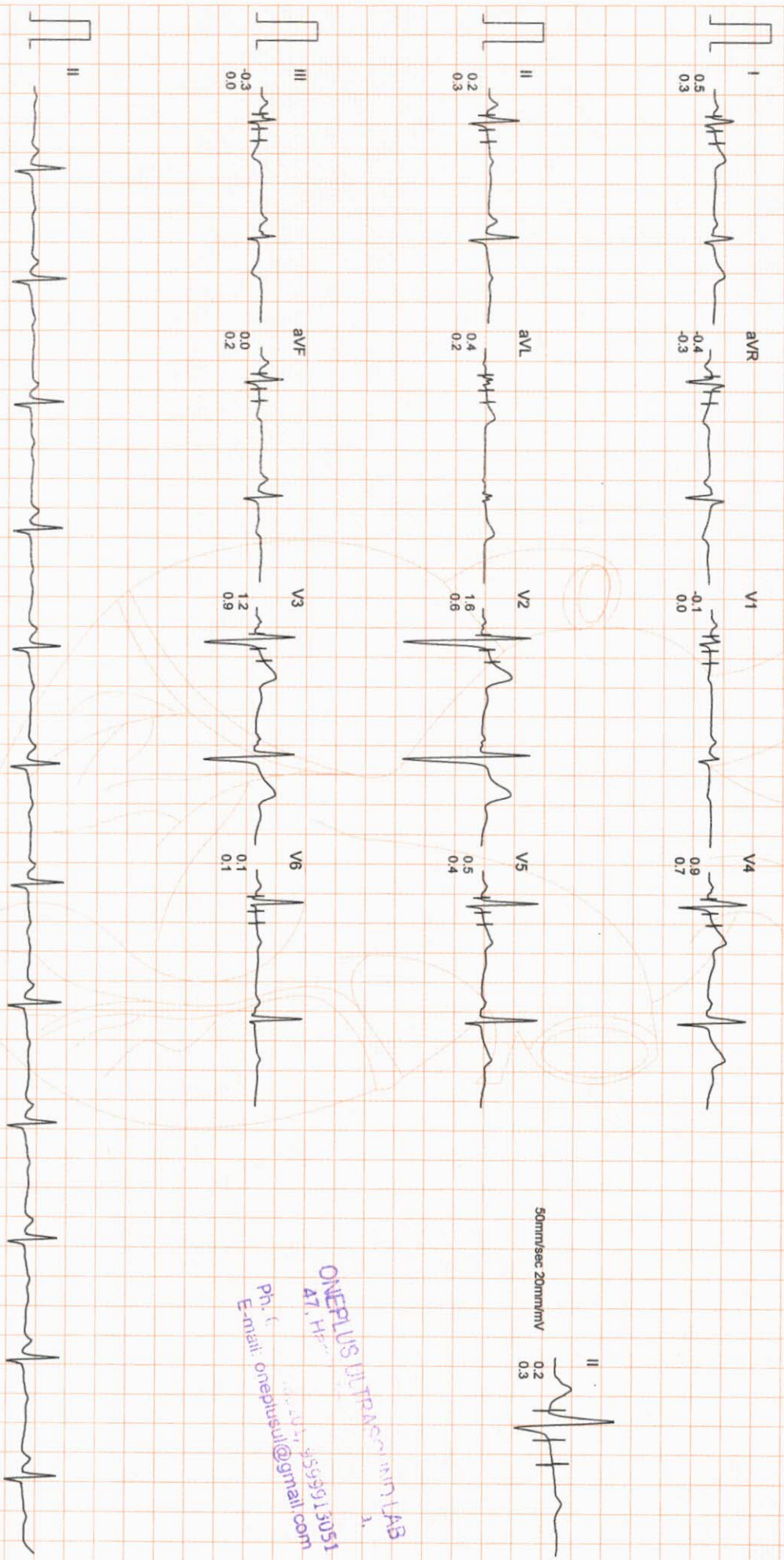
STANDING
PRETEST

ST @ 10mm/mV
80ms PostJ

Mr. SUMIT KUMAR
I.D : 988
AGE/SEX : 28/M
RECORDED : 26-2-2022 11:00

RATE : 74 BPM
B.P. : 138/86 mmHg

LINKED MEDIAN



ONEPLUS ULTRASOUND LAB
AT, H.P.
Ph. : 091-731-26207/40
E-mail: oneplusul@gmail.com

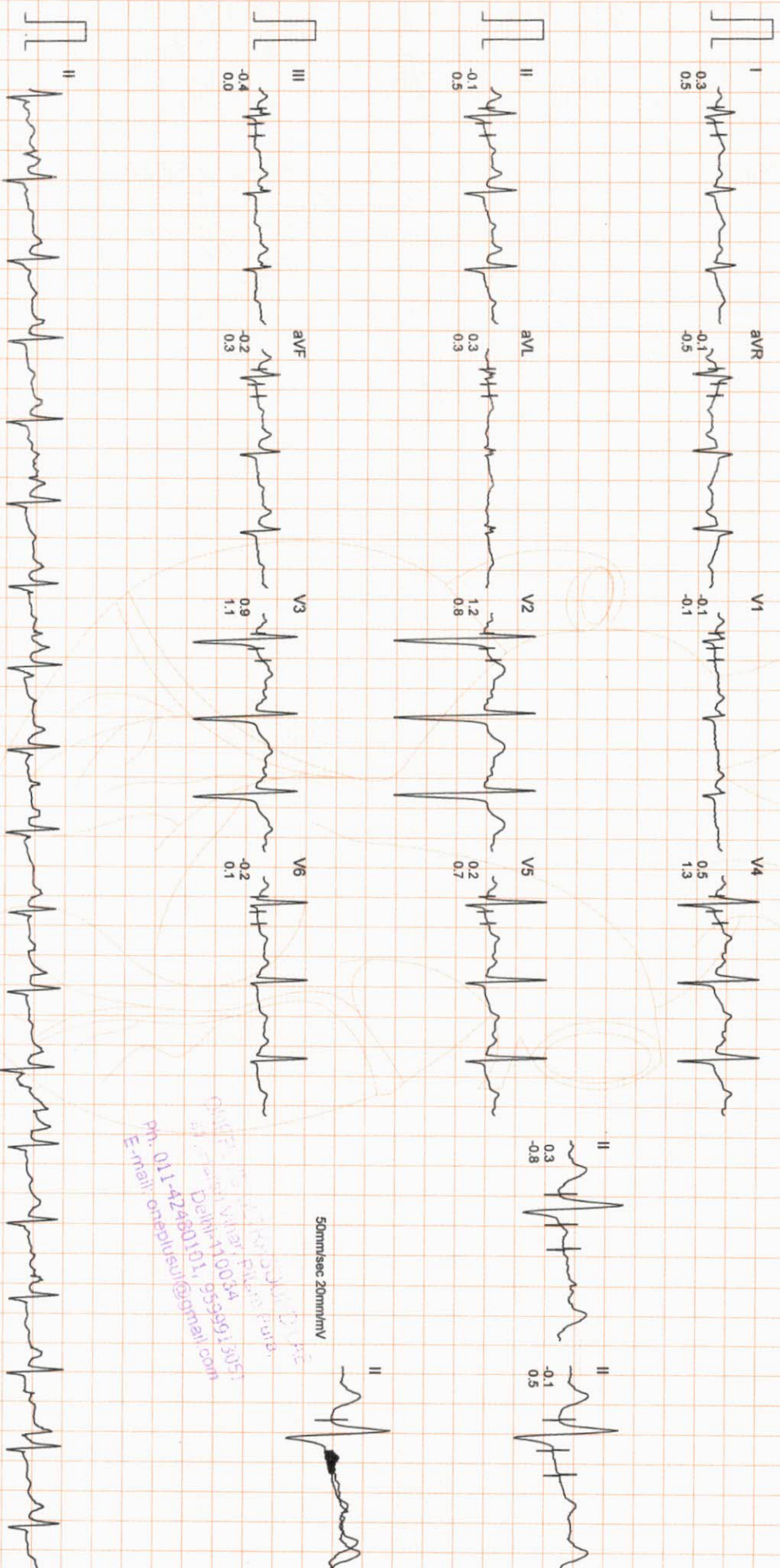
ONEPLUS ULTRASOUND LAB

M. SUMIT KUMAR
I.D. : 988
AGE/SEX : 28/M
RECORDED : 26-2-2022 11:00

RATE : 116 BPM
B.P. : 138/86 mmHg

BRUCE
EXERCISE 1
PHASE TIME : 2:59
STAGE TIME : 2:59

ST @ 10mm/mV
80ms PostJ
SPEED : 2.7 Km./Hr.
GRADE : 10.0 %
LINKED MEDIAN



Dr. Sumit Kumar, MD, DM, DNB
D-110, Vardaan, Panchsheel Park,
Delhi-110034
Ph: 011-42448011, 65566913051
E-mail: onmedul@rediffmail.com

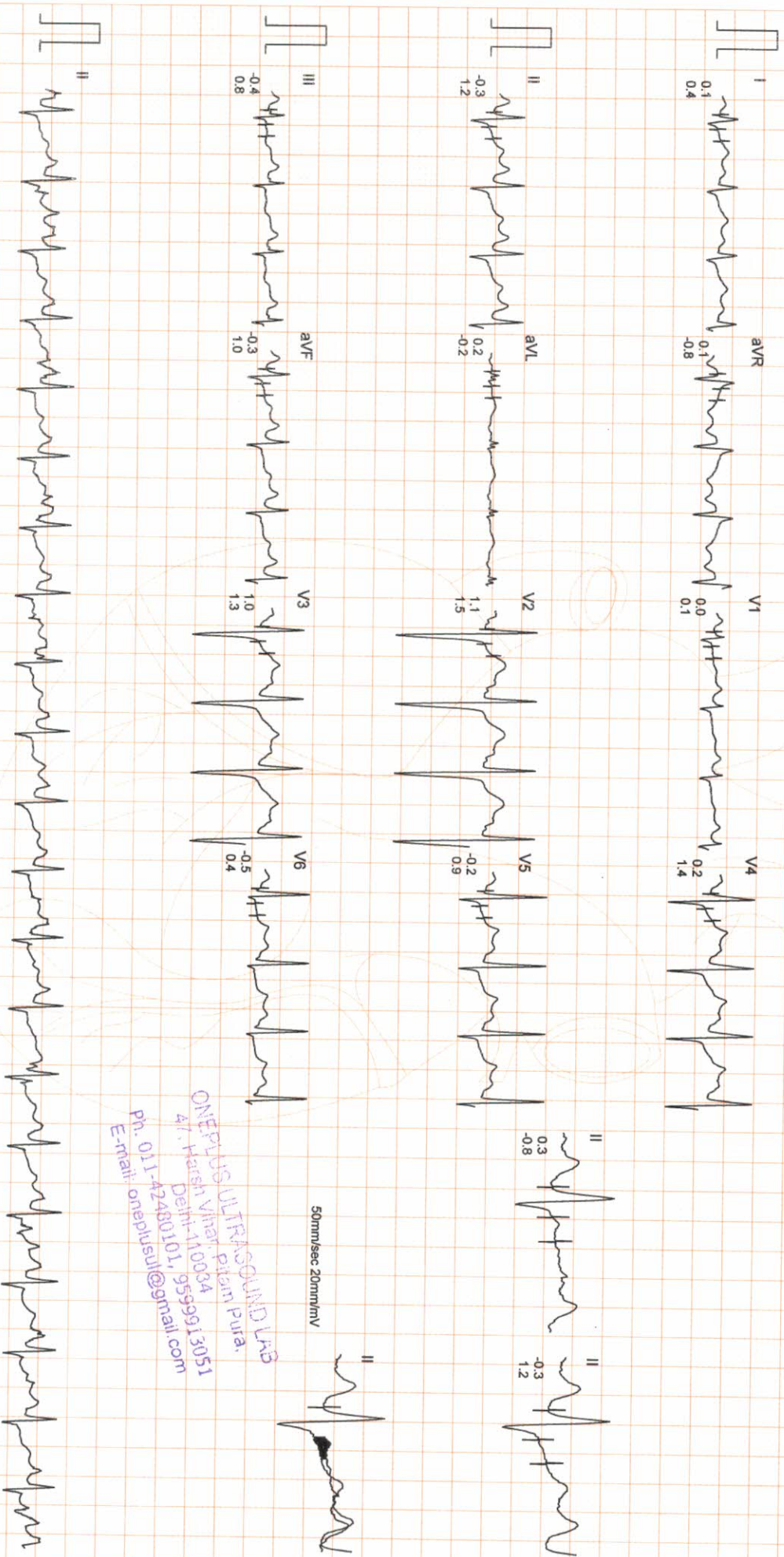
ONEPLUS ULTRASOUND LAB

Mr. SUMIT KUMAR
I.D. : 988
AGE/SEX : 28/M
RECORDED : 26-2-2022 11:00

RATE : 129 BPM
B.P. : 150/90 mmHg

BRUCE
EXERCISE 2
PHASE TIME : 5:59
STAGE TIME : 2:59

ST @ 10mm/mv
80ms PostJ
SPEED : 4.0 Km./Hr.
GRADE : 12.0 %
LINKED MEDIAN



ONEPLUS ULTRASOUND LAB
47, Harsh Vihar, Pitam Pura,
Delhi-110034
Ph. 011-42480101, 9599913051
E-mail: oneplusul@gmail.com

50mm/sec 20mm/mv

Filtered

Computer Corrected Baseline

25mm/sec 10mm/mv

ARROW

CardiCom, INDIA Ph.:091-731-2620740, TeleFax:091-731-2431214

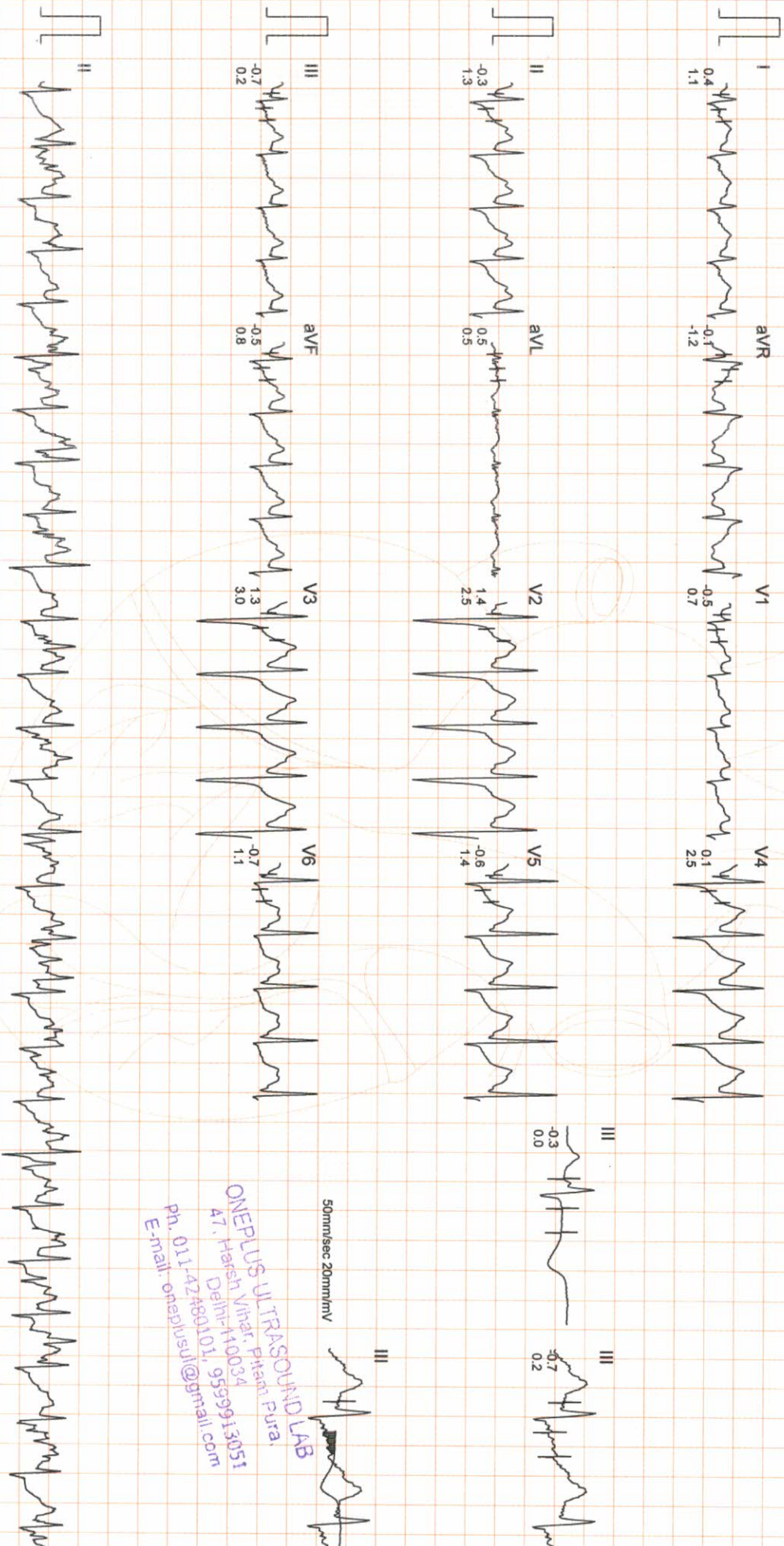
ONEPLUS ULTRASOUND LAB

Mr. SUMIT KUMAR
ID : 988
AGE/SEX : 28/M
RECORDED : 26-2-2022 11:00

RATE : 167 BPM
B.P. : 164/92 mmHg

BRUCE
EXERCISE 3
PHASE TIME : 7:59
STAGE TIME : 1:59

ST @ 10mm/mV
80ms PostJ
SPEED : 5.4 Km./HR.
GRADE : 14.0 %
LINKED MEDIAN



50mm/sec 20mm/mV
ONEPLUS ULTRASOUND LAB
47, Harsh Vihar, Pitampura,
Delhi-110034
Ph. 011-42480101, 9599913051
E-mail: oneplusul@gmail.com

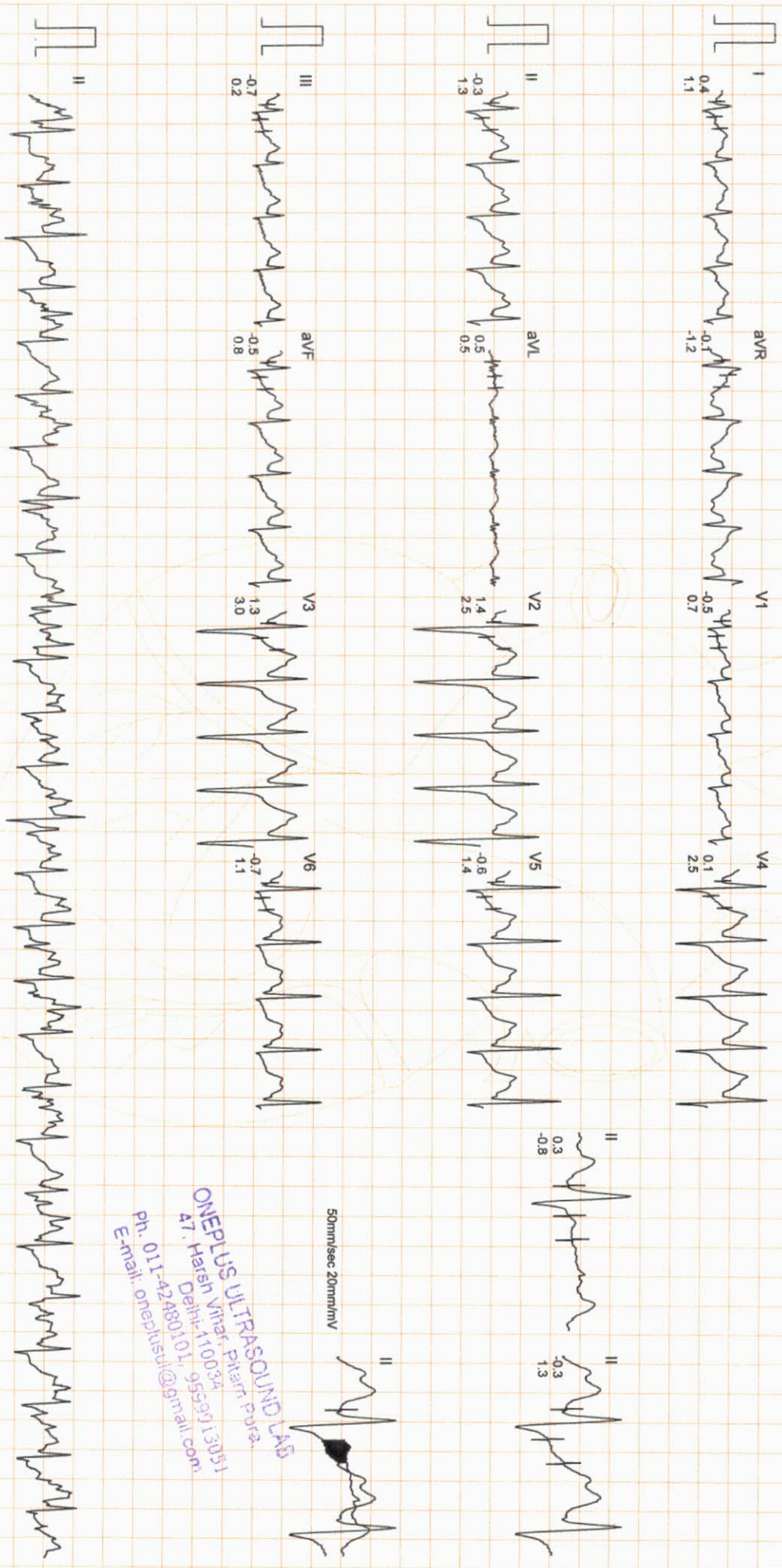
ONEPLUS ULTRASOUND LAB

Mr. SUMIT KUMAR
ID : 988
AGE/SEX : 28/M
RECORDED : 26-2-2022 11:00

RATE : 168 BPM
B.P. : 164/92 mmHg

BRUCE
PEAK EXER
PHASE TIME : 8:00
STAGE TIME : 2:00

ST @ 10mm/mV
80ms PostJ
SPEED : 5.4 Km./Hr.
GRADE : 14.0 %
LINKED MEDIAN



ONEPLUS ULTRASOUND LAB
Dr. Harish Vignaraj, Partner, MD
47, Hareesh Nagar, Perambur,
Dharmaram Colony, Chennai-600021
www.oneplusultrasoundlab.com
ph: 011-42480101, 95559133021
Email: info@oneplusul.com

ONEPLUS ULTRASOUND LAB

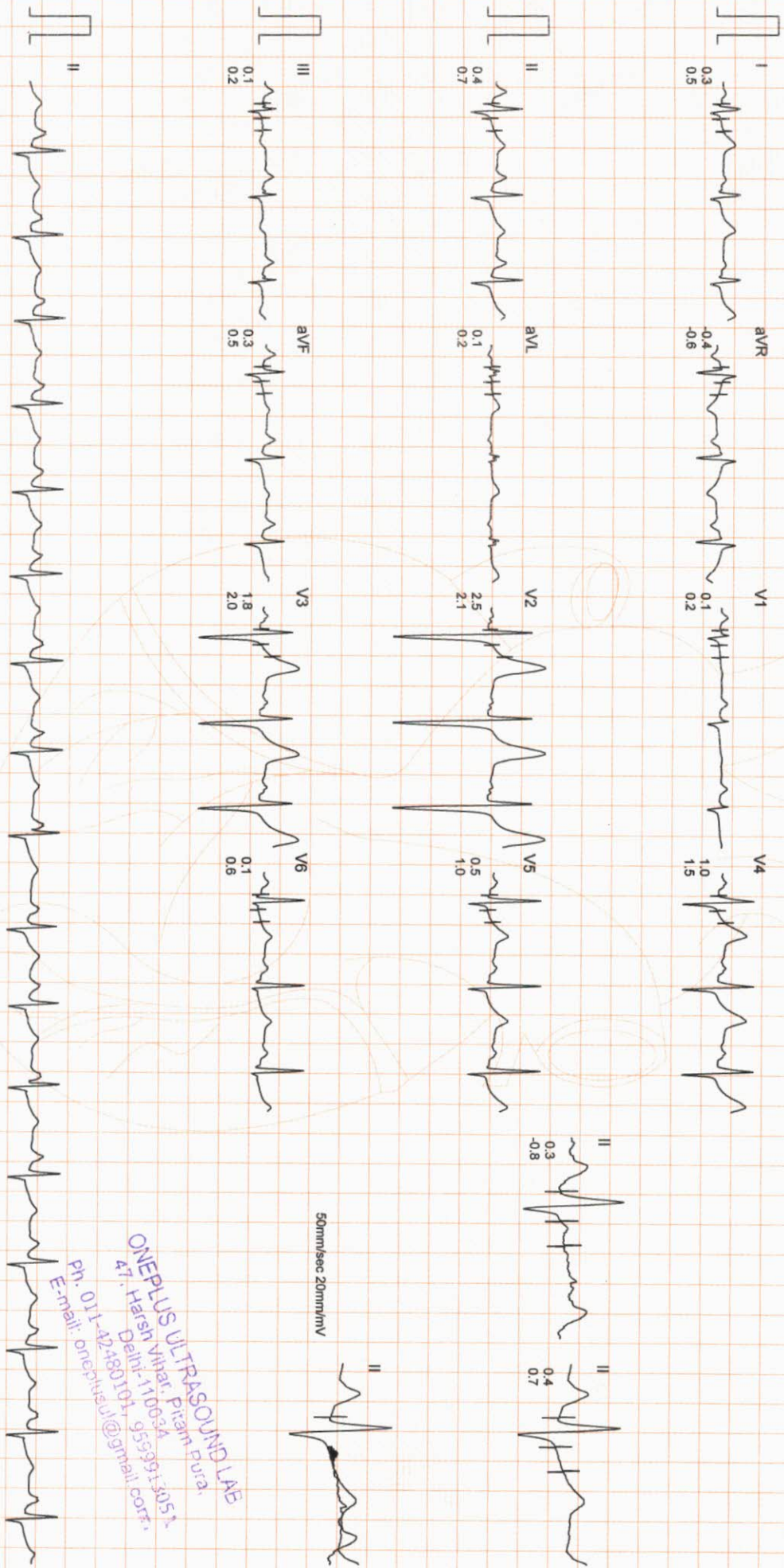
Mr. SUMIT KUMAR
I.D. : 988
AGE/SEX : 28/M
RECORDED : 26-2-2022 11:00

RATE : 105 BPM
B.P. : 138/88 mmHg

BRUCE
RECOVERY
PHASE TIME : 2:59

ST @ 10mm/mV
80ms PostJ
SPEED : 0.0 Km./Hr.
GRADE : 0.0 %

LINKED MEDIAN

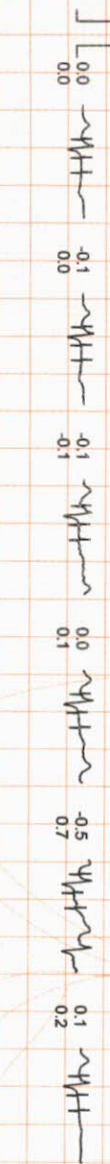
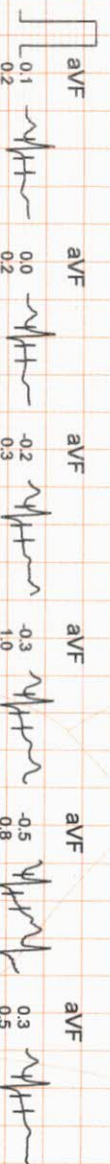


50mm/sec 20mm/mV

ONEPLUS ULTRASOUND LAB
47, H. Harsana Vihar, Pitampura,
Delhi-110064
Ph: 011-42480101, 65599913051
E-mail: oneplusultrasoundlab@gmail.com

ONEPLUS ULTRASOUND LAB

STAGE	TIME	HR	BP	SpO2
SUPINE	2:59	73 bpm	138/86	98%
STANDING	2:59	74 bpm	138/86	98%
STAGE 1	2:59	116 bpm	138/86	98%
STAGE 2	2:59	129 bpm	150/90	98%
PEAK EXERCISE	2:00	168 bpm	164/92	98%
RECOVERY	2:59	105 bpm	138/88	98%



ONEPLUS ULTRASOUND LAB
 47, Harish Vihar, Pitambara, New Delhi-110044
 Ph: 011-42480101, 9955369130, 9955369131
 E-mail: oneplusul@gmail.com

ONEPLUS ULTRASOUND LAB


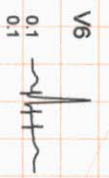




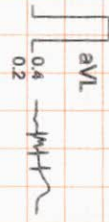















COMPARISON REPORT

STANDING
 0.0kmph
 0.0%
 74 bpm
 B.P. 138/86
 80ms PostJ

PEAK EXERCISE
 8:00
 2:00
 5.4kmph
 14.0%
 168 bpm
 B.P. 164/92
 80ms PostJ

STANDING
 0.0kmph
 0.0%
 74 bpm
 B.P. 138/86
 80ms PostJ

PEAK EXERCISE
 8:00
 2:00
 5.4kmph
 14.0%
 168 bpm
 B.P. 164/92
 80ms PostJ



ONEPLUS ULTRASOUND LAB
 47, 17, Harshit Vihar Pitam Pura,
 Delhi-110034
 Ph. 011-42460101, 9599913051
 E-mail: oneplusul@gmail.com



OnePLUS
Ultrasound Lab
— QUALITY FIRST... ALWAYS! —

Dr. Nitin Agarwal
Pathologist & Director
Ex. Sr. Res. MAMC
& Lok Nayak Hospital
Ex. Chief of Lab Dr. Lal Path Labs.

Dr. Pooja (Garg) Agarwal
Radiologist & Director
MAMC & Lok Nayak Hospital

Name	: Mr. SUMIT KUMAR	Age/Sex	: 28 YRS/Male
Ref. By	: Dr. MEDIWHEEL	Lab No	: 012202260009
Date	: 26-Feb-2022	Patient ID	: LSHHI91727

ULTRASOUND EXAMINATION---WHOLE ABDOMEN

Liver is normal in size (12.1 cm) and normal in outline with **altered echopattern. Diffuse increase in echogenicity of liver parenchyma is noted, suggestive of fatty infiltration (grade I). Intrahepatic biliary radicles are not dilated.** No abscess or mass lesion seen. Hepatic veins, portal vein, IVC and aorta are normal. CBD is normal in caliber.

Gall bladder is well distended with anechoic lumen. Wall thickness is normal.

Both kidneys are normal in size, shape, position, outline and echopattern. Corticomedullary differentiation is maintained. No pelvicalyceal dilation or mass lesion is seen.

Spleen is normal in size and echotexture. No mass lesion seen.

Pancreas is normal in size, outline and echotexture.

Urinary bladder is normal in shape and position. No evidence of intravesical stone or mass seen.

Prostate is normal in size, shape and echopattern.

Prostate measures 2.6 x 3.2 x 4.3 cm. **Weight of prostate is 18.7 grams.**

No abnormal bowel wall thickening seen in right iliac fossa.
No free fluid seen anywhere in abdomen.

IMPRESSION:

- **Fatty infiltration of liver (grade I) with no hepatomegaly.**

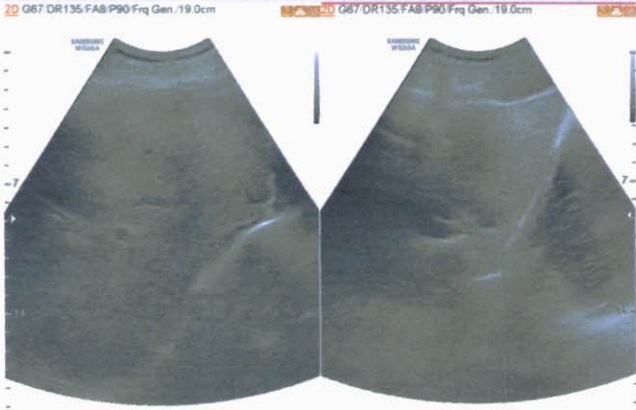
DR. POOJA GARG
RADIOLOGIST
REG NO- DMC/R/03398

Dr. POOJA GARG
M.B.B.S., D.M.R.D.
Reg No. DMC/R/03398
Radiologist

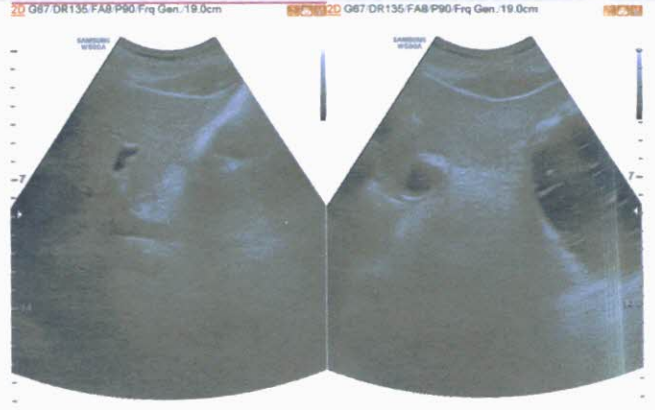
Type By : pooja

47, Harsh Vihar, Pitampura, New Delhi-110034 | Ph.: 011-42480101, 9599913051
E-mail: oneplusul@gmail.com | Web.: www.oneplusul.in

W590A MR SUMIT 28M OnePlus Ultrasound Lab MI 1.4 26-02-2022
CA1-7A / Abdomen / FR 22Hz Tls 0.1 10:29:45 AM



W590A MR SUMIT 28M OnePlus Ultrasound Lab MI 1.4 26-02-2022
CA1-7A / Abdomen / FR 22Hz Tls 0.1 10:29:50 AM

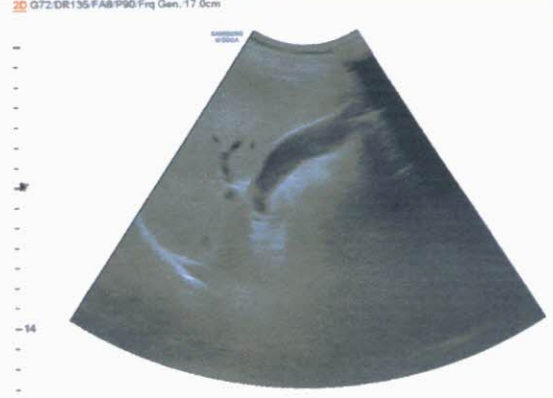

W590A MR SUMIT 28M OnePlus Ultrasound Lab MI 1.4 26-02-2022
CA1-7A / Abdomen / FR 22Hz Tls 0.1 10:30:10 AM

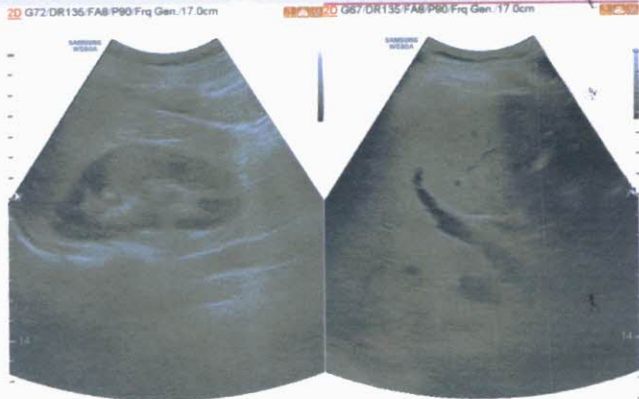

D1 12.10 cm

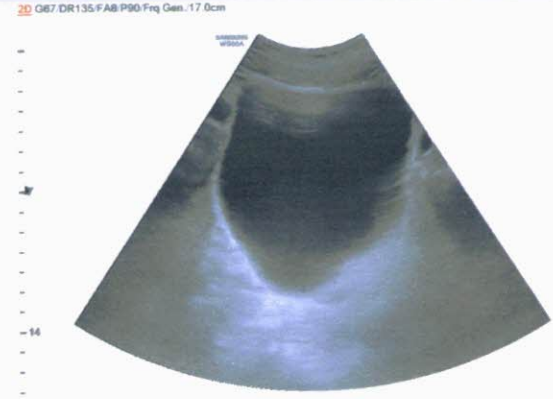
W590A MR SUMIT 28M OnePlus Ultrasound Lab MI 1.4 26-02-2022
CA1-7A / Abdomen / FR 24Hz Tls 0.1 10:30:31 AM



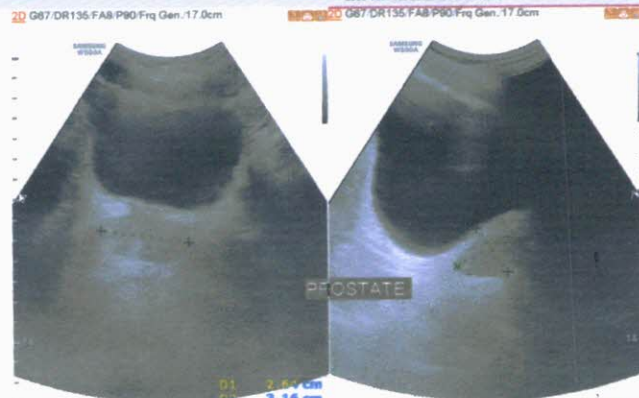
W590A MR SUMIT 28M OnePlus Ultrasound Lab MI 1.4 26-02-2022
CA1-7A / Abdomen / FR 24Hz Tls 0.1 10:30:58 AM



W590A MR SUMIT 28M OnePlus Ultrasound Lab MI 1.4 26-02-2022
CA1-7A / Abdomen / FR 24Hz Tls 0.1 10:31:02 AM



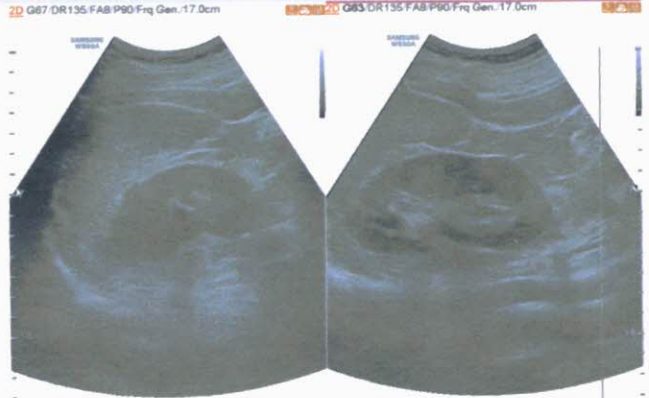W590A MR SUMIT 28M OnePlus Ultrasound Lab MI 1.4 26-02-2022
CA1-7A / Abdomen / FR 24Hz Tls 0.1 10:31:29 AM











D1 2.64 cm
D2 3.16 cm
D3 4.29 cm
Vol. 18.72 ml

D1 2.64 cm
D2 3.16 cm

W590A MR SUMIT 28M OnePlus Ultrasound Lab MI 1.4 26-02-2022
CA1-7A / Abdomen / FR 24Hz Tls 0.1 10:31:28 AM







OnePLUS
Ultrasound Lab
— QUALITY FIRST... ALWAYS! —

Dr. Nitin Agarwal

Pathologist & Director
Ex. Sr. Res. MAMC
& Lok Nayak Hospital
Ex. Chief of Lab Dr. Lal Path Labs.

Dr. Pooja (Garg) Agarwal


Radiologist & Director
MAMC & Lok Nayak Hospital

Name	: Mr. SUMIT KUMAR	Age/Sex	: 28 YRS/Male
Ref. By	: Dr. MEDIWHEEL	Lab No	: 012202260009
Date	: 26-Feb-2022	Patient ID	: LSHHI91727

X-ray-Chest PA view

Bony cage and soft tissues are normal.
Cardiothoracic ratio is normal.
Mediastinum is normal.
Both hila are normal.
Both costophrenic angles are clear.
Both domes of diaphragm are normal.
Lung fields are clear. No parenchymal lesion seen.

IMPRESSION: Normal Study.

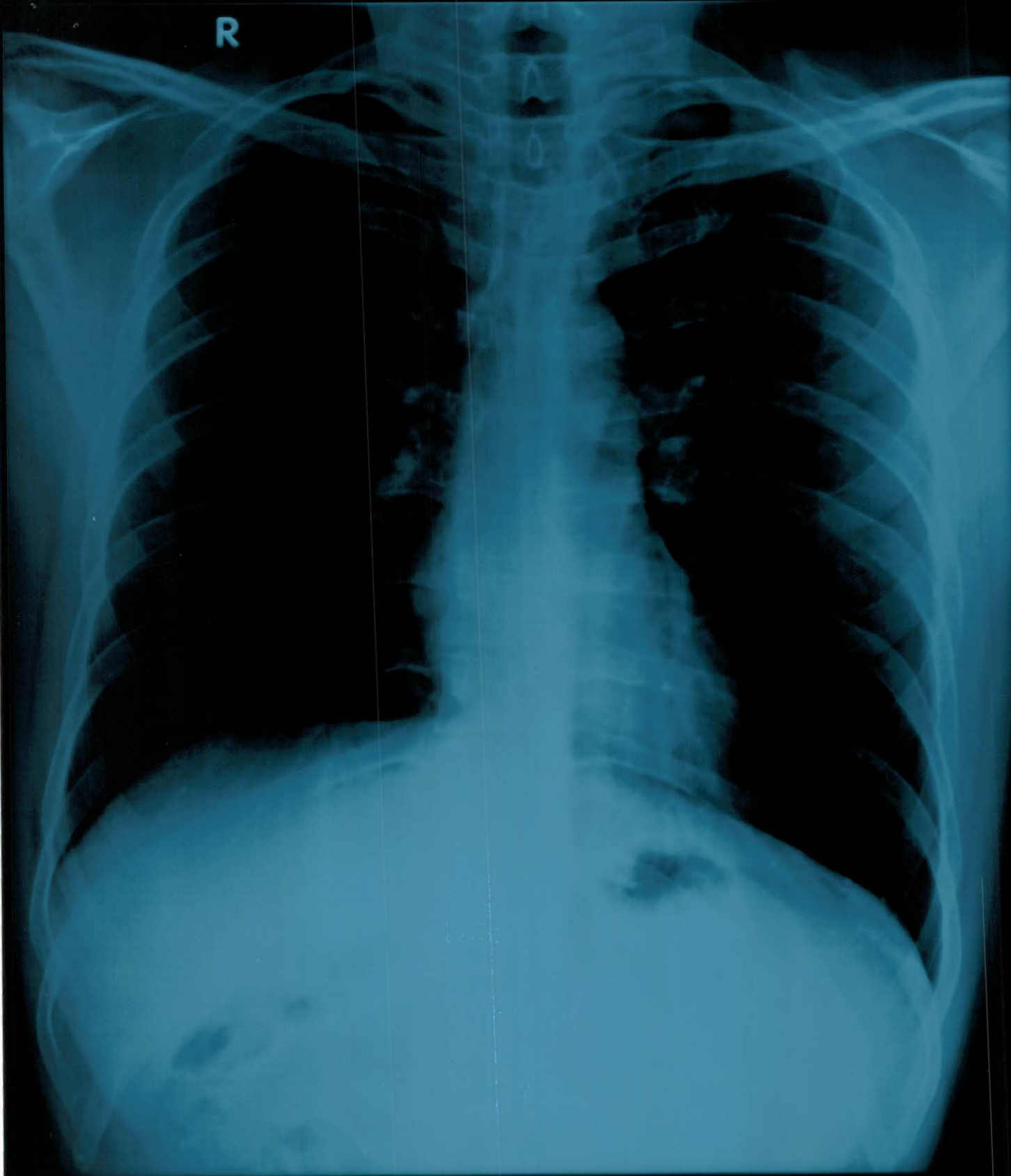
DR. POOJA GARG
RADIOLOGIST
REG NO- DMC/R/03398
Dr. POOJA GARG
M.B.B.S., D.M.R.D
Reg No. DMC/R/03398
Radiologist

Type By : pooja

47, Harsh Vihar, Pitampura, New Delhi-110034 | Ph.: 011-42480101, 9599913051
E-mail: oneplusul@gmail.com | Web.: www.oneplusul.in

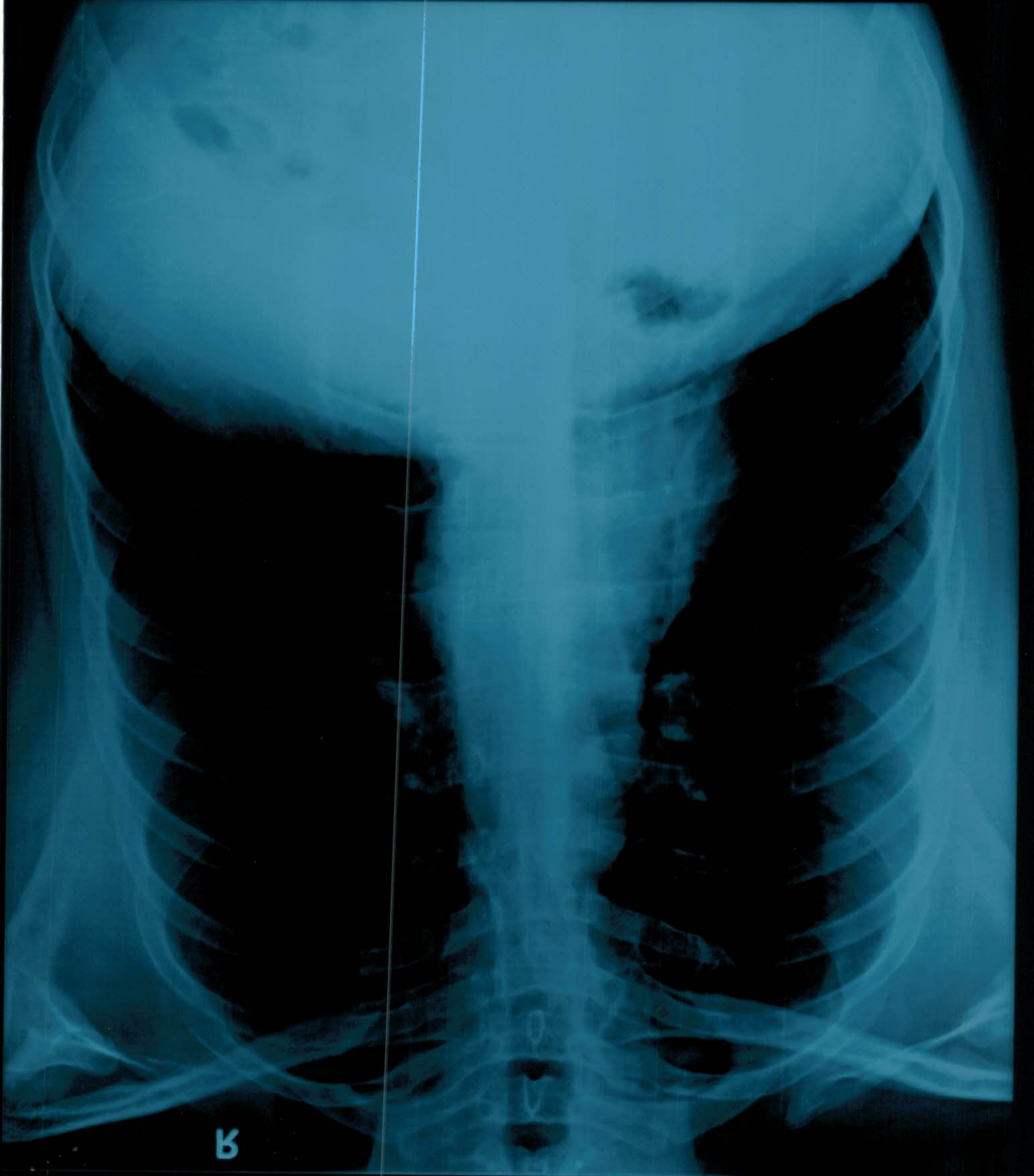Clinical correlation is essential for final diagnosis. • If test results are unsatisfactory please contact personally or on phone. • This report is for perusal of doctors only.
• All disputes Subject to Delhi Jurisdiction only. • Not for medicolegal purposes. • All congenital anomalies in a foetus may not be diagnosed in routine obstetric ultrasound.

R



MR SUMIT AGE 28 YRS 26-2-2022 M CHEST PA VIEW
ONEPLUS ULTRASOUND LAB, 47-HARSH VIHAR, PITAMPURA

WEI V A T S E T A V I E M M C H E S T P A V I E M
5202-5-2525 28 Y P S A C E T I M U S M B
A P U M A T A M P U K A V I H A B ' P I T A M P U K A
H A B ' T A H A P 2 H V I H A B ' P I T A M P U K A
O I E P C U S U T P A S O U I D I A B ' T A H A P 2 H V I H A B ' P I T A M P U K A



В