



BMI CHART

Date: 11/10/24

Name: Mrs. Sheetal Sharma Age: 62 yrs

Sex: M / F

BP: _____ Height (cms): _____ Weight(kgs): _____ BMI: _____

WEIGHT lbs	100	105	110	115	120	125	130	135	140	145	150	155	160	165	170	175	180	185	190	195	200	205	210	215
kgs	45.5	47.7	50.0	52.3	54.5	56.8	59.1	61.4	63.6	65.9	68.2	70.5	72.7	75.0	77.3	79.5	81.8	84.1	86.4	88.6	90.9	93.2	95.5	97.7
HEIGHT In/cm	Underweight					Healthy					Overweight					Obese			Extremely Obese					
5'0" - 152.4	19	20	21	22	23	24	25	26	27	28	29	30	31	32	33	34	35	36	37	38	39	40	41	42
5'1" - 154.9	18	19	20	21	22	23	24	25	26	27	28	29	30	31	32	33	34	35	36	37	38	39	40	
5'2" - 157.4	18	19	20	21	22	23	24	25	26	27	28	29	30	31	32	33	34	35	36	37	38	39		
5'3" - 160.0	17	18	19	20	21	22	23	24	25	26	27	28	29	30	31	32	33	34	35	36	37	38		
5'4" - 162.5	17	18	19	20	21	22	23	24	25	26	27	28	29	30	31	32	33	34	35	36	37			
5'5" - 165.1	16	17	18	19	20	21	22	23	24	25	26	27	28	29	30	31	32	33	34	35	36			
5'6" - 167.6	16	17	18	19	20	21	22	23	24	25	26	27	28	29	30	31	32	33	34	35				
5'7" - 170.1	15	16	17	18	19	20	21	22	23	24	25	26	27	28	29	30	31	32	33	34				
5'8" - 172.7	15	16	17	18	19	20	21	22	23	24	25	26	27	28	29	30	31	32	33	34				
5'9" - 176.2	14	15	16	17	18	19	20	21	22	23	24	25	26	27	28	29	30	31	32	33				
5'10" - 177.8	14	15	16	17	18	19	20	21	22	23	24	25	26	27	28	29	30	31	32	33				
5'11" - 180.3	14	15	16	17	18	19	20	21	22	23	24	25	26	27	28	29	30	31	32	33				
6'0" - 182.8	13	14	15	16	17	18	19	20	21	22	23	24	25	26	27	28	29	30	31	32				
6'1" - 185.4	13	14	15	16	17	18	19	20	21	22	23	24	25	26	27	28	29	30	31	32				
6'2" - 187.9	12	13	14	15	16	17	18	19	20	21	22	23	24	25	26	27	28	29	30	31				
6'3" - 190.5	12	13	14	15	16	17	18	19	20	21	22	23	24	25	26	27	28	29	30	31				
6'4" - 193.0	12	13	14	15	16	17	18	19	20	21	22	23	24	25	26	27	28	29	30	31				

Doctors Notes:

Signature



UHID	12918037	Date	11/01/2024		
Name	Mrs. Sheetal Sharma	Sex	Female	Age	42
OPD	Pap	Health Check Up			

SIB Dr. Sheetal:

Drug allergy: → No
 Sys illness:

42/F P2L2 A1 - Prev ~~done~~ USG ~~TL~~ not done.

No fresh Complaint
 k/clo Epilepsy on medication at age of 16 yrs.

AMP → 4/1/24.
 Regular Cycle / Moderate flow 4 days / Every 16-28 days.
 o/h/o Cyst in breast (recurrent) benign
 Adv.

Father → DM, liver cirrhosis

Mother → HTN

Aunt (Paternal) → ? uterus related.

last Pap done 1yr ago → Negative

— Pap Smear after 10-16 of menses.

— Counselling for HPV Vaccine for daughter.

— Mammogram every 1yr
 — USG AFP every 1yr
 — Pap Smear every 3yrs



UHID	12918037	Date	11/01/2024		
Name	Mrs. Sheetal Sharma	Sex	Female	Age	42
OPD	Opthal 14	Health Check Up			

Cl₀ → Pre-glucosa. (Unif Medial^m keroprox)

Drug allergy: → Not Know
 Sys illness: → NO

Habit: → NO

W/G → NO

F/H/O → Unclebel ghuma)

Unclebel → RE → 6/60 (Blf)
 LG → 6/60

Ref. → RE → 3.00 @ 6/6
 LG → 3.00 @ 6/6
 Add → + 1.25 → N6

(Apos. Same as P.U.P.)

I.O.P. → RE → 18.1
 LG → 17.2

All up

C.K.J
 20 - 20 rule
 +
 20mm / 30mi
 +
 20pd / 30sq
 (rest)

* Soft drops. (1) + (1) + (1)
 Hmehy



UHID	12918037	Date	11/01/2024		
Name	Mrs. Sheetal Sharma	Sex	Female	Age	42
OPD	Dental 12	Health Check Up			

Drug allergy:
 Sys illness:

O/E - Stains +
 - Calculus +

- Attrition $\bar{0} \frac{\quad}{6 \mid 6}$

- Carious $\bar{0} \frac{\quad}{\quad \mid 7}$

Treatment

① Scaling (Cleaning)

② Filling $\bar{0} \frac{\quad}{6 \mid 6}$

A. Injeti



MC-5837

REF. DOCTOR :

PATIENT NAME : MRS.SHEETAL SHARMA

CODE/NAME & ADDRESS : C000045507

FORTIS VASHI-CHC -SPLZD
FORTIS HOSPITAL # VASHI,
MUMBAI 440001

ACCESSION NO : 0022XA001959

PATIENT ID : FH.12918037

CLIENT PATIENT ID: UID:12918037

ABHA NO :

AGE/SEX : 42 Years Female

DRAWN : 11/01/2024 10:59:00

RECEIVED : 11/01/2024 10:59:11

REPORTED : 11/01/2024 14:27:12

CLINICAL INFORMATION :

UID:12918037 REQNO-1649169

CORP-OPD

BILLNO-150124OPCR001982

BILLNO-150124OPCR001982

Test Report Status	Results	Biological Reference Interval	Units
Final			

CLINICAL PATH - STOOL ANALYSIS

STOOL; OVA & PARASITE

PHYSICAL EXAMINATION,STOOL

COLOUR

BROWN

METHOD : VISUAL
CONSISTENCY

WELL FORMED

METHOD : VISUAL
MUCUS

NOT DETECTED

NOT DETECTED

METHOD : VISUAL
VISIBLE BLOOD
METHOD : VISUAL

ABSENT

ABSENT

CHEMICAL EXAMINATION,STOOL

OCCULT BLOOD

METHOD : GUAIAC ACID METHOD

NOT DETECTED

NOT DETECTED

MICROSCOPIC EXAMINATION,STOOL

PUS CELLS

1-2

/hpf

METHOD : MICROSCOPIC EXAMINATION

RED BLOOD CELLS

NOT DETECTED

NOT DETECTED

/HPF

METHOD : MICROSCOPIC EXAMINATION

CYSTS

NOT DETECTED

NOT DETECTED

METHOD : MICROSCOPIC EXAMINATION

OVA

NOT DETECTED

NOT DETECTED

METHOD : MICROSCOPIC EXAMINATION

LARVAE

NOT DETECTED

NOT DETECTED

METHOD : MICROSCOPIC EXAMINATION

TROPHOZOITES

NOT DETECTED

NOT DETECTED

METHOD : MICROSCOPIC EXAMINATION

Rekha N

Dr. Rekha Nair, MD
(Reg No. MMC 2001/06/2354)
Microbiologist



View Details



View Report

PERFORMED AT :

Agilus Diagnostics Ltd.
Hiranandani Hospital-Vashi, Mini Seashore Road, Sector 10,
Navi Mumbai, 400703
Maharashtra, India
Tel : 022-39199222,022-49723322,
CIN - U74899PB1995PLC045956
Email : -



Patient Ref. No. 2200000895987



PATIENT NAME : MRS.SHEETAL SHARMA

REF. DOCTOR :

CODE/NAME & ADDRESS : C000045507
 FORTIS VASHI-CHC -SPLZD
 FORTIS HOSPITAL # VASHI,
 MUMBAI 440001

ACCESSION NO : 0022XA001959
PATIENT ID : FH.12918037
CLIENT PATIENT ID: UID:12918037
ABHA NO :

AGE/SEX : 42 Years Female
DRAWN : 11/01/2024 10:59:00
RECEIVED : 11/01/2024 10:59:11
REPORTED : 11/01/2024 14:27:12

CLINICAL INFORMATION :

UID:12918037 REQNO-1649169
 CORP-OPD
 BILLNO-150124OPCR001982
 BILLNO-150124OPCR001982

Test Report Status	Results	Biological Reference Interval	Units
Final			

REMARK

YEAST CELL DETECTED (FEW)

Interpretation(s)

**** End Of Report ****

Please visit www.agilusdiagnostics.com for related Test Information for this accession

Rekha N

Dr. Rekha Nair, MD
 (Reg No. MMC 2001/06/2354)
 Microbiologist



View Details



View Report

PERFORMED AT :

Agilus Diagnostics Ltd.
 Hiranandani Hospital-Vashi, Mini Seashore Road, Sector 10,
 Navi Mumbai, 400703
 Maharashtra, India
 Tel : 022-39199222, 022-49723322,
 CIN - U74899PB1995PLC045956
 Email : -



Patient Ref. No. 22000000895987

PATIENT NAME : MRS.PRABHA NARAYANRAO GORE		REF. DOCTOR :	
CODE/NAME & ADDRESS : C000045507	ACCESSION NO : 0022XA001957	AGE/SEX : 70 Years Female	DRAWN : 11/01/2024 10:32:00
FORTIS VASHI-CHC -SPLZD	PATIENT ID : FH.12918252	RECEIVED : 11/01/2024 10:32:28	REPORTED : 11/01/2024 12:12:15
FORTIS HOSPITAL # VASHI,	CLIENT PATIENT ID: UID:12918252		
MUMBAI 440001	ABHA NO :		

CLINICAL INFORMATION :

UID:12918252 REQNO-1649284
 CORP-OPD
 BILLNO-150124OPCS002008
 BILLNO-150124OPCS002008

Test Report Status	Final	Results	Biological Reference Interval	Units
--------------------	-------	---------	-------------------------------	-------

CLINICAL PATH - STOOL ANALYSIS

STOOL: OVA & PARASITE

PHYSICAL EXAMINATION,STOOL

COLOUR	BROWN		
METHOD : VISUAL			
CONSISTENCY	WELL FORMED		
METHOD : VISUAL			
MUCUS	ABSENT	NOT DETECTED	
METHOD : VISUAL			
VISIBLE BLOOD	ABSENT	ABSENT	
METHOD : VISUAL			

CHEMICAL EXAMINATION,STOOL

OCCULT BLOOD	NOT DETECTED	NOT DETECTED	
METHOD : GUAIAC ACID METHOD			

MICROSCOPIC EXAMINATION,STOOL

PUS CELLS	0-1		/hpf
METHOD : MICROSCOPIC EXAMINATION			
RED BLOOD CELLS	NOT DETECTED	NOT DETECTED	/HPF
METHOD : MICROSCOPIC EXAMINATION			
CYSTS	NOT DETECTED	NOT DETECTED	
METHOD : MICROSCOPIC EXAMINATION			
OVA	NOT DETECTED		
METHOD : MICROSCOPIC EXAMINATION			
LARVAE	NOT DETECTED	NOT DETECTED	
METHOD : MICROSCOPIC EXAMINATION			
TROPHOZOITES	NOT DETECTED	NOT DETECTED	
METHOD : MICROSCOPIC EXAMINATION			

Rekha N

Dr. Rekha Nair, MD
 (Reg No. MMC 2001/06/2354)
 Microbiologist



View Details



View Report

PERFORMED AT :

Agilus Diagnostics Ltd.
 Hiranandani Hospital-Vashi, Mini Seashore Road, Sector 10,
 Navi Mumbai, 400703
 Maharashtra, India
 Tel : 022-39199222,022-49723322,
 CIN - U74899PB1995PLC045956
 Email : -



Patient Ref. No. 22000000895985


PATIENT NAME : MRS.PRABHA NARAYANRAO GORE		REF. DOCTOR :
CODE/NAME & ADDRESS : C000045507	ACCESSION NO : 0022XA001957	AGE/SEX : 70 Years Female
FORTIS VASHI-CHC -SPLZD	PATIENT ID : FH.12918252	DRAWN : 11/01/2024 10:32:00
FORTIS HOSPITAL # VASHI,	CLIENT PATIENT ID: UID:12918252	RECEIVED : 11/01/2024 10:32:28
MUMBAI 440001	ABHA NO :	REPORTED : 11/01/2024 12:12:15

CLINICAL INFORMATION :

UID:12918252 REQNO-1649284
 CORP-OPD
 BILLNO-150124OPCS002008
 BILLNO-150124OPCS002008

Test Report Status	Final	Results	Biological Reference Interval	Units
--------------------	-------	---------	-------------------------------	-------

Interpretation(s)****End Of Report****Please visit www.agilusdiagnostics.com for related Test Information for this accession

Rekha. N


Dr. Rekha Nair, MD
 (Reg No. MMC 2001/06/2354)
 Microbiologist

Page 2 Of 2



View Details



View Report

PERFORMED AT :

Agilus Diagnostics Ltd.
 Hiranandani Hospital-Vashi, Mini Seashore Road, Sector 10,
 Navi Mumbai, 400703
 Maharashtra, India
 Tel : 022-39199222,022-49723322,
 CIN - U74899PB1995PLC045956
 Email : -



Patient Ref. No. 27000000895985

12918037
42 Years

SHEETAL SHARMA
Female

1/11/2024 9:59:32 AM

Hee
shows rhythm abnormality
No significant

Rate 62 . Sinus rhythm.....normal P axis, V-rate 50- 99
Short PR interval.....PR <110ms

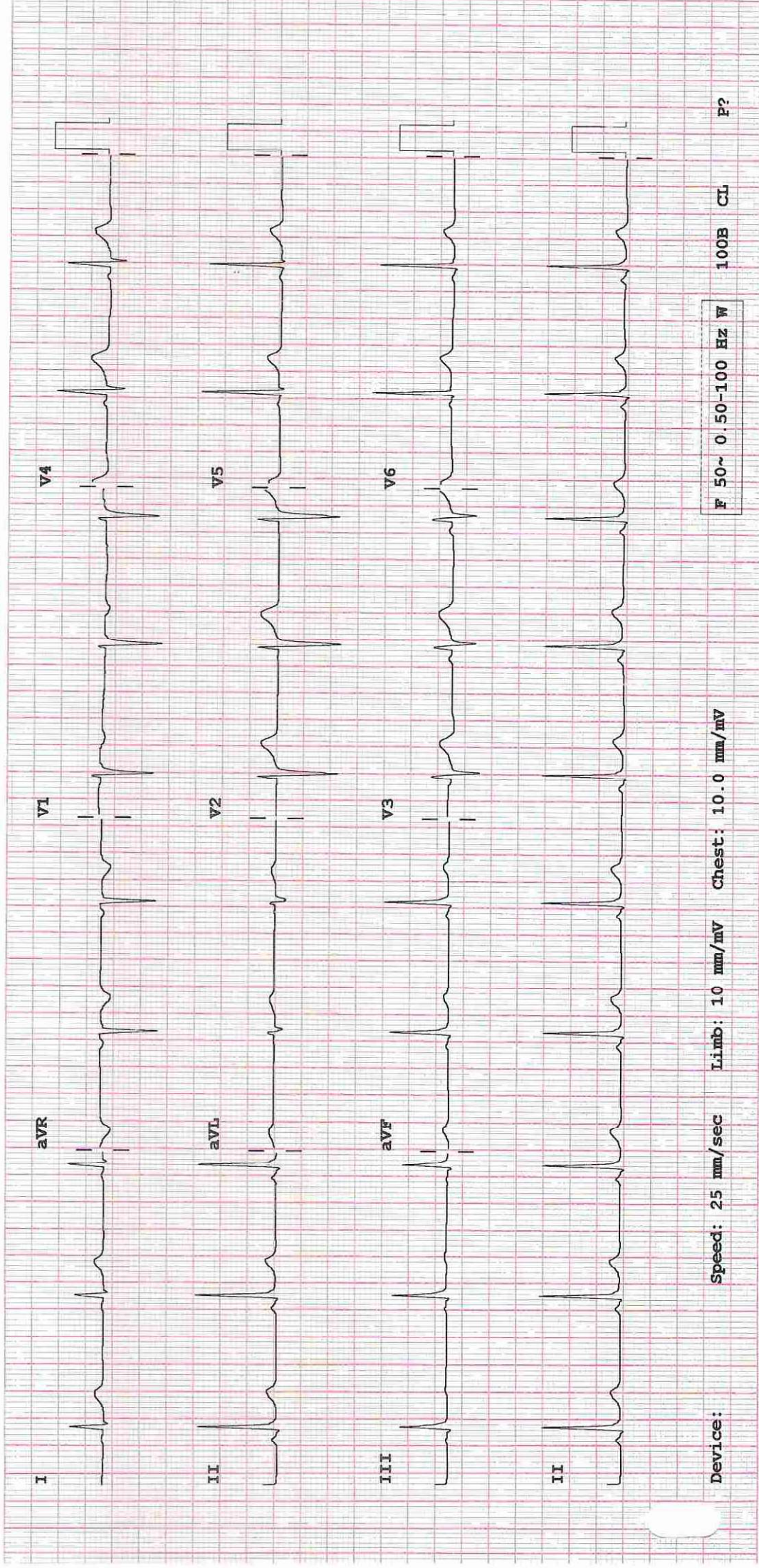
PR 94
QRSD 90
QT 384
QTc 390

--AXIS--
P 45
QRS 65
T 33

12 Lead; Standard Placement

- BORDERLINE ECG -

Unconfirmed Diagnosis



Device: Speed: 25 mm/sec Limb: 10 mm/mV Chest: 10.0 mm/mV

F 50~ 0.50-100 Hz W

100B CL P?



DEPARTMENT OF NIC

Date: 11/Jan/2024

Name: Mrs. Sheetal Sharma
Age | Sex: 42 YEAR(S) | Female
Order Station : FO-OPD
Bed Name :

UHID | Episode No : 12918037 | 2104/24/1501
Order No | Order Date: 1501/PN/OP/2401/4254 | 11-Jan-2024
Admitted On | Reporting Date : 11-Jan-2024 14:06:56
Order Doctor Name : Dr.SELF .


TRAD MILL TEST (TMT)

Resting Heart rate	58 bpm
Resting Blood pressure	114/74 mmHg
Medication	Nil
Supine ECG	Normal
Standard protocol	BRUCE
Total Exercise time	09 min47seconds
Maximum heart rate	162 bpm
Maximum blood pressure	129/83 mmHg
Workload achieved	12.60 METS
Reason for termination	Target heart rate achieved

Final Impression :

STRESS TEST IS POSITIVE FOR EXERCISE INDUCED MYOCARDIAL ISCHEMIA AT 12.60 METS AND 90 % OF MAXIMUM PREDICTED HEART RATE.

DR.PRASHANT PAWAR,
DNB(MED),DNB(CARD)


DR.AMIT SINGH,
MD(MED), DM(CARD)

Hiranandani Healthcare Pvt. Ltd.

Mini Sea Shore Road, Sector 10-A, Vashi, Navi Mumbai - 400703.

Board Line: 022 - 39199222 | Fax: 022 - 39133220

Emergency: 022 - 39199100 | Ambulance: 1255

For Appointment: 022 - 39199200 | Health Checkup: 022 - 39199300

www.fortishealthcare.com | vashi@fortishealthcare.com

CIN: U85100MH2005PTC 154823

GST IN : 27AABCH5894D1ZG

PAN NO : AABCH5894D



Hiranandani
HOSPITAL
(A Fortis Network Hospital)

DEPARTMENT OF RADIOLOGY

Date: 11/Jan/2024

Name: Mrs. Sheetal Sharma

Age | Sex: 42 YEAR(S) | Female

Order Station : FO-OPD

Bed Name :

UHID | Episode No : 12918037 | 2104/24/1501

Order No | Order Date: 1501/PN/OP/2401/4254 | 11-Jan-2024

Admitted On | Reporting Date : 11-Jan-2024 10:06:42

Order Doctor Name : Dr.SELF .

X-RAY-CHEST- PA

Findings:

Both lung fields are clear.

The cardiac shadow appears within normal limits.

Trachea and major bronchi appears normal.

Both costophrenic angles are well maintained.

Bony thorax is unremarkable.

DR. YOGINI SHAH
DMRD., DNB. (Radiologist)



(For Billing/Reports & Discharge Summary only)

Patient Name	: Sheetal Sharma	Patient ID	: 12918037
Sex / Age	: F / 42Y 4D	Accession No.	: PHC.7289973
Modality	: US	Scan DateTime	: 11-01-2024 09:56:40
IPID No	: 2104/24/1501	ReportDatetime	: 11-01-2024 12:14:09

USG - WHOLE ABDOMEN

LIVER is normal in size and echogenicity. No IHBR dilatation. No focal lesion is seen in liver. Portal vein appears normal in caliber.

GALL BLADDER is physiologically distended. Gall bladder reveals normal wall thickness. No evidence of calculi in gall bladder. No evidence of pericholecystic collection.

CBD appears normal in caliber.

SPLEEN is normal in size and echogenicity.

BOTH KIDNEYS are normal in size and echogenicity. The central sinus complex is normal. No evidence of calculi/hydronephrosis.

Right kidney measures 9.8 x 4.0 cm.

Left kidney measures 9.0 x 4.0 cm.

PANCREAS is normal in size and morphology. No evidence of peripancreatic collection.

URINARY BLADDER is normal in capacity and contour. Bladder wall is normal in thickness. No evidence of intravesical calculi.

UTERUS is normal in size, measuring 8.3 x 5.0 x 4.2 cm.

Endometrium measures 5 mm in thickness.

Both ovaries are normal.

Right ovary measures 4.4 x 2.3 cm.

Left ovary measures 3.5 x 2.6 cm.

No evidence of ascites.

Impression:

- No significant abnormality is detected.


DR. KUNAL NIGAM
M.D. (Radiologist)