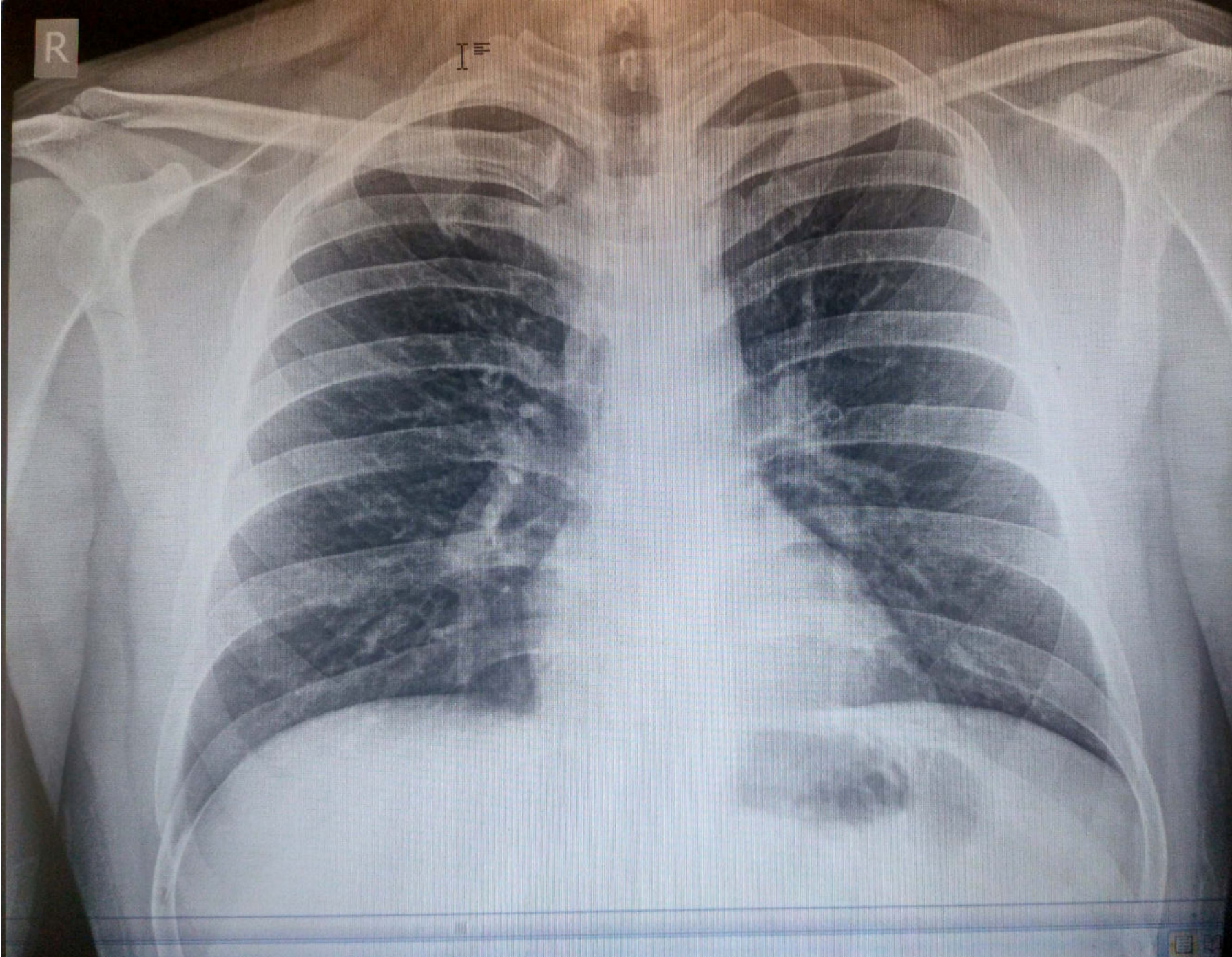
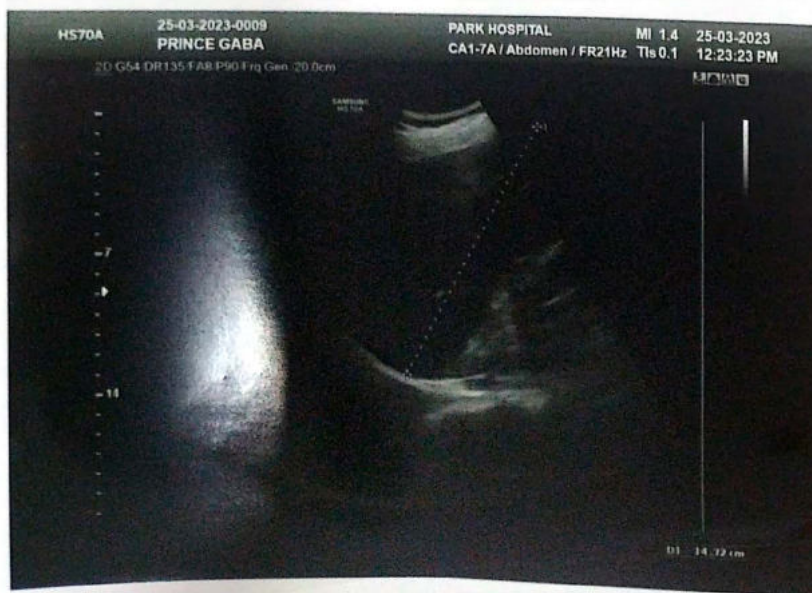
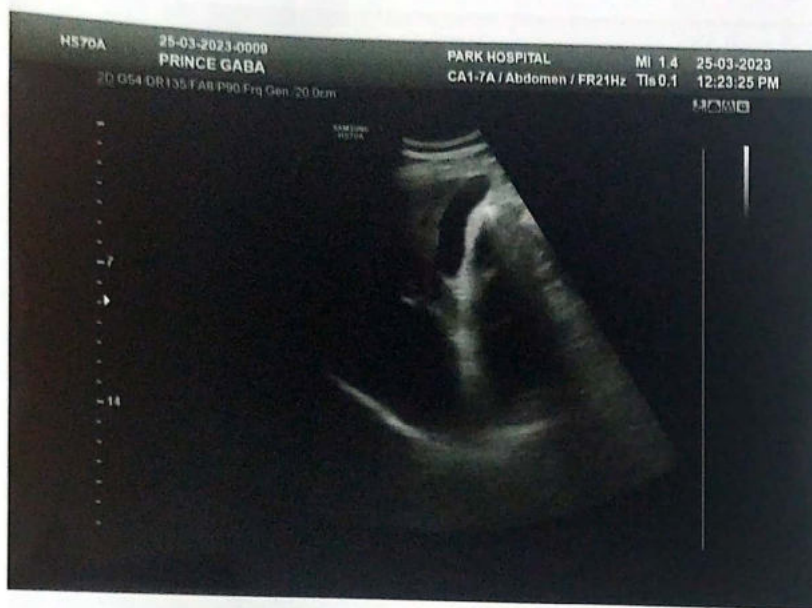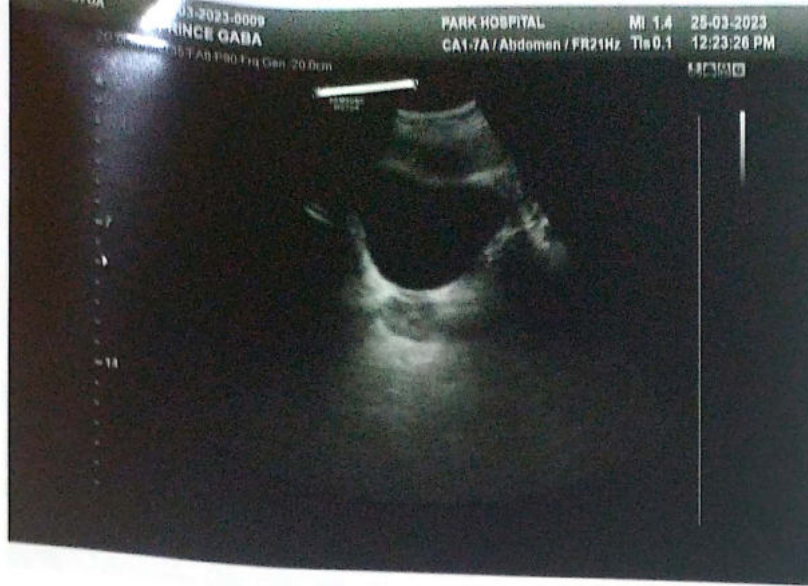PRINCE GABA 33Y/M Chest PA 24063754 3/25/2023 9:45:49 AM
PARK HOSPITAL, SOUTH CITY II, GURGAON, HARYANA





Pt - Pooja Chabra.
age - 33y/M
Dr. Anurag Anand
Date - 25/3/23

Health checkup

VA → 6/6 unaided
→ 6/6

RV → 6/6 unaided.
→ 6/6

RCV → 13
→ 13.

colour vision — normal.

Fundus - Normal



(This is only professional opinion and not the diagnosis, please correlate clinically)

Cert. No. H-2016-0369 Cert. No. MC - 4830 Q Block, South City -II, Sohna Road, Sector-47, Gurgaon, Haryana
Ph.: 0124-4900000 (100 Lines), Toll Free No. : 1800-102-6767, Mob.: 62 62 82 82 35, Email: customercare@parkhospital.in

PARK GROUP OF HOSPITALS : West Delhi - Gurugram - Faridabad - Sonipa - Panipat - Karnal - Ambala - Patiala - Behror - Jaipur



Prince Gaba
33/m



27/3/23

Dermatology -

No skin complaints
ar present

Vitals :

Chief Complaints :

H/O Present Illness :

Acne

Past History :

No actinic
inverventio

Investigation :

Drug Allergies : (if any)

legmies ar
presen

Treatment :



25.5.23



Park Hospital

GROUP SUPER SPECIALITY HOSPITAL




Mr. Pince Gaba

ENT

Dr Anjy

Ear



Vitals :

BP 110/80

wt - 84.3 kg

HT - 5.10 feet

Chief Complaints :

TM

H/O Present Illness :

Nose - septum midline
R turbinate hypertrophy

Past History :

Oral - Grade I tonsil enlargement.

Investigation :

Drug Allergies : (if any)

Treatment :

Adw

PTA




Gurgaon

Q Block South City 11, Sohna Road, Main Sector-47, Gurgaon, Haryana Ph.: 0124-49000000 Fax : 0124-2218733
E-mail : parkmedicenters@gmail.com

● West Delhi ● South Delhi ● Faridabad ● Panipat ● Karnal

the health care providers

the health care providers



Dental

25/3/23

Op: Stain ++, Calculus ++.
Grossly decayed 5/7, Decayed 6/6
Missing 1/67.

- Advised:
- ① scaling & polishing
 - ② Extraction 5/7
 - ③ Adv Implant 1/67.
 - ④ Retraction 6/6



(This is only professional opinion and not the diagnosis, please correlate clinically)

Q Block, South City -II, Sohna Road, Sector-47, Gurgaon, Haryana
Ph.: 0124-4900000 (100 Lines), Toll Free No. : 1800-102-6767, Mob.: 62 62 82 82 35, Email: customercare@parkhospital.in

PARK GROUP OF HOSPITALS : West Delhi - Gurugram - Faridabad - Sonapat - Panipat - Karnal - Ambala - Patiala - Behror - Jaipur



DEPARTMENT OF PATHOLOGY

Patient Name : Mr. PRINCE GABA
MR No : 674626
Age/Sex : 33 Years 9 Months 7 Days / Male
Type : OPD
TPA/Corporate : MEDIWHEEL PVT LTD

Bill Date : 25/03/2023
Reporting Date : 25/03/2023
Sample ID : 115660
Bill/Req. No. : 24063754
Ref Doctor : Dr.RMO

Test	Result	Bio. Ref. Interval	Units	Method
URINE ROUTINE AND MICROSCOPY				
PHYSICAL CHARACTERSTICS				
QUANTITY	30ml	5 - 100	ml	
COLOUR	Pale Yellow	Pale Yellow		Vishal
TURBIDITY	Clear	clear		
SPECIFIC GRAVITY	1.015	1.000-1.030		urinometer
PH	Acidic	Acidic/Alkaline		PH PAPER
CHEMICAL EXAMINATION-1				
UROBILINOGEN	NIL	NIL		Ehrlich
URINE PROTEIN	NIL	NIL	mg/cl	Protein error indicator
BLOOD	NIL	NIL		
URINE BILIRUBIN	NIL	NIL		
GLUCOSE	NIL	NIL	mg/dL	GOD-POD/Benedicts
URINE KETONE	NIL	NIL		SOD.
MICRO.EXAMINATION				
PUS CELL	2-3	0-5	cells/hpf	Microscopic
RED BLOOD CELLS	Nil	0-2	cells/hpf	
EPITHELIAL CELLS	NIL	0-5	cells/hpf	
CASTS	NIL	NIL	/lpf	
CRYSTALS	NIL	NIL	/hpf	

***** END OF THE REPORT *****



Sonia



Sample no.

Dr. SONIA KUMARI

MBBS, MD (PATHOLOGY) Gold medalist

Dr. PRADIP KUMAR

Consultant (Microbiology)

Dr. NISHA TIWARI

MBBS, MD (Microbiology)

USER NM

AMIT1



Cert. No. H-2016-0369 Cert. No. MC - 4830

(This is only professional opinion and not the diagnosis, please correlate clinically)

Q Block, South City -II, Sohna Road, Sector-47, Gurgaon, Haryana Page 1 of 1

Ph.: 0124-4900000 (100 Lines), Toll Free No. : 1800-102-6767, Mob.: 62 62 82 82 35, Email: customercare@parkhospital.in

PARK GROUP OF HOSPITALS : West Delhi - Gurugram - Faridabad - Sonapat - Panipat - Karnal - Ambala - Patiala - Behror - Jaipur



DEPARTMENT OF PATHOLOGY

Patient Name : Mr. PRINCE GABA
MR No : 674626
Age/Sex : 33 Years 9 Months 7 Days / Male
Type : OPD
TPA/Corporate : MEDIWHEEL PVT LTD
Ref Doctor : Dr.RMO
Bill Date : 25/03/2023 9.14 AM
Sample Col Dt/Tm : 25/03/2023 09:54 am
Sample Rec Dt/Tm : 25/03/2023 03:58 pm
Reporting Date : 2023-03-25 00:23:08-01 14:07
Sample ID : 115660
Bill/Req. No. : 24063754

Test	Result	Bio. Ref. Interval	Units	Method
BLOOD SUGAR FASTING				
PLASMA GLUCOSE FASTING	85	60 - 110	mg/dl	GOD TRINDERS

***** END OF THE REPORT *****



Dr. PRADIP KUMAR
Consultant (Microbiology)

Dr. SONIA KUMARI
MD Pathology (Gold Medalist)

Dr. NISHA TIWARI
MBBS, MD (Microbiology)

USER NM AMIT1



(This is only professional opinion and not the diagnosis, please correlate clinically)

Q Block, South City-II, Sohna Road, Sector-47, Gurgaon, Haryana
 Ph.: 0124-4900000 (100 Lines), Toll Free No. : 1800-102-6767, Mob.: 62 62 82 82 35, Email: customer@parkhospital.in

PARK GROUP OF HOSPITALS : West Delhi - Gurugram - Faridabad - Sonapat - Panipat - Karnal - Ambala - Patiala - Behror - Jaipur



DEPARTMENT OF PATHOLOGY

Patient Name : Mr. PRINCE GABA

MR No : 674626

Age/Sex : 33 Years 9 Months 7 Days / Male

Type : OPD

TPA/Corporate : MEDIWHEEL PVT LTD

Bill Date : 25/03/2023

Reporting Date : 25/03/2023

Sample ID : 115660

Bill/Req. No. : 24063754

Ref Doctor : Dr.RMO

Test	Result	Bio. Ref. Interval	Units	Method
------	--------	--------------------	-------	--------

BLOOD GROUPING AND RH FACTOR

BLOOD GROUP	" O " RH POSITIVE			MATRIX GEL
-------------	-------------------	--	--	------------

***** END OF THE REPORT *****



Sample no.

Dr. SÓNIA KUMARI

MBBS, MD (PATHOLOGY) Gold medalist

Dr. PRADIP KUMAR

Consultant (Microbiology)

Dr. NISHA TIWARI

MBBS, MD (Microbiology)

USER NM

AMIT1



Cert. No. H-2016-0369 Cert. No. MC - 4830

(This is only professional opinion and not the diagnosis, please correlate clinically)

Q Block, South City -II, Sohna Road, Sector-47, Gurgaon, Haryana Page 1 of 1

Ph.: 0124-4900000 (100 Lines), Toll Free No. : 1800-102-6767, Mob.: 62 62 82 82 35, Email: customercare@parkhospital.in

PARK GROUP OF HOSPITALS : West Delhi - Gurugram - Faridabad - Sonapat - Panipat - Karnal - Ambala - Patiala - Behror - Jaipur



DEPARTMENT OF PATHOLOGY

Patient Name : Mr. PRINCE GABA

MR No : 674626

Age/Sex : 33 Years 9 Months 7 Days / Male

Type : OPD

TPA/Corporate : MEDIWHEEL PVT LTD

Bill Date : 25/03/2023

Reporting Date : 25/03/2023

Sample ID : 115660

Bill/Req. No. : 24063754

Ref Doctor : Dr.RMO

Test	Result	Bio. Ref. Interval	Units	Method
LFT (LIVER FUNCTION TEST)				
LFT				
TOTAL BILIRUBIN	2.0	H 0 - 1.2	mg/dL	DIAZO
DIRECT BILIRUBIN	0.7	H 0 - 0.4	mg/dL	DIAZO
INDIRECT BILIRUBIN	1.3	H 0.10 - 0.6	mg/dL	CALCULATED
SGOT (AST)	31	0 - 45	U/L	IFCC WITHOUT
SGPT (ALT)	31	0 - 45	U/L	IFCC WITHOUT
ALKALINE PHOSPHATASE	89	30 - 170	IU/L	MODIFIED IFCC
TOTAL PROTEINS	6.0	L 6.4 - 8.0	g/dL	BIURET
ALBUMIN	4.5	3.3 - 5.5	g/dL	BCG DYE
GLOBULIN	1.5	L 2.3 - 4.5	g/dL	CALCULATED
A/G RATIO	3.0	H 1.1 - 2.2		CALCULATED

***** END OF THE REPORT *****



Signature



Sample no.

Dr. SONIA KUMARI

MBBS, MD (PATHOLOGY) Gold medalist

Dr. PRADIP KUMAR

Consultant (Microbiology)

Dr. NISHA TIWARI

MBBS, MD (Microbiology)

USER NM

AMIT1



Cert. No. H-2016-0369 Cert. No. MC - 4830

(This is only professional opinion and not the diagnosis, please correlate clinically)

Q Block, South City -II, Sohna Road, Sector-47, Gurgaon, Haryana Page 1 of 1

Ph.: 0124-4900000 (100 Lines), Toll Free No. : 1800-102-6767, Mob.: 62 62 82 82 35, Email: customercare@parkhospital.in

PARK GROUP OF HOSPITALS ; West Delhi - Gurugram - Faridabad - Sonapat - Panipat - Karnal - Ambala - Patiala - Behror - Jaipur



DEPARTMENT OF PATHOLOGY

Patient Name : Mr. PRINCE GABA
MR No : 674626
Age/Sex : 33 Years 9 Months 7 Days / Male
Type : OPD
TPA/Corporate : MEDIWHEEL PVT LTD

Bill Date : 25/03/2023
Reporting Date : 25/03/2023
Sample ID : 115660
Bill/Req. No. : 24063754
Ref Doctor : Dr.RMO

Test	Result	Bio. Ref. Interval	Units	Method
KFT (RENAL PROFILE)				
KFT				
SERUM UREA	20	10 - 45	mg/dL	UREASE-GLDH
SERUM CREATININE	1.1	0.4 - 1.4	mg/dL	MODIFIED JAFFES
SERUM URIC ACID	5.2	2.5 - 7.0	mg/dL	URICASE
SERUM SODIUM	140	136 - 148	mmol/L	ISE
SERUM POTASSIUM	4.6	3.5 - 5.5	meq/l	ISE
SERUM CALCIUM	9.1	8.5 - 10.5	mg/dL	ARSENAZO III
SERUM PHOSPHORUS	2.8	2.5 - 4.5	mg/dL	AMMONIUM

***** END OF THE REPORT *****



Sample no.

Dr. SONIA KUMARI
 MBBS, MD (PATHOLOGY) Gold medalist

Dr. PRADIP KUMAR
 Consultant (Microbiology)

Sant
Dr. NISHA TIWARI
 MBBS, MD (Microbiology)

USER NM AMIT1



Cert. No. H-2016-0369 Cert. No. MC - 4830

(This is only professional opinion and not the diagnosis, please correlate clinically)

Q Block, South City -II, Sohna Road, Sector-47, Gurgaon, Haryana Page 1 of 1
 Ph.: 0124-4900000 (100 Lines), Toll Free No. : 1800-102-6767, Mob.: 62 62 82 82 35, Email: customercare@parkhospital.in

PARK GROUP OF HOSPITALS : West Delhi - Gurugram - Faridabad - Sonapat - Panipat - Karnal - Ambala - Patiala - Behror - Jaipur



DEPARTMENT OF PATHOLOGY

Patient Name : Mr. PRINCE GABA
MR No : 674626
Age/Sex : 33 Years 9 Months 7 Days / Male
Type : OPD
TPA/Corporate : MEDIWHEEL PVT LTD

Bill Date : 25/03/2023
Reporting Date : 25/03/2023
Sample ID : 115660
Bill/Req. No. : 24063754
Ref Doctor : Dr.RMO

Test	Result	Bio. Ref. Interval	Units	Method
LIPID PROFILE				
TOTAL CHOLESTEROL	153	0 - 250	mg/dL	CHOD -Trinder
SERUM TRIGLYCERIDES	115	60 - 165	mg/dl	GPO-TRINDER
HDL-CHOLESTEROL	41	30 - 70	mg/dl	DIRECT
VLDL CHOLESTEROL	23	6 - 32	mg/dL	calculated
LDL	89	50 - 135	mg/dl	calculated
LDL CHOLESTEROL/HDL RATIO	2.1	1.0 - 3.0	mg/dL	calculated
TOTAL CHOLESTEROL/HDL RATIO	3.7	2.0 - 5.0	mg/dl	calculated

***** END OF THE REPORT *****



Sample no.

Dr. SONIA KUMARI

MBBS, MD (PATHOLOGY) Gold medalist

Dr. PRADIP KUMAR

Consultant (Microbiology)

Dr. NISHA TIWARI

MBBS, MD (Microbiology)

USER NM

AMIT1



(This is only professional opinion and not the diagnosis, please correlate clinically)

Cert. No. H-2016-0369 Cert. No. MC - 4830 Q Block, South City -II, Sohna Road, Sector-47, Gurgaon, Haryana Page 1 of 1

Ph.: 0124-4900000 (100 Lines), Toll Free No. : 1800-102-6767, Mob.: 62 62 82 82 35, Email: customercare@parkhospital.in

PARK GROUP OF HOSPITALS : West Delhi - Gurugram - Faridabad - Sonapat - Panipat - Karnal - Ambala - Patiala - Behror - Jaipur



Park Hospital

GROUP SUPER SPECIALITY HOSPITAL

<u>Measurements</u>	<u>Normal Values</u>	<u>Measurements</u>	<u>Normal Value</u>
IVSD : 0.8cm	(0.6-1.1cm))	LA : 2.8cm	(1.9-4.0cm)
LVID : 5.0cm	(3.7-5.6cm)	LVOT : 1.5cm	
LVPW : 0.8m	(0.6-1.1cm)	AORTA : 3.0cm	(2.0-3.7cm)
EF : 65%	(55% - 80%)	IVSmotion :	Normal / Flat / Paradoxical
Any Other			

CHAMBERS:-

- LV** Normal / Enlarged / Clear / Thrombus /
Contraction Normal LV shows concentric LVH, no gradient across LVOT /Inetic / Intra capillary
Regional wall motion abnormality: Absent/ Present
- LA** Normal /Enlarged / Clear /Thrombus / Myxoma; LAA: Clear / Thrombus
- RA** Normal / Clear / Thrombus, Dilated.
- RV** Normal / Enlarged / Clear / Thrombus / Hypertrophied/ Dilated.
- PERICARDIUM** Normal / Thickening / Calcification / Effusion.

COMMENTS & SUMMARY:-

- All cardiac chambers dimensions are with in normal limits.
- Global LVEF - 65%
- No RWMA
- NORMAL LV FUNCTION
- NO MR / NO AR
- TRACE TR
- No Flow seen across IAS/IVS.
- No Thrombus/Mass in any chamber.
- No Pericardial Effusion.

Please correlate clinically

Navjeet Singh

Dr. NAVJEET SINGH

M.D. (Medicine) D.M (Cardiology).
HOD &.Director Interventional cardiology.



(This is only professional opinion and not the diagnosis, please correlate clinically)

Cert. No. H-2016-0369 Cert. No. MC - 4830

Q Block, South City -II, Sohna Road, Sector-47, Gurgaon, Haryana

Ph.: 0124-4900000 (100 Lines), Toll Free No. : 1800-102-6767, Mob.: 62 62 82 82 35, Email: customercare@parkhospital.in

PARK GROUP OF HOSPITALS : West Delhi - Gurugram - Faridabad - Sonapat - Panipat - Karnal - Ambala - Patiala - Behror - Jaipur

the **health** care providers

the **health** care providers



NAME	: MR.PRINCE GABA	DATE	: 25 / 03 / 2023
Age Sex	: 33 Years / Male	Inpatient No	:
PERFORMED BY	: Dr.NAVJEET SINGH	UHID	: 24063754

TRANS THORACIC ECHO CARDIOGRAPHY REPORT

MITRAL VALVE

Morphology AML: Normal / Thickening / Calcification / Flutter / Vegetation / Non significant Prolapse / SAM

PML: Normal / Thickening / Calcification / Prolapse / Paradoxical Motion / Fixed.
Subvalvular deformity: Present / Absent

Doppler Normal / Abnormal

Mitral Stenosis Present / Absent

Mitral Regurgitation; Absent / Normal / Mild / Trace / Moderate / Severe.

TRICUSPID VALVE

Morphology Normal / Atresia / Thickening / Calcification / Prolapse / Vegetation / Doming.

Doppler Normal / Abnormal

Tricuspid Stenosis : Present / Absent.

Tricuspid Regurgitation; Absent / Normal / Mild / Trace / Moderate / Severe.

PULMONARY VALVE

Morphology Normal / Atresia / Thickening / Calcified / Doming / Vegetation.

Doppler Normal / Abnormal.

Pulmonary stenosis : Present / Absent

Pulmonary regurgitation : Present / Absent

AORTIC VALVE

Morphology Normal / Thickened / Mildly / Calcified / Flutter / Vegetation / Restricted / Opening
No. of Cusps 1 / 2 / 3 / 4

Doppler Normal / Abnormal

Aortic Stenosis : Present / Absent

Aortic regurgitation : Present / Absent / Mild / Trace



(This is only professional opinion and not the diagnosis, please correlate clinically)

Cert. No. H-2015-0369 Cert. No. MC - 4830

Q Block, South City -II, Sohna Road, Sector-47, Gurgaon, Haryana
Ph.: 0124-4900000 (100 Lines), Toll Free No. : 1800-102-6767, Mob.: 62 62 82 82 35, Email: customercare@parkhospital.in

PARK GROUP OF HOSPITALS : West Delhi - Gurugram - Faridabad - Sonapat - Panipat - Karnal - Ambala - Patiala - Behror - Jaipur



DEPARTMENT OF RADIOLOGY

Patient Name	Mr PRINCE GABA	Billed Date	: 25/03/2023	9.14 AM
Reg No	674626	Reported Date	: 25/03/2023	
Age/Sex	33 Years 9 Months 7Days / Male	Req. No.	: 24063754	
Type	OPD	Consultant Doctor	: Dr. RMO	

USG WHOLE ABDOMEN

LIVER : The liver is normal in size 14.3cm **with fatty infiltration**. No evidence of any focal lesion. IHBR is not dilated.

GALL BLADDER: The gall bladder is well distended. No evidence any calculus or mass seen. GB wall thickness with in normal limits. No evidence of pericholecystic fluid is seen.

BILE DUCT :The common bile duct is normal in caliber. Its measures 4.2 mm at porta hepatis. No evidence of calculus is noted in common bile duct.

SPLEEN :The spleen is enlarged in size **12.9cm**. Its echotexture is homogeneous. No evidence of focal lesion is noted.

PANCREAS :The pancreas is normal in size, shape, contours and echotexture.No evidence of solid or cystic mass lesion is noted.MPD is not dilated. No evidence of peripancreatic collection.

KIDNEYS : The bilateral kidneys are normal in size and echotexture. Cortico-medullary differentiation is maintained.There is no evidence of obvious calculus or hydronephrosis.

URINARY BLADDER :The urinary bladder is well distended.It shows uniformly thin walls and sharp mucosa.No evidence of calculus is seen. No evidence of mass or diverticulum is noted.

PROSTATE: Prostate appears normal in shape, size and echotexture.



No evidence of ascites or interbowel free fluid is seen.

No evidence of obvious retroperitoneal or mesantric lymphadenopathy is seen.

IMPRESSION:-

Grade I fatty liver

Mild splenomegaly

To be correlated clinically.

Dr. ANSUL K SHARMA
MBBS,MD
CONSULTANT RADIOLOGIST

Dr. MANJEET SEHRAWAT
MBBS,MD,PDCC
CONSULTANT RADIOLOGIST

Dr. NEENA SIKKA
MBBS,DNB
CONSULTANT RADIOLOGIST



Cert. No. H-2016-0369 Cert. No. MC - 4830

(This is only professional opinion and not the diagnosis, please correlate clinically)

Q Block, South City -II, Sohna Road, Sector-47, Gurgaon, Haryana

Ph.: 0124-4900000 (100 Lines), Toll Free No. : 1800-102-6767, Mob.: 62 62 82 82 35, Email: customercare@parkhospital.in

PARK GROUP OF HOSPITALS : West Delhi - Gurugram - Faridabad - Sonapat - Panipat - Karnal - Ambala - Patiala - Behror - Jaipur



DEPARTMENT OF RADIOLOGY

Patient Name	Mr PRINCE GABA	Billed Date	: 25/03/2023	9.14 AM
Reg No	674626	Reported Date	: 25/03/2023	
Age/Sex	33 Years 9 Months 7Days / Male	Req. No.	: 24063754	
Type	OPD	Consultant Doctor	: Dr. RMO	

X-RAY CHEST AP/PA

X-RAY CHEST P.A. VIEW

Bilateral lungs appears normal.

No focal lung lesion seen.

No evidence of free fluid is seen.

Both hila are normal in size, have equal density and bear normal relationship.

The heart and trachea are central in position and no mediastinal abnormality is visible.

The cardiac size is normal for patient age and view.

The domes of the diaphragms are normal in position, and show smooth outline.

To be correlated clinically



Dr. ANSHU K. SHARMA
MBBS, MD
CONSULTANT RADIOLOGIST

Dr. MANJEET SEHRAWAT
MBBS, MD, PDCC
CONSULTANT RADIOLOGIST

Dr. NEENA SIKKA
MBBS, DNB
CONSULTANT RADIOLOGIST



Cert. No. H-2016-0369 Cert. No. MC - 4830

(This is only professional opinion and not the diagnosis, please correlate clinically)

Q Block, South City -II, Sohna Road, Sector-47, Gurgaon, Haryana

Ph.: 0124-4900000 (100 Lines), Toll Free No. : 1800-102-6767, Mob.: 62 62 82 82 35, Email: customercare@parkhospital.in

Page 1 of 1

PARK GROUP OF HOSPITALS : West Delhi - Gurugram - Faridabad - Sonapat - Panipat - Karnal - Ambala - Patiala - Behror - Jaipur



DEPARTMENT OF PATHOLOGY

Patient Name : Mr. PRINCE GABA

MR No : 674626

Age/Sex : 33 Years 9 Months 7 Days / Male

Type : OPD

TPA/Corporate : MEDIWHEEL PVT LTD

Bill Date : 25/03/2023

Reporting Date : 25/03/2023

Sample ID : 115660

Bill/Req. No. : 24063754

Ref Doctor : Dr.RMO

Test	Result	Bio. Ref. Interval	Units	Method
------	--------	--------------------	-------	--------

THYROID PROFILE

TRI-IODOTHYRONINE (T3)	1.20	0.60 - 1.81	ng/ml	Chemiluminescence
THYROXINE (T4)	8.4	5.01 - 12.45	µg/dL	Chemiluminescence
THYROID STIMULATING HORMONE	3.63	0.5-5.50	µIU/ml	
SPECIMEN TYPE	SERUM			

Method : chemiluminescent immunoassay

Note : Clinical Significance:

Thyroid function tests (TFTs) is a collective term for blood tests used to check the function of the thyroid. TFTs may be requested if a patient is thought to suffer from hyperthyroidism (overactive thyroid) or hypothyroidism (underactive thyroid), or to monitor the effectiveness of either thyroid-suppression or hormone replacement therapy. It is also requested routinely in conditions linked to thyroid disease, such as atrial fibrillation and anxiety disorder. A TFT panel typically includes thyroid hormones such as thyroid-stimulating hormone (TSH, thyrotropin) and thyroxine (T4), and triiodothyronine (T3) depending on local laboratory policy.

Note: Please correlate with clinical condition

***** END OF THE REPORT *****



Signature



Sample no.

Dr. SONIA KUMARI

MBBS, MD (PATHOLOGY) Gold medalist

Dr. PRADIP KUMAR

Consultant (Microbiology)

Dr. NISHA TIWARI

MBBS, MD (Microbiology)

USER NM

DINESH



(This is only professional opinion and not the diagnosis, please correlate clinically)

Cert. No. H-2016-0369 Cert. No. MC - 4830 Q Block, South City -II, Sohna Road, Sector-47, Gurgaon, Haryana Page 1 of 1

Ph.: 0124-4900000 (100 Lines), Toll Free No. : 1800-102-6767, Mob.: 62 62 82 82 35, Email: customer@parkhospital.in

PARK GROUP OF HOSPITALS : West Delhi - Gurugram - Faridabad - Sonapat - Panipat - Karnal - Ambala - Patiala - Behror - Jaipur



DEPARTMENT OF PATHOLOGY

Patient Name : Mr. PRINCE GABA

MR No : 674626

Age/Sex : 33 Years 9 Months 7 Days / Male

Type : OPD

TPA/Corporate : MEDIWHEEL PVT LTD

Bill Date : 25/03/2023

Reporting Date : 25/03/2023

Sample ID : 115660

Bill/Req. No. : 24063754

Ref Doctor : Dr.RMO

Test	Result	Bio. Ref. Interval	Units	Method
ESR (WESTERGREN)				
E.S.R. - II HR.	20		mm II Hr.	Westergren

***** END OF THE REPORT *****



Handwritten signature



Sample no.

Dr. SONIA KUMARI

MBBS, MD (PATHOLOGY) Gold medalist

Dr. PRADIP KUMAR

Consultant (Microbiology)

Dr. NISHA TIWARI

MBBS, MD (Microbiology)

USER NM : AMIT1



(This is only professional opinion and not the diagnosis, please correlate clinically)

Cert. No. H-2016-0369 Cert. No. MC - 4830

Q Block, South City -II, Sohna Road, Sector-47, Gurgaon, Haryana Page 1 of 1

Ph.: 0124-4900000 (100 Lines), Toll Free No. : 1800-102-6767, Mob.: 62 62 82 82 35, Email: customercare@parkhospital.in

PARK GROUP OF HOSPITALS : West Delhi - Gurugram - Faridabad - Sonapat - Panipat - Karnal - Ambala - Patiala - Behror - Jaipur



DEPARTMENT OF PATHOLOGY

Patient Name : Mr. PRINCE GABA
MR No : 674626
Age/Sex : 33 Years 9 Months 7 Days / Male
Type : OPD
TPA/Corporate : MEDIWHEEL PVT LTD

Bill Date : 25/03/2023
Reporting Date : 25/03/2023
Sample ID : 115660
Bill/Req. No. : 24063754
Ref Doctor : Dr.RMO

Test	Result	Bio. Ref. Interval	Units	Method
CBC				
HAEMOGLOBIN	14.8	12 - 16	gm/dL	COLORIMETRY
TOTAL LEUCOCYTE COUNT	4900	4000-11000	/ μ L	ELECTRICAL
DIFFERENTIAL COUNT				
NEUTROPHILS	64	40.0 - 80.0	%	FLOW CYTOMETRY
LYMPHOCYTES	26	20.0 - 40.0	%	FLOW CYTOMETRY
MONOCYTES	07	2.0 - 10.0	%	FLOW CYTOMETRY
EOSINOPHILS	03	0.0 - 5.0	%	FLOW CYTOMETRY
BASOPHILS	00	0.0 - 2.0	%	FLOW CYTOMETRY
RED BLOOD CELL COUNT	4.5	3.5 - 5.5	millions/ μ L	ELECTRICAL
PACKED CELL VOLUME	46.2	35.0 - 50.0	%	ELECTRICAL
MEAN CORPUSCULAR VOLUME	102.4	<i>H</i> 83 - 101	fL	ELECTRICAL
MEAN CORPUSCULAR HAEMOGLOBIN	32.8	<i>H</i> 27 - 31	Picogrames	CALCULATED
MEAN CORPUSCULAR HB CONC	32.0	<i>L</i> 33 - 37	g/dl	CALCULATED
PLATELET COUNT	129	<i>L</i> 150 - 450	thou/ μ L	ELECTRICAL
RDW	12.1	11.6 - 14.5	%	CALCULATED

***** END OF THE REPORT *****



Sample no.

Dr. SONIA KUMARI

MBBS, MD (PATHOLOGY) Gold medalist

Dr. PRADIP KUMAR

Consultant (Microbiology)

Dr. NISHA TIWARI

MBBS, MD (Microbiology)

USER NM

AMIT1



Cert. No. H-2016-0369 Cert. No. MC - 4830

(This is only professional opinion and not the diagnosis, please correlate clinically)

Q Block, South City -II, Sohna Road, Sector-47, Gurgaon, Haryana Page 1 of 1

Ph.: 0124-4900000 (100 Lines), Toll Free No. : 1800-102-6767, Mob.: 62 62 82 82 35, Email: customercare@parkhospital.in

PARK GROUP OF HOSPITALS : West Delhi - Gurugram - Faridabad - Sonapat - Panipat - Karnal - Ambala - Patiala - Behror - Jaipur