

DAKSH HOSPITAL

396 - 397, Gandhi Nagar, Scheme No. 8, ALWAR -301001

Ref. No.

Date.....

MEDICAL EXAMINATION REPORT

Mediwheel (BOB)

Name: Mrs Beena Meena

Age: 37 yrs Sex:Female

Date: 05/10/2023

General Physical Examination


Height	: 157 cm.	Weight	: 66 kg
Pulse	: 82 bpm	BP	: 110/70 mm/hg.
Temp.	: 97.7 °F	Respiration SpO2	: 99 %
BMI	: 26.8		

Systemic Exam:- NORMALDental Check up :- NORMALEye check-up :- NORMALSkin Check up:- NORMALENT Check up:- NORMALGynae Check up:- PLUMMImpression:-

Paps smear taken
 pt normal on examination.
 pt has PROMPT - needs further evaluation

Recommendation:-

MBSAS / HCV /
 ANA
 w/ Reducron



Dr. Mukesh Kumar Gupta
 MD Gen. Medicine
 Reg. No 5423/16262

डॉ० मुकेश गुप्ता
 M.D.F.C.C.S.
 फिजिशियन एवं मधुमेह रोग विशेषज्ञ
 दक्ष हॉस्पिटल, अलवर
 रजि० नं०-5423/16262

Results

Run Date 05/10/2023 09:54:10 AM

Operator DAKSH

Last Name

Sample ID 4

First Name MRS BEENA MEENA

Department

Gender Female

Age

Physician DR. MUKESH GUPTA M.D

Patient ID AUTO_PID16512

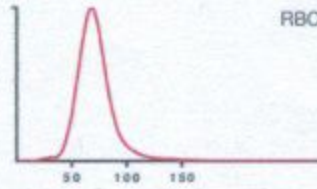
Type Woman

Date of birth

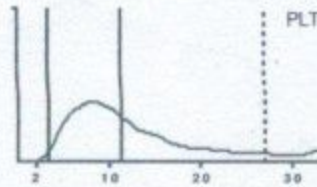
Sample comments

Susp. Pathologies
Poikilocytosis

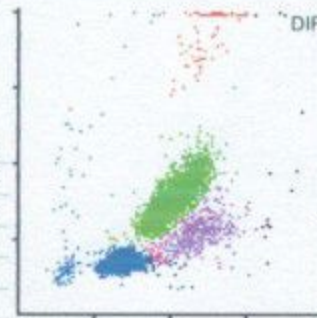
				Range
RBC	4.29	*	10 ⁶ /μL	3.80 - 5.50
HGB	10.1		g/dL	11.5 - 15.2
HCT	31.0	L*	%	35.0 - 46.0
MCV	72.2	*	μm ³	77.0 - 97.0
MCH	23.4	L	pg	26.0 - 34.0
MCHC	32.5		g/dL	32.0 - 35.0
RDW-CV	18.6	H	%	11.0 - 17.0
RDW-SD	53.1	h	μm ³	37.0 - 49.0



				Range
PLT	300		10 ³ /μL	150 - 450
PCT	0.33		%	0.15 - 0.40
MPV	11.1	h	μm ³	8.0 - 11.0
PDW	18.6		μm ³	11.0 - 22.0
P-LCC	122		10 ³ /μL	44 - 140
P-LCR	40.6		%	18.0 - 50.0



				Range
WBC	7.91		10 ³ /μL	3.50 - 10.00
	#			
NEU	4.78		1.60 - 7.00	60.6
LYM	2.68		1.00 - 3.00	34.0
MON	0.20		0.20 - 0.80	2.6
EOS	0.15		0.00 - 0.50	1.9
BAS	0.07		0.00 - 0.15	0.9
LIC	0.03		0.00 - 0.10	0.3



Signature
Dr. R. S. GUPTA
M.D. (Pathology) (MCH)
M.D. (Pathology) (MCH)
D. R. S. GUPTA
M.D. (Pathology)
Signature

Date :-05/10/2023

Name :- MRS. BEENA MEENA

Age & Sex :- 37 Yrs/ Female

Refd. :- Dr Mukesh Gupta M.D.

	TEST NAME	RESULT	REFERENCE RANGE	
	ESR	10	00 -20 mm/hrs	
	Blood Group & Rh Factor	O ⁺ POSITIVE		
	HbA1C	4.5	4 - 5.6%	
	Blood Sugar (F)	81.6	< 70 - 100 mg/dl	
	Blood Sugar (PP)	105.4	< 140 mg/dl	
	Urine Sugar (F)	NIL	-	
	Urine Sugar (PP)	NIL	-	
LIVER	S.Bilirubin Total	0.90	0.30 - 1.20 mg/dl	
	S.Bilirubin Direct	0.20	0.10 - 0.30 mg/dl	
	S.Bilirubin Indirect	0.70	0.30 - 0.90 mg/dl	
	S.G.O.T.	56	> 37 u/l	
	S.G.P.T.	65	> 40 u/l	
	S.Alk. Phosp.	175	80 - 306 u/l	
	G.G.T.	32	5 -40 u/l	
	Total Protein	6.8	6.5 - 8.5 gm/dl	
	Albumin	3.7	3.8 - 5.4 gm/dl	
	Globulin	3.1	2.3 - 3.5 gm/dl	
	A/G Ratio	1.2	-	
AST/ALT Ratio	0.8	-		
KIDNEY	Blood Urea	24.1	15 -45 mg/dl	
	S.Creatinine	0.78	0.60 - 1.30 mg/dl	
	BUN	18.0	6 -24 mg/dl	
	S.Uric Acid	5.0	M 3.1 - 7.0, F 2.5 - 5.6 mg/dl	
	BUN/Creatinine Ratio	24.3	-	
LIPID PROFILE	Total Cholesterol	160.1	Up to 200 mg/dl	
	S.HDL	44.1	30 - 70 mg/dl	
	S.LDL	70.1	Up to 170 mg/dl	
	S.VLDL	36.1	5.0 - 40 mg/dl	
	S. Triglycerides	180.1	Up to 170 mg/dl	
	LDL/HDL Ratio	1.5	-	
	Total Cholesterol/ HDL Ratio	3.6	-	
THYROID	T3	85	40 - 181 ng/dl	
	T4	6.8	4.6 - 10.5 µg/dl	
	TSH	4.3	0.30 - 5.0 mIU/l	
		URINE EXAMINATION	Microscopic Examination :	
General/Chemical Examination:			RBC	3-4
	Colour	Pale Yellow	WBC	1-2
	Reaction	Acidic	Epithelial Cells	0-1
	Specific Gravity	QNS	Cast	Absent
	Appearance	Clear	Crystal	Absent
	Albumin	Nil	Spermatozoa	Absent
	Sugar	Nil	Amorphous Sediments	Absent
			Other	Absent
X-RAY CHEST		NORMAL STUDY		
		STOOL EXAMINATION	Microscopic Examination :	
General/ Chemical Examination:			RBC	-
	Colour	-	WBC	-
	Consistency	-	Ova & Parasites	-
	PH	-		
	Reducing Substances	-		

Dr. R. S. GUPTA
MD (Pathology) (MAHE)
RMC No. 7924/19778

TECHNOLOGIST

Investigations have their own limitations regarding the sensitivity & specificity of individual assay procedures, Isolated laboratory investigations never confirm the final diagnosis of the disease. They only help in arriving at a diagnosis in conjunction with clinical presentation and other related investigations. Report is not valid for medico-legal purpose subject to ALWAR jurisdiction only.

Date :- 05/10/2023

Name :- Mrs. Beena Meena

Refd. :- Dr Mukesh Gupta MD

Age & Sex :- 37Yrs/ Female

CYTO-PATHOLOGY

PAP SMEAR

1. Specimen type	Received two conventional smears.
2. Specimen adequacy	Smears are satisfactory for evaluation.
3. Microscopic finding	Smears are moderately cellular comprises of predominantly intermediate with mature superficial squamous epithelial cells arranged in clusters & scattered singly.
4. Inflammation	Not seen
5. Bacilli	Not seen
6. Endocervical cells	Not seen
7. Koilocytic changes	Not seen
8. Trichomonas	Not seen
9. Dysplasia	Nil
10. Neoplasia	Nil
11. Endometrial cells	Nil

Impression:- Negative for intraepithelial lesion or malignancy


डॉ. मुकेश गुप्ता
MBBS, D.C.S.
फिजिशियन & सिटीजन विरोषज्ञ
दक्ष हॉस्पिटल, अलवर
रजि० नं०-5423/16262


Dr. R.S. GUPTA
MD (Pathology) (MAHE)
RMC No. 7924/19778

Doctor


TECHNOLOGIST

All investigation have their own limitations regarding the sensitivity & specificity of individual assay procedures, isolated laboratory investigations never confirm the final diagnosis of the disease. They only help in arriving at a diagnosis in conjunction with clinical presentation and other related investigations. Report is not valid for medico-legal purpose subject to ALWAR jurisdiction only.



दक्ष हॉस्पिटल

396, गाँधी नगर स्कीम नं.8, अलवर (राज०) ☎ 0144-2703340

Sonography / 2D Echo Cardiography / Doppler Report

NAME :- MRS BEENA MEENA/F/37 YRS

5-Oct-23

BOB HEALTH CHECKUP

U.S.G. OF ABDOMEN & PELVIS

LIVER

Liver is normal in size shape with normal echo-texture. Intra hepatic biliary radicals Are not dilated. No evidence of focal or diffuse lesion.

GALL BLADDER

Gall bladder is normal.

PANCREAS

Pancreas is normal in size, shape & echo-texture. No evidence of focal or diffuse lesion. MPD not dilated.

SPLEEN

Normal in size with normal shape & echo- texture. Spleen vein is normal. No evidence of focal or diffuse lesion

KIDNEY

Both kidneys are normal.

URINARY BLADDER

UB is normal.

UTERUS:

Uterus is **enlarged** in size (10.5x4.4x5.4cm) with homogenous echo-texture. Endometrial 12 mm in thickness & echo genicity

OVARIES:

Both ovaries are normal.

Advice- follow up/ hormonal study review at higher center for confirmation

Please correlate clinically. USG accuracy is 95 % due to technical limitations as well as inaccuracies inherent in the laboratory and statistical analysis biological process.
This report is not valid for medico-legal cases


Dr. Mukesh Kumar Gupta

Physician & Sonologist

DR. MUKESH GUPTA

SONOLOGIST

RM 5423/16262

Physician & Sonologist
Dr. Mukesh Kumar Gupta



"भ्रूण लिंग परीक्षण की शिकायत
104 टोल फ्री सेवा पर भी की
जा सकती है"

भ्रूण लिंग परीक्षण की शिकायत 104 टोल फ्री सेवा पर भी की जा सकती है।



दक्ष हॉस्पिटल

396, गाँधी नगर स्कीम नं.8, अलवर (राज०) ☎ 0144-2703340

Sonography / 2D Echo Cardiography / Doppler Report

2D/ ECHO REPORT

Name: - Mrs Beena Meena

Age: - 37 Yrs

Date: - 5-Oct-23

Reg. No.:- Alw/2009/04

BOB health checkup

PROCEDURES:

M-MODE/2D/DOPPLER/COLOR/CONTRAST B.A.S. M²


MEASUREMENT:			DOPPLER:				
AOD	22	NORMAL (20- 37mm)	MV	0.8	NORMAL (cm/sec.) (0.8- 1.3)	MR	No
LA	24	(19- 40mm)	AV	1.3	(1.2- 1.8)	AR	No
AVO	16	(12- 25mm)	TV	0.6	(0.3- 0.8)	TR	No
RVDd.	11	(03- 09mm)	PV	0.8	(0.7- 1.1)	PR	No
LVDd	47	(37- 56mm)	MITRAL VALVE-				
LVDs	29	(22- 40mm)			AML	Normal	
IVS d	7.8	(06- 12mm)			PML	Normal	
IVS s	11.6						
PWd	3.9	(05- 10mm)	AORTIC VALVE			Normal	
LV FUNCTION			TV & PV are normal.				
M- E- S Separation		<0.9cm					
Minor		24.42%					
LV Ejection Fraction	69%	65 +/- 12%					

LV WALL MOTION: NO RWMA
ALL CARDIAC CHAMBERS ARE NORMAL
ALL VALVES ARE NORMAL
NO CLOT, VEGETATION, PERICARDIAL EFFUSION

FINAL DIAGNOSIS: NORMAL STUDY

Adv: - Follow up/ review at higher center for confirmation

Note:- Please Correlate clinically. Due to technical limitations as well as inaccuracies inherent in the laboratory and statistical analysis of biological process. Diagnostic accuracy of ECHO is up to 95% only.
Report is not valid for medico-legal purpose.


Dr. Mukesh Kumar Gupta
DR. MUKESH GUPTA
Physician & Sonologist
PHYSICIAN
RM 5423/16262



"भ्रूण लिंग परीक्षण की शिकायत
104 टोल फ्री सेवा पर भी की
जा सकती है"

भ्रूण लिंग परीक्षण की शिकायत 104 टोल फ्री सेवा पर भी की जा सकती है।

ID: 985

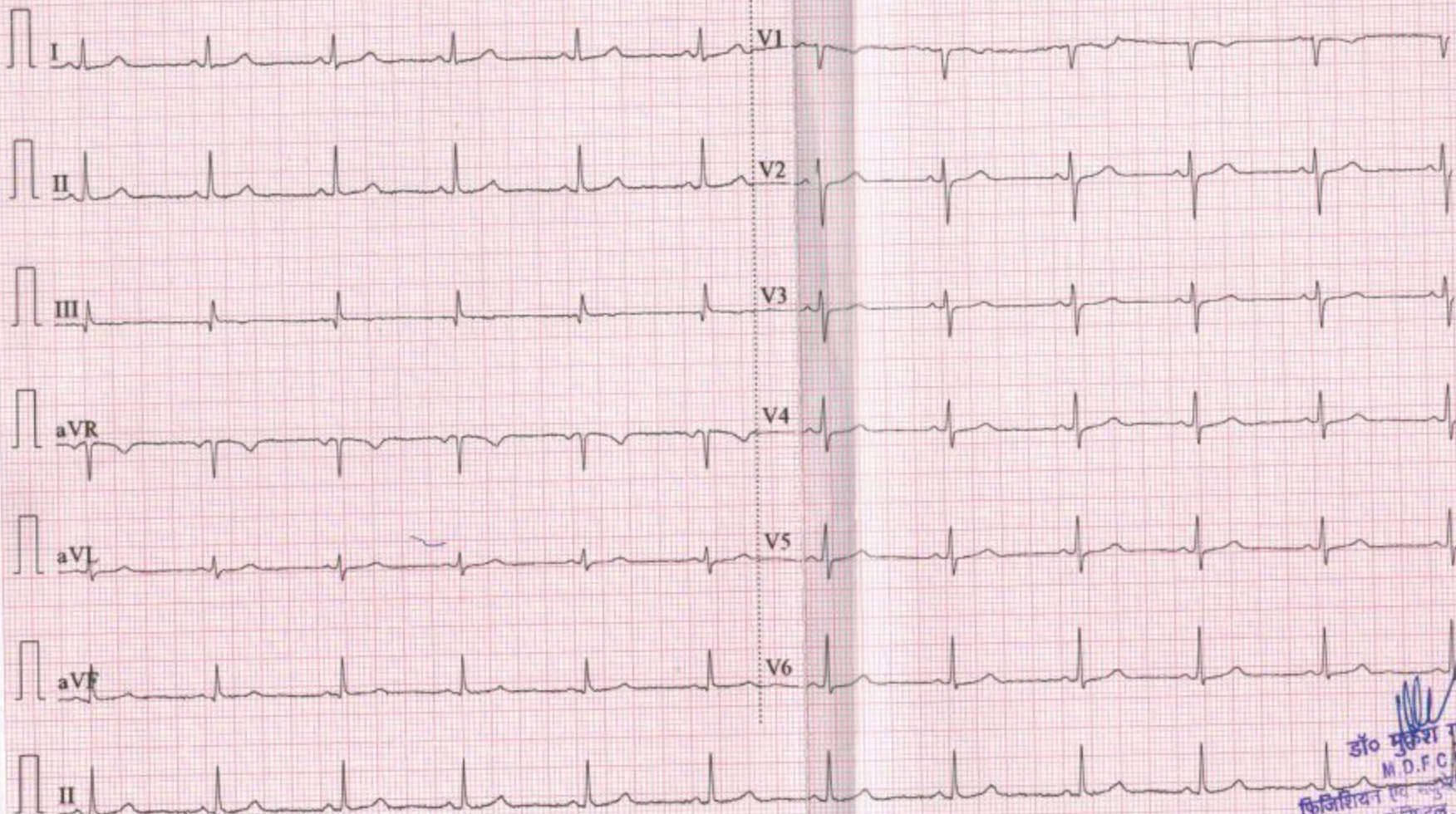
BPL-02 05-10-2023 12:52:24

Female Years
Req. No. :

HR : 68 bpm
P : 86 ms
PR : 114 ms
QRS : 78 ms
QT/QTcBz : 386/411 ms
P/QRST : 29/53/30 ms
RV5/SV1 : 0.597/0.429 mV

Diagnosis Information:
Sinus rhythm
Normal ECG

Report Confirmed by:



डॉ० मुकेश गुप्ता
M.D.F.C.C.S.
कैथिरीयन एवं हृदय रोग विशेषज्ञ
दक्ष हॉस्पिटल, अलवर
रजि० नं०-5423/16262

R

