



Aakriti Labs

3 Mahatma Gandhi Marg, Gandhi Nagar Mod
Tonk Road, Jaipur (Raj.) Ph.: 0141-2710661
www.aakritilabs.com
CIN NO.: U85195RJ2004PTC019563



Name : Mrs. MUNESHEE KUMARI
Age/Gender: 34 Y/Female
Patient ID : 012203270027
BarcodeNo : 10041453
Referred By : Self

Registration No: 27646
Registered : 27/Mar/2022 09:26AM
Analysed : 28/Mar/2022 01:23PM
Reported : 28/Mar/2022 01:23PM
Panel : Medi Wheel (ArcoFemi
Healthcare Ltd)

DIGITAL X-RAY CHEST PA VIEW


Soft tissue shadow and bony cages are normal.
Trachea is central.
Bilateral lung field and both CP angle are clear.
Domes of diaphragm are normally placed.
Transverse diameter of heart appears with normal limits.

IMPRESSION:- NO OBVIOUS ABNORMALITY DETECTED.

*** End Of Report ***

wellness
partner




Dr. Neera Mehta
M.B.B.S., D.M.R.D.
RMCNO.005807/14853



Aakriti Labs

3 Mahatma Gandhi Marg, Gandhi Nagar Mod
Tonk Road, Jaipur (Raj.) Ph.: 0141-2710661
www.aakritilabs.com
CIN NO.: U85195RJ2004PTC019563

PATIENT NAME: MRS MUNESHEE KUMARI	AGE & SEX: 34 Y/Female
REF. BY : MEDI WHEEL	DATE: 27.03.2022

USG: WHOLE ABDOMEN (Female)

- LIVER** : Is normal in size, shape and echogenecity.
The IHBR and hepatic radicals are not dilated.
No evidence of focal echopoor/echorich lesion seen.
Portal vein diameter and Common bile duct normal in size
- GALL** : Is normal in size, shape and echotexture. Walls are smooth and
BLADDER regular with normal thickness. There is no evidence of cholelithiasis.
- PANCREAS**: Is normal in size, shape and echotexture. Pancreatic duct is not dilated.
SPLEEN : Is normal in size, shape and echogenecity. Spleenic hilum is not dilated.
- KIDNEYS** : Right Kidney:- Size: 96x41 mm, Left Kidney:- Size: 88x43 mm.
Bilateral Kidneys are normal in size, shape and echotexture,
corticomedullary differentiation is fair and ratio appears normal.
Pelvi calyceal system is normal. No evidence of hydronephrosis/ nephrolithiasis.
- URINARY** : Bladder walls are smooth, regular and normal thickness.
BLADDER : No evidence of mass or stone in bladder lumen.
- UTERUS** : Uterus is anteverted with normal in size shape & echotexture.
Uterine muscular shadows normal echopattern.
Endometrium is normal and centrally placed with size: 3 mm.
No evidence of mass lesion is seen. Size of uterus: 80x46x32 mm.
- ADNEXA** : Both the ovaries are normal in size shape and echotexture.
No mass lesion/ polycystic ovarian cyst is seen.
- SPECIFIC** : No evidence of retroperitoneal mass or free fluid seen in peritoneal cavity.
: NO evidence of lymphadenopathy or mass lesion in retroperitoneum.
: Visualized bowel loop appear normal. Great vessels appear normal.

IMPRESSION: Ultra Sonography findings are suggestive of: NORMAL STUDY.


DR NEERA MEHTA
MBBS, DMRD
RMCNO.005807/14853



Aakriti Labs

3 Mahatma Gandhi Marg, Gandhi Nagar Mod
Tonk Road, Jaipur (Raj.) Ph.: 0141-2710661
www.aakritilabs.com
CIN NO.: U85195RJ2004PTC019563

Ms. Myneshree Kumari

Mob - 9785444209

Age - 34/F

W 6/9
6/12
P.H 6/6
6/6

Ref - R $0.50 \ 20' \ 6/6$
L $0.75 \ 170' \ 6/6$

Adv

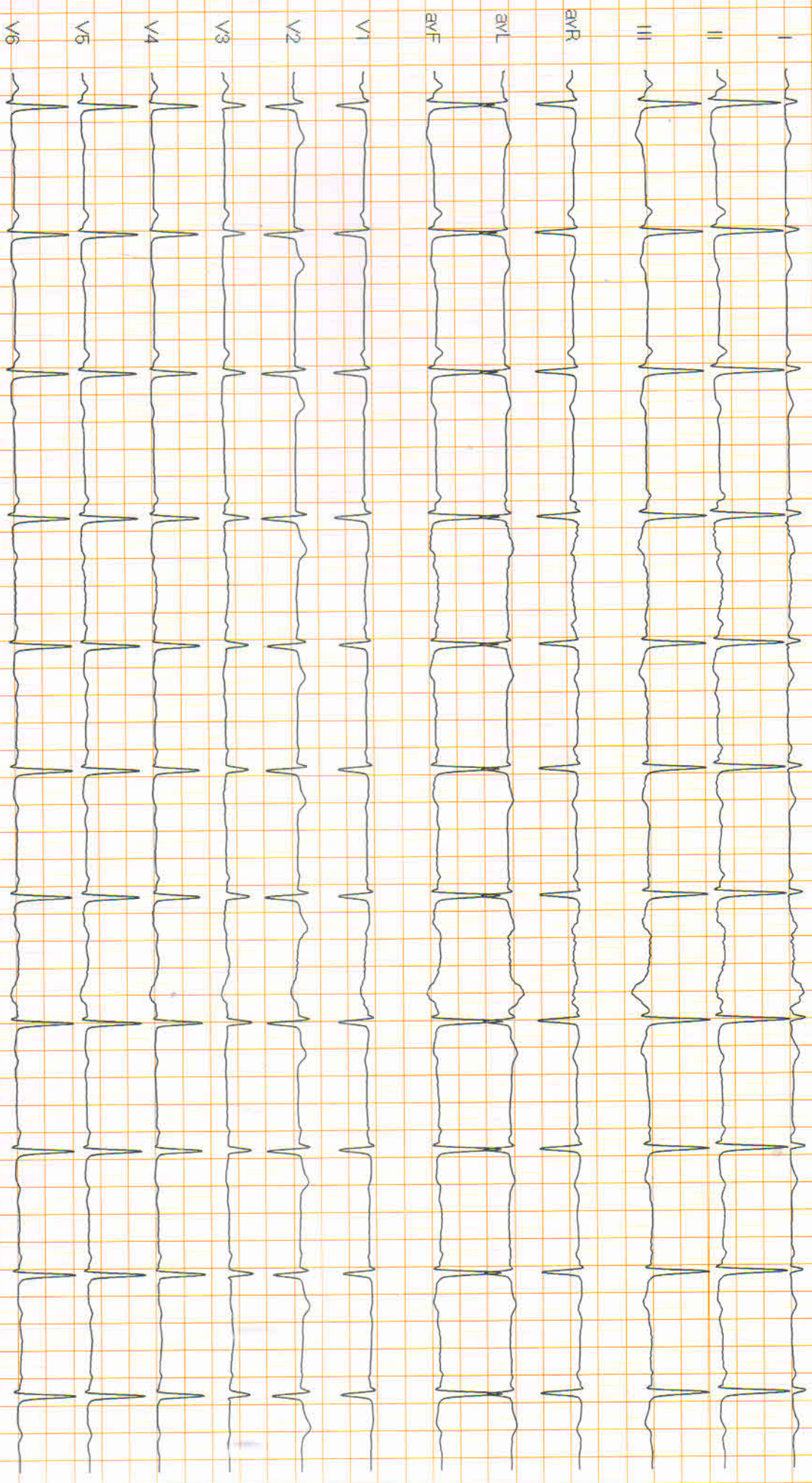

DR. RAKESH SHARMA
M.S.OPTH. B.OPTH
FICLLP

wellness partner



434 / MRS MUNESHI KUMARI / 34 Yrs / F

Date: 27-Mar-2022 11:10:23 AM



Dr. NITIZ GOYAL
 M.B.B.S., M.D.
 RMC - 0233319
 (011) 705259 Gemini A-DX by Allergens

Mrs ST - 1
convert to digital

	Time	Duration	Belt Speed (mph)	Elevation	MEts	Rate	%THR Achieved	BP	RPP	PVG	Comments
Supine	00:03	0:01	01.1	00.0	01.0	70	38%	---/---	000	00	
Standing	00:06	0:01	00.0	00.0	01.0	74	40%	---/---	000	00	
HV	00:17	0:01	00.0	00.0	01.0	114	61%	---/---	000	00	
Warm Up	00:23	0:04	01.7	10.0	01.1	097	52%	---/---	000	00	
ExStart	00:25	0:06	01.7	10.0	01.1	106	57%	---/---	000	00	
BRUCE Stage 1	03:25	3:00	01.7	10.0	04.7	122	66%	120/70	146	00	
BRUCE Stage 2	06:25	3:00	02.5	12.0	07.1	141	76%	120/80	169	00	
PeakEx	07:47	1:22	03.4	14.0	08.5	161	87%	120/80	193	08	
Recovery	08:46	1:00	00.0	00.0	01.2	130	70%	130/80	169	00	
Recovery	09:46	2:00	00.0	00.0	01.0	082	44%	130/80	106	00	
Recovery	10:46	3:00	00.0	00.0	01.0	084	45%	135/80	113	00	
Recovery	11:46	4:00	00.0	00.0	01.0	076	41%	120/80	091	00	
Recovery	11:55	4:08	00.0	00.0	01.0	076	41%	120/80	091	00	

Findings :

Exercise Time : 07:23
 Max HR Attained : 161 bpm 87% of Target 186
 Max BP Attained : (Sys) 135/80
 Max Workload Attained : 8.5
 Test End Reasons : Test Complete, Fatigue, Heart Rate Achieved

Report :

FINAL IMPRESSION - TEST IS NEGATIVE FOR INDUCIBLE ISCHAEMIA

Dr. NITIZ GOYAL

Dr. NITIZ GOYAL

Dr. NITIZ GOYAL
 M.B.B.S., M.D.
 Doctor : BKGN123319