


<b>Name</b> : Mr. Ritesh Thakur  <b>Address</b> : bangalore  <b>Plan</b> : ARCOFEMI MEDIWHEEL MALE AHC CREDIT PAN INDIA OP AGREEMENT	<b>Age:</b> 28 Y  <b>Sex:</b> M	<b>UHID:</b> CINR.0000159422  <small>* CINR . 0 0 0 0 1 5 9 4 2 2 *</small> <b>OP Number:</b> CINROPV211790 <b>Bill No :</b> CINR-OCR-91081 <b>Date</b> : 30.11.2023 10:44
--	---------------------------------------	---

Sno	Service Type/ServiceName	Department
1	ARCOFEMI - MEDIWHEEL - FULL BODY ANNUAL PLUS MALE - TMT - PAN INDIA - FY2324	
<del>1</del>	<del>URINE GLUCOSE(FASTING)</del>	
<del>2</del>	<del>GAMMA GLUTAMYL TRANSFERASE (GGT)</del>	
<del>3</del>	<del>HbA1c, GLYCATED HEMOGLOBIN</del>	
<del>4</del>	<del>LIVER FUNCTION TEST (LFT)</del>	
<del>5</del>	<del>X-RAY CHEST PA</del>	
<del>6</del>	<del>GLUCOSE, FASTING</del>	
<del>7</del>	<del>HEMOGRAM + PERIPHERAL SMEAR</del>	
<del>8</del>	<del>ENT CONSULTATION</del>	
<del>9</del>	<del>CARDIAC STRESS TEST(TMT)</del>	
<del>10</del>	<del>FITNESS BY GENERAL PHYSICIAN</del>	
<del>11</del>	<del>DIET CONSULTATION</del>	
<del>12</del>	<del>COMPLETE URINE EXAMINATION</del>	
<del>13</del>	<del>URINE GLUCOSE(POST PRANDIAL)</del>	
<del>14</del>	<del>PERIPHERAL SMEAR</del>	
<del>15</del>	<del>ECG</del>	
<del>16</del>	<del>BLOOD GROUP ABO AND RH FACTOR</del>	
<del>17</del>	<del>LIPID PROFILE</del>	
<del>18</del>	<del>BODY MASS INDEX (BMI)</del>	
<del>19</del>	<del>OPHTHAL BY GENERAL PHYSICIAN</del>	
<del>20</del>	<del>RENAL PROFILE/RENAL FUNCTION TEST (RFT/KFT)</del>	
<del>21</del>	<del>ULTRASOUND - WHOLE ABDOMEN - 9</del>	
<del>22</del>	<del>THYROID PROFILE (TOTAL T3, TOTAL T4, TSH)</del>	
<del>23</del>	<del>DENTAL CONSULTATION</del> <i>(D)</i>	
<del>24</del>	<del>GLUCOSE, POST PRANDIAL (PP), 2 HOURS (POST MEAL)</del>	

*Ritesh*

Date : 30-11-2023

Department : GENERAL

MR NO : CINR.0000159422

Doctor :

Name : Mr. Ritesh Thakur

Registration No :

Age/ Gender : 28 Y / Male

Qualification :

Consultation Timing: 10:43

Height : 179 cm	Weight : 74.7	BMI : 23.3 kg/m <sup>2</sup>	Waist Circum : 91 cm
Temp : 98.6 F	Pulse : 78 bpm	Resp : 18 bpm	B.P : 118 / 80 mmHg

General Examination / Allergies  
History

Clinical Diagnosis & Management Plan

Follow up date:

Doctor Signature

MR RITESH THAKUR,

Patient ID: 159422

30.11.2023 Male 179 cm 74.7 kg

1:18:50pm 28 yrs Indian

Meds:

Test Reason:

Medical History:

Ref. MD: Ordering MD:

Technician: Test Type:

Comment:

*negative for Induce  
No HR response*

BRUCE: Exercise Time 09:46  
Max HR: 164 bpm 85 % of max predicted 192 bpm HR at rest: 86  
Max BP: 160/90 mmHg Max RPP: 25420 mmHg\*bpm  
Maximum Workload: 12.50 METS  
Max. ST: -1.40 mm, -0.08 mV/s in II: EXERCISE STAGE 4 9:30  
Arrhythmia: A:20

ST/HR index: 0.12  $\mu$ V/bpm

HR reserve used: 73 %

HR recovery: 47 bpm

VE recovery: 0 VE/min

ST/HR hysteresis: 0.016 mV (V2)

QRS duration: BASELINE: 90 ms, PEAK EX: 88 ms, REC: 92 ms

**Reasons for Termination:** Target heart rate achieved

**Summary:**

**Resting ECG:** normal. **Functional Capacity:** normal. **HR Response to Exercise:** appropriate. **BP Response to Exercise:** normal resting BP - appropriate response.

**Chest Pain:** none. **Arrhythmias:** none. **ST Changes:** none. **Overall impression:** Normal stress test.

**Conclusion:** GOOD EFFORT TOLERANCE

NORMAL HR AND BP RESPONSE

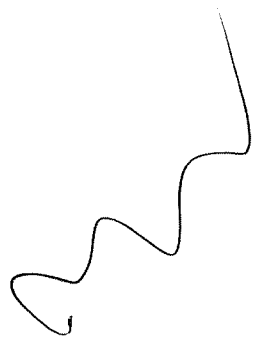
NO ANGINA AND ARRHYTHMIA DURING TEST

STRESS TEST IS NEGATIVE FOR THE EXERCISE INDUCIBLE ISCHEMIA

Room: \_\_\_\_\_

Location: \* 0 \*

Phase Name	Stage Name	Time in Stage	Speed [mph]	Grade [%]	Workload [METS]	HR [bpm]	BP [mmHg]	RPP [mmHg*bp]	VE [l/min]	ST Level II [mm]	Comment
PRE-TEST	SUPINE	00:21	0.00	0.00	1.0	77			0	0.50	
	STANDING	00:06	0.00	0.00	1.0	74			0	0.50	
	HYPERV.	00:05	0.00	0.00	1.0	74			0	0.50	
	WARM-UP	00:41	0.00	0.00	1.0	86			0	0.50	
EXERCISE	STAGE 1	03:00	1.70	10.00	4.6	100			0	0.40	
	STAGE 2	03:00	2.50	12.00	7.0	111	140.87	15540	0	0.25	
	STAGE 3	03:00	3.40	14.00	10.1	151	155.90	23405	0	-0.70	
	STAGE 4	00:46	4.20	16.00	12.5	164		25420	0	-0.10	
RECOVERY		03:00	0.00	0.00	1.0	103	140.82	14420	0	0.10	



MR RITESH THAKUR,

Patient ID: 159422

30.11.2023

1:19:15pm

Male 179 cm

74.7 kg

28 yrs Indian

77 bpm

Exercise Test / 12-Lead Report

PRETEST

SUPINE

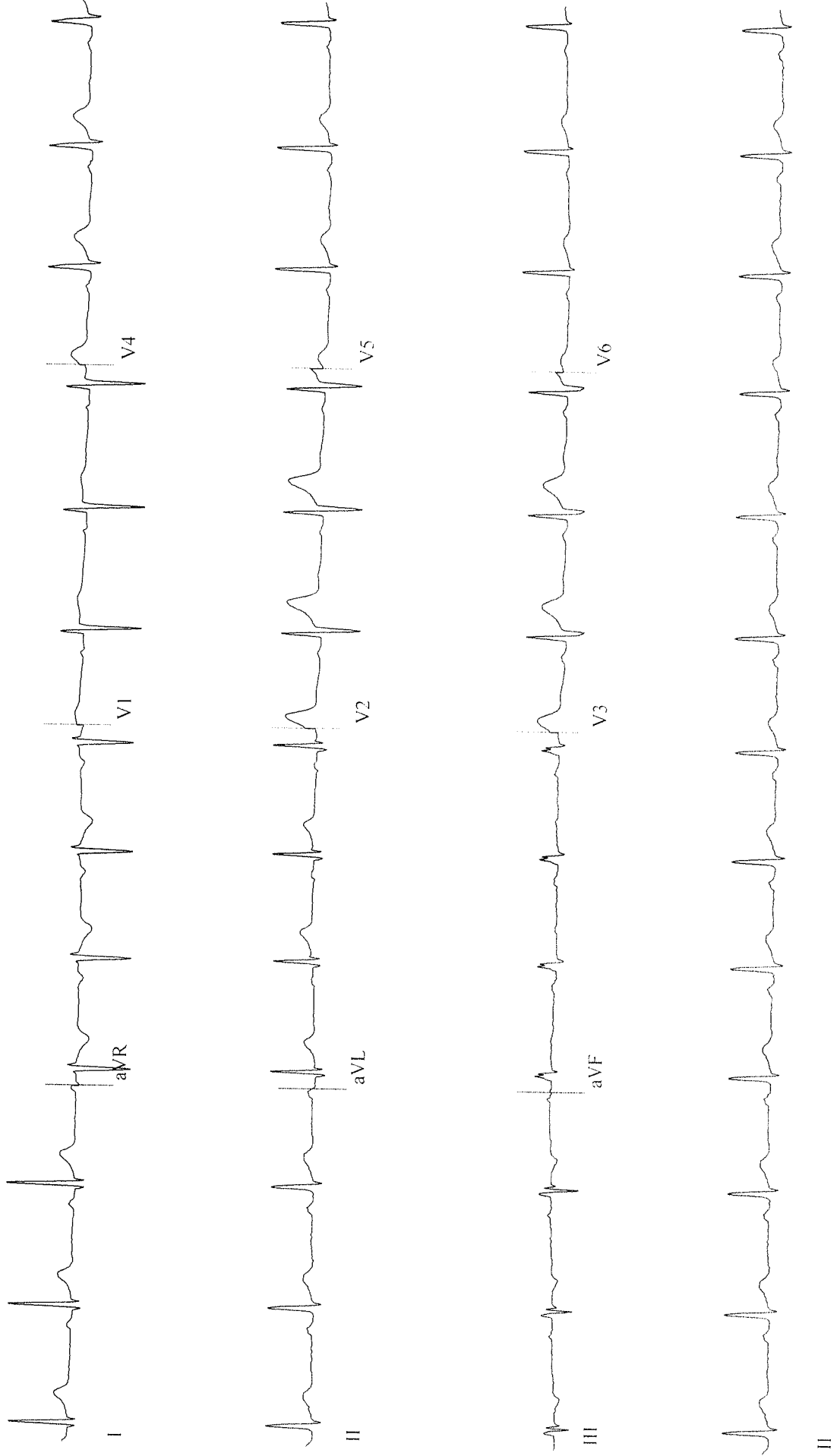
00:19

APOLLO CLINIC

BRUCE

0.0 mph

0.0 %



Exercise Test / 12-Lead Report

MR RITESH THAKUR,

Patient ID: 159422

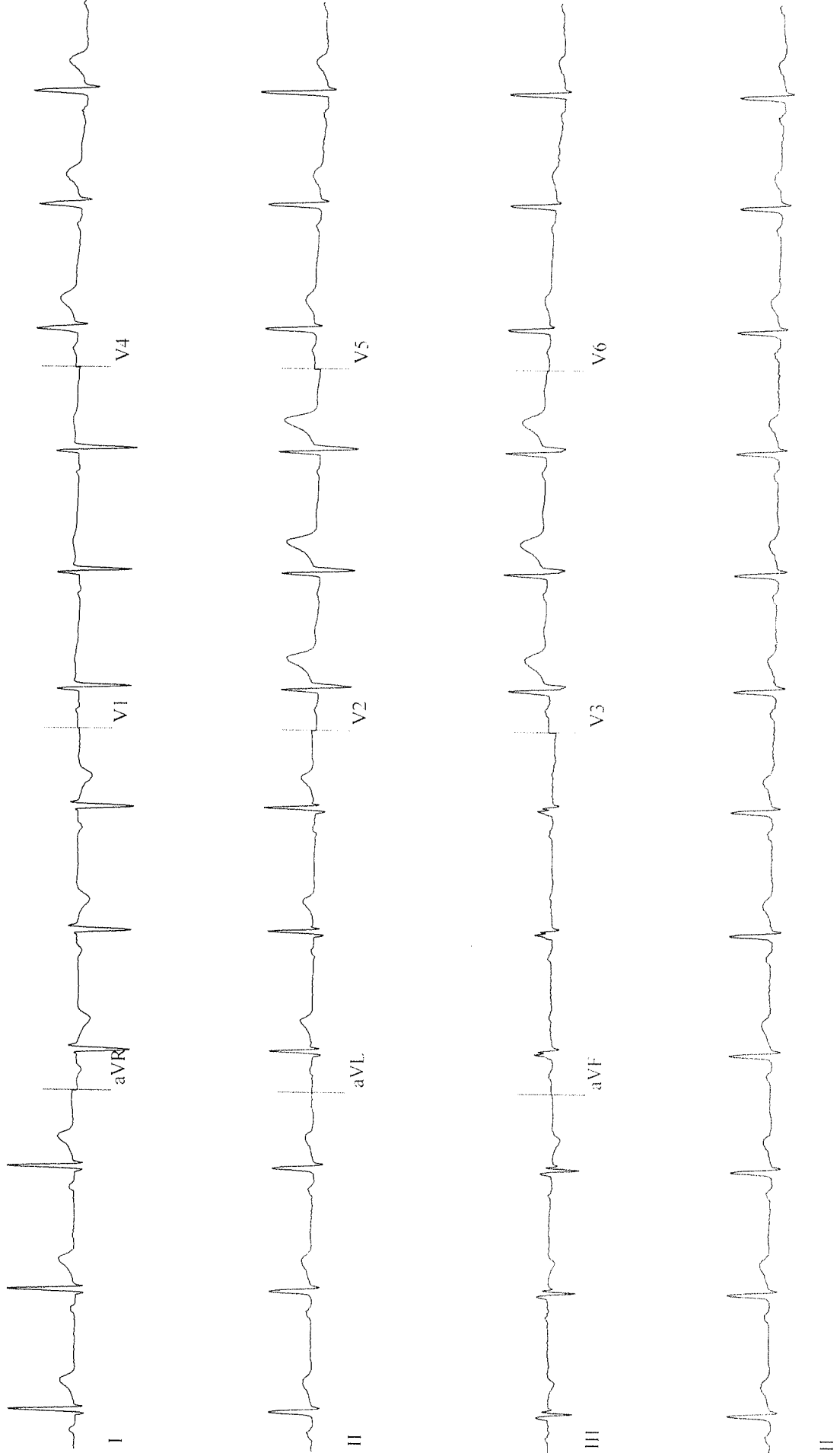
30.11.2023 Male 179 cm 74.7 kg

1:19:21pm 28 yrs Indian

BRUCE  
0.0 mph  
0.0 %

PRETEST  
STANDING  
00:25

75 bpm



Exercise Test / 12-Lead Report

MR RITESH THAKUR,

Patient ID: 159422

30.11.2023

1:19:26pm

Male

179 cm

28 yrs

Indian

74 bpm

PRETEST

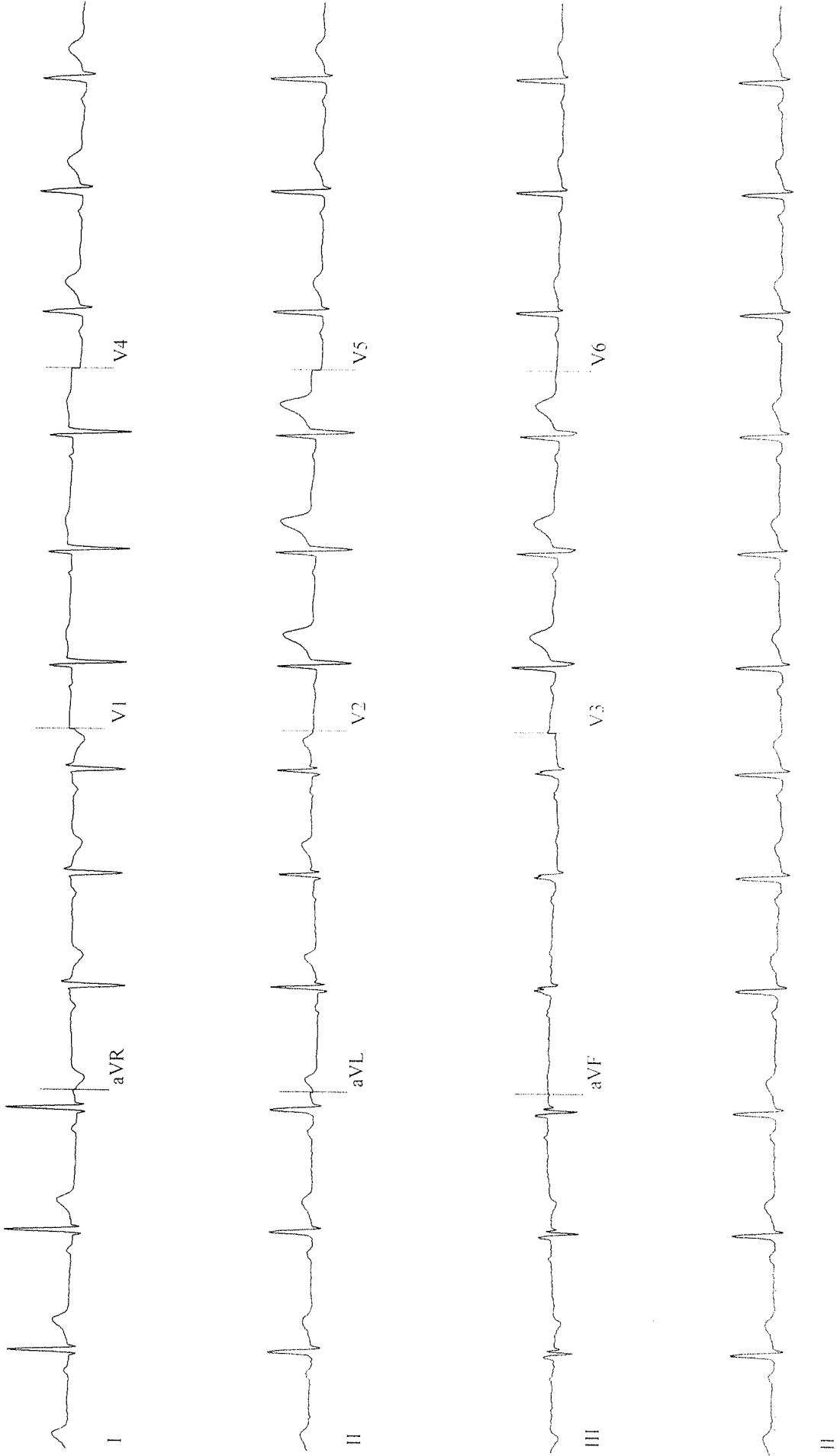
WARM-UP

00:30

BRUCE

0.0 mph

0.0 %



**MR RITESH THAKUR,**

Patient ID: 159422

30.11.2023

1:19:43pm

Male 179 cm 74.7 kg

28 yrs Indian

75 bpm

Exercise Test / 12-Lead Report

PRETEST


~~WARNING~~  
00:47

BRUCE

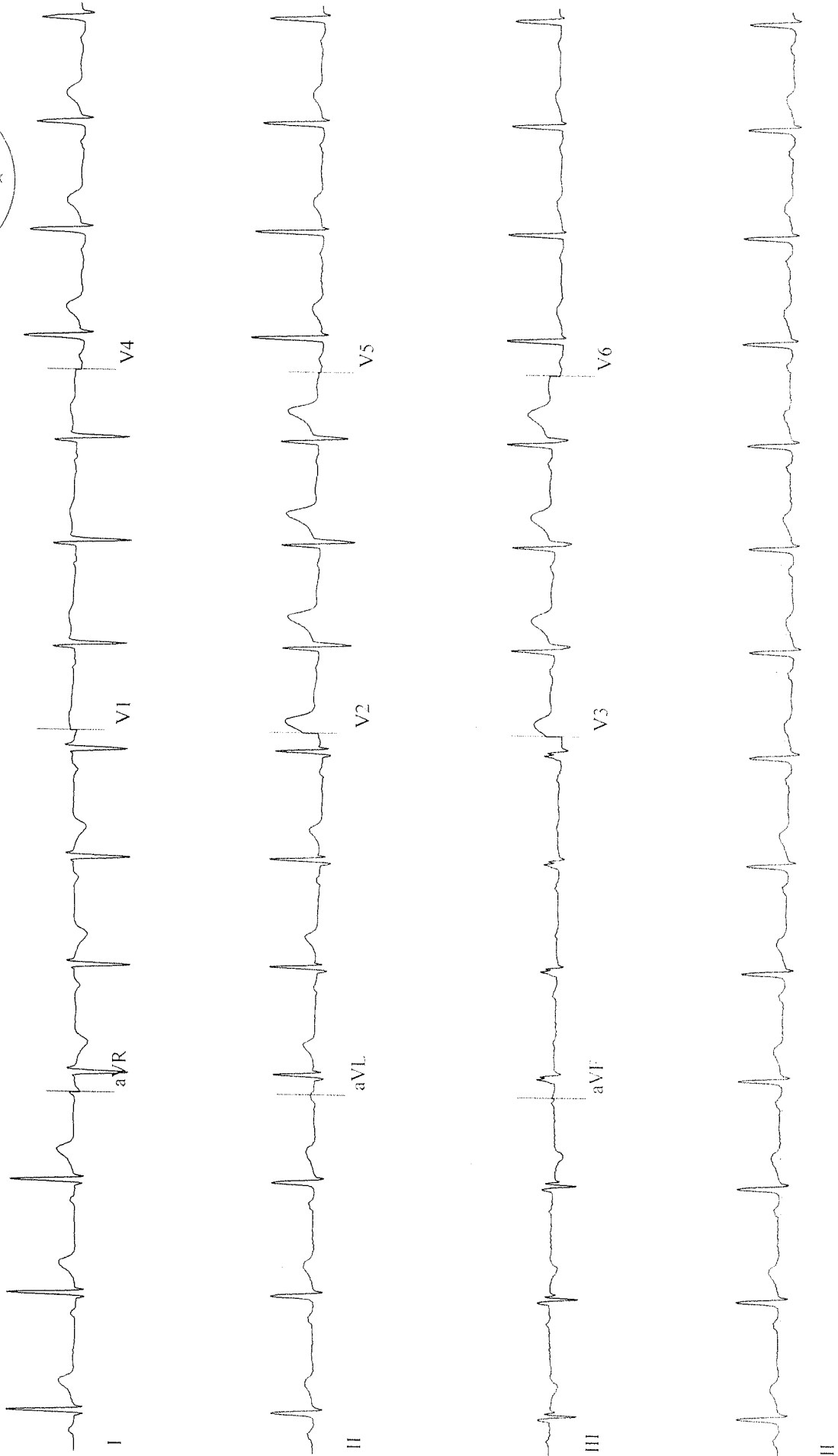
0.0 mph

0.0 %

APOLLO CLINIC



ECG



MR RITESH THAKUR,

Patient ID: 159422

30.11.2023

1:22:49pm

Male 179 cm 74.7 kg

28 yrs Indian

98 bpm

Exercise Test / Linked Medians

EXERCISE

STAGE 1

02:50

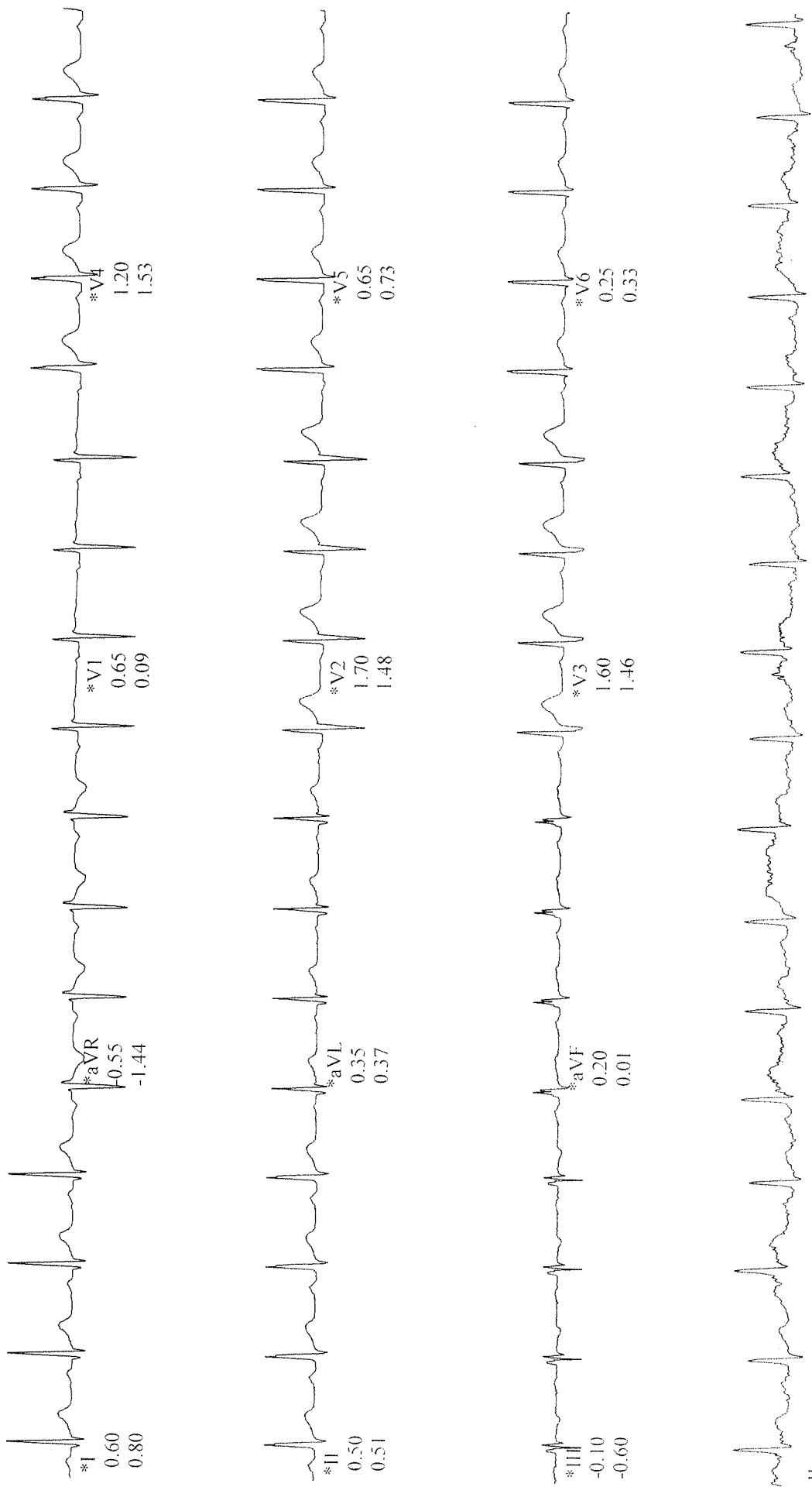
APOLLO CLINIC

BRUCE

1.7 mph

10.0 %

Lead  
ST Level (mm)  
ST Slope (mV/s)



II  
Raw Data

\*Computer Synthesized Rhythms



**MR RITESH THAKUR,**

Patient ID: 159422

30.11.2023

1:25:49pm

Male 179 cm 74.7 kg

28 yrs Indian

Exercise Test / Linked Medians

EXERCISE

STAGE 2

05:50

109 bpm

140/87 mmHg

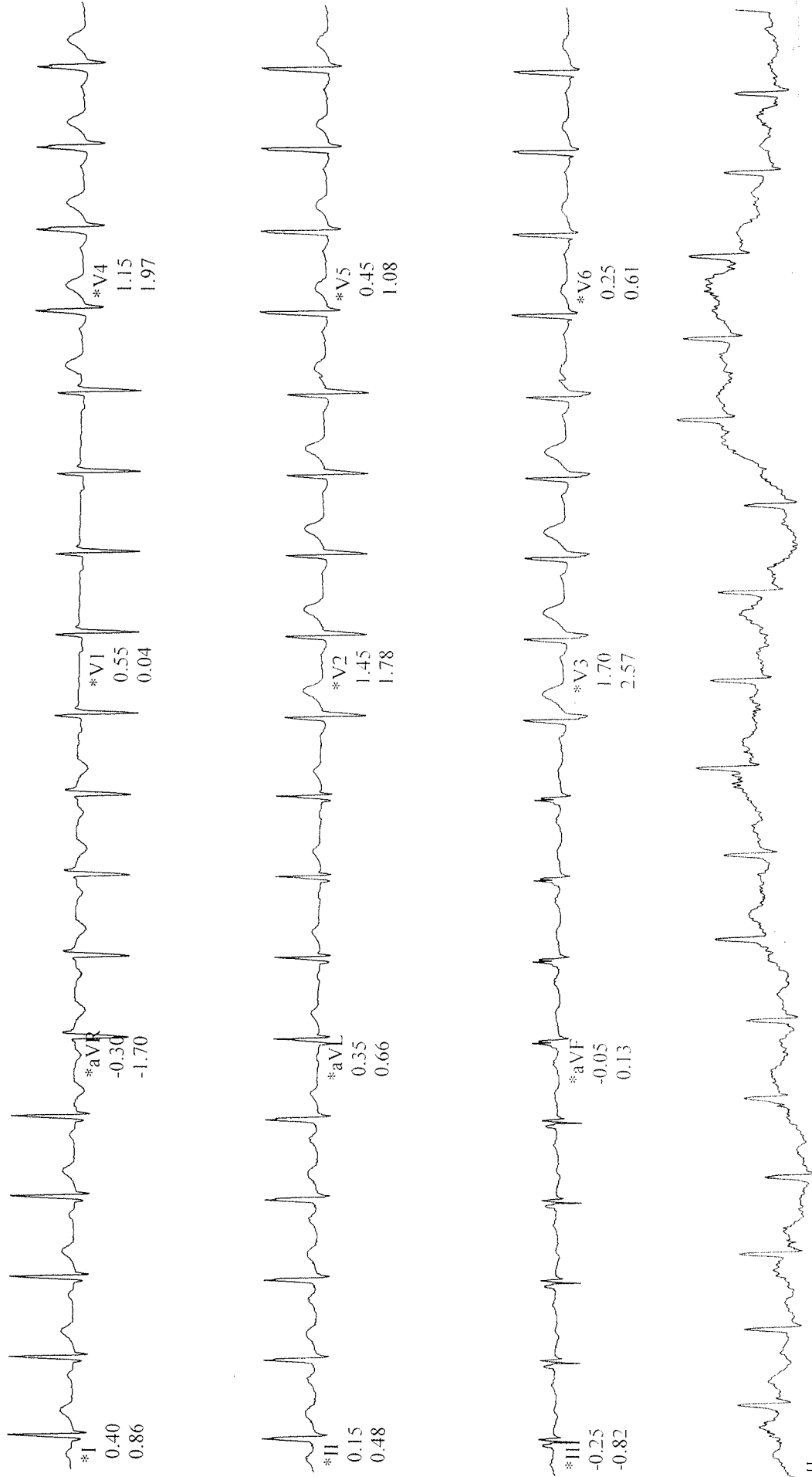
APOLLO CLINIC

BRUCE

2.5 mph

12.0 %

Lead  
ST Level (mm)  
ST Slope (mV/s)



II  
Raw Data

\*Computer Synthesized Rhythms

**MR RITESH THAKUR,**

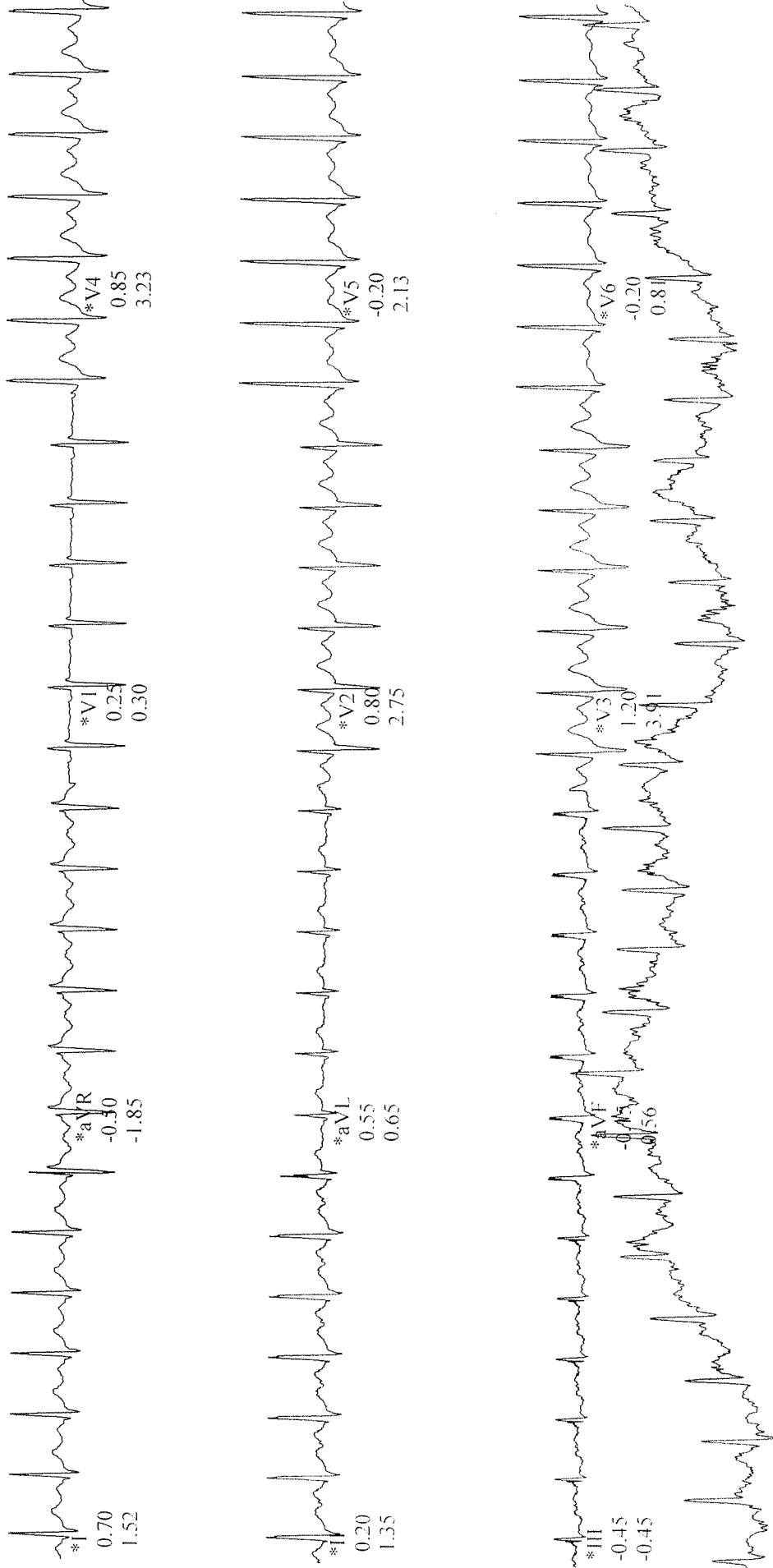
Patient ID: 159422  
30.11.2023 Male 179 cm 74.7 kg  
1:28:49pm 28 yrs Indian

Exercise Test / Linked Medians

EXERCISE STAGE 3  
08:50  
153 bpm  
155/90 mmHg  
BRUCE  
3.4 mph  
14.0 %

APOLLO CLINIC

Lead  
ST Level (mm)  
ST Slope (mV/s)



II  
Raw Data

\*Computer Synthesized Rhythms

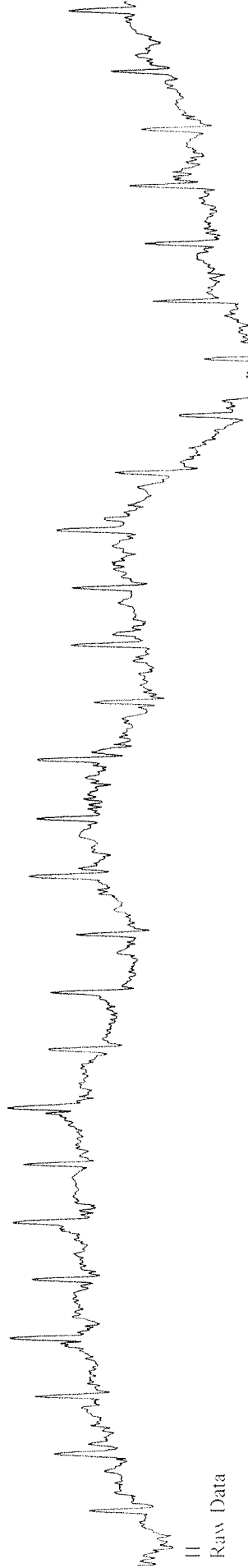

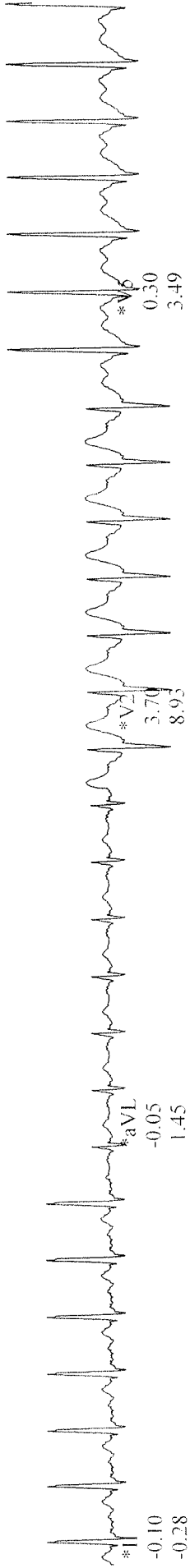
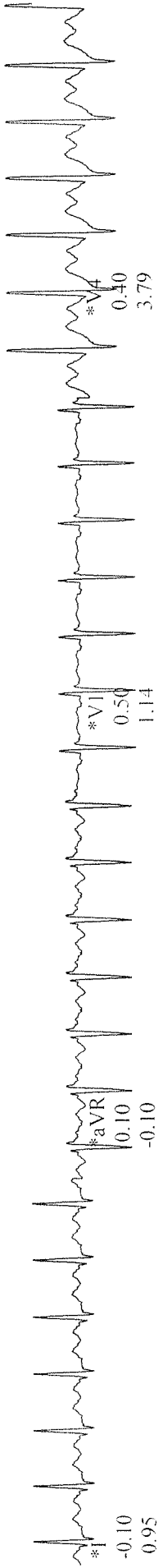
Exercise Test / Linked Medians ( PEAK EXERCISE )

MR RITESH THAKUR,  
Patient ID: 159422  
30.11.2023 Male 179 cm 74.7 kg  
1:29:45pm 28 yrs Indian

EXERCISE STAGE 4  
09:46  
BRUCE  
4.2 mph  
16.0 %

164 bpm

Lead  
ST Level (mm)  
ST Slope (mV/s)



II  
Raw Data

\*Computer Synthesized Rhythms

MR RITESH THAKUR,

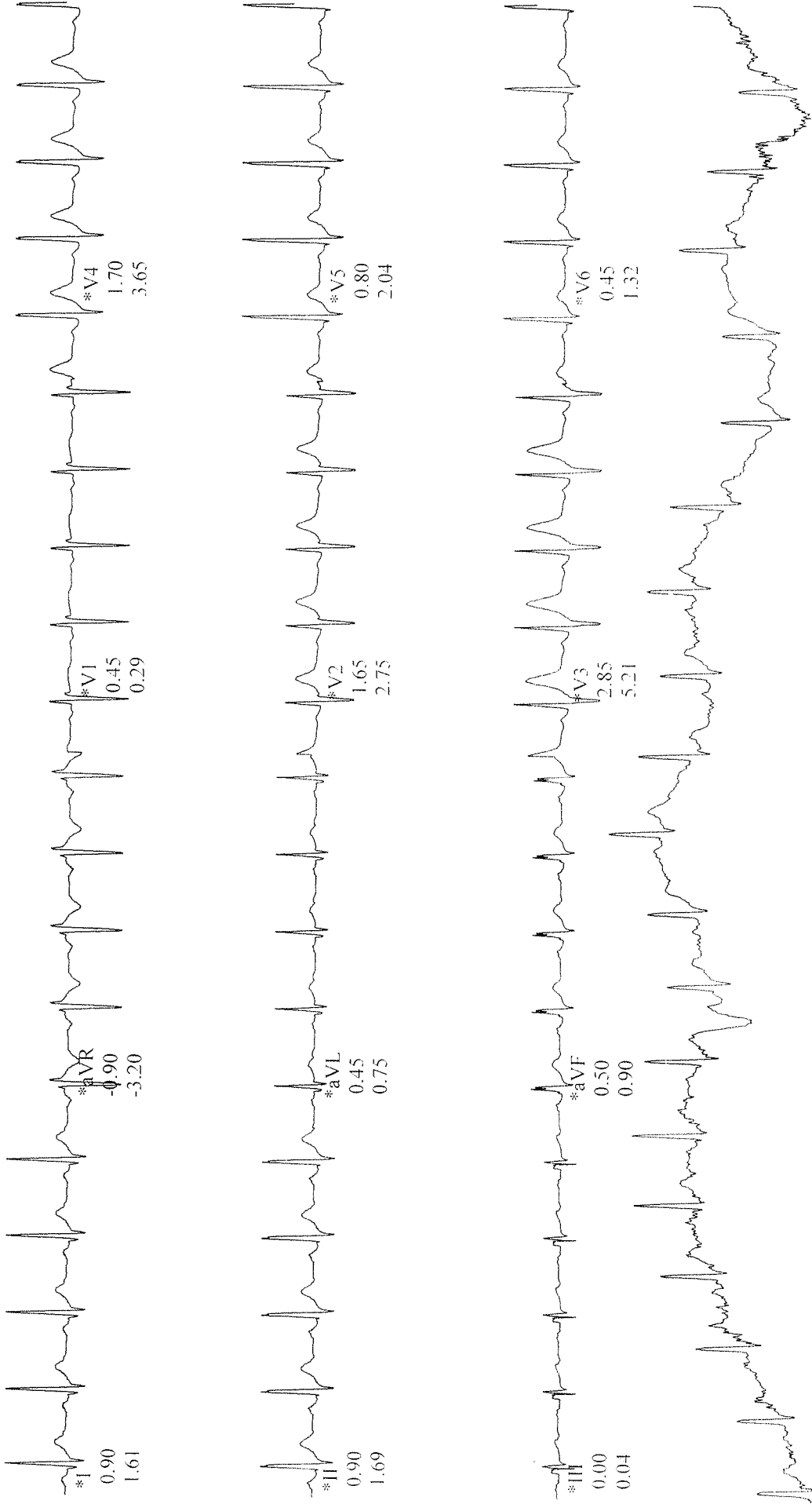
Patient ID: 159422  
30.11.2023 Male 179 cm 74.7 kg  
1:30:45pm 28 yrs Indian

Exercise Test / Linked Medians

RECOVERY #1 01:00  
117 bpm  
160/90 mmHg

APOLLO CLINIC

BRUCE  
0.0 mph  
0.0 %  
Lead  
ST Level (mm)  
ST Slope (mV/s)



Raw Data

\*Computer Synthesized Rhythms

MR RITESH THAKUR,

Patient ID: 159422

30.11.2023

Male 179 cm 74.7 kg

1:32:45pm 28 yrs Indian

Exercise Test / Linked Medians

RECOVERY

#1

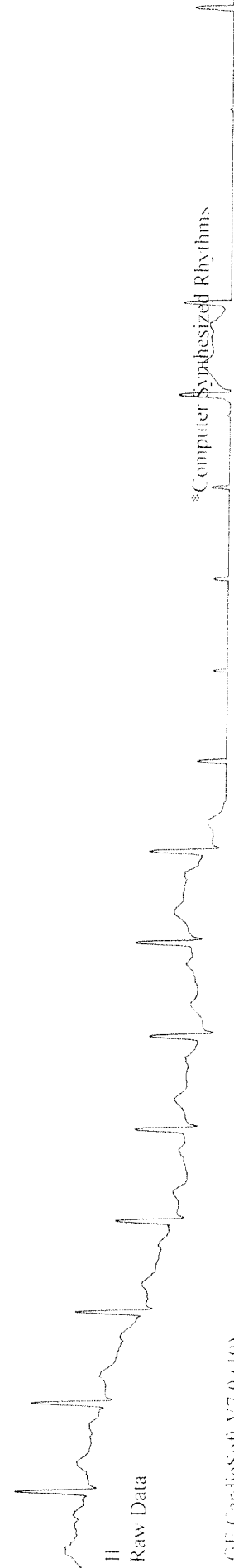
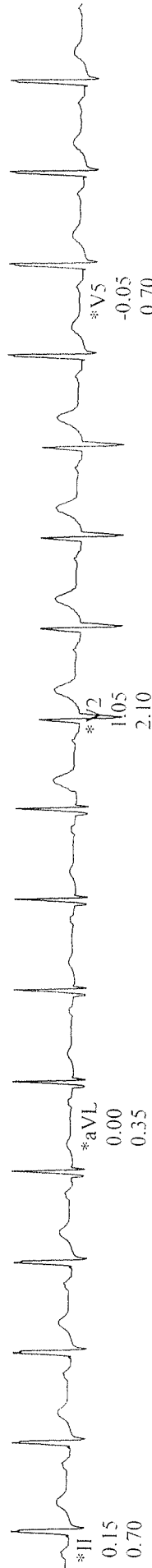
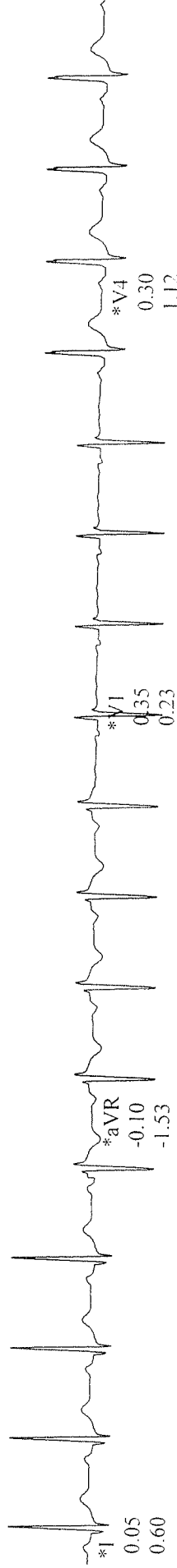
03:00

103 bpm

140/82 mmHg

APOLLO CLINIC

Lead  
ST Level (mm)  
ST Slope (mV/s)



GE CardioSoft V7.0 (10)  
25 mm s 10 mm mV 50 Hz 0.05 - 40 Hz FRF- HR(LV4)

Start of Test: 1:18:50pm

**Dear Ritesh Thakur .,**

Namaste Team,

Greetings from Apollo Clinics,

With regards to the below request the below appointment is scheduled at **INDIRANAGAR** clinic on **2023-11-30** at **08:45-09:00**.

Payment Mode	<b>Credit</b>
Corporate Name	<b>ARCOFEMI HEALTHCARE LIMITED</b>
Agreement Name	<b>ARCOFEMI MEDIWHEEL MALE AHC CREDIT PAN INDIA OP AGREEMENT</b>
Package Name	<b>[ARCOFEMI - MEDIWHEEL - FULL BODY ANNUAL PLUS MALE - 2D ECHO - PAN INDIA - FY2324]</b>

**"As stated in the agreement terms, kindly carry all relevant documents such as HR Authorization Letter, Appointment Confirmation Mail, valid government ID proof, company ID card etc. along with you."**

**Note: Video recording or taking photos inside the clinic premises or during camps is not allowed and would attract legal consequences.**

**Note: Also once appointment is booked, based on availability of doctors at clinics tests will happen, any pending test will happen based on doctor availability and clinics will be updating the same to customers.**

**Instructions to undergo Health Check:**

1. Please ensure you are on complete fasting for 10-To-12-Hours prior to check.
2. During fasting time do not take any kind of medication, alcohol, cigarettes, tobacco or any other liquids (except Water) in the morning.
3. Bring urine sample in a container if possible (containers are available at the Health Check Centre).
4. Please bring all your medical prescriptions and previous health medical records with you.
5. Kindly inform the health check reception in case if you have a history of diabetes and cardiac problems.

<b>Patient Name</b>	: Mr. Ritesh Thakur	<b>Age/Gender</b>	: 28 Y/M
<b>UHID/MR No.</b>	: CINR.0000159422	<b>OP Visit No</b>	: CINROPV211790
<b>Sample Collected on</b>	:	<b>Reported on</b>	: 30-11-2023 14:04
<b>LRN#</b>	: RAD2164493	<b>Specimen</b>	:
<b>Ref Doctor</b>	: SELF		
<b>Emp/Auth/TPA ID</b>	: 9092154550		

## DEPARTMENT OF RADIOLOGY

### ULTRASOUND - WHOLE ABDOMEN

**LIVER:** Appears normal in size, shape and echopattern. No focal parenchymal lesions identified. No evidence of intra/extrahepatic biliary tree dilatation noted. Portal vein appears to be of normal size.

**GALLBLADDER:** Moderately distended. No definite calculi identified. No evidence of abnormal wall thickening noted.

**SPLEEN:** Appears normal in size, shape and echopattern. No focal parenchymal lesions identified.

**PANCREAS:** Obscured by bowel gas. However, the visualized portion appear normal.

**KIDNEYS:** Both kidneys appear normal in size, shape and echopattern. Corticomedullary differentiation appears maintained. No evidence of calculi or hydronephrosis on either side.

**URINARY BLADDER:** Distended and appears normal. No evidence of abnormal wall thickening noted.

**PROSTATE:** Prostate is normal in size and echo-pattern.

No free fluid or lymphadenopathy is seen.

#### IMPRESSION:

**NO SIGNIFICANT SONOGRAPHIC ABNORMALITY DETECTED.**



**Dr. DHANALAKSHMI B**  
MBBS, DMRD  
Radiology

**Patient Name** : Mr. Ritesh Thakur

**Age/Gender** : 28 Y/M

**UHID/MR No.** : CINR.0000159422

**OP Visit No** : CINROPV211790

**Sample Collected on** :

**Reported on** : 30-11-2023 20:12

**LRN#** : RAD2164493

**Specimen** :

**Ref Doctor** : SELF

**Emp/Auth/TPA ID** : 9092154550

---

**DEPARTMENT OF RADIOLOGY**

---

**X-RAY CHEST PA**

Both lung fields and hila are normal .

No obvious active pleuro-parenchymal lesion seen .

Both costophrenic and cardiophrenic angles are clear .

Both diaphragms are normal in position and contour .

Thoracic wall and soft tissues appear normal.

**CONCLUSION :**

No obvious abnormality seen

**Dr. RAMESH G**  
**MBBS DMRD**  
**RADIOLOGY**