



भारतीय विशिष्ट पहचान प्राधिकरण

भारत सरकार
Unique Identification Authority of India
Government of India

नामांकन क्रम / Enrollment No. : 1190/75556/05560

To
हरिश कुमार घुलियानी
Harish Kumar Ghullani
BAHYOG APPARAJUNT ROAD NUMBER 6
NEAR SANT NAGAR RAJIV GANDE VIHAR
Saraswati Vihar
Saraswati Vihar
Saraswati Vihar North West Delhi
Delhi 110034
9811164662

15/07/2013
59910443



MN599104435FT



Handwritten signature

आपका आधार क्रमांक / Your Aadhaar No.

3017 2542 1953

आधार - आम आदमी का अधिकार

Handwritten signature

Dr. NITIN AGARWAL
MBBS, MD
Regn. No. DMC-R-1436
ONEPLUS ULTRASOUND LAB
47, Harsh Vihar, Pitam Pura,
Delhi-110034
2480101, 9599913051
E-mail: oneplusul@gmail.com



भारत सरकार
Government of India




हरिश कुमार घुलियानी
Harish Kumar Ghullani
पिता : जगदीश लाल घुलियानी
Father : Jagdish Lal Ghullani
जन्म तिथि / DOB : 11/12/1968
पुरुष / Male



3017 2542 1953

आधार - आम आदमी का अधिकार



Dr. NITIN AGARWAL
MBBS, MD
Regn. No. DMC-R-1436

ONEPLUS ULTRASOUND LAB
47, Harshil Nagar, Pitam Pura,
Delhi-110034
Ph. 011-42480101, 9599913051
E-mail: oneplusul@gmail.com

ONEPLUS ULTRASOUND LAB

47, HARSH VIHAR, PITAMPURA, DELHI- 110034

MR. HARISH KUMAR GULYANI

Age : 55/M

Ref. by : MEDIWHEEL

Indication1 :

Indication2 :

Indication3 :

COMMENTS :

ID : 1869

HtWt : 177/117

Recorded : 12-2-2022 9:57

Medication1 :

Medication2 :

Medication3 :

BPM : 80

P Axis : 114/74

QRS Axis : 19 deg

T Axis : 27 deg

deg

P duration : 80 msec

PR duration : 140 msec

QRS duration : 113 msec

QT interval : 323 msec

QTc interval : 358 msec

Raw E.C.G.(Seq)

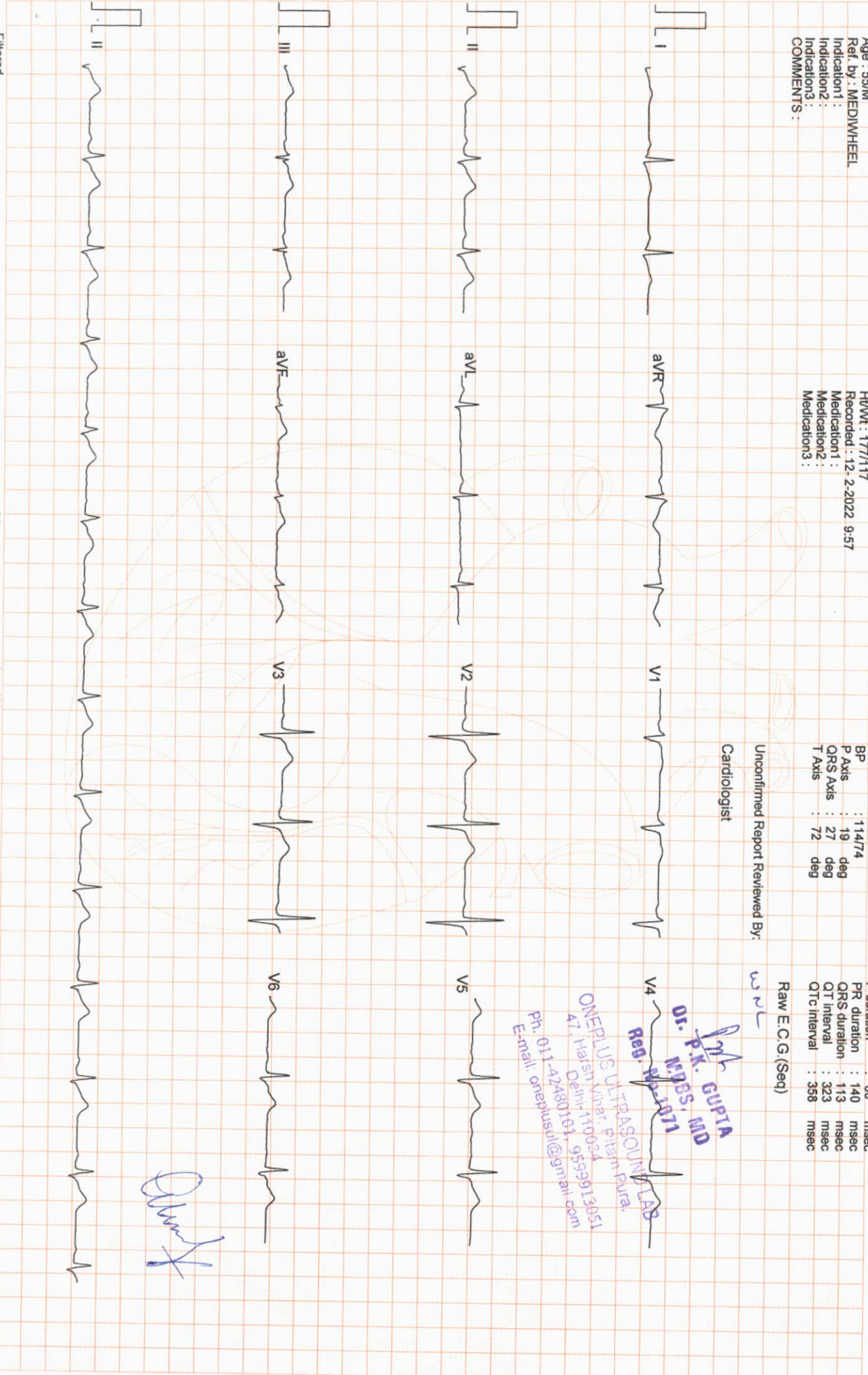
WNL

Unconfirmed Report Reviewed By:
Cardiologist

Dr. P.K. GUPTA
MBBS, MD
Reg. No. 1071

ONEPLUS ULTRASOUND LAB
47, Harsh Vihar, Pitampura,
Delhi-110034
Ph. 011-42480101, 9599913951
E-mail: oneplusul@gmail.com

Dr. P.K. Gupta



Filtered

25mm/sec 10mm/mV

ASCO

CardCom, INDIA

ONEPLUS ULTRASOUND LAB

47, HARSH VIHAR PITAMPURA DELHI 110034

Mr. HARISH KUMAR GULYANI

Age/Sex : 56/M

Ref. by : MEDIWHEEL

Indication1 :

Indication2 :

Indication3 :

ID : 988
HWM : 177/117

Recorded : 12-2-2022 9:59

TREADMILL TEST SUMMARY REPORT

Protocol: BRUCE

History:

Medication1 :

Medication2 :

Medication3 :

PHASE	PHASE TIME	STAGE TIME	SPEED (Km./Hr.)	GRADE (%)	H.R. (BPM)	B.P. (mmHg)	RPP X100	II	ST LEVEL (mm) V2	V5	METS
STANDING SUPINE					81	114/74	92	0.7	1.0	0.8	
STAGE 1	2:59	2:59	2.70	10.00	108	126/78	136	1.0	1.2	0.8	4.80
STAGE 2	5:59	2:59	4.00	12.00	127	136/80	172	0.5	1.0	0.5	7.10
STAGE 3	7:29	1:29	5.40	14.00	146	150/84	219	1.0	0.8	0.4	8.54
PEAK EXER	7:31	1:31			146	150/84	219	0.8	1.0	0.3	8.57
RECOVERY	2:59	2:59	0.00	0.00	98	118/76	115	0.6	0.4	0.5	

RESULTS

Exercise Duration

Max Heart Rate

Max Blood Pressure

Max Work Load

Reason of Termination

IMPRESSIONS

7:31 Minutes
146 bpm 88 % of target heart rate 165 bpm
150/84 mmHg
8.57 METS
Negative for ischaemic chest

[Signature]

Cardiologist

Dr. P.K. GUPTA
MBBS, MD

Reg. No-1071

[Signature]

ONEPLUS ULTRASOUND LAB
47, Harsh Vihar Pitampura,
Delhi-110034
Ph. 011-42480101, 9539913051
E-mail: oneplusul@gmail.com

ONEPLUS ULTRASOUND LAB

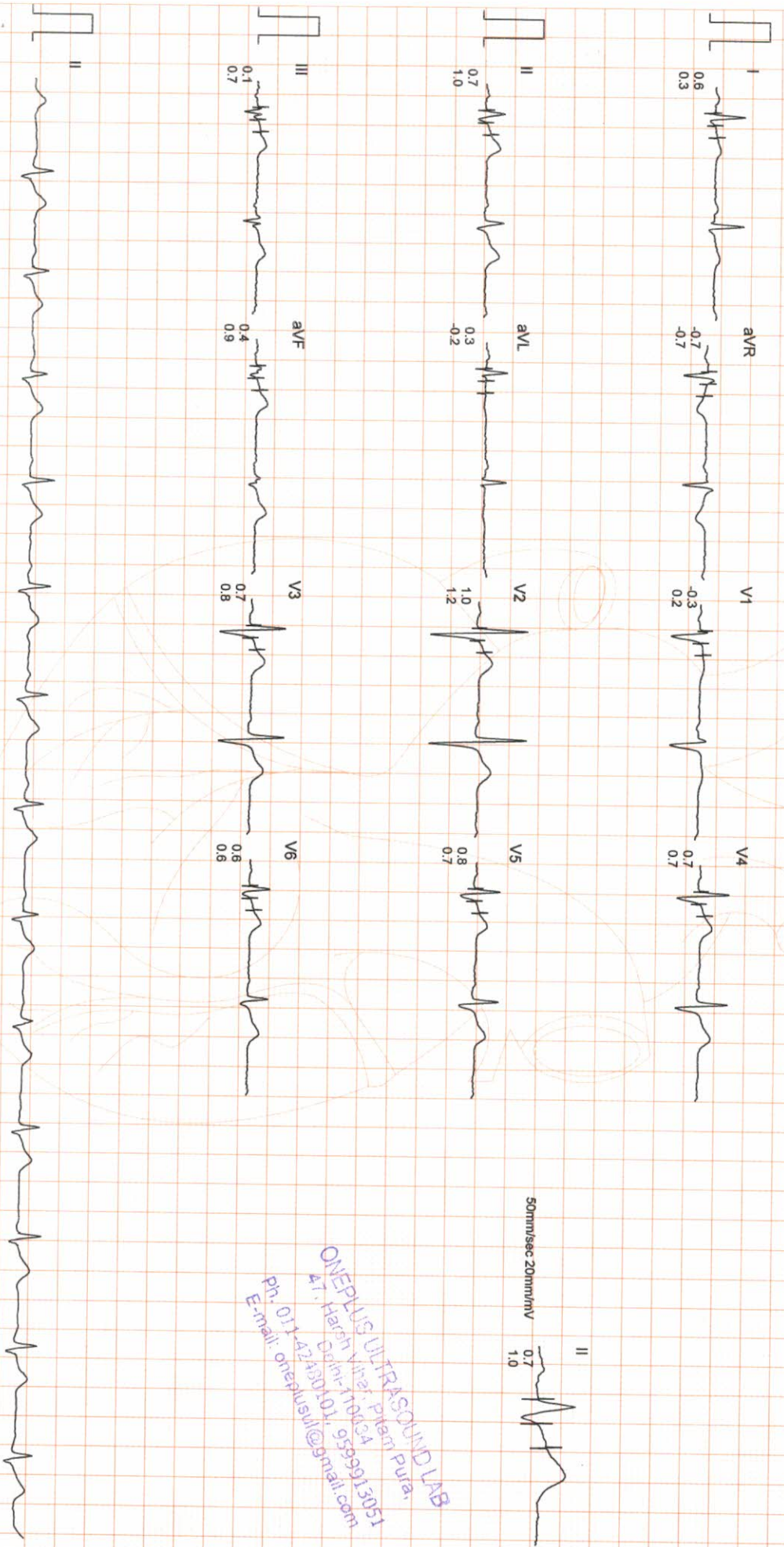
STANDING
PRETEST

ST @ 10mm/mV
80ms PostI

Mr. HARISH KUMAR GULYANI
I.D. : 988
AGE/SEX : 55/M
RECORDED : 12-2-2022 9:59

RATE : 81 BPM
B.P. : 114/74 mmHg

LINKED MEDIAN



ONEPLUS ULTRASOUND LAB
A1, Harsh Vihar, Pitam Pura,
Delhi-110034
Ph: 011-42430101, 9599913051
E-mail: oneplusul@gmail.com

Filtered

Computer Corrected Baseline

25mm/sec 10mm/mV

ART-1V

Cardicom, INDIA Ph.:091-731-2620740, TeleFax:091-731-2431214

ONEPLUS ULTRASOUND LAB

SUPINE
PRETEST

ST @ 10mm/mV
80ms PostJ

Mr. HARISH KUMAR GULYANI

I.D. : 988

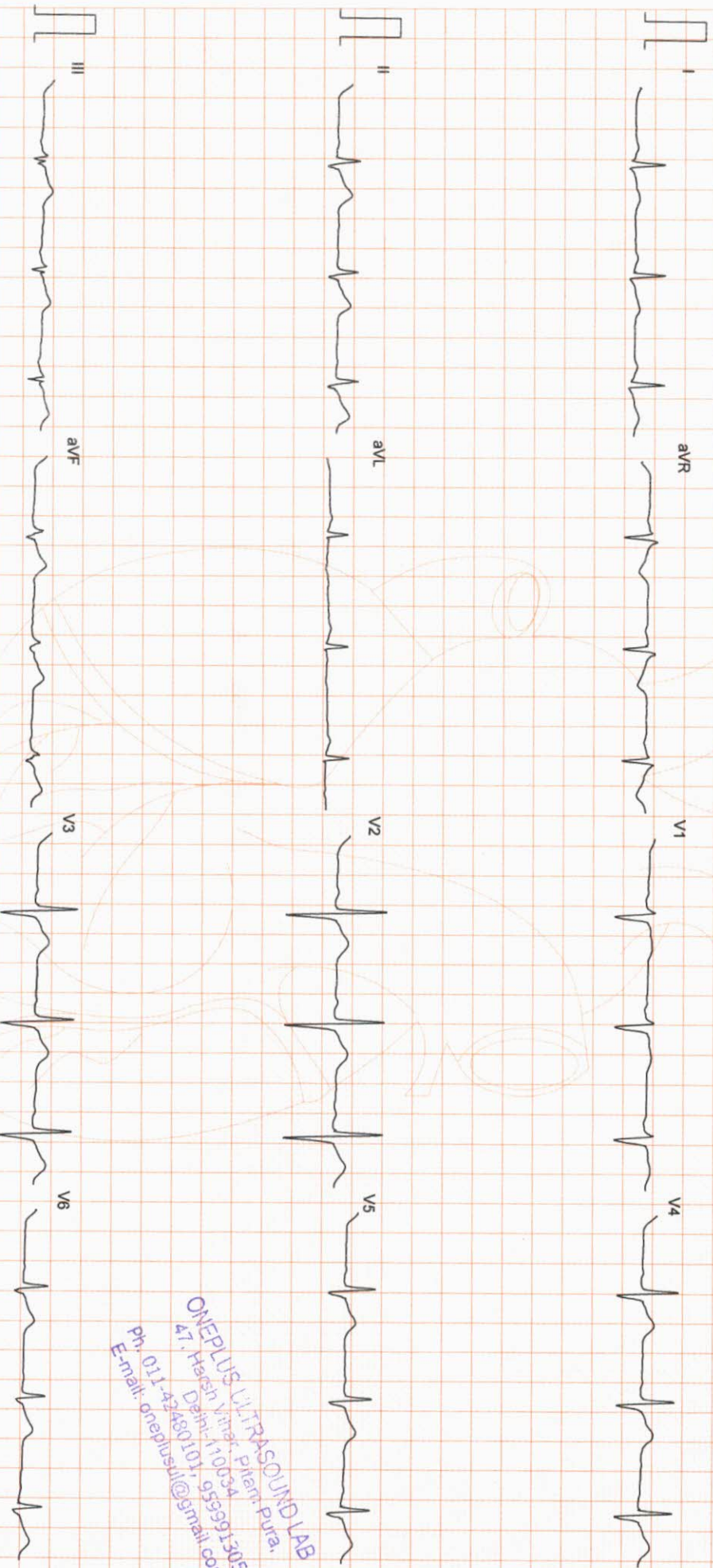
AGE/SEX : 55/M

RECORDED : 12-2-2022 9:59

RATE : 81 BPM

B.P. : 114/74 mmHg

RAW E.C.G.



ONEPLUS ULTRASOUND LAB
47, Harish Vihar, Pitampura,
Delhi-110034
Ph: 011-42460101, 95666913051
E-mail: oneplusul@gmail.com

Filtered

25mm/sec 10mm/mV

ARROW

CardiCom, INDIA Ph.:091-731-2620740, Telefax:091-731-2431214

ONEPLUS ULTRASOUND LAB

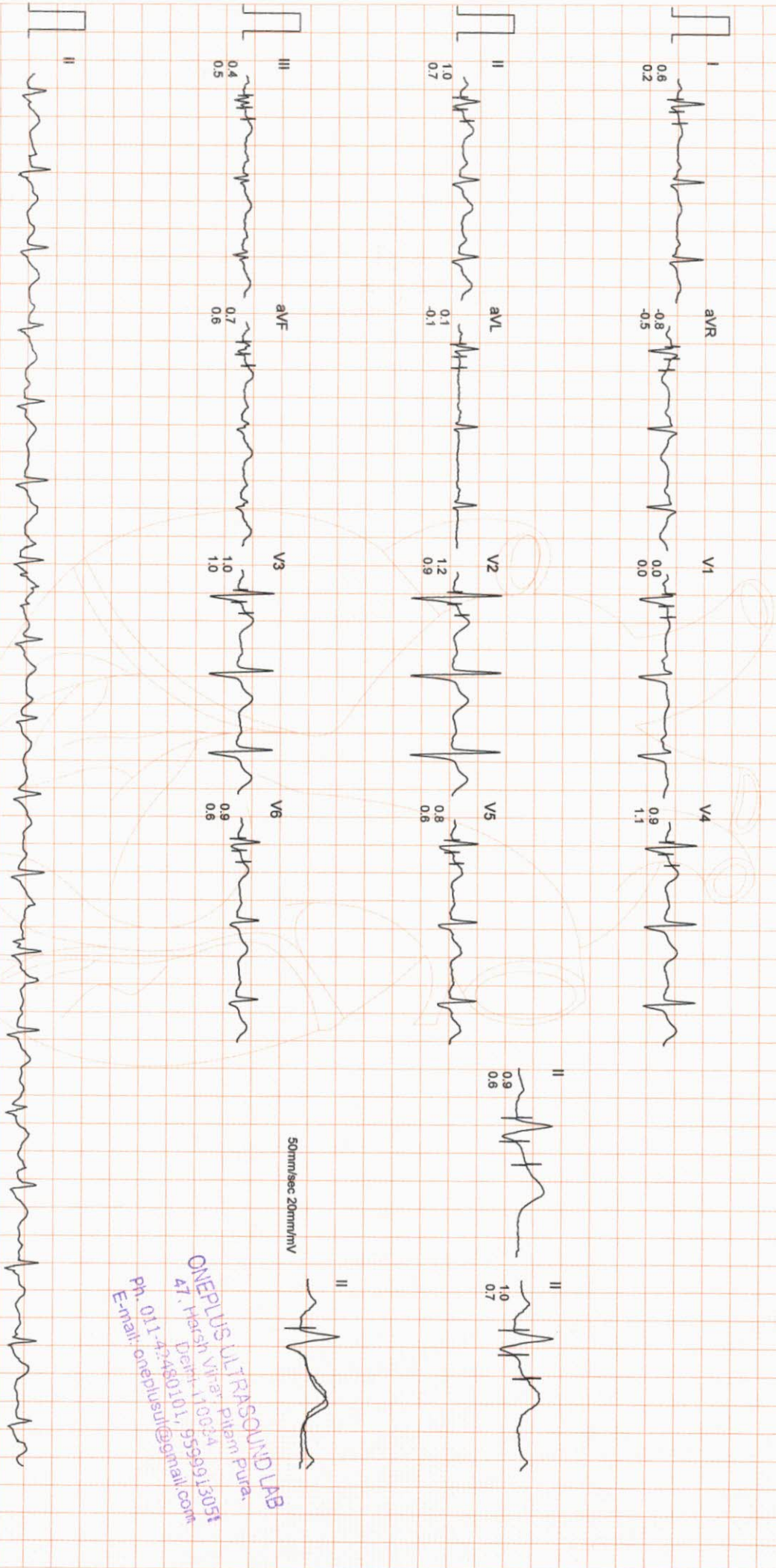
Mr. HARISH KUMAR GULYANI
 I.D. : 988
 AGE/SEX : 55/M
 RECORDED : 12-2-2022 9:59

RATE : 108 BPM
 B.P. : 126/78 mmHg

BRUCE
 EXERCISE 1
 PHASE TIME : 2:59
 STAGE TIME : 2:59

ST @ 10mm/mV
 80ms PostJ
 SPEED : 2.7 Km./Hr.
 GRADE : 10.0 %

LINKED MEDIAN



ONEPLUS ULTRASOUND LAB
 47, 1 Harish Vihar, Pitam Pura,
 Delhi-110034
 9599913051
 E-mail: oneplusul@gnnmail.com
 Ph: 011-434480101



ONEPLUS ULTRASOUND LAB

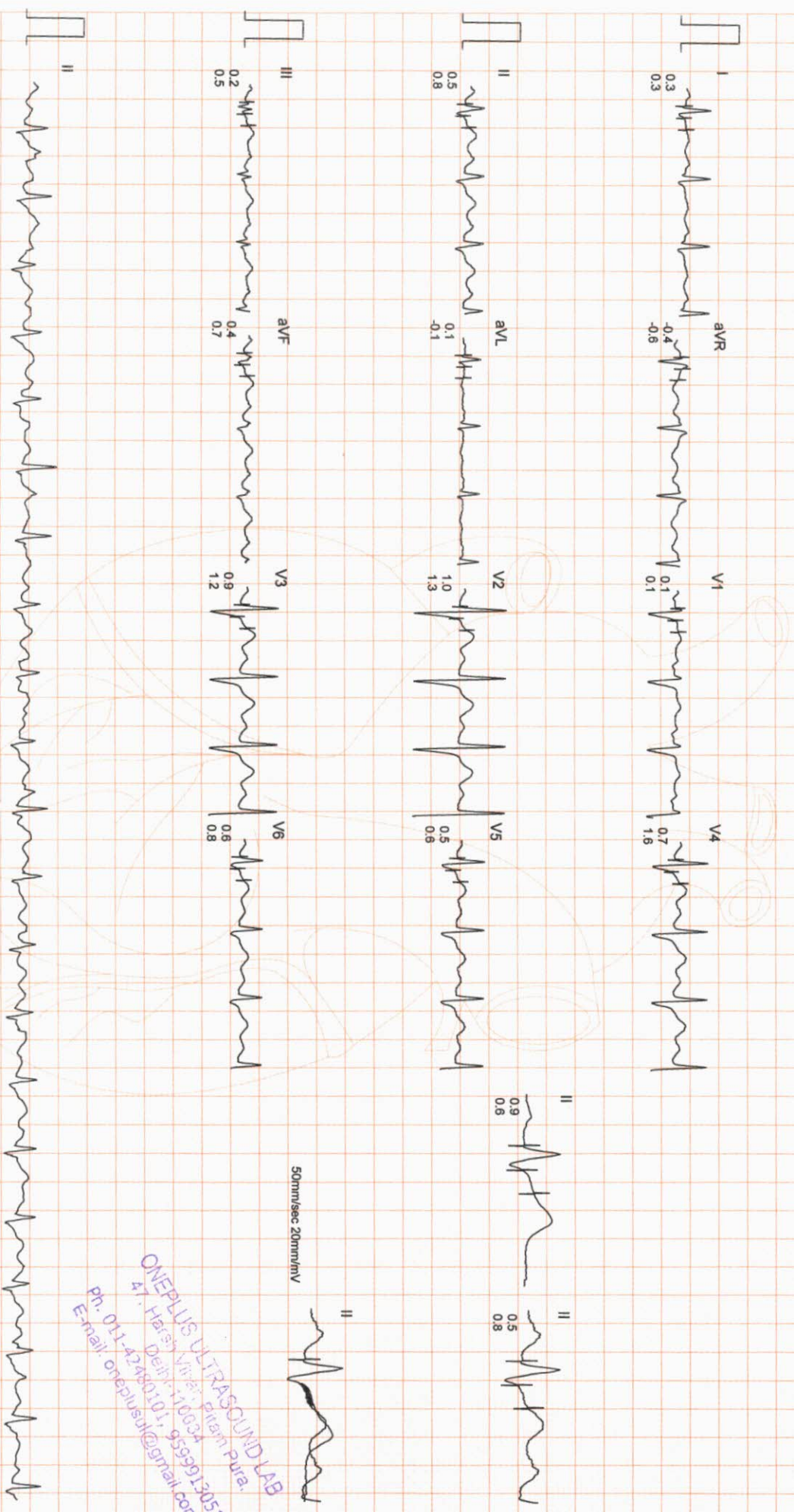
Mr. HARISH KUMAR GULYANI
I.D. : 988
AGE/SEX : 55/M
RECORDED : 12-2-2022 9:59

RATE : 127 BPM
B.P. : 136/80 mmHg

BRUCE
EXERCISE 2
PHASE TIME : 5:59
STAGE TIME : 2:59

ST @ 10mm/mV
80ms PostJ
SPEED : 4.0 Km./Hr.
GRADE : 12.0 %

LINKED MEDIAN



ONEPLUS ULTRASOUND LAB
47, Harsy Nihar, Bitem Pura,
Delhi-110034
Ph. 011-42760101, 9599913051
E-mail: oneplusul@gmail.com

ONEPLUS ULTRASOUND LAB

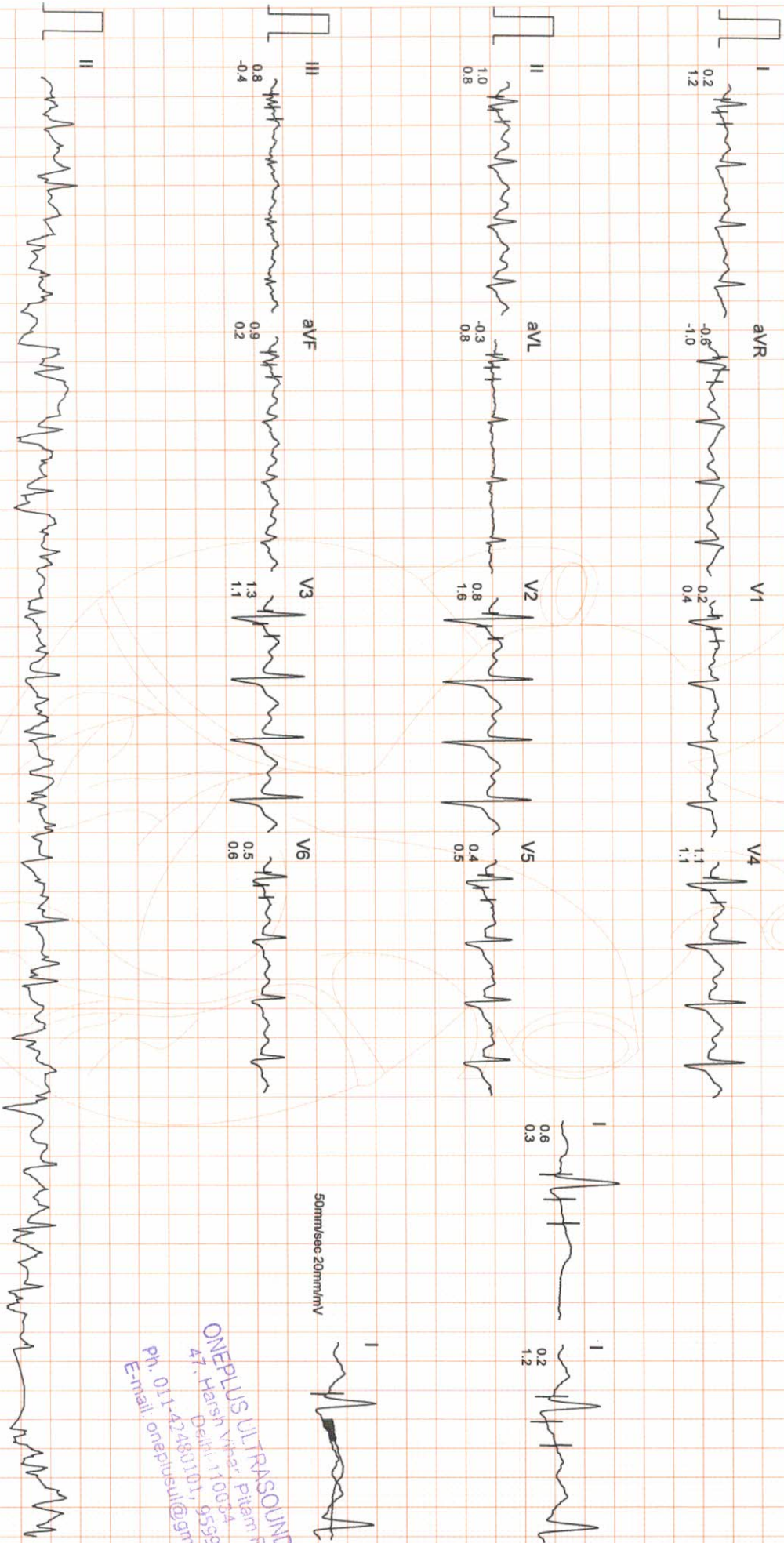
MR. HARISH KUMAR GULYANI
I.D. : 988
AGE/SEX : 55/M
RECORDED : 12-2-2022 9:59

RATE : 146 BPM
B.P. : 150/84 mmHg

BRUCE
EXERCISE 3
PHASE TIME : 7:29
STAGE TIME : 1:29

ST @ 10mm/mV
80ms PostJ
SPEED : 5.4 Km./Hr.
GRADE : 14.0 %

LINKED MEDIAN



50mm/sec 20mm/mV

ONEPLUS ULTRASOUND LAB
47, Harsh Vihar, Pitam-pur,
Delhi, 110034
95599913051
Dellhi, 110034
Email: oneplusul@gnratil.com
Ph. 011-42480101

Filtered

Computer Corrected Baseline

25mm/sec 10mm/mV

ARUN

CardiCom, INDIA Ph.:091-731-2620740, TeleFax:091-731-2431214

ONEPLUS ULTRASOUND LAB

Mr. HARISH KUMAR GULYANI

I.D. : 988

AGE/SEX : 55/M

RECORDED : 12-2-2022 9:59

RATE : 146 BPM

B.P. : 150/84 mmHg

BRUCE

PEAK EXER

PHASE TIME : 7:31

STAGE TIME : 1:31

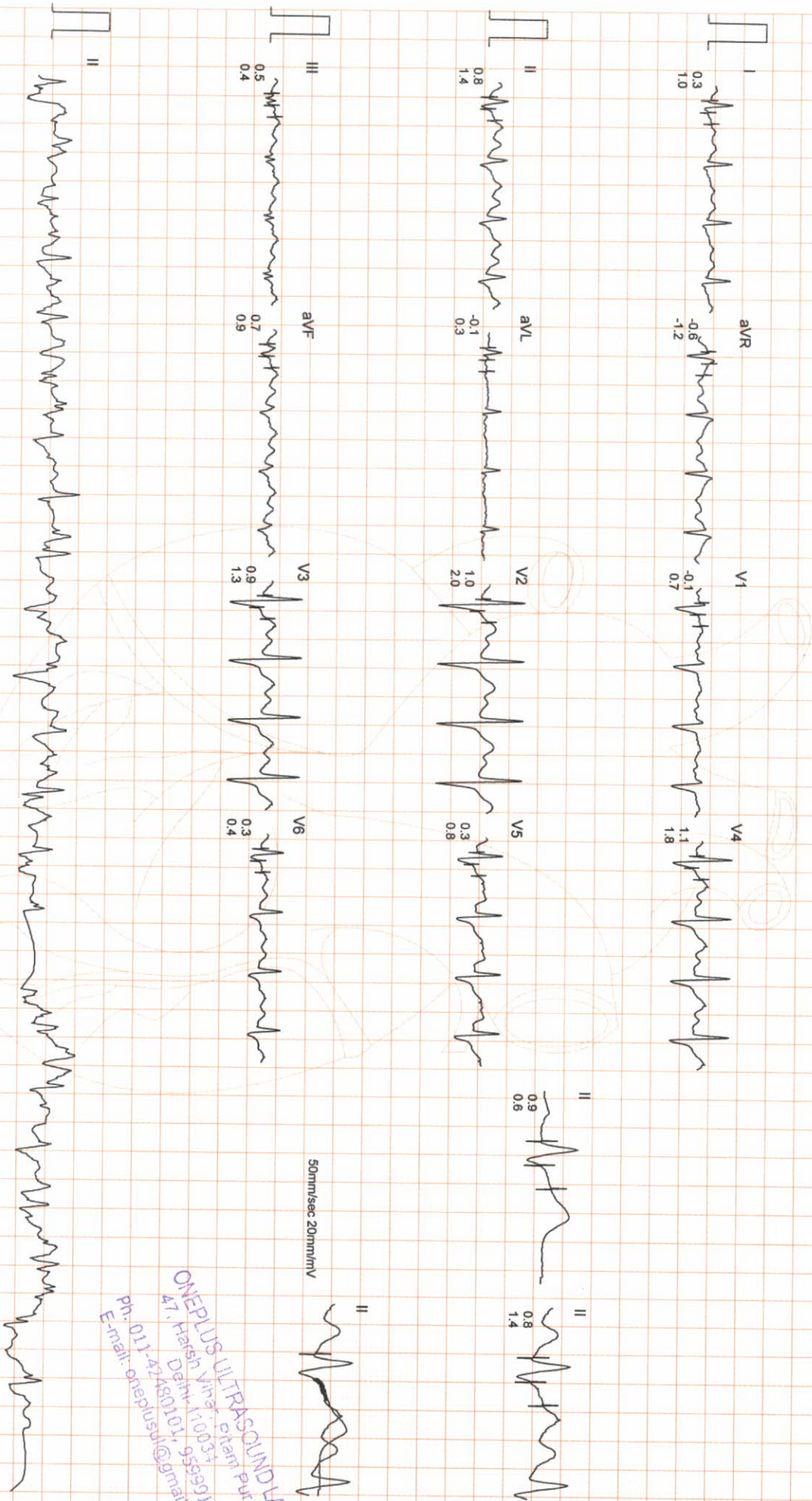
ST @ 10mm/mV

80ms PostJ

SPEED : 5.4 Km./Hr.

GRADE : 14.0 %

LINKED MEDIAN



50mm/sec 20mm/mV

ONEPLUS ULTRASOUND LAB
 417, Harish Vihar, Pitampura,
 Delhi-110034
 Ph: 011-22480101, 95599013051
 E-mail: oneplusul@gmail.com

Filtered

Computer Corrected Baseline

25mm/sec 10mm/mV

ASAP

CardiCom, INDIA Ph.:091-731-2620740, Telefax:091-731-2431214

ONEPLUS ULTRASOUND LAB

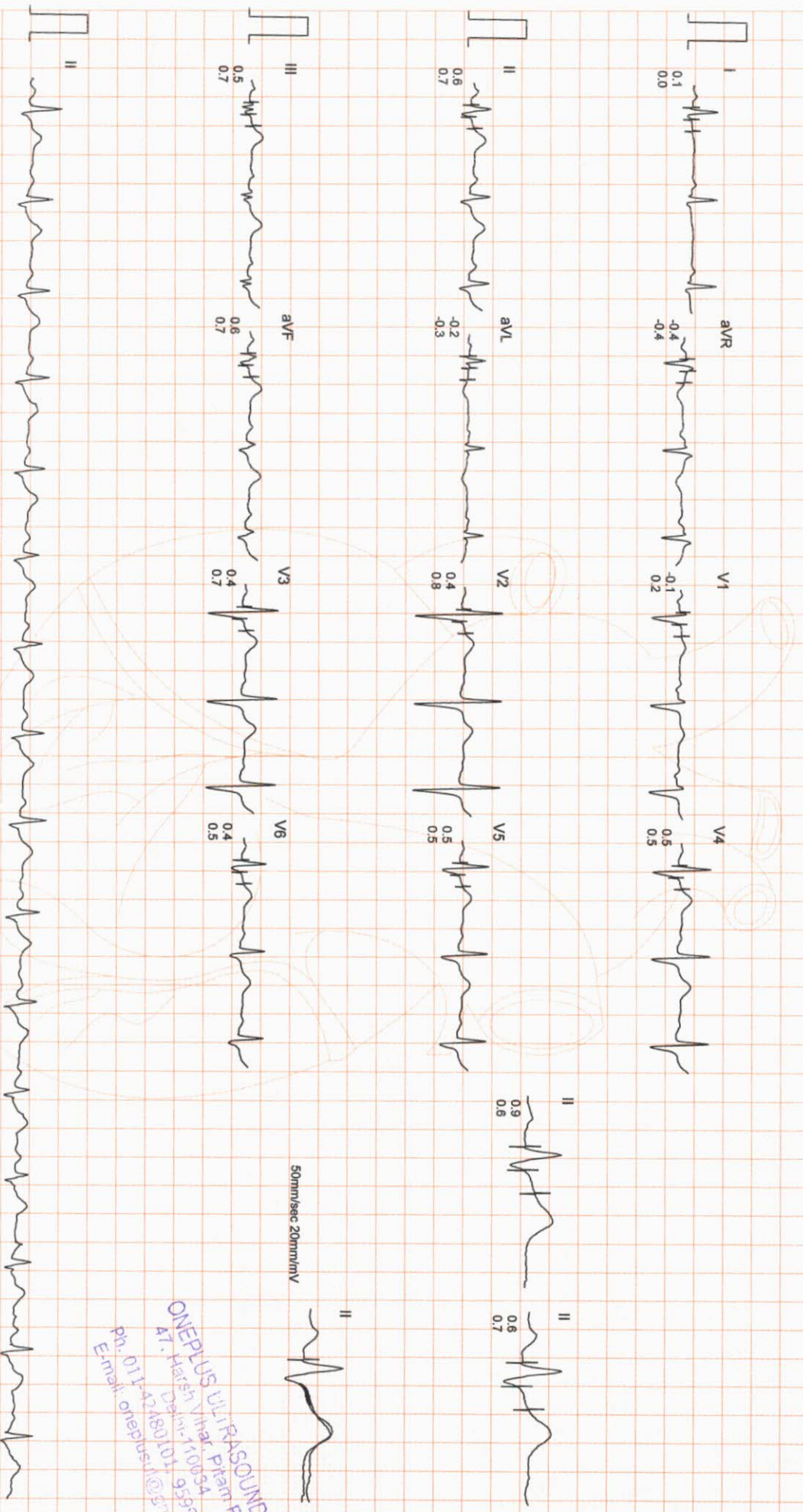
Mr. HARISH KUMAR GULYANI
I.D. : 988
AGE/SEX : 55/M
RECORDED : 12-2-2022 9:59

RATE : 98 BPM
B.P. : 118/76 mmHg

BRUCE
RECOVERY
PHASE TIME : 2:59

ST @ 10mm/mV
80ms PostJ
SPEED : 0.0 Km./Hr.
GRADE : 0.0 %

LINKED MEDIAN



50mm/sec 20mm/mV

ONEPLUS ULTRASOUND LAB
Dr. Harish Vikram, Pragam Pura,
Dahisar-710054
Ph. 011-42480101, 95999313051
E-mail: oneplusul@51mail.com


Filtered

Computer Corrected Baseline

25mm/sec 10mm/mV

CardiCom, INDIA Ph.:091-731-2620740, TeleFax:091-731-2431214





ONEPLUS ULTRASOUND LAB
 47, Harist Vihar, Pitam pura,
 Delhi-110024
 Ph. 011-22480101, 9559013051
 E-mail: oneplusul@rediffmail.com

ONEPLUS ULTRASOUND LAB

AGE/SEX : 55/M

RECORDED : 12-2-2022 9:59

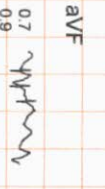







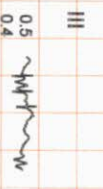


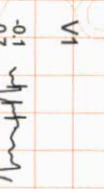



COMPARISON REPORT

SUPINE
 0.0kmph
 0.0%
 81 bpm
 B.P. 114/74
 80ms PostU

PEAK EXERCISE
 7:31
 1:31
 5.4kmph
 14.0%
 146 bpm
 B.P. 150/84
 80ms PostU

SUPINE
 0.0kmph
 0.0%
 81 bpm
 B.P. 114/74
 80ms PostU

PEAK EXERCISE
 7:31
 1:31
 5.4kmph
 14.0%
 146 bpm
 B.P. 150/84
 80ms PostU



ONEPLUS ULTRASOUND LAB
 47, Harish Mihar, Pijampura,
 Delhi 110034
 Ph: 011-42-4811101, 9599913051
 E-mail: oneplusul@gmail.com



OnePLUS Ultrasound Lab

Dr. Nitin Agarwal
Pathologist & Director
Ex. Sr. Res. MAMC
& Lok Nayak Hospital
Ex. Chief of Lab Dr. Lal Path Labs.

Dr. Pooja (Garg) Agarwal
Radiologist & Director
MAMC & Lok Nayak Hospital



QUALITY FIRST... ALWAYS!

NAME	:Mr. HARISH KUMAR GHULYANI	Barcode No	:10113355
AGE/GENDER	:55 YRS/Male	SPECIMEN DATE	:12/Feb/2022 09:12AM
PATIENT ID	:91070	SPECIMEN RECEIVED	:12/Feb/2022 09:21AM
REFERRED BY	:Dr. MEDIWHEEL	REPORT DATE	:12/Feb/2022 01:43PM
CENTRE NAME	:ONEPLUS ULTRASOUND LAB	LAB NO.	:012202120009

Test Name	Result	Unit	Ref. Range
-----------	--------	------	------------

HAEMATOLOGY

Health checkup 2 Male

Glycosylated Hemoglobin (HbA1c)	5.5	%	Non Diabetic adults <5.7 Prediabetic (at risk) 5.7-6.4 Diabetes >6.4
--	-----	---	--

Estimated average blood glucose (eag) 111

Reference range (mg/dl):

90 - 120:Excellent control, 121 - 150:Good Control, 151 - 180:Average Control, 181 - 210:Action Suggested

>211:Panic value

BLOOD GROUP (ABO)	B
Rh typing	POSITIVE

NOTE :

- * Apart from major A,B,H antigens which are used for ABO grouping and Rh typing, many minor blood group antigens exist. Agglutination may also vary according to titre of antigen and antibody.
- * So before transfusion, reconfirmation of blood group as well as cross-matching is needed.
- * Presence of maternal antibodies in newborns, may interfere with blood grouping.
- * Auto agglutination (due to cold antibody, falciparum malaria, sepsis, internal malignancy etc.) may also cause erroneous result.

CBC

Haemoglobin	10.6	g/dl	13.0-17.0
Total Leucocyte Count	7010	/cumm	4000-10000
Differential leucocyte count			
Neutrophils	54.5	%	40-80
Lymphocyte	23.20	%	20-40
Monocytes	5.30	%	2-10
Eosinophils	16.4	%	1-6
Basophils	0.6	%	0-2
RBC Count	4.43	million/cumm	4.5 - 5.5

Checked By.

DR. NITIN AGARWAL
MBBS, MD (PATHOLOGIST)
Dr NITIN AGARWAL
MBBS, MD (Path)
DMCR/01436

47, Harsh Vihar, Pitampura, New Delhi-110034 | Ph.: 011-42480101, 9599013051

E-mail: oneplusul@gmail.com | Web.: www.oneplusul.in

Page 1 of 4



OnePLUS Ultrasound Lab

QUALITY FIRST... ALWAYS!

Dr. Nitin Agarwal
Pathologist & Director
Ex. Sr. Res. MAMC
& Lok Nayak Hospital
Ex. Chief of Lab Dr. Lal Path Labs.

Dr. Pooja (Garg) Agarwal
Radiologist & Director
MAMC & Lok Nayak Hospital



NAME	:Mr. HARISH KUMAR GHULYANI	Barcode No	:10113355
AGE/GENDER	:55 YRS/Male	SPECIMEN DATE	:12/Feb/2022 09:12AM
PATIENT ID	:91070	SPECIMEN RECEIVED	:12/Feb/2022 09:21AM
REFERRED BY	:Dr. MEDIWHEEL	REPORT DATE	:12/Feb/2022 01:43PM
CENTRE NAME	:ONEPLUS ULTRASOUND LAB	LAB NO.	:012202120009

Test Name	Result	Unit	Ref. Range
PCV(Hematocrit)	34.6	%	40-50
MCV	78.2	fL	83-101
MCH	24	Pg	27-32
MCHC	30.7	G/dL	32-35
Platelet count	319000	/cumm	150000-450000
RDW-CV	14.7	%	11.4-14.0
ESR(WESTEGRENs METHOD)	15	mm in 1st hr	0-20

BIOCHEMISTRY

<u>Blood sugar fasting</u>	108	mg/dL	70-110
<u>Bun (blood urea nitrogen)</u>	14.60	mg/dl	8.4-25.7
<u>Uric acid, serum</u>	4.2	mg/dl	3.4-7.0
<u>Creatinine, serum</u>	0.75	mg/dl	0.60-1.1

LFT(LIVER FUNCTION TEST)

Bilirubin Total	0.65	mg/dl	0.1-1.2
Bilirubin Conjugated	0.24	mg/dl	0-0.4
Bilirubin Unconjugated	0.41	mg/dl	up to 0.7
SGOT (AST)	27	U/L	0-35
SGPT (ALT)	26	U/L	<45.0
Alkaline phosphatase	96	U/L	40-129
Gamma glutamyl transpeptidase	27	U/L	<66
Total Protein	6.8	gm/dl	6.60 - 8.70
Albumin	3.8	g/dL	3.8-5.1
Globulin	3.00	gm/dl	1.8-3.4
Albumin/Globulin Ratio	1.27		1.10 - 2.50

LIPID PROFILE

Cholesterol	169	mg/dl	50-200
Triglycerides	131	mg/dL	25-150
HDL Cholesterol	45	mg/dL	30-70

Checked By.

DR. NITIN AGARWAL
MBBS,MD(PATHOLOGY)

47, Harsh Vihar, Pitampura, New Delhi-110034 | Ph.: 011-42480101, 9599913355

E-mail: oneplusul@gmail.com | Web.: www.oneplusul.in

DR. NITIN AGARWAL
MBBS, MD (Path)
DMC/R/01436
Page 2 of 4



OnePLUS Ultrasound Lab

QUALITY FIRST... ALWAYS!

Dr. Nitin Agarwal
Pathologist & Director
Ex. Sr. Res. MAMC
& Lok Nayak Hospital
Ex. Chief of Lab Dr. Lal Path Labs.

Dr. Pooja (Garg) Agarwal
Radiologist & Director
MAMC & Lok Nayak Hospital



NAME	:Mr. HARISH KUMAR GHULYANI	Barcode No	:10113355
AGE/GENDER	:55 YRS/Male	SPECIMEN DATE	:12/Feb/2022 09:12AM
PATIENT ID	:91070	SPECIMEN RECEIVED	:12/Feb/2022 09:21AM
REFERRED BY	:Dr. MEDIWHEEL	REPORT DATE	:12/Feb/2022 01:43PM
CENTRE NAME	:ONEPLUS ULTRASOUND LAB	LAB NO.	:012202120009

Test Name	Result	Unit	Ref. Range
LDL cholesterol	98	mg/dL	<130
VLDL cholesterol	26.2	mg/dL	5-40
Cholesterol/HDL Ratio	3.8		Low Risk 3.3-4.97 Average Risk 4.4-7.1 Moderate Risk 7.1-11.0 High Risk >11.0
LDL/HDL Ratio	2.2		0 - 3.55

According to ATP III and NCEP guidelines

Parameter	Normal	Desirable	Borderline	High
Total cholesterol	<200	200-239		240
Triglycerides	<150	150-199	200-499	500
LDL	Optimal <100 Near Optimal 100-129	130-159	160-180	190
HDL	<40 : LOW 60 : HIGH			

CLINICAL PATHOLOGY

URINE ROUTINE

Physical examination

Quantity	20	ML
Colour	PALE YELLOW	
Transparency	SLIGHTLY TURBID	CLEAR
Sp.gravity	1.020	1.010-1.030
pH	6.00	
Reaction	ACIDIC	ACIDIC

Chemical examination

Urine protein	NIL	NIL
Urine sugar	NIL	NIL
Bilirubin, urine	NEGATIVE	NEGATIVE

Checked By.

DR. NITIN AGARWAL
MBBS, MD(PATHOLOGIST)

DR. NITIN AGARWAL
MBBS, MD (Path)
DMCR/01436

47, Harsh Vihar, Pitampura, New Delhi-110034 | Ph.: 011-42480101, 9599913053
E-mail: oneplusul@gmail.com | Web.: www.oneplusul.in



OnePLUS

Ultrasound Lab

QUALITY FIRST... ALWAYS!

Dr. Nitin Agarwal
Pathologist & Director
Ex. Sr. Res. MAMC
& Lok Nayak Hospital
Ex. Chief of Lab Dr. Lal Path Labs.

Dr. Pooja (Garg) Agarwal
Radiologist & Director
MAMC & Lok Nayak Hospital



NAME	:Mr. HARISH KUMAR GHULYANI	Barcode No	:10113355
AGE/GENDER	:55 YRS/Male	SPECIMEN DATE	:12/Feb/2022 09:12AM
PATIENT ID	:91070	SPECIMEN RECEIVED	:12/Feb/2022 09:21AM
REFERRED BY	:Dr. MEDIWHEEL	REPORT DATE	:12/Feb/2022 01:43PM
CENTRE NAME	:ONEPLUS ULTRASOUND LAB	LAB NO.	:012202120009

Test Name	Result	Unit	Ref. Range
Urobilinogen	NORMAL		NORMAL
Ketones	NEGATIVE		NEGATIVE
Microscopic examination			
Pus cells.	4-6	/HPF	0-2
Epithelial cells	1-2	/HPF	NIL
R.B.C.	NIL	/HPF	NIL
Casts	NIL	/HPF	NIL
Crystals	NIL	/HPF	NIL
Bacteria	NIL	/HPF	NIL
Others.	NIL	NIL	NIL

*** End Of Report ***

Checked By.

DR. NITIN AGARWAL
MBBS,MD(PATHOLOGIST)

Dr. NITIN AGARWAL
MBBS, MD (Path)
DMC/R/01436

47, Harsh Vihar, Pitampura, New Delhi-110034 | Ph.: 011-42480101, 9599913058

E-mail: oneplusul@gmail.com | Web.: www.oneplusul.in

Clinical correlation is essential for final diagnosis. • If test results are unsatisfactory please contact personally or on phone. • This report is for perusal of doctors only.
• All disputes Subject to Delhi Jurisdiction only. • Not for medicolegal purposes. • All congenital anomalies in a foetus may not be diagnosed in routine obstetric ultrasound.



OnePLUS Ultrasound Lab

— QUALITY FIRST... ALWAYS! —

Dr. Nitin Agarwal
Pathologist & Director
Ex. Sr. Res. MAMC
& Lok Nayak Hospital
Ex. Chief of Lab Dr. Lal Path Labs.

Dr. Pooja (Garg) Agarwal
Radiologist & Director
MAMC & Lok Nayak Hospital



NAME	:Mr. HARISH KUMAR GHULYANI	Barcode No	:10113355
AGE/GENDER	:55 YRS/Male	SPECIMEN DATE	:12/Feb/2022 09:12AM
PATIENT ID	:91070	SPECIMEN RECEIVED	:12/Feb/2022 02:29PM
REFERRED BY	:Dr. MEDIWHEEL	REPORT DATE	:12/Feb/2022 04:37PM
CENTRE NAME	:ONEPLUS ULTRASOUND LAB	LAB NO.	:012202120009

Test Name	Result	Unit	Ref. Range
-----------	--------	------	------------

BIOCHEMISTRY

Health checkup 2 Male

Blood sugar pp	120	mg/dL	70.0-140.0
-----------------------	-----	-------	------------

ENDOCRINOLOGY

PSA TOTAL

Prostatic specific antigen, Total	0.94	ng/ml	<4.0
-----------------------------------	------	-------	------

< 40 years	0.21 to 1.72 ng/ml
40 - 49	0.27 to 2.19 ng/ml
50 - 59	0.27 to 3.42 ng/ml
60 - 69	0.22 to 6.16 ng/ml
> 69	0.21 to 6.77 ng/ml

Notes:

PSA is principally produced by the glandular epithelium of the prostate, and is secreted in the seminal fluid. PSA is also present in urine and blood. PSA acts on seminal fluid to fluidify and increase sperm mobility. PSA levels rise in prostatic pathologies such as benign prostatic hyperplasia (BPH) or prostate cancer.

THYROID PROFILE(T3,T4,TSH)

Triiodothyronine total [t3]	0.68	ng/dl	0.52-1.9
Thyroxine total [t4]	6.50	µg/dl	4.4 - 10.8
TSH (Thyroid Stimulating Hormone)	2.20	µIU/ml	0.25-5.0

AGE WISE VARIATION IN TSH

AGE	TSH(µIU/ml)	AGE	TSH(µIU/ml)
1-4 weeks	1.00 - 19.0	16-20 yrs	0.25 - 5.0
1-12 mths	1.70 - 9.1	21 - 80 yrs	0.25 - 5.0
1-5 yrs	0.80 - 8.2	I st trimester	0.25 - 5.0
6-10 yrs	0.25 - 5.0	II nd trimester	0.50 - 5.0

Checked By.

DR. NITIN AGARWAL
MBBS,MD(PATHOLOGIST)
Dr NITIN AGARWAL
MBBS, MD (Path)
DMC/R/01051

47, Harsh Vihar, Pitampura, New Delhi-110034 | Ph.: 011-42480101, 9599913036
E-mail: oneplusul@gmail.com | Web.: www.oneplusul.in



OnePLUS
Ultrasound Lab
— QUALITY FIRST... ALWAYS! —

Dr. Nitin Agarwal
Pathologist & Director
Ex. Sr. Res. MAMC
& Lok Nayak Hospital
Ex. Chief of Lab Dr. Lal Path Labs.

Dr. Pooja (Garg) Agarwal
Radiologist & Director
MAMC & Lok Nayak Hospital



NAME	:Mr. HARISH KUMAR GHULYANI	Barcode No	:10113355
AGE/GENDER	:55 YRS/Male	SPECIMEN DATE	:12/Feb/2022 09:12AM
PATIENT ID	:91070	SPECIMEN RECEIVED	:12/Feb/2022 02:29PM
REFERRED BY	:Dr. MEDIWHEEL	REPORT DATE	:12/Feb/2022 04:37PM
CENTRE NAME	:ONEPLUS ULTRASOUND LAB	LAB NO.	:012202120009

Test Name	Result	Unit	Ref. Range
11-15 yrs	0.25 - 5.0	II rd trimester	0.4 - 6.0

Reference ranges - Interpretation of Diagnostic tests - (Jacques Wallach)

1. Primary hypothyroidism is accompanied by depressed serum T3 and T4 values and elevated serum TSH level.
2. Primary hyperthyroidism is accompanied by elevated serum T3 and T4 levels along with depressed TSH values.
3. Slightly elevated T3 levels may be found in pregnancy and estrogen therapy, while depressed levels may be encountered in severe illness, renal failure and during therapy with drugs like propranolol and propyl thiouracil.
4. Although elevated TSH levels are nearly always indicative of primary hypothyroidism, and may be seen in secondary thyrotoxicosis

CLINICAL PATHOLOGY

STOOL ROUTINE

Physical examination

Colour	BROWNISH		
Consistency	SEMI FORMED		Semi Formed
Blood	ABSENT		Absent
Mucus	ABSENT		Absent

Chemical examination, stool

pH	5.50		
----	------	--	--

Microscopic examination

Pus cells	0-1	/HPF	
Red blood cells	NIL	/HPF	NIL
Ova	NIL		NIL
Cysts	NIL		NIL
Bacteria	PRESENT	/HPF	NIL
Others	NIL		

*** End Of Report ***

Checked By.

DR. NITIN AGARWAL
MBBS, MD (PATHOLOGIST)

Dr NITIN AGARWAL
MBBS, MD (Path)
DMC/R/01436

47, Harsh Vihar, Pitampura, New Delhi-110034 | Ph.: 011-42480101, 011-2999913051
E-mail: oneplusul@gmail.com | Web.: www.oneplusul.in



OnePLUS
Ultrasound Lab

— QUALITY FIRST... ALWAYS! —

Dr. Nitin Agarwal

Pathologist & Director
Ex. Sr. Res. MAMC
& Lok Nayak Hospital
Ex. Chief of Lab Dr. Lal Path Labs.

Dr. Pooja (Garg) Agarwal

Radiologist & Director
MAMC & Lok Nayak Hospital

Name	: Mr. HARISH KUMAR GHULYANI	Age/Sex	: 55 YRS/Male
Ref. By	: Dr. MEDIWHEEL	Lab No	: 012202120009
Date	: 12-Feb-2022	Patient ID	: LSHHI91070

X-ray-Chest PA view

Bony cage and soft tissues are normal.

Cardiomegaly is present .

Mediastinum is normal.


Both hila are normal.

Both costophrenic angles are clear.

Both domes of diaphragm are normal.

Pulmonary vascular markings are prominent. No parenchymal lesion seen.

IMPRESSION: Cardiomegaly .


DR. POOJA GARG
RADIOLOGIST
REG NO- DMC/R/03398

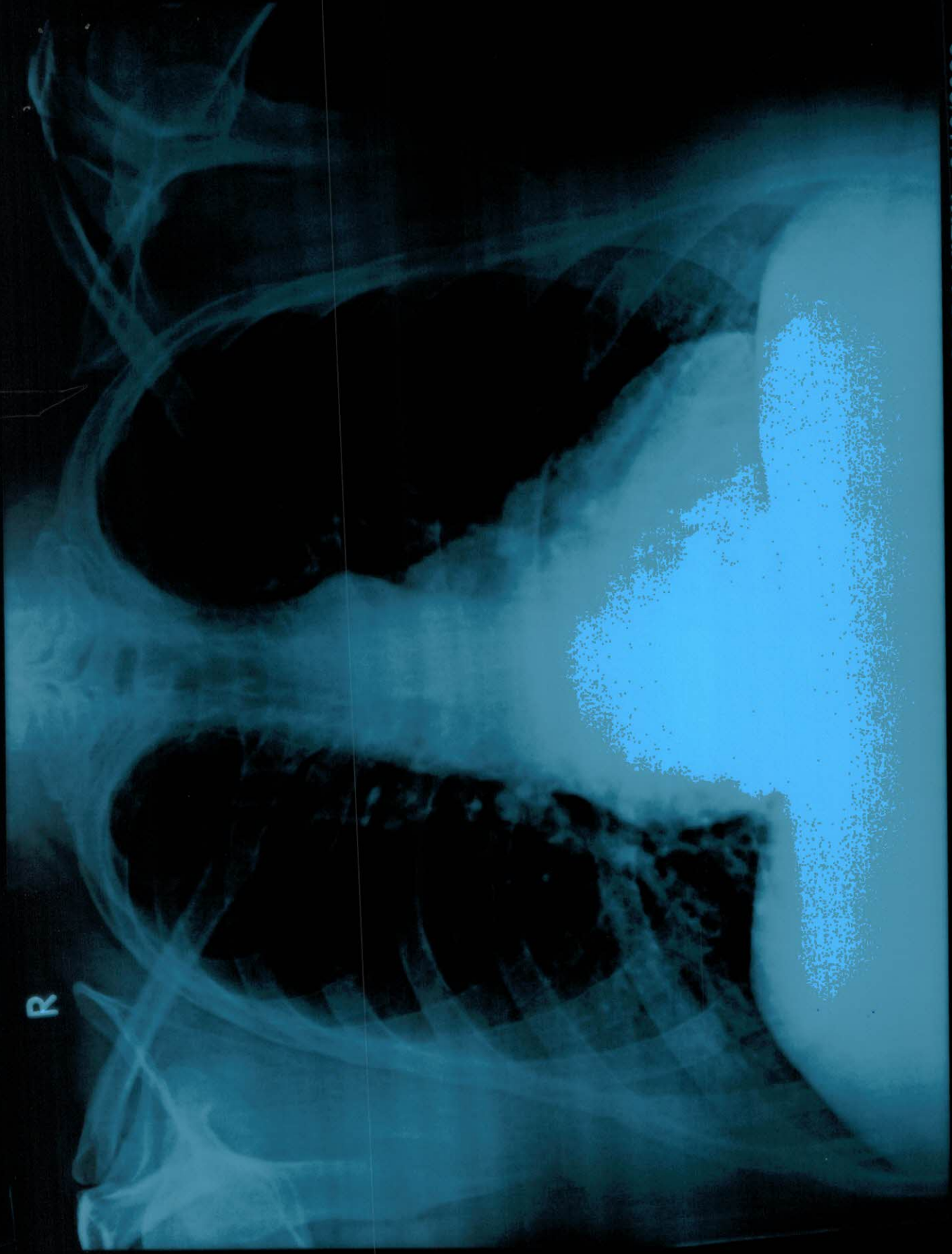
DR. POOJA GARG
M.B.B.S., D.M.R.D
Reg No. DMC/R/03398
Radiologist

Type By : pooja

47, Harsh Vihar, Pitampura, New Delhi-110034 | Ph.: 011-42480101, 9599913051
E-mail: oneplusul@gmail.com | Web.: www.oneplusul.in

Clinical correlation is essential for final diagnosis. • If test results are unsatisfactory please contact personally or on phone. • This report is for perusal of doctors only.
• All disputes Subject to Delhi Jurisdiction only. • Not for medicolegal purposes. • All congenital anomalies in a foetus may not be diagnosed in routine obstetric ultrasound.

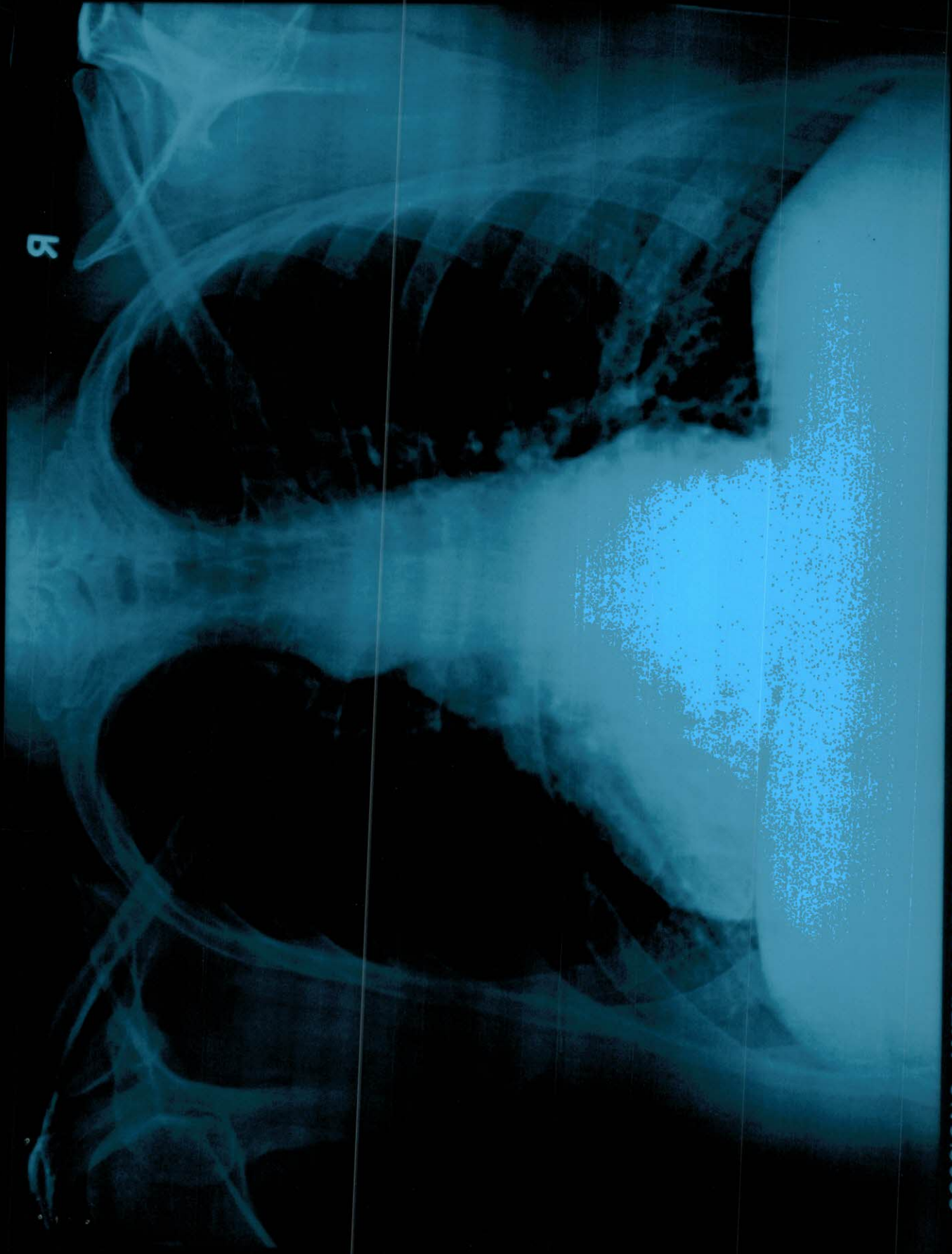
R



MR GHULYANI HARISH KUMAR 55 YRS 12-2-2022 M CHEST PA VIEW 2/12/2022
ONEPLUS ULTRASOUND LAB, 47-HARSH VIHAR, PITAMPURA

ONEPLUS ULTRASOUND LAB 43-HARSH NIHAR, BILAMPUR
MR GHULYANI HARISH KUMAR 22 YRS 15-5-5055 M CHEST PA VIEW 51515055

R





OnePLUS
Ultrasound Lab

— QUALITY FIRST... ALWAYS! —

Dr. Nitin Agarwal
Pathologist & Director
Ex. Sr. Res. MAMC
& Lok Nayak Hospital
Ex. Chief of Lab Dr. Lal Path Labs.

Dr. Pooja (Garg) Agarwal
Radiologist & Director
MAMC & Lok Nayak Hospital

Name	: Mr. HARISH KUMAR GHULYANI	Age/Sex	: 55 YRS/Male
Ref. By	: Dr. MEDIWHEEL	Lab No	: 012202120009
Date	: 12-Feb-2022	Patient ID	: LSHHI91070

ULTRASOUND EXAMINATION---WHOLE ABDOMEN

Suboptimal evaluation is possible due to body habitus of the patient.

Liver is enlarged in size (16.5 cm) and normal in outline with altered echopattern. Diffuse increase in echogenicity of liver parenchyma is noted, suggestive of fatty infiltration (grade II). Intrahepatic biliary radicles are not dilated. No abscess or mass lesion seen. Hepatic veins, portal vein, IVC and aorta are normal. CBD is normal in caliber.

Gall bladder is well distended with anechoic lumen. Wall thickness is normal.

Both kidneys are normal in size, shape, position, outline and echopattern. Corticomedullary differentiation is maintained. No pelvicalyceal dilation or mass lesion is seen.

Renal measurements are --

Rt. Kidney - 12.3 x 5.3 cm.
Lt. kidney - 12.6 x 5.5 cm

Spleen is normal in size and echotexture. No mass lesion seen.

Pancreas is normal in size, outline and echotexture.

Urinary bladder is normal in shape and position. No evidence of intravesical stone or mass seen.

Prostate is enlarged, normal in shape and echopattern.

Prostate measures 3.2 x 4.1 x 5.3 cm. **Weight of prostate is 35.9 grams.**


Pre void volume is 200 cc

Post void volume is 30 cc

No abnormal bowel wall thickening seen in right iliac fossa.
No free fluid seen anywhere in abdomen.

IMPRESSION:

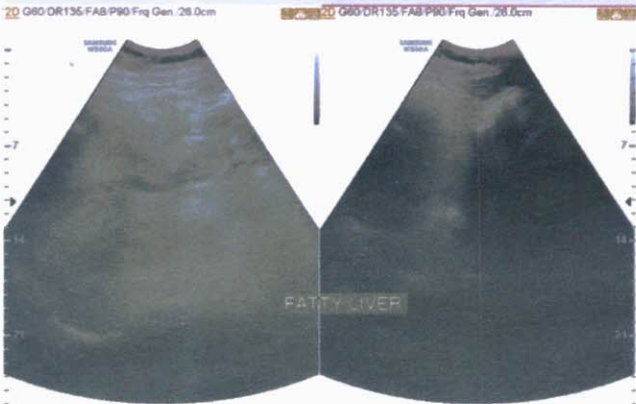- Fatty infiltration of liver (grade II) with hepatomegaly.
- Prostatic hypertrophy without significant residual urine.


DR. POOJA GARG
RADIOLOGIST
REG NO. DMC/R/03398
DR. POOJA GARG
M.B.B.S., D.M.R.D.
Reg. No. DMC/R/03398
Radiologist

Type By : pooja

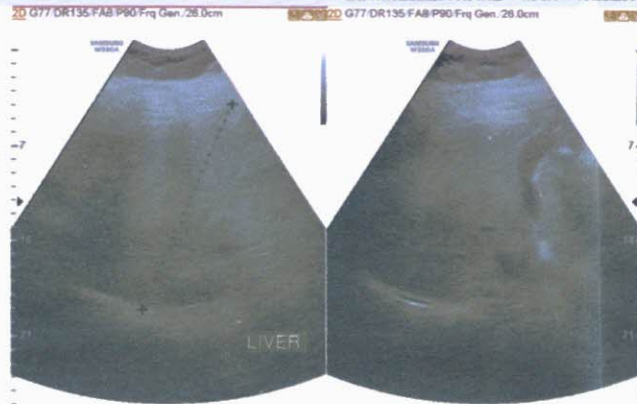
47, Harsh Vihar, Pitampura, New Delhi-110034 | Ph.: 011-42480101, 9599913051
E-mail: oneplusul@gmail.com | Web.: www.oneplusul.in

MR HARISH KUMAR
OnePlus Ultrasound Lab
CA1-7A / Abdomen / FR 17Hz
MI 1.4 12-02-2022
Tis 0.1 10:25:06 AM

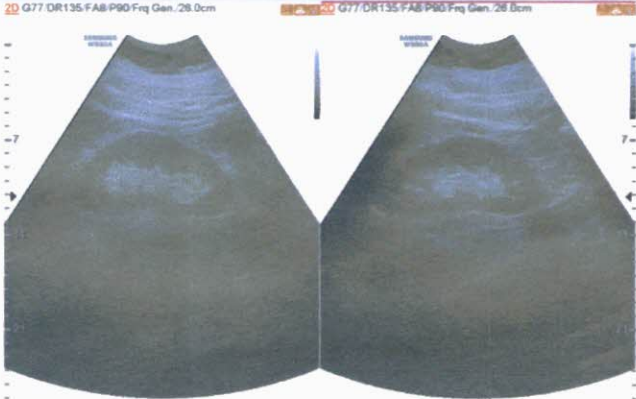

D1 16.53 cm

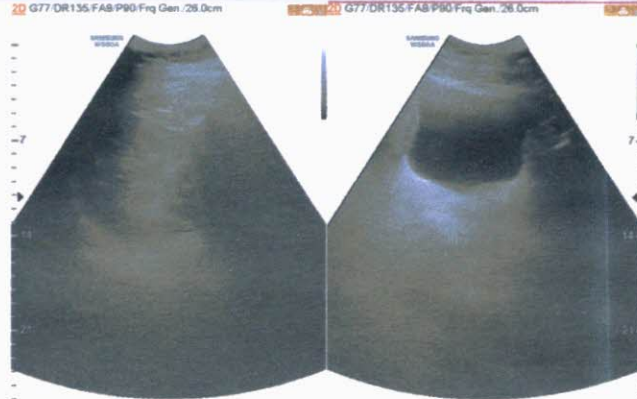
MR HARISH KUMAR
OnePlus Ultrasound Lab
CA1-7A / Abdomen / FR 17Hz
MI 1.4 12-02-2022
Tis 0.1 10:25:20 AM



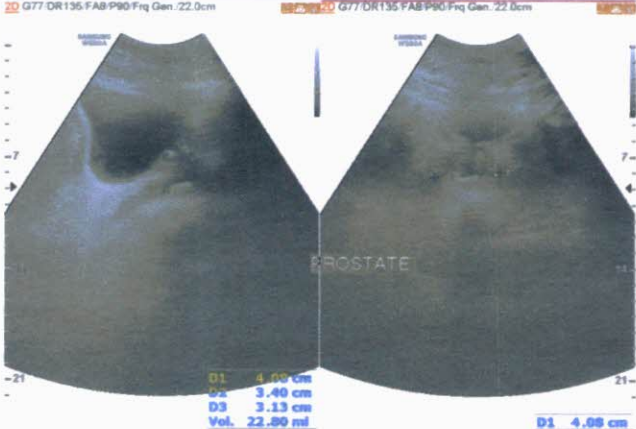
MR HARISH KUMAR
OnePlus Ultrasound Lab
CA1-7A / Abdomen / FR 17Hz
MI 1.4 12-02-2022
Tis 0.1 10:25:57 AM



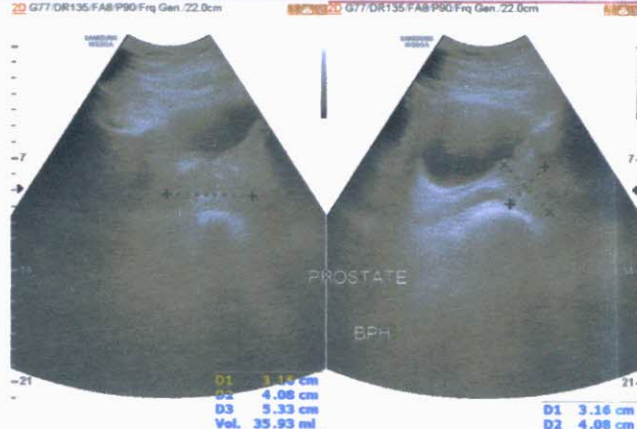
MR HARISH KUMAR
OnePlus Ultrasound Lab
CA1-7A / Abdomen / FR 17Hz
MI 1.4 12-02-2022
Tis 0.1 10:26:20 AM



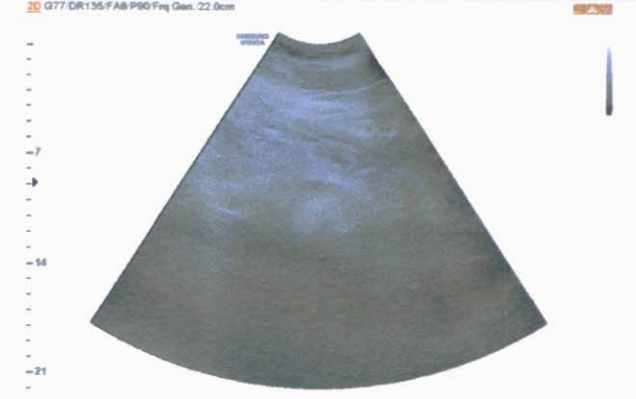MR HARISH KUMAR
OnePlus Ultrasound Lab
CA1-7A / Abdomen / FR 19Hz
MI 1.4 12-02-2022
Tis 0.1 10:26:49 AM



MR HARISH KUMAR
OnePlus Ultrasound Lab
CA1-7A / Abdomen / FR 19Hz
MI 1.4 12-02-2022
Tis 0.1 10:27:16 AM



MR HARISH KUMAR
OnePlus Ultrasound Lab
CA1-7A / Abdomen / FR 19Hz
MI 1.4 12-02-2022
Tis 0.1 10:27:20 AM



MR HARISH KUMAR
OnePlus Ultrasound Lab
CA1-7A / Abdomen / FR 19Hz
MI 1.4 12-02-2022
Tis 0.1 10:28:22 AM

