



A.L.C. Advance Imaging Dignostics

ISO 9001:2015 Certified center

(A Unit of Subham Imaging P.K. Arogyam Health & Wellness Center)

E-95, P.C. Colony, Near Sai Netryalaya Transformer, Kankarbagh, Patna - 20

alcdiagnostics@gmail.com

www.pkarogayamhealthcheckup.com

7050037694 8271206196

OPINION MUST BE CORRELATES WITH CLINICALLY & OTHER INVESTIGATION FOR FINAL DIAGNOSIS. NOT FOR MEDICO LEGAL PURPOSE

PATIENT NAME : Mr. HIMANSHU KR SINHA

PATIENT ID: 2787

COL DATE : 29/12/2022 REPORTING DATE: 29/12/2022 AGE SEX:- 40 YRS/M

REF.BY : DR. / MEDIWHEEL.

TEST NAME	RESULT	Unit	REF.RANGE
-----------	--------	------	-----------

BLOOD GROUP	:	' O '	
-------------	---	-------	--

Rh Typing	:	NEGATIVE	
-----------	---	----------	--

Note: Do always cross – matching before blood transfusion

ESTB BY:-

Dr. P. K. Tiwari
MD, M.Sc (Radio Imaging)
Ph.D (Art Nuclear Medicine)
Consultant Imaginologist & Sonologist

Dr. S. Kumar
MD (Pat)
Consultant Pathologist

Dr. Abhishek Kumar
MBBS, MD
Consultant Neuropatho Physiologist

Dr. Kumari Suman
MBBS, DGO, MD
Consultant (TVS & HSG Specialist)

Dr. A.K. Singh
MBBS, PGDMCH
Consultant Radiologist & Sonologist


Dr. Ankur Kumar
MD
Consultant Radiologist & Sonologist

PRINTING MISTAKE SHOULD BE REPORTED BACK IMMEDIATELY/ यहाँ जन्म से पहले भुण का लिंग जाँच नहीं होता है ।



A.L.C. Advance Imaging Dignostics

ISO 9001:2015 Certified center

(A Unit of Subham Imaging P.K. Arogyam Health & Wellness Center)

E-95, P.C. Colony, Near Sai Netryalaya Transformer, Kankarbagh, Patna - 20

alcdiagnostics@gmail.com

www.pkarogayamhealthcheckup.com

7050037694, 8271206196

OPINION MUST BE CORRELATES WITH CLINICALLY & OTHER INVESTIGATION FOR FINAL DIAGNOSIS. NOT FOR MEDICO LEGAL PURPOSE

PATIENT NAME : Mr. HIMANSHU KR SINHA

PATIENT ID : 2787

COL DATE : 29/12/2022 REPORTING DATE: 29/12/2022 AGE SEX : 40 YRS/M

REF.BY : DR./ MEDIWHEEL.

GLYCOSYLATED HEMOGLOBIN

TEST NAME	RESULT	Unit	REF.RANGE
HbA1c	3.8 %		Below 5.7 % : Normal 5.7 – 6.4 % : Prediabetic > = 6.5 % : Diabetic
AVERAGE PLASMA GLUCOSE	92.0 mg/dl		90 – 120 mg/dl : Good Control 121 – 150 mg/dl : Fair Control 151- 180 mg/dl: Unsatisfactory Control >180 mg/dl : Poor Control

ESTB BY:-

Dr. P. K. Tiwari
MD, M.Sc (Radio Imaging)
Ph.D (AI) Nuclear Medicine)
Consultant Imagiologist & Sonologist

Dr. S. Kumar
MD (Pat)
Consultant Pathologist

Dr. Abhishek Kumar
MBBS, MD
Consultant Neuropatho Physiologist

Dr. Kumari Sumon
MBBS, DGO, MD
Consultant (TVS & HSG Specialist)

Dr. Ankur Kumar
Consultant Radiologist
MBBS, MD
Consultant Radiologist
Reg No. 39540

PRINTING MISTAKE SHOULD BE REPORTED BACK IMMEDIATELY/ यहाँ जन्म से पहले भ्रूण का लिंग जाँच नहीं होता है ।



A.L.C. Advance Imaging Dignostics

ISO 9001:2015 Certified center

(A Unit of Subham Imaging P.K. Arogyam Health & Wellness Center)

E-95, P.C. Colony, Near Sai Netryalaya Transformer, Kankarbagh, Patna - 20

alcdiagnostics@gmail.com

www.pkarogayamhealthcheckup.com

7950037494, 9271204196

OPINION MUST BE CORRELATES WITH CLINICALLY & OTHER INVESTIGATION FOR FINAL DIAGNOSIS. NOT FOR MEDICO LEGAL PURPOSE

PATIENT NAME : Mr. HIMANSHU KR SINHA

PATIENT ID: 2787

COL DATE : 29/12/2022 REPORTING DATE: 29/12/2022 AGE SEX:- 40 YRS/M

REF.BY : DR. / MEDIWHEEL.

TEST NAME	RESULT	Unit	REF.RANGE
ESR	12 mm/hr		<20 mm/hr
CBC			
Total W.B.C. Count	6,300 /cumm		4000-11,000 /cumm
R B C COUNT	4.70 Million/ CUmm		4 - 7 Million/ CUmm
Platelets count	1.58 Lakh/ cumm		1.5-5.0 Lakh/ cumm
Differential Count of W.B.C.			
Neutrophils	69 %		40-70%
Lymphocytes	25 %		25-40%
Eosinophils	05 %		01-05%
Mnonocytes	01 %		00-02%
Basophiles	00 %		00 -0%
HAEMOGLOBIN	14.8 gm/dl (101.3 %)		14.6 gm/dl = 100%
PCV	43.3 %		35-47 %
MCV	92.2 fl		76-96 fl
MCH	31.5 pg		29-35 pg
MCHC	34.2 %		30-38 %

ESTB BY:-

Dr. P. K. Tiwari
MD, M.Sc (Radio Imaging)
Ph.D (Ab Nuclear Medicine)
Consultant Imaginologist & Sonologist

Dr. S. Kumar
MD (Pat)
Consultant Pathologist

Dr. Abhishek Kumar
MBBS, MD
Consultant Neuropatho Physiologist

Dr. Kumari Suman
MBBS, DGO, MD
Consultant (IVS & HSG Specialist)

Dr. Ankur Kumar
MBBS, Radiologist
Consultant Radiologist
Dr. A. K. Singh
MBBS, PGDMCH
Consultant Radiologist / Sonologist

PRINTING MISTAKE SHOULD BE REPORTED BACK IMMEDIATELY/ यहाँ जन्म से पहले बुध का लिंग जाँच नहीं होता है ।



A.L.C. Advance Imaging Diagnostics

ISO 9001:2015 Certified center

(A Unit of Subham Imaging P.K. Arogyam Health & Wellness Center)

E-95, P.C. Colony, Near Sai Netryalaya Transformer, Kankarbagh, Patna - 20

alcdiagnostics@gmail.com

www.pkarogyamhealthcheckup.com

7050037694, 8271206196

OPINION MUST BE CORRELATES WITH CLINICALLY & OTHER INVESTIGATION FOR FINAL DIAGNOSIS. NOT FOR MEDICO LEGAL PURPOSE

PATIENT NAME : Mr. HIMANSHU KR SINHA

PATIENT ID: 2787

COL DATE : 29/12/2022 REPORTING DATE: 29/12/2022 AGE SEX:- 40 YRS/M

REF.BY : DR./ MEDIWHEEL..

TEST NAME	RESULT	Unit	REF.RANGE
LFT:-			
SGPT	53.1	IU/L	5 - 48 IU/L
S G O T	37.8	IU/L	5 - 40 IU/L
ALKALINE PHOSPHATASE	102.3	IU/L	25 - 147 IU/L
TOTAL PROTIN	7.7	g/dl	6.0 - 8.7 g/dl
SERUM ALBUMIN	4.8	g/dl	3.5 - 5.4 g/dl
SERIUM GLUBLINE	2.9	g/dl	2.3 - 3.6 g/dl
AG RATIO	1.6: 1		1.0 - 2.3 g/dl
BILIRUBIN			
TOTAL	0.62	mg/dl	0.1 - 1.1 mg/dl
IRECT	0.21	mg/dl	0.0 - 0.32 mg/dl
INDIRECT	0.41	mg/dl	0.0 - 0.78 mg/dl
GGTP (GGT)	26.2	iu/L	8 - 38 iu/L
KFT/RFT			
URIC ACID	5.7	mg/dl	3.2 - 7.0 mg/dl
SERUM CREATNINE	1.1	mg/dl	0.6 - 1.5 mg/dl
BLOOD URIA	34.4	mg/dl	5 - 45 mg/dl
BLOOD URIA NITROZEN(BUN).	16.0	mg/dl	5 - 24 mg/dl

ESTB BY:-

Dr. P. K. Tiwari
MD, M.Sc (Radio Imaging)
Ph.D (Alt Nuclear Medicine)
Consultant Imagingologist & Sonologist

Dr. S. Kumar
MD (Pat)
Consultant Pathologist

Dr. Abhishek Kumar
MBBS, MD
Consultant Neuropatho Physiologist

Dr. Kumari Sumar
MBBS, DGO, MD
Consultant (TVS & HSG Specialist)

Dr. Ankur Kumar
Consultant Radiologist
MBBS, MD
Dr. Anurag Singh
MBBS, PGDINCH
Consultant Radiologist, Esophagologist

PRINTING MISTAKE SHOULD BE REPORTED BACK IMMEDIATELY/ यहाँ जन्म से पहले भुण का लिंग जाँच नहीं होता है ।



A.L.C. Advance Imaging Dignostics

ISO 9001:2015 Certified center

(A Unit of Subham Imaging P.K. Arogyam Health & Wellness Center)

E-95, P.C. Colony, Near Sai Netryalaya Transformer, Kankarbagh, Patna - 20

alcdiagnostics@gmail.com

www.pkarogyamhealthcheckup.com

7050037694, 8271206196

OPINION MUST BE CORRELATES WITH CLINICALLY & OTHER INVESTIGATION FOR FINAL DIAGNOSIS. NOT FOR MEDICO LEGAL PURPOSE

PATIENT NAME : Mr. HIMANSHU KR SINHA

PATIENT ID:2787

COL DATE : 29/12/2022 REPORTING DATE: 29/12/2022 AGE SEX : 40 YRS/M

REF.BY : DR. /MEDIWHEEL.

TEST NAME	RESULT	Unit	REF.RANGE
BLOOD SUGAR (F)	79.0 mg/dl		70 - 110 mg/dl

LIPID PROFILE:-

TOTAL CHOLESTROL	162.7 mg/dl		130 -250 mg/dl
TRIGLYCERIDE	155.2 mg/dl		50 -160 mg/dl
HDL CHOLESTROL	43.0 mg/dl		30 - 60 mg/dl
LDL CHOLESTROL	88.7 mg/dl		80 -130 mg/dl
VLDL CHOLESTROL	31.0 mg/dl		15 - 40 mg/dl
T.CH./HDL RATIO	3.5 :1		Upto 5:1
LDL./HDL RATIO	2.0 :1		2 - 4:1

ESTB BY:-

Dr. P. K. Tiwari
MD, M.Sc (Radio Imaging)
Ph.D (All Nuclear Medicine)
Consultant Imagonologist & Sonologist

Dr. S. Kumar
MD (Pat)
Consultant Pathologist

Dr. Abhishek Kumar
MBBS, MD
Consultant Neuropatho Physiologist

Dr. Kumari Suman
MBBS, DGO, MD
Consultant (TVS & HSG Specialist)

Dr. A. K. Singh
MBBS, PGDMCH
Consultant Radiologist & Sonologist

Dr. Ankur Kumar
MBBS, MD
Consultant Radiologist
Reg No 39540

PRINTING MISTAKE SHOULD BE REPORTED BACK IMMEDIATELY/ यहाँ जन्म से पहले भुण का लिंग जाँच नहीं होता है ।

ID 2787 CASE :

HIMANSHU KUMAR SINHA

29/12/2022 12:34:42

AGE 40Y 0M 0D

MALE

ALC ADVANCE IMAGING DIAGNOSTICS
E95 PC COLONY KANKARBAGH PATNA

Cms 89KG

RATE : 66 bpm SINUS RHYTHM
 R-R : 896 ms INFERIOR T WAVE ABNORMALITY IS NONSPECIFIC
 P-R : 122 ms
 QRS : 90 ms
 QT : 396 ms
 QTc : 407 ms



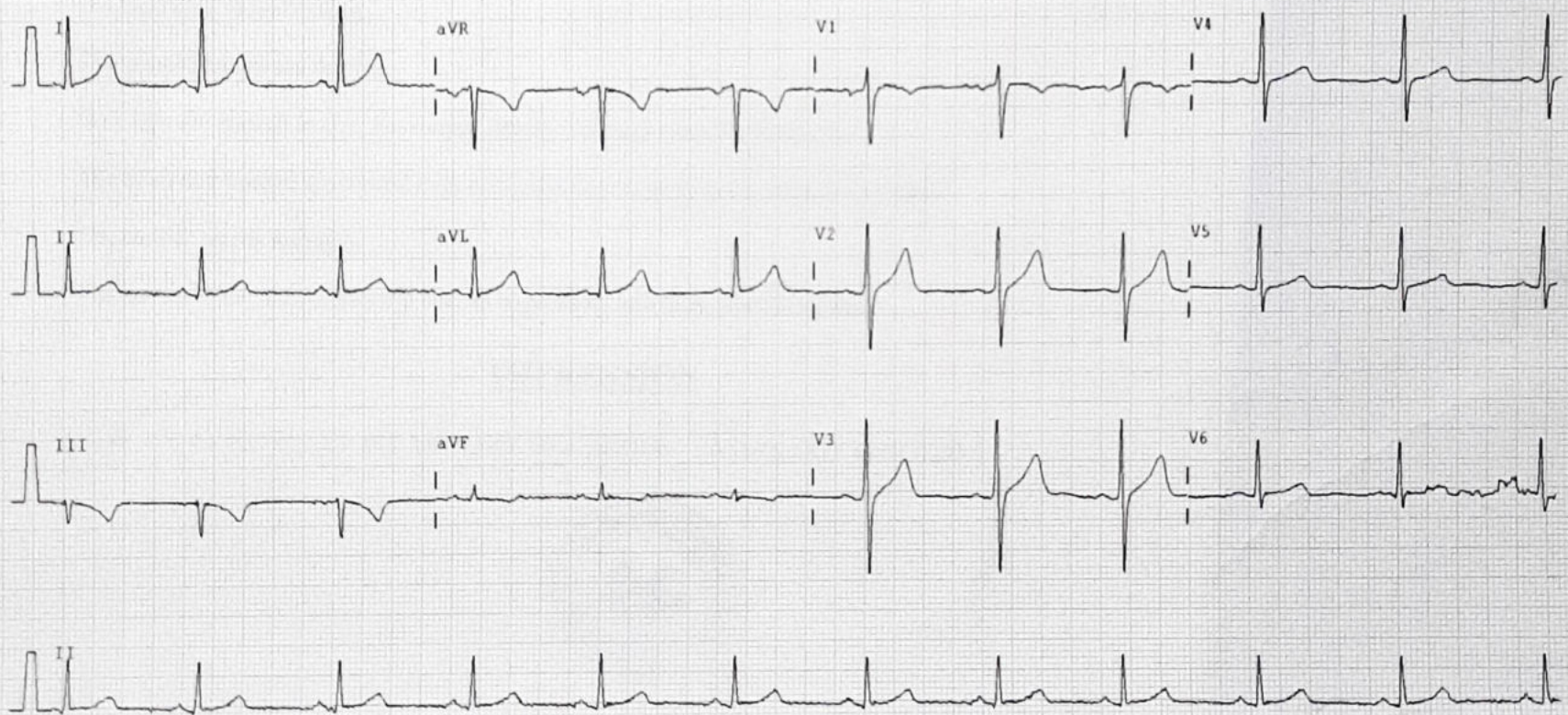
--AXIS--

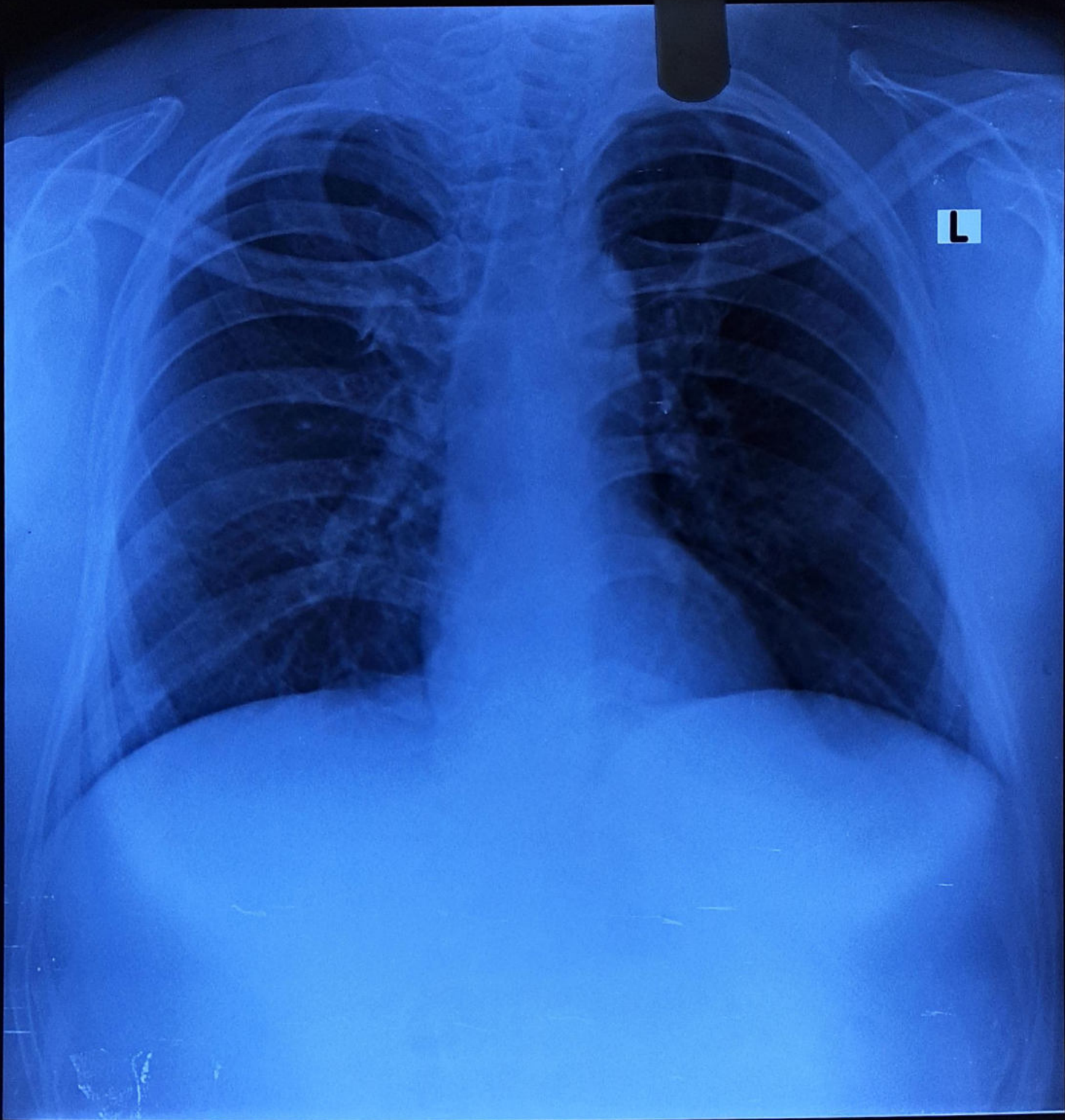
P : 24°
 QRS : 08°
 T : -03°

12 SL. REPORT FORMAT: 3x4+1L SQ

REF: DR B O B

Dr. DR ABHISHEK KUMAR MD





HIMANSHU KUMAR SINHA AGE 40 YEARS 2787 BY DR. MEDIWHEEL CHEST,FRN P->A 12/16/2022

A.L.C. Advance Imaging Diagnostics Centre PATNA - 20



A.L.C. Advance Imaging Dignostics

ISO 9001 2015 Certified center

(A Unit of Subham Imaging P.K. Arogyam Health & Wellness Center)

E-95, P.C. Colony, Near Sai Netryalaya Transformer, Kankarbagh, Patna - 20

alcdiagnostics@gmail.com

www.pkarogayamhealthcheckup.com

7050037694, 8271206196

OPINION MUST BE CORRELATES WITH CLINICALLY & OTHER INVESTIGATION FOR FINAL DIAGNOSIS. NOT FOR MEDICO LEGAL PURPOSE

Pt. Name :- HIMANSHU KR SINHA

Date:- 30-Dec-22

Ref. By :- DR. MEDIWHEEL

Age / Sex - 40 Yrs. M.

Thanks for your kind referral

X-RAYCHEST (P.A.VIEW)

The lungs on the either side show equal translucency.

The peripheral pulmonary vasculature is normal.

No focal lung lesion is seen.

The pleural spaces are normal.

Both hila are normal in size, have equal density and bear normal relationship.

The heart and trachea are central in position and no mediastinal abnormality is visible.

The cardiac size is normal.

The domes of the diaphragms are normal in position, and show smooth outline.

IMPRESSION

- NO EVIDENCE OF PULMONARY OR CARDIAC PATHOLOGY IS NOTED.



ESTB BY:-

Consultant Radiologist

Dr. P. K. Tiwari
MD, M.Sc (Radio Imaging)
Ph.D (Ab Nuclear Medicine)
Consultant Imagonologist & Sonologist

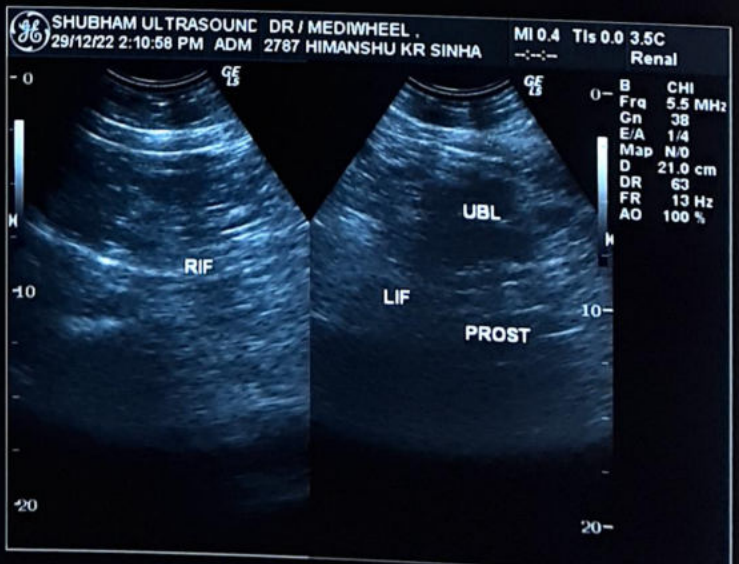
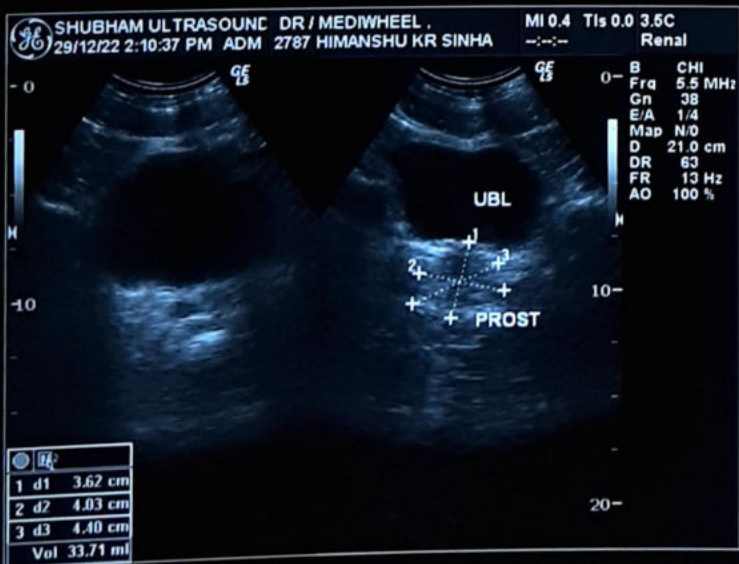
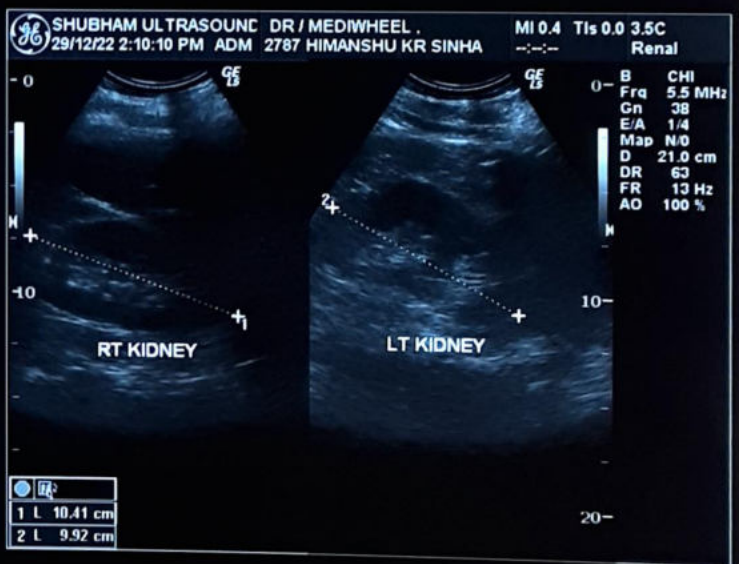
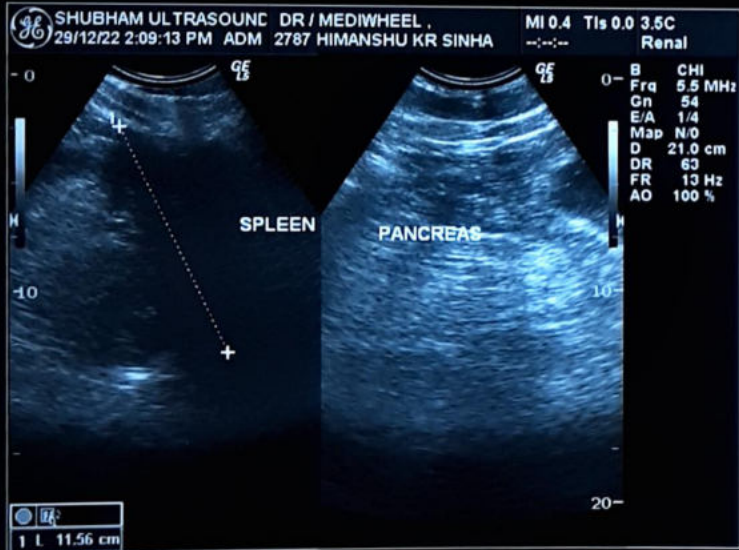
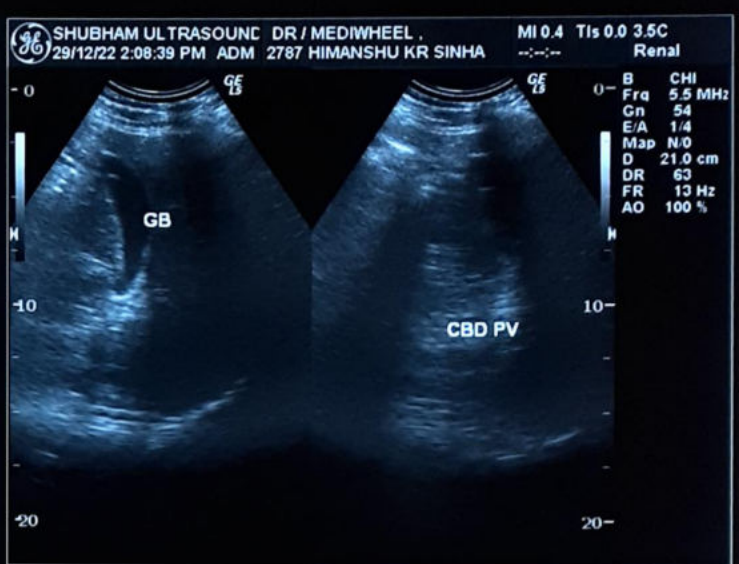
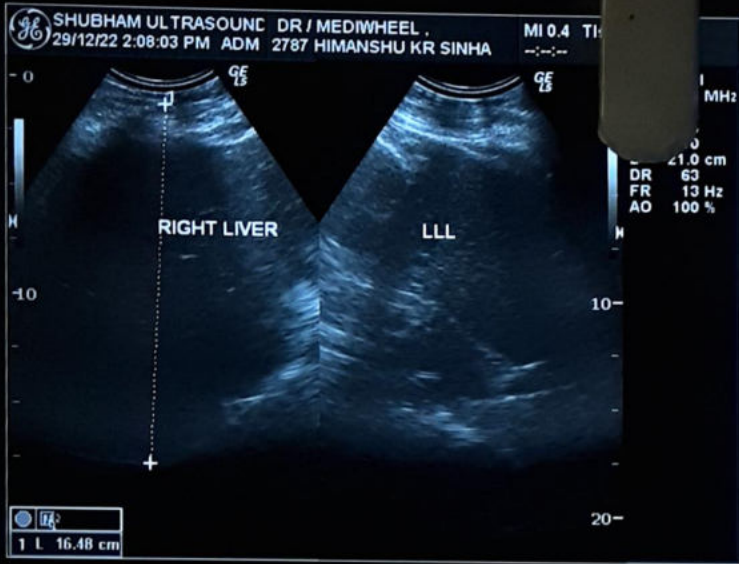
Dr. S. Kumar
MD (Pat)
Consultant Pathologist

Dr. Abhishek Kumar
MBBS, MD
Consultant Neuropatho Physiologist

Dr. Kumari Suman
MBBS, DGO, MD
Consultant (TVS & HSG Specialist)

Dr. A. K. Singh
MBBS, PGDMCH
Consultant Radiologist & Sonologist

PRINTING MISTAKE SHOULD BE REPORTED BACK IMMEDIATELY/ यहाँ जन्म से पहले भ्रुण का लिंग जाँच नहीं होता है ।





A.L.C. Advance Imaging Diagnostics

ISO 9001:2015 Certified center

(A Unit of Subham Imaging P.K. Arogyam Health & Wellness Center)

E-95, P.C. Colony, Near Sai Netryalaya Transformer, Kankarbagh, Patna - 20

alcdiagnostics@gmail.com

www.pkarogayamhealthcheckup.com

7050037694 8271206196

OPINION MUST BE CORRELATES WITH CLINICALLY & OTHER INVESTIGATION FOR FINAL DIAGNOSIS. NOT FOR MEDICO LEGAL PURPOSE

Pt. Name :- HIMANSHU KUMAR SINHA

Date:- 29-Dec-22

Ref. By :- DR . /MEDIWHEEL

Age / Sex - 40 Yrs. M.

REAL TIME U.S.G. OF WHOLE ABDOMEN

Thanks for your kind referral

(Report.)

LIVER :- Measures 16.48 cm. Mild Enlarged in shape , size and echo texture fatty change seen in liver parenchyma .I.H.B.R. are not dilated.

Hepatic veins are normal. No SOL seen.

G.BL. :- Lumen is echo free. Wall thickness appears normal.

C.B.D. :- Measures 3.5 mm in diameter with echo free lumen. No calculi or mass seen.

P.V. :- Measures 7.7 mm in diameter. Appears normal. No thrombus seen.

PANCREAS :- Normal in shape, size and echo texture. No calcification mass seen.

SPLEEN :- Measures 11.56 cm. Normal in shape, size and echo texture.
No SOL seen.

KIDNEY :- Both kidney shows normal shape, size & echotexture. C.M.D.intact.
P.C.S.is not dilated.

Right Kidney :- Measures 10.51 X 4.50 cm.

Left Kidney :- Measures 9.92 X 3.50 cm.

URETER :- Not dilated .No apparent calculi seen.

U.BLADDER:- Shows normal in outline with echo free lumen. No calculi or mass seen.

Pre void - 320 ml. Post void -40 is in significant

PROSTATE :- Measures 33 gms.(approx). Mild Enlarged in size, shape, and echo texture.

No calcification , mass ,growth seen. capsule is intact.

R.I.F. :- Son graphically no appendicular mass or collection seen.

OTHERS :- No Ascites . no Lymph Adenopathy. No pleural effusion seen on either side .

IMPRESSION

- Mild Hepatomegaly With fatty liver G-I
- Mild Enlarged Prostate (BPH) Grade I with 40 ml PVR
- Adv:- Further work up other investigation

Otherwise son graphically normal scan. of rest organs

1
29/12/22

ESTB BY:-

Consultant Radiologist

Dr. P. K. Tiwari
MD, M.Sc (Radio Imaging)
Ph.D (Al) Nuclear Medicine
Consultant Imacionologist & Sonologist

Dr. S. Kumar
MD (Pat)
Consultant Pathologist

Dr. Abhishek Kumar
MBBS, MD
Consultant Neuropatho Physiologist

Dr. Kumari Suman
MBBS, DGO, MD
Consultant (TVS & HSG Specialist)

Dr. A. K. Singh
MBBS, PGDMCH
Consultant Radiologist & Sonologist

PRINTING MISTAKE SHOULD BE REPORTED BACK IMMEDIATELY/ यहाँ जन्म से पहले भ्रुण का लिंग जाँच नहीं होता है ।