

LETTER OF APPROVAL / RECOMMENDATION

To,

The Coordinator,
Mediwheel (Arcofemi Healthcare Limited)
Helpline number: 011- 41195959

Dear Sir / Madam,

Sub: Annual Health Checkup for the employees of Bank of Baroda

This is to inform you that the following employee wishes to avail the facility of Cashless Annual Health Checkup provided by you in terms of our agreement.

PARTICULARS	EMPLOYEE DETAILS
NAME	MR. SARKAR RAJENDRA KUMAR
EC NO.	156198
DESIGNATION	BRANCH OPERATIONS
PLACE OF WORK	KOLKATA, SERVICE BRANCH
BIRTHDATE	10-02-1965
PROPOSED DATE OF HEALTH CHECKUP	31-01-2022
BOOKING REFERENCE NO.	21M156198100010180E

This letter of approval / recommendation is valid if submitted along with copy of the Bank of Baroda employee id card. This approval is valid from **28-01-2022** till **31-03-2022**. The list of medical tests to be conducted is provided in the annexure to this letter. Please note that the said health checkup is a **cashless facility** as per our tie up arrangement. We request you to attend to the health checkup requirement of our employee and accord your top priority and best resources in this regard. The EC Number and the booking reference number as given in the above table shall be mentioned in the invoice, invariably.

We solicit your co-operation in this regard.

Yours faithfully,

Sd/-

Chief General Manager
HRM Department
Bank of Baroda

(Note: This is a computer generated letter. No Signature required. For any clarification, please contact Mediwheel (Arcofemi Healthcare Limited))

Rajendra Kumar Sarkar



सत्यमेव जयते
Hindustan Sarkar



आधार

भारतीय विशिष्ट परिचय प्राधिकरण

भारत सरकार

Unique Identification Authority of India
Government of India

তালিকাভুক্তির আই ডি / Enrollment No.: 1062/11011/01308

To
রাজেন্দ্র কুমার সরকার
Rajendra Kumar Sarkar
S/O: Mahendra Nath Sarkar
2/13 WEST RABINDRA NAGAR
South Dumdum(m)
Rabindra Nagar
North 24 Paraganas North 24 Parganas
West Bengal 700065
9851335692

03/07/2015

269829218



MP698292182FT



আপনার আধার সংখ্যা / Your Aadhaar No. :

9226 0180 9618

আধার - সাধারণ মানুষের অধিকার



ভারত সরকার
Government of India



রাজেন্দ্র কুমার সরকার
Rajendra Kumar Sarkar
জন্মতারিখ / DOB : 10/02/1965
পুরুষ / Male



9226 0180 9618

আধার - সাধারণ মানুষের অধিকার

Rajendra Sarkar

9226 0180 9618

Address: S/O: Mahendra Nath Sarkar, 2/13, WEST RABINDRA NAGAR, South Dumdum(m), North 24 Parganas, Rabindra Nagar, West Bengal, 700065

Unique Identification Authority of India



■ Aadhaar will be helpful in availing Government and Non-Government services in future .

■ Aadhaar is valid throughout the country .

■ আধার সার্বভৌম এবং সরকারী পরিষেবা গ্রহণে সহায়ক হবে।

■ আধার সারা দেশে প্রযোজ্য।

- To establish identity, authenticate online .
- Aadhaar is proof of identity, not of citizenship .

INFORMATION

- আধার পরিচয়ের প্রমাণ, নাগরিকত্বের প্রমাণ নয়।
- পরিচয়ের প্রমাণ ত্রুটিহীন প্রমাণিতকরণে সহায়ক হবে।

তথ্য



Government of India





नाम

Name : SARKAR RAJENDRA KUMAR

कर्मचारी कूट. क्र.

E. C. No. 156198

कार्यकर्ता प्राधिकारी

भारत के हस्ताक्षर

Rajendra Kumar

K.Z.

ભાગીદારી અને સહાયકોના નામો
અથવા સંબંધિત (જોઈએ) : કે સહાયકો, સહાયકો અને
ધી - 26, સુભાષી, સુભાષી સ્ટેડિયમ, સુભાષી (સુભાષી), સુભાષી 400 051, સુભાષી
સુભાષી: 91 22 6698 5196, ફેક્સ: 91 22 2652 5747
if Found, Please return to:
Asst. General Manager (Security) Bank of Baroda, Baroda Cantonment Centre
C-26, S. Subhashi, Subhashi Stadium, Mumbai 400 051, India
Phone: 91 22 6698 5196 Fax: 91 22 2652 5747
સહાયકો અને સહાયકોના નામો સંબંધિત : 8013787814
Name & Ph./Person of emergency contact: 8013787814

સહાયકો/Blood Group AB+

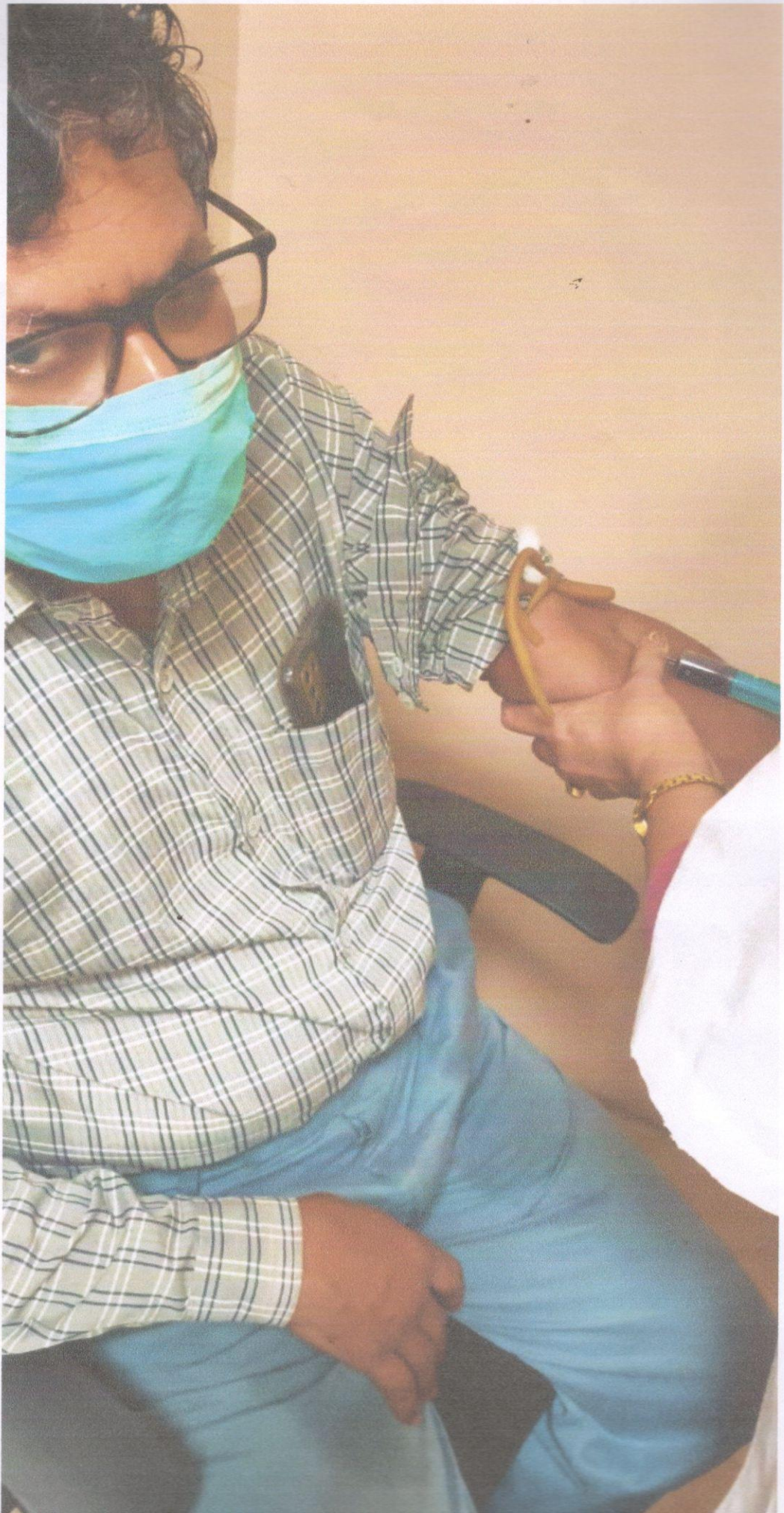સહાયકો/Allergy NIL

સહાયકો/Identification mark

સહાયકો/issuing office

BOB, KOLKATA ZONE, Plot No 38/2, Block - GN, Sector-V, Salt Lake City, Kolkata - 700091





DEPARTMENT OF RADIOLOGY X-RAY OF CHEST (PA) VIEW

MR. NO- FSIN.0000000

SEX-MALE

NAME: -RAJENDRA KUMAR SARKAR

EXAMINATION DATE-04/02/2022

AGE-57 YRS


REPORT DATE-04/02/2022

REF DR:- SELF

FINDINGS:

- Bilateral accentuated pulmonary vascular marking noted.
- Both hilum appear normal.
- CTR within normal limit.
- Tracheal shadow is in the midline.
- Bilateral CP angle are clear
- No definite bone fracture is noted.

Impression:- Bilateral pulmonary vascular congestion.


DR.ARNAB MANDAL

MD, Physician, PGDUS (Delhi) CEPT-USG (WBUHS KOLKATA)
Fellow of Jefferson Ultrasound Radiology and Education Institute
Philadelphia Ex-Radiology Resident (S.E.Railway)
Regd.No:72022(WBMC)



NAME:MR.RAJENDRA KR SARKAR	MR. NO: FSIN-0000	DATE: 04/02/2022
AGE :57YRS	SEX:MALE	REF. BY: SELF

ULTRASOUND OF WHOLE ABDOMEN

LIVER: Liver is **Enlarged fatty infiltration** in size(**17.59cm**) shape, outline and echotexture. The intrahepatic tubular structures are normal. Enlarged liver with increased echogenicity is noted. The porta hepatis is normal. The common bile duct measures **4mm** in diameter. The portal vein measures **10mm** at porta.

GALLBLADDER: Gall bladder is partially distended. Wall is normal. No calculus or mass is seen within the gall bladder.

PANCREAS: It is normal in size, Shape, Outline and echotexture. Pancreatic duct is not dilated.

SPLEEN: It is normal in size **9.42cm**, Shape, Outline and echotexture. No parenchymal lesion is noted.

BOTH KIDNEYS: Both kidneys are normal in position, size, shape, outline and echotexture. The cortico medullary differentiation is maintained. No calculus or hydronephrosis is seen.


RIGHT KIDNEY measures **10.05cm**.
LEFT KIDNEY measures **11.49cm**.

URINARY BLADDER: It is well distended with normal wall thickness. No calculus or mass is seen within the urinary bladder.

PROSTATE: It is **enlarge** in size, shape & homogenous echotexture. The prostatic outline is smooth. The periprostatic plane is normal. It is normal in size measures **4.89cmX3.65cmX3.36cm** **VOL=31.45gms**

IMPRESSION:

- HEPATOMEGALY .
- ENLARGED FATTY INFILTRATION.
- ENLARGE PROSTATE.



A.K.ROY

M.B.B.S, Dip BMSc, DTM&H (Cal)

Certificate on CEBT Abdomino Pelvic, USG(WBHSU)



Patient Name: Mr. RAJENDRA KR SARKAR 57/M

Resting ECG Report

February 04, 2022

QT / QTc : 0.166 / 0.184 Sec

PR Interval: 0.14 sec

RR Interval: 0.71 sec

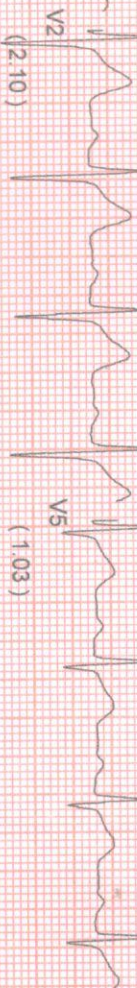
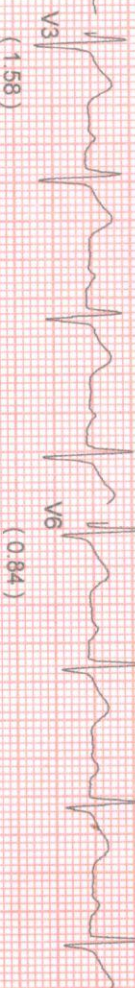
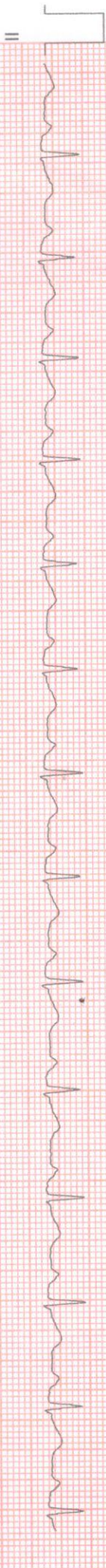
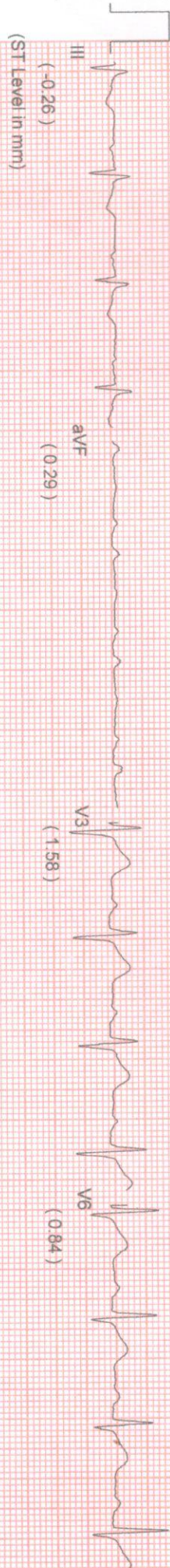
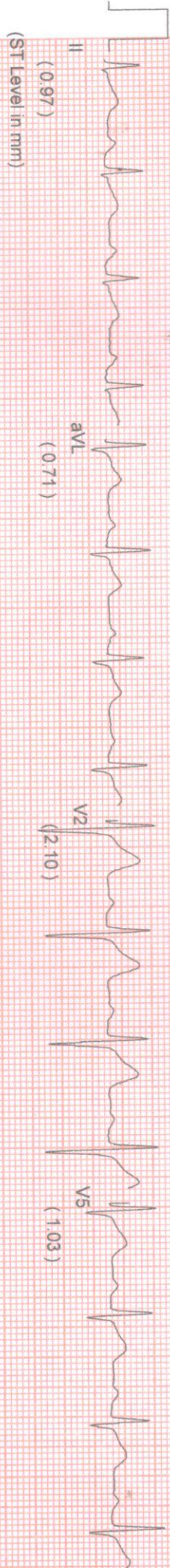
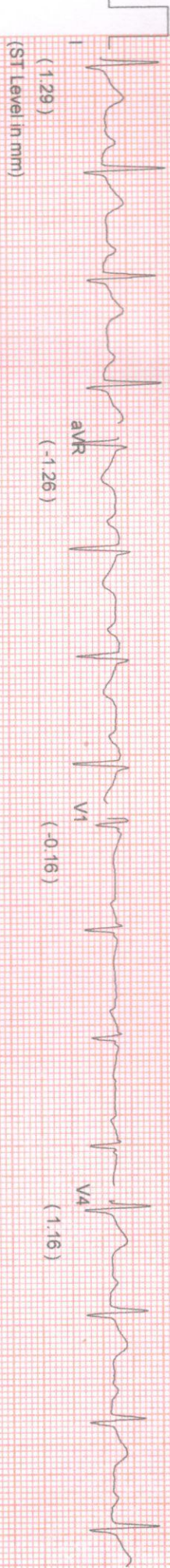
HR : 84 bpm

BP : 120 / 70 mmHg

Time: 14.13.35

P-QRS-T Axis (20)-(0)-(33) deg

QRS Duration : 0.064 Sec



Comments :-

Rajendra Kr Sarkar

NAME: MR.RAJENDRA KR SARKAR	MR NO: FSIN-0000	DATE : 04.02.2022
AGE: 57YRS.	SEX:MALE	REF BY: SELF(CORPORATE)

ECG REPORT

HR : 84 b/min
AXIS : NORMAL
RHYTHM : SINUS
PR INTERVAL : 0.14 sec
QT INTERVAL : 0.184 sec
QRS DURATION : 0.064 sec
T-WAVE : NORMAL.

IMPRESSION:

- RESTING ECG IS WITHIN NORMAL LIMITS.


Dr. SIDDHARTHA KUNDU
MBBS (Cal), PGDCC, CCEBDM
Clinical Cardiologist
Ex Sr Resident, Cardiology Dept
B.R Singh Hospital, Eastern Railway



DR. ABHIRUP MUKHERJEE

BDS (WBUHS)
Oral & Dental Surgeon
Regn.No. 3726 Part A (Wbdc)

TO WHOM IT MAY CONCERN

THIS IS TO CERTIFY THAT **MR. RAJENDRA KUMAR SARKAR**, 57Y/MALE,
HAS NO ORAL PROBLEM.

THERE IS NO CAVITY AND BAD SMELL OBSERVED IN HIS MOUTH.

DATE: 8/12/22

A. Mukherjee
SIGNATURE
DC STAMP

APOLLO CLINIC OM TOWER
36C, B.T ROAD OPP "RBU"
KOL 700002
Ph 033 25565555
033 25563333

DR. ABHIRUP MUKHERJEE
BDS (WBUHS)
Oral & Dental Surgeon
Regn. No. 3726 Part A (WBDC)

DR. BOUDHAYAN BHATTACHARJEE
MBBS. (MEDICAL COLLEGE, KOLKATA) MD (TROPICAL MEDICINE)
CONSULTANT PHYSICIAN & INTENSIVIST

APOLLO CLINIC @ OM TOWER
Opp. of Rabindra Bharati University

TO WHOM IT MAY CONCERN

THIS IS TO CERTIFY THAT, MR. RAJENDRA KUMAR SARKAR,
AGE- 57Y/MALE, IS PHYSICALLY FIT.

DATE: 8.2.22.....

APOLLO CLINIC OM TOWER
36C, B.T ROAD OPP "RBU"
KOL 700002
Ph 033 25565555
033 25563333

Boudhayan Bhattacharyee

SIGNATURE

STAMP

Dr. BOUDHAYAN BHATTACHARJEE
MBBS, MD (TROPICAL MEDICINE)
65631 of WBMC



DR. RAKTIMA BAKSHI MANDAL

CONSULTANT EYE SURGEON
& OPHTHALMOLOGIST

TO WHOM IT MAY CONCERN

THIS IS TO CERTIFY THAT MR. RAJENDRA KUMAR SARKAR,
AGE- 57Y/MALE.

HE IS WITH CLEAR VISION, WITH NO COLOR BLINDNESS.

RIGHT EYE	NORMAL
LEFT EYE	NORMAL

DATE: 8/2/22

APOLLO CLINIC @ OM TOWER
36C, B.T. ROAD OPP "RBU"
KOL 700002
Ph 033 25565555
033 25563333

R.B. Mandal

SIGNATURE

DC STAMP

DR. RAKTIMA BAKSHI MANDAL
M.B.B.S., M.S. (OPHTHALMOLOGY)
Regn. No. 69521 of WBMC
Consultant Eye Surgeon



DR. SOURADEEP RAY

MBBS, MS (ENT)
ASSOCIATE PROFESSOR R.G. KAR MEDICAL, KOLKATA.
REGD.NO. 63999 (WBMC)

TO WHOM IT MAY CONCERN

THIS IS TO CERTIFY THAT
MR. RAJENDRA KUMAR SARKAR, AGE-57Y/MALE,
HAS NO PROBLEM IN HIS EAR, NOSE AND THROAT.

HIS EAR IS CLEAN, NO HEARING PROBLEM OBSERVED,
NASAL PASAGE IS CLEAR, WITH PROPER SMELLING CAPACITY,
THROAT IS CLEAR, NO INFECTION FOUND IN TONSILS.

DATE: 08-02-22

Souradeep Ray
.....

SIGNATURE
DC STAMP

APOLLO CLINIC OM TOWER
36C, B.T ROAD OPP "RBU"
KOL 700002
Ph 033 25565555
033 25563333