

mediwhee |


"DR. PLUS HEALTHCARE CENTRE"
NATHANI HEIGHTS', B-WING,
42, MUMBAI CENTRAL (EAST)

R
DR. HARI CHHABLANI
M.B.B.S;FC C.P.(RESP.MEDICINE) PGDMM, PGDMLS
FELLOW INTENSIVE CARE
MMC REG. NO. - 91702

Abhi

(33/4)

भारत सरकार
GOVERNMENT OF INDIA



गरिमा दीप्ती
Garima Dipti
जन्म तिथि / DOB: 17/09/1988
लिंग / GENDER: FEMALE
Mobile No.: 8291745557
8302 8528 9756
VID - 0135 0093 9005 1254

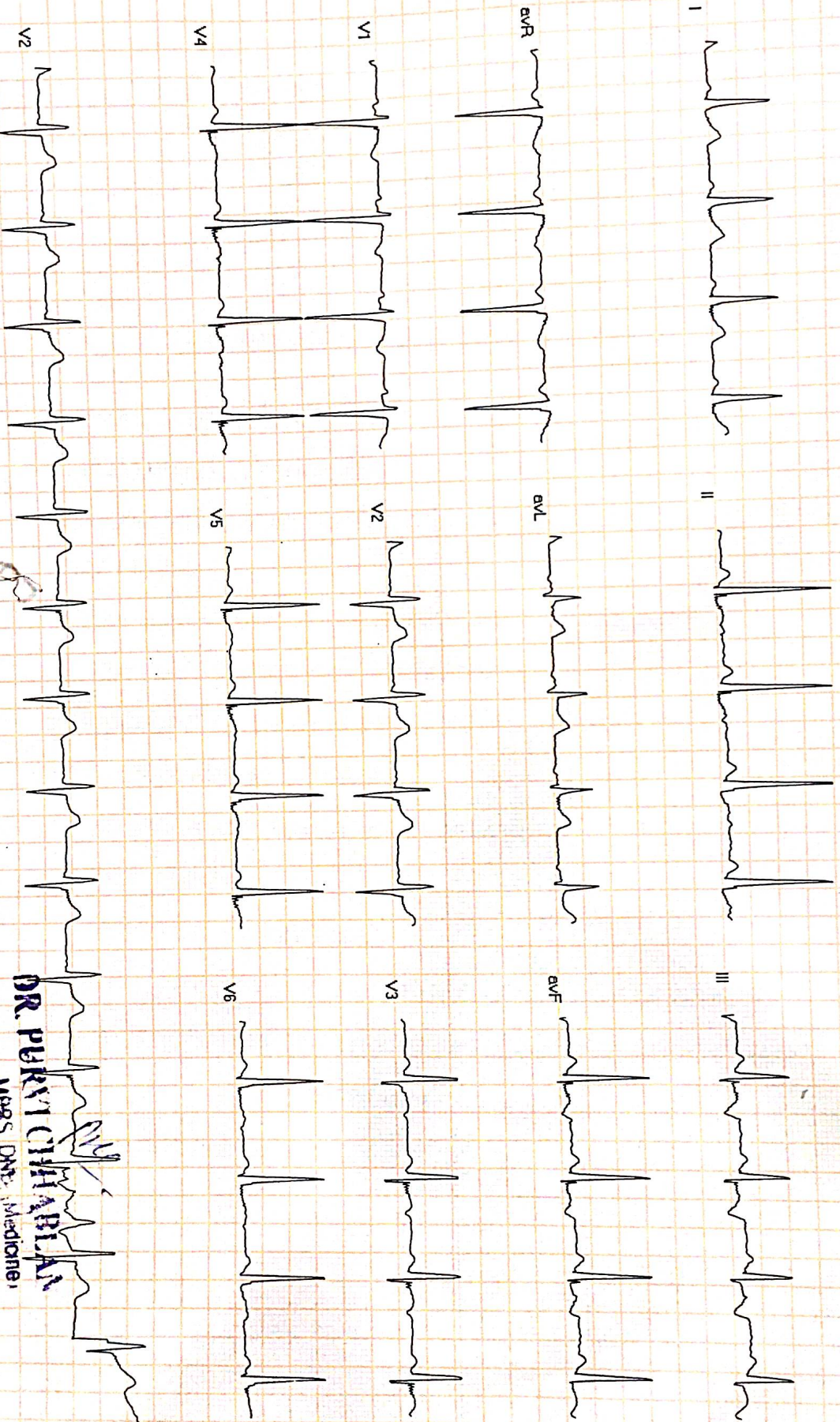
मेरा आधार, मेरी पहचान

ECG

DR PLUS HEALTHCARE CENTRE- MUMBAI CENTRAL

1693 / GARIMA DPTI / 33 Yrs / F

Heart Rate : 88 bpm / Tested On : 26-Mar-22 13:15:21 / HF 0.05 Hz - LF 100 Hz / Notch 50 Hz / Sn 1.00 Cm/mV / Sw 25 mm/s
/ Ref'd By: DR. HARI CHHABLANI



DR. PURVI CHHABLANI
MBBS DNB (Medicine)
Consultant Physician And Internist
Reg. No. 77899F
Reported By: DR. HARI CHHABLANI



NAME : GARIMA DIPTI

33/F

DATE:26/03/2022

REF BY : DR. HARI CHHABLANI

2D-ECHO. AND COLOR DOPPLER REPORT

- NORMAL CARDIAC VALVES WITH TRIVIAL TR.
- NORMAL CARDIAC CHAMBERS
- NO E/O REGIONAL WALL MOTION ABNORMALITY. WITH NORMAL LVEF OF 62 %.
- NO E/O PULMONARY HYPERTENSION .PASP 34 mmHg by TR jet.
- NO E/O LEFT VENTRICULAR HYPERTROPHY.
- NO E/O DIASTOLIC DYSFUNCTION.
- NO E/O PERICARDIAL EFFUSION.
- NO E/O INTRACARDIAC CLOT OR VEGETATION
- INTACT IAS / IVS

- CONVENTIONL DOPPLER :

E TO A RATIO IS MORE THAN ONE IN LV INFLOW.


THERE IS NO GRADIENT ACROSS AV,LVOT OR RVOT

PASP FROM TR JET IS 34 mm OF Hg.

- COLOUR DOPPLER:

TRIVIAL TR

EF Slope	86	mm/sec		
Opening Amplitude	21			
Posterior leaflet				
E.P.S.S	02	mm		
Mitral valve prolapse				
Vegetations				
TRICUSPID VALVE	OBSERVED	NORMAL VALUES		
PULMONARY VALVE	OBSERVED	NORMAL VALUES		
EF Slope				
'A' Wave				
Midsystolic notch				
Flutter				
Other Findings				
AORTIC VALVE	OBSERVED	NORMAL VALUES		
Cuspal opening	15	mm		
Close line	Central			
Eccentricity index	1			
Other Findings				
DIMENSIONS	OBSERVED	NORMAL VALUES		
1. Lvd (Diastolic)	42	26-52		
2. Lvd (Systolic)	29	24-42mm		
3. RVD (Diastolic)	19	7-23mm		
4. IVST (Diastolic)	08	6-11mm		
5. IVST (Systolic)	15			
6. LVPWT (Diastolic)	09	6-11mm		
7. LVPWT (Systolic)	14			
8. Aortic root	33	22-37mm		
9. left Atrium	24	19-40mm		
	STRUCTURE	REGURG GRADING	VELOCITY m/sec	STENOSIS GRADIENT mm/Hg
			Max mean	Peak mean
MITRAL VALVE	NORMAL	0/3	/	/
TRICUSPID VELVE	NORMAL	TRIVIAL	/	/
PULMONARY VELVE	NORMAL	0/4	/	/
AORTIV VALVE	NORMAL	0/4	/	/


DR.P.H.CHHABLANI
 M.B.B.S, DNB.(MEDICINE)
 CONSULTANT PHYSICIAN AND CARDIOLOGIST.

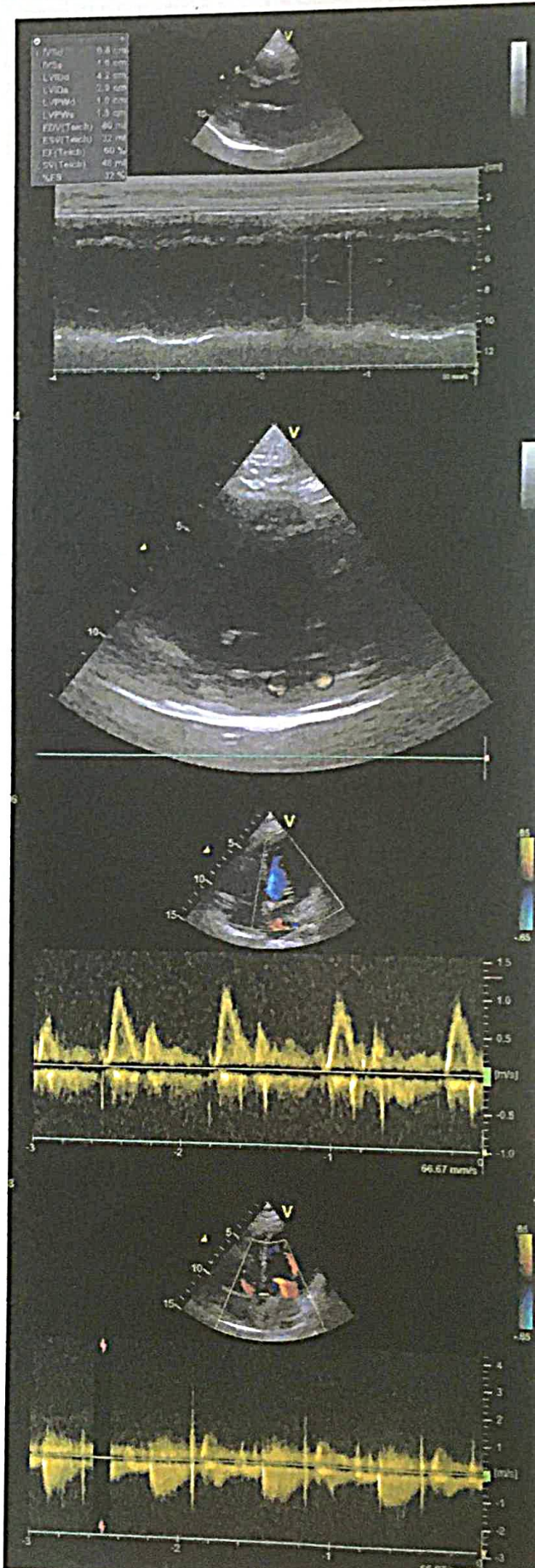
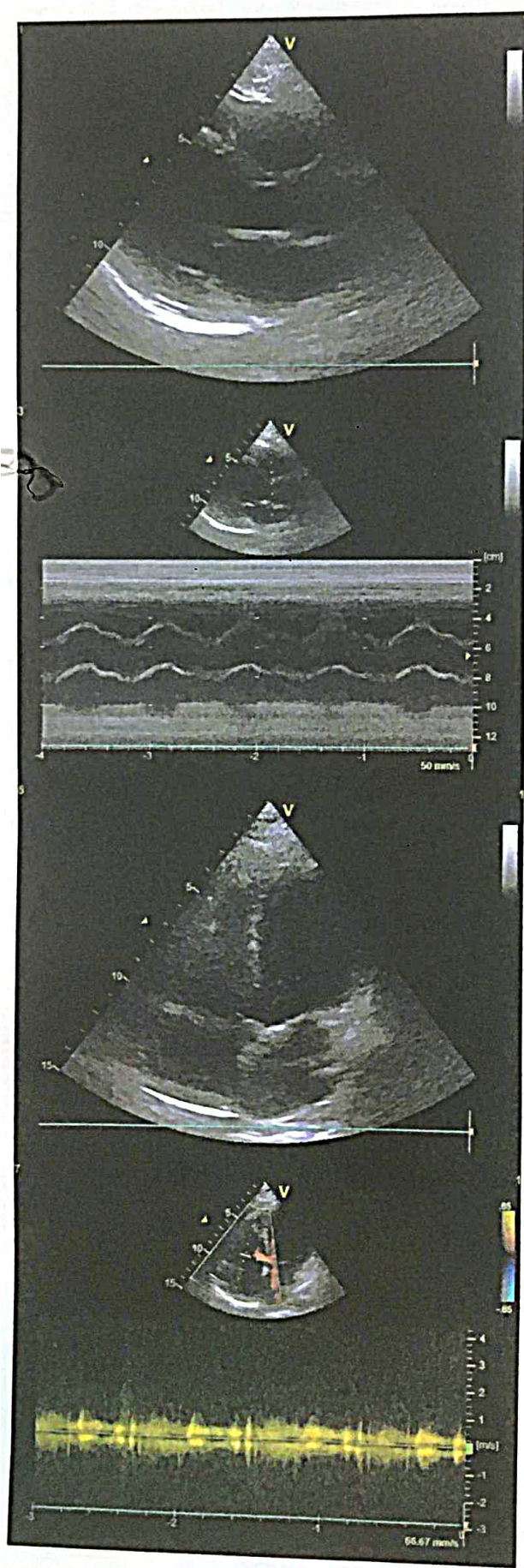
DR. PURVI CHHABLANI
 MBBS DNB- (Medicine)
 Consultant Physician And Intensivist

Name **GARIMA DIPTI**

Age **33**

Sex **Female**

Date **26/03/2022**





Dr-Plus Healthcare Centre

NATHANI HEIGHTS, B-Wing, Shop No. 42, Ground Floor, Opp. Mumbai Central Station (East), Mumbai - 400 008.

Patient Name	: GARIMA DIPTI	Sex:	Female
Doctor's Name	: SELF	Age:	33 Years
Date	: 26/03/2022		

ULTRASONOGRAPHY OF THE ABDOMEN AND THE PELVIS:

The relevant sonographic findings include the following:

HEPATOBIILIARY APPARATUS

The liver is normal in size and echogenicity. No obvious focal parenchymal lesion is seen. Intrahepatic biliary radicals are not dilated.

The portal vein and the common bile duct are normal.

GALL BLADDER

The gall bladder is adequately distended. The wall thickness is normal.

No echogenic contents are noted in its lumen. There is no pericholecystic collection noted.

PANCREAS

The pancreas shows normal echogenicity and size.

No focal or diffuse lesions are noted. No evidence of calcification is noted.

SPLEEN

The spleen appears normal in size and echogenicity.

No focal or diffuse lesions are noted. No evidence of calcification is noted.

KIDNEYS

Right kidney measures : 9.9 x 5.1 cm , Left kidney measures : 10.2 x 4.4 cm.

Both the kidneys appear normal in size, shape and echogenicity. Both the pelvicalyceal system is normal and both corticomedullary differentiations are well maintained. There is no obvious focal or diffuse lesion noted.

No evidence of any calculus seen in either kidney.

URINARY BLADDER

The urinary bladder shows anechoic contents. Its wall thickness appears normal.

UTERUS

The uterus is normal in size , shape and position .

A posterior wall fibroid(2.8 x 2.6 x 2.7cm) . it is causing significant mass effect on the endometrium . and it appears hypervascular .

The uterus measures 7.8 x 4.5 x 5.7cm.

The cervix appears normal .

OVARIES

Both ovaries are bulky in size. Two to three chocolate cysts

A follicular and a hemorrhagic cyst seen in the left ovary .

Right ovary measures : 4.5 x 3.0 x 2.9 cm Volume = 18 cc

Left ovary measures : 4.3 x 2.57 x 2.83 cm Volume = 13 cc

No other obvious pelvic mass is seen. No probe-tenderness is noted.

IMPRESSION:INTRAMURAL FIBROID PRESENT .

RIGHT OVARY CHOCOLATE CYSTS PRESENT .

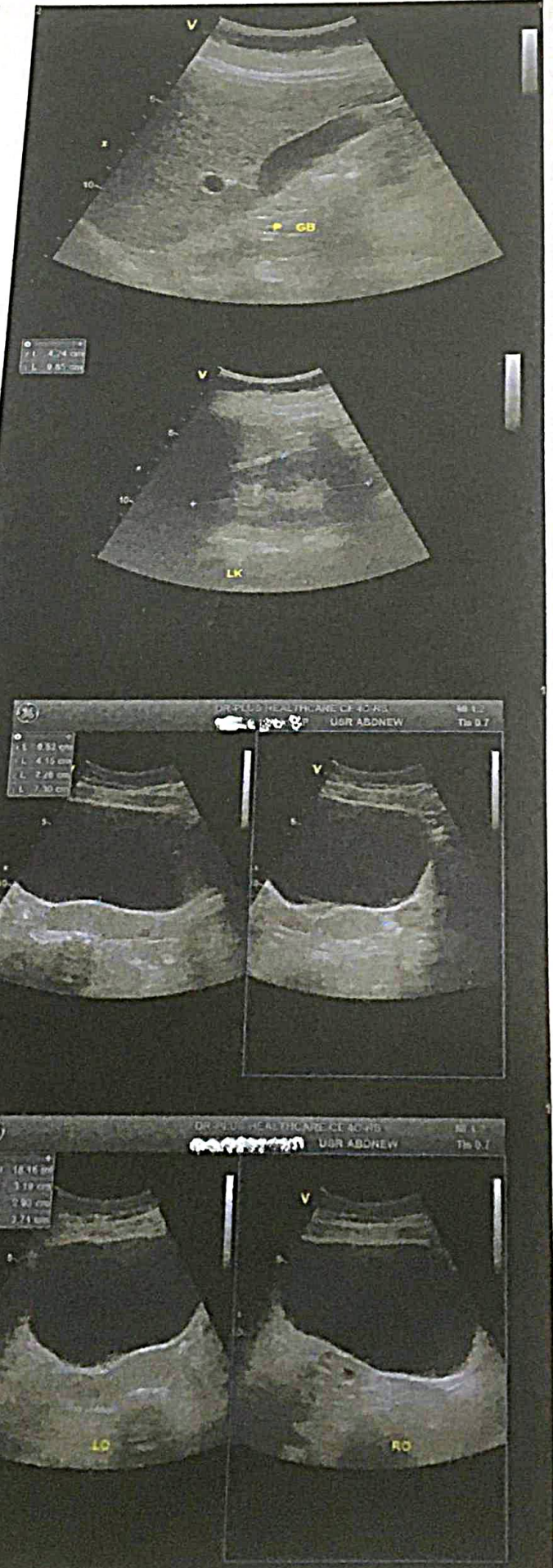
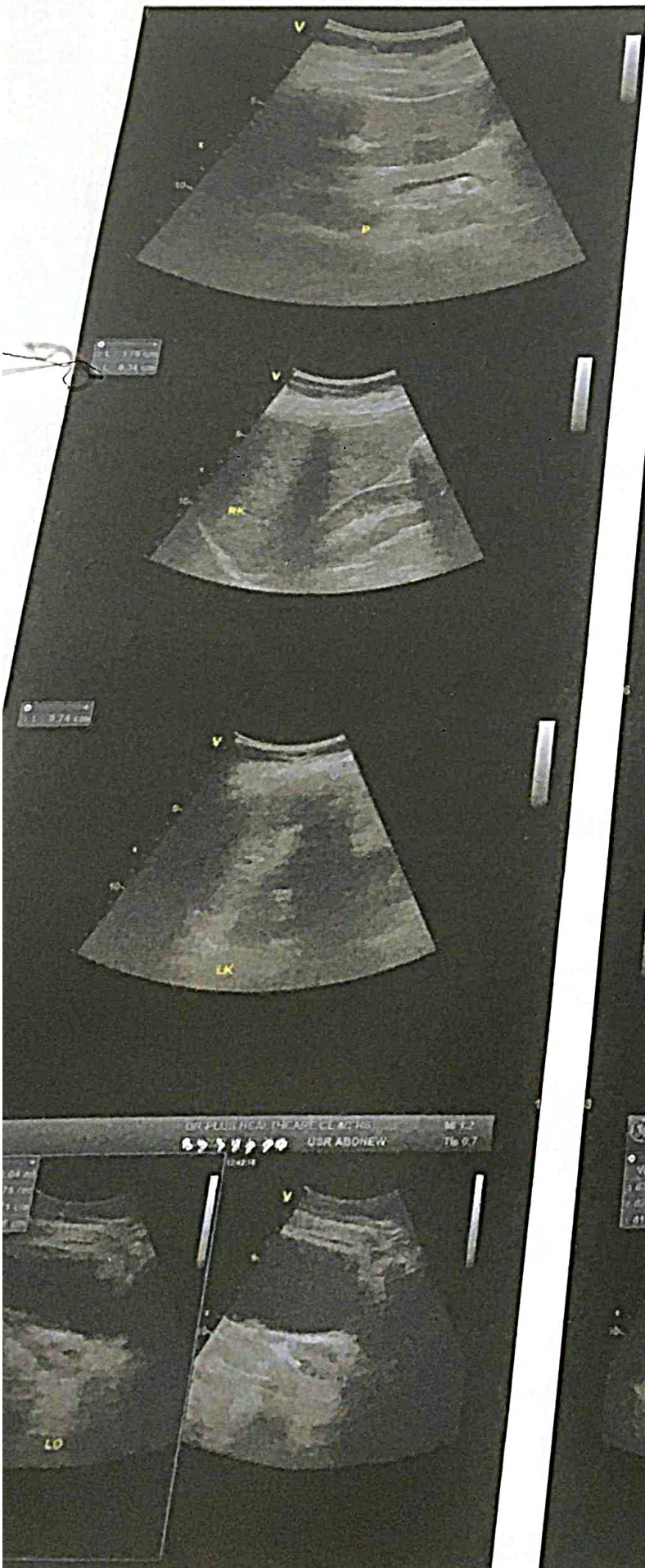
Dr. Harag Jhaveri
MBBS (BOM), DMRE(BOM)
Radio-Sonologist

**DR. PLUS HEALTHCARE CENTRE'S
NATHANI HEIGHTS', B-WING,
42, MUMBAI CENTRAL (EAST)**

Name **GARIMA DIPTI**

Sex **Female**

Age **33**





Dr-Plus Healthcare Centre

NATHANI HEIGHTS, B-Wing, Shop No. 42, Ground Floor, Opp. Mumbai Central Station (East), Mumbai - 400 008.

Patient's Name : GARIMA DIPTI

Referred By Dr. : SELF

Report : 26/03/2022


Age : 33 Years

Sex : FEMALE

Chest X-ray PA

No active pulmonary lesion seen.

- Trachea and mediastinum are in midline .
- Cardiac size and configuration are within normal limits .
- Pleural cavities are clear .
- Domes of diaphragm are smooth in outline.
- Bony thorax is normal .


- Radiologist

DR. A. J. MAZUMDAR

MD. DMRE, MDRD

DR. PLUS HEALTHCARE CENTRE
NATHANI HEIGHTS, B-WING,
42, MUMBAI CENTRAL (EAST)

Patient's Name : GARIMA DIPTI

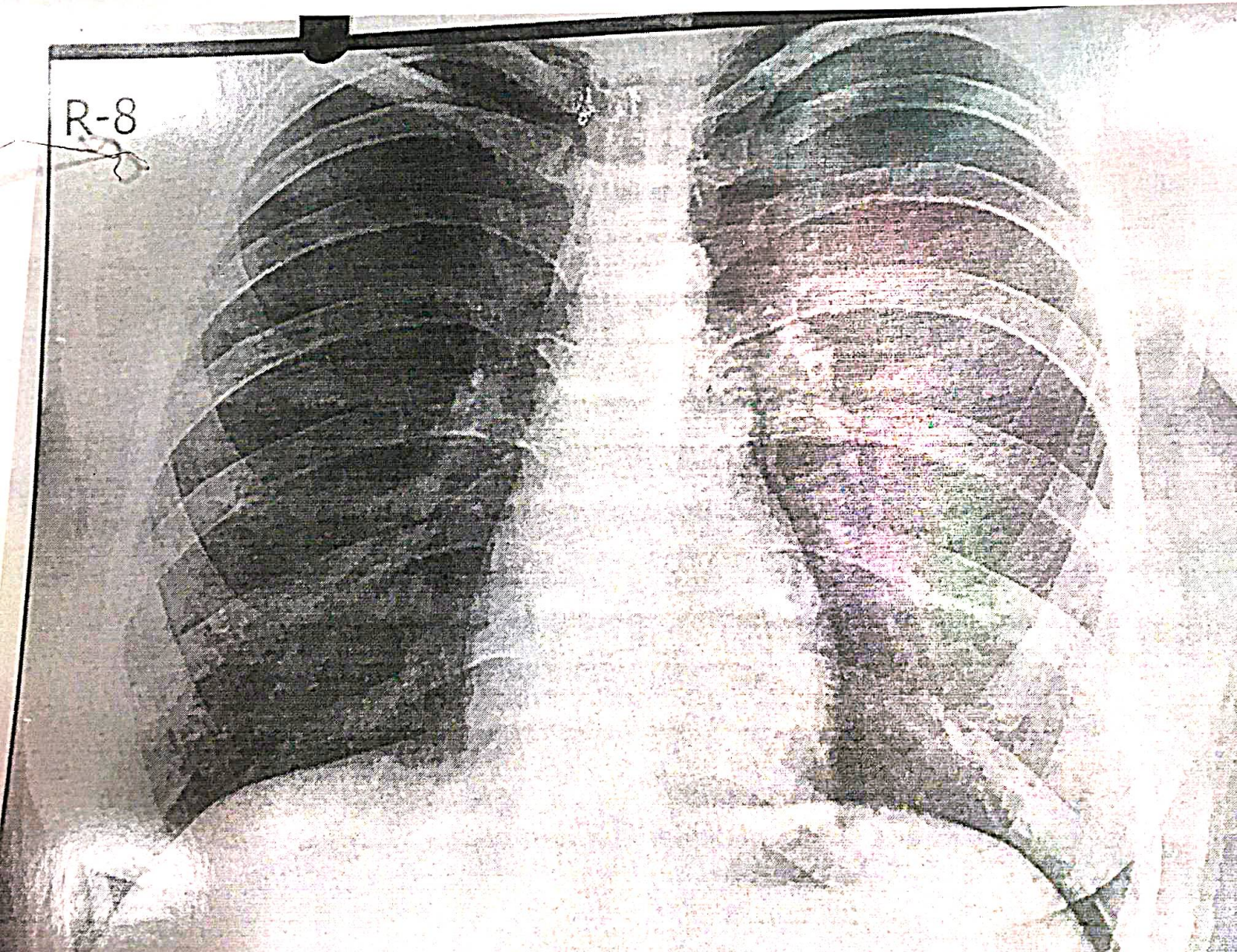
Report : 26/03/2022

Referred By Dr. : SELF

Age : 33 Years

Sex : FEMALE

R-8





Dr-Plus Healthcare Centre

NATHANI HEIGHTS, B-Wing, Shop No. 42, Ground Floor, Opp. Mumbai Central Station (East), Mumbai - 400 008.

Full Name

GARIMA DIPTI

33/F

26/03/2022

Life to be assured:

	Type of Test	Actual Reading	Normal Range
1	Fasting Blood Sugar	91.4	70-100 mg%
2	PPBS	121.8	110 TO 140 mg%
3	Total Cholesterol	185	120-200 mg%
4	VERY LOW DENSINTY LEVEL(VLDL)	20	10-30 mg/dl
5	High Density Lipid (HDL)	55	40-60 mg%
6	Low Density Lipid (LDL)	110	Upto 150
7	S. Triglycerides	111.5	50-150 mg%
8	CHOL/HDL	3.3	Upto 5
9	HDL/LDL	0.5	
10	S. Creatinine	0.8	0.5-1.2 mg%
11	Blood Urea Nitrogen (BUN)	20.1	7-21 mg%
12	BUN/CREAT RATIO	25.1	
13	S. Proteins	7.2	6.0-7.9 mg%
14	(a) Albumin	4.1	3.5-5.5 mg%
15	(b) Globulin	3.1	2.0-3.5 mg%
16	A/G RATIO	1.3	
17	S. Bilirubin	0.8	0.3-1.3mg%
18	(a) Direct	0.5	0.0-0.8 mg%
19	(b) Indirect	0.3	0.0-0.5 mg%
20	SGOT (AST)	24	05-34 IU
21	SGPT (ALT)	35	05-40 IU
22	GGTP (GGT)	37.4	05-50 IU
23	SGOT/SGPT	0.68	
24	HBA1C	5.32	UPTO 6.5
25	S. Alkaline Phosphatase	95	30-115 IU
26	T3	124.5	80-180ng/dl
27	T4	6.74	4.6-12 ug/dl
28	TSH	3.21	0.4-4.0 mIU/L
29	SERUM URIC ACID	5.51	2.5-7.2mg/dl
30	URINE SUGAR PP	ABSENT	
31	URINE SUGAR FASTING	ABSENT	
32	BLOOD GROUP	" AB " NEGATIVE	

DR. RAKESH PATKAR
M.D., D.N.B. (Pathology)
Reg. No. 2013/05/1660



Dr-Plus Healthcare Centre

NATHANI HEIGHTS, B-Wing, Shop No. 42, Ground Floor, Opp. Mumbai Central Station (East), Mumbai - 400 008.

Full Name
Life to be assured:

GARIMA DIPTI

33/F

26/03/2022

HAEMOGRAM

Normal Range

1.	Red Blood Cell Count	3.5	[M : 4.5 - 5.6 / F : 3.5 - 5.5/cu.mm]
2.	Hb%	11.0	[M: 14-18 / F : 11-16%]
3.	Hematocrit	45.4	[M : 40-53 / F : 30-47 %]
4.	Indices:		
(a)	MCV(Mean Corpuscular Volume)	87.64	[79-101 cu.mi.]
(b)	MCH(Mean Corpuscular Hb)	30.3	[27-32 pg]
(c)	MCHC(Mean Corpuscular Hb Concentration)	29.3	[32-38%]
5.	Morphology		
	Macrocytes :	--	Microcytes: -- Hypochromia: --
	Poikilocytosis:	--	Anisocytosis: --
6.	Target cells:	--	
	Spherocytes:	--	Elliptocytes: --
7.	TOTALW.B.C.Count	6,500	{4000-11000/cu.mm}
Differential Count ⁰			
a)	Neutrophils :	50	[45 -70%] c) Eosinophils: 05 [01 - 06%]
b)	Lymphocytes :	40	[20 - 45%] d) Monocytes: 05 [00 - 08%]
e)	Basophils :	00	[00 - 01%]
8.	Platelets :3.0	1.5-4.5 Lacks/cu.mm	
9.	Erythrocyte Sedimentation Rate:10	20 mm at end of 1 hour	Method : Westergrens

ROUTINE URINE EXAMINATION (RUA)

1. Physical Examination:

(i)	Colour:	YELLOW	(ii)	Sediment:	CLEAR
(iii)	Transparency:	CLEAR	(iv)	Reaction:	ACIDIC
(v)	Specific gravity	1.010			

2. Chemical Examination:

(i)	Protein :	NIL	(ii)	Sugar:	NIL
(iii)	Bile salt:	NIL	(iv)	Bile pigment:	NIL

3. Microscopic Examination:

(i)	Red Blood Cells:	ABSENT	(ii)	Epithelial Cells:	1 TO 2/ HPF
(iii)	Crystals:	ABSENT	(iv)	Pus Cells:	2 TO 3/HPF
(v)	Casts:	ABSENT	(vi)	Deposits:	ABSENT
(vii)	Bacteria's :	ABSENT			

DR. RAKESH PATKAR
M.D., D.N.B. (Pathology)
Reg. No. 2013/05/1660



Dr. Hari Chhablani

Cardiometabolic Physician & Intensivist
M.B.B.S., F.C.C.P. (RESP. MED.), PGDHHM,
PGDMLS, FELLOW INTENSIVE CARE MED.

ATTACHED TO: Wockhardt Hospital • Saifee Hospital • Apollo Spectra Hospital

NATHANI HEIGHTS, B-Wing, Shop No. 42, Ground Floor, Opp. Mumbai Central Station (East),
Mumbai - 400 008. • Cell : 98206 46163 • E : drharichhablani@gmail.com

PHYSICIAN REPORT

DATE : 26/03/2022

NAME : GARIMA DIPTI 33/F

PRESENTING COMPLAINS : K/C/O PCOS - 2015, UTERINE FIBROID -2018 ON HOMEOPATHY
TREATMENT .

TREATMENT : ON HOMEOPATHY TREATMENT .

PAST HISTORY :H/O FISTULA AND OVARIAN CYST SURGERY - 2016 .

H/O OVARIAN CYST AND FIBROID SURGERY - 2018.

FAMILY HISTORY: NOT SIGNIFICANT

HABITS : NIL.

DENTAL EXAMINATION: NAD

HT.- 158 CM. WT.- 68 Kg. BMI. 27.3

P: 88/MIN ., REGULAR

BP: 120/80

RS: CLEAR CVS: S1,S2 REGULAR

PA: SOFT

CNS: CLINICALLY NAD

EYE EXAMINATION : NEAR VISION -B/E N6 , DISTANT VISION -BE-- 6/6 , COLOUR VISION - NORMAL

LABS: ATTACHED

ECG: WNL

CHEST X-RAY :WNL

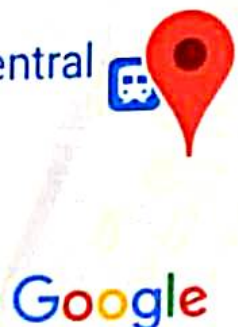SONOGRAPHY : ATTACHED

2-D-ECHO : WNL

ADVICE : REFER TO GYNEACOLOGIST .

DR.HARI CHHABLANI

DR. HARI CHHABLANI
M.B.B.S:F.C.C.P.(RESP MEDICINE) PGDHHM, PGDMLS
FELLOW INTENSIVE CARE
MMC REG. NO. - 91702



Mumbai, Maharashtra, India
Shop No 65, Nathani Heights, Marzban Parsi Colony, Dalal Estate, Mumbai Central, Mumbai, Maharashtra 400008, India
Lat 18.968746°
Long 72.819958°
26/03/22 09:53 AM