



भारतीय विशिष्ट पहचान प्राधिकरण
UNIQUE IDENTIFICATION AUTHORITY OF INDIA

पता:

Address

Date: 6/18/2017
आत्मज: श्यामलाल, 432,
ओम पूरवा, कानपुर, कानपुर
नगर,
उत्तर प्रदेश - 208007

S/O: Shyamlal, 432, om
purwa, Kanpur, Kanpur
Nagar, Uttar Pradesh -
208007

9616 9250 8611



1947

1800 300 1947



help@uidai.gov.in

www

www.uidai.gov.in



P.O. Box No. 1947,
Bengaluru-560 001



भारत सरकार

GOVERNMENT OF INDIA



रुचित कुमार सज्जन

Ruchit Kumar Sajjan

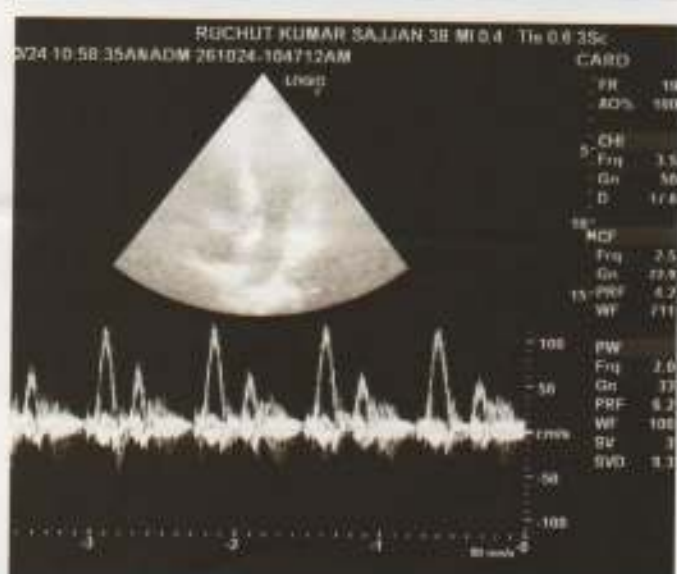
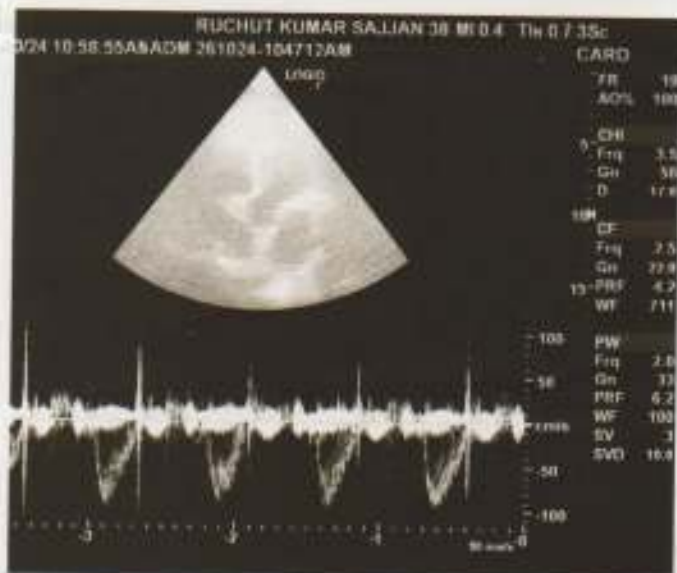
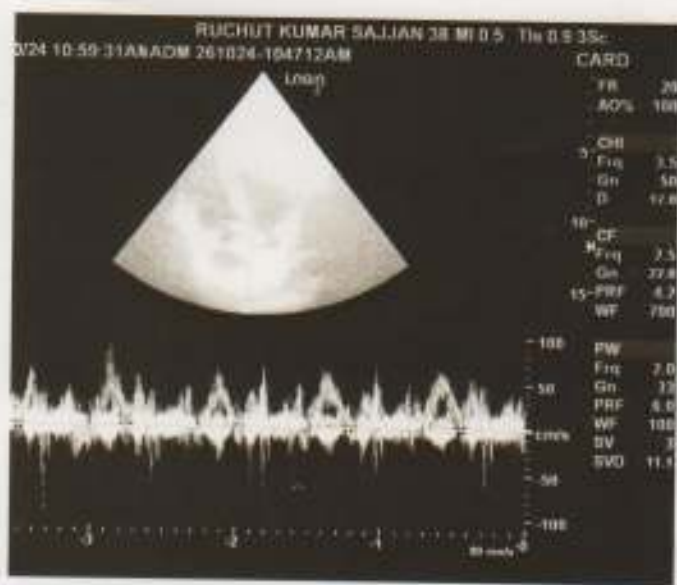
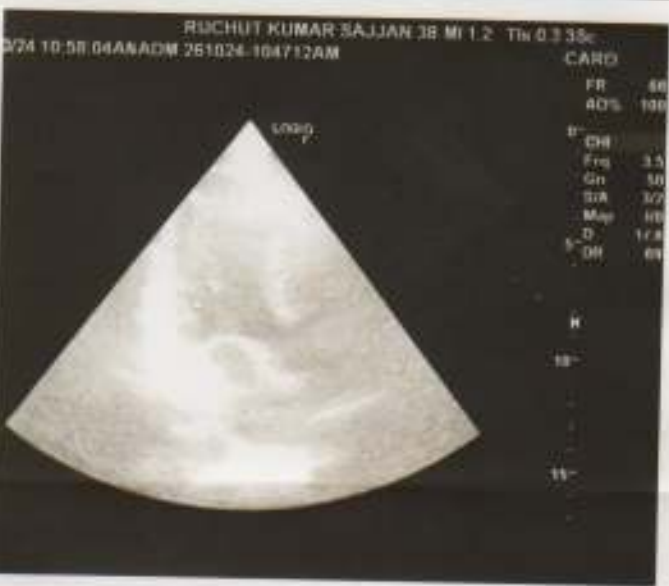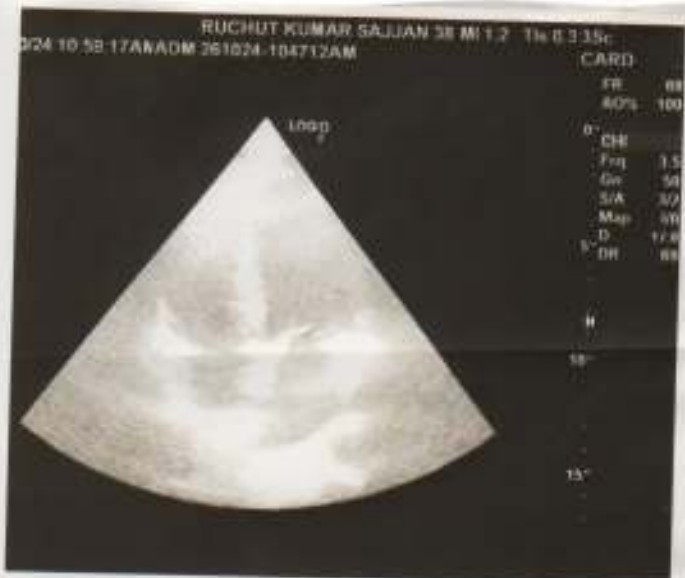
जन्म तिथि / DOB : 04/05/1986

पुरुष / MALE



9616 9250 8611

मेरा आधार मेरी पहचान



ADHAAR CARD OF CLIENT SAJJAN RACHIT KUMAR

DATE: 26 OCTOBER 2024



भारत सरकार
GOVERNMENT OF INDIA



रुचित कुमार सज्जन
Ruchit Kumar Sajjan
जन्म तिथि / DOB : 04/05/1986
पुरुष / MALE



9616 9250 8611

मेरा आधार मेरी पहचान

ORIGINAL SEEN AND VERIFIED



भारतीय विशिष्ट पहचान प्राधिकरण
UNIQUE IDENTIFICATION AUTHORITY OF INDIA

पता:

Address

Date: 6.16.2017
आत्मज: श्यामलाल, 432,
ओम पूरवा, कानपुर, कानपुर
नगर,
उत्तर प्रदेश - 208007

S/O: Shyamlal, 432, om
purwa, Kanpur, Kanpur
Nagar, Uttar Pradesh -
208007

9616 9250 8611



1947
1199 199 1947



help@uidai.gov.in



www.uidai.gov.in



P.O. Box No. 1947,
Bangalore-560 001

CLIENT SIGNATURE

Ruchit

HOSPITAL AUTHORITY SIGNATURE





TAURUS HOSPITAL

(A Unit of Taurus Medicare Pvt. Ltd.)

208. Safipur 1st Ramadevi G. T. Road, Kanpur-208 007



Phone
0512 -2400779
0512 -2400774
0512 -2400737
8601955058

Pathology Report

Lab. No. : 1287	Date : 2024-10-26 09:10:14
Patient Name : Mr. SAJJAN RACHIT KUMAR	Guardian Name :
Age/Sex : 38 Years/Male	Address : OM PURWA KANPUR,
Referred By : SELF	
0	

Test Name	Observed Values	Unit	Normal Values
Blood Chemistry			
KFT			
CRET	0.89	mg/dl	0.70 - 1.40 mg/dl
UREA	25.31	mg/dl	15.00 - 45.00 mg/dl
BUN	12.65	mg/dl	5.00 - 25.00 mg/dl
UAC	3.42	mg/dl	2.50 - 7.50 mg/dl
Haematology			
CBC (Complete Blood Counts)			
Hb	13.90	mg/dl	11.50 - 17.50 mg/dl
TLC	6700	/CU MM	4000-11000
DLC		%	
NEUTROPHILL	55	%	40.0-80.0
LYMPHOCYTE	36	%	20.0-40.0
MONOCYTE	04	%	2.0-10.0
EOSINOPHILL	05	%	1.0-6.0
BASOPHILL		%	2.00 - 2.00 %
RBC	3.58	U/L	4.7-7.1
PCV	38.6	%	36.0-46.0
MCV	107.8	FL	83.0-101.0
MCH	38.8	%	11-20
MCHC	36.0	g/dl	31.5-34.5
PLatelet count	2.46	laks/cum	1.50-4.0
RDW-CV	15.2	%	11.6-14.0

Serology

Blood Group ABO+ Rh "B" POSITIVE gh



Dr. Vishakha Pal
MBBS, DCP (PATH)

Affiliated with CGHS/CAPF/TPA



TAURUS HOSPITAL

(A Unit of Taurus Medicare Pvt. Ltd.)

208. Safipur 1st Ramadevi G. T. Road, Kanpur-208 007

Phone

0512 -2400779

0512 -2400774

0512 -2400737

8601955058



Pathology Report

Lab. No. : 1287	Date : 2024-10-26 09:10:14
Patient Name : Mr. SAJJAN RACHIT KUMAR	Guardian Name :
Age/Sex : 38 Years/Male	Address : OM PURWA KANPUR,
Referred By : SELF	
0	

Test Name	Observed Values	Unit	Normal Values
-----------	-----------------	------	---------------

Biochemistry

Lipid Profile (With Direct - HDL & L)

Cholesterol	188.10	mg/dl	0.00 - 200.00 mg/dl
triglycerides	71.05	mg/dl	0.00 - 150.00 mg/dl
HDL	48.31	mg/dl	30.00 - 65.00 mg/dl
LDL	84.24	mg/dl	0.00 - 130.00 mg/dl
VLDL	27.31	mg/dl	2.00-30.00
Cholesterol/HDL Ratio	3.58	.	<4.00
LDL/HDL cholesterol Ratio	1.58	.	<3.50
HDL/LDL Cholesterol Ratio	0.63	.	<3.50

Blood Chemistry

L.F.T.

BILI TOTAL	0.89	mg/dl	0-2.0 mg/dl
BILI DIRECT	0.19	mg/dl	0-0.20 mg/dl
BILI (IND)	0.70	mg/dl	0.20-0.60mg/dl
SGPT(ALT)	32.4	IU/L	up-45 IU/L
SGOT	30.6	IU/L	up-35 IU/L
ALP(ALKALINE PHOSPHATASE)	71.4	IU/L	54-119 IU/L
TOTAL PROTEIN	6.89	g/dl	6.4-8.3 g/dl
ALBUMIN(ALB)	3.61	g/dl	3.5-4.6 g/dl



Dr. Vishakha Pal
MBBS, DCP (PATH)

Affiliated with CGHS/CAPF/TPA



TAURUS HOSPITAL

(A Unit of Taurus Medicare Pvt. Ltd.)

208. Safipur 1st Ramadevi G. T. Road, Kanpur-208 007

Phone
0512 -2400779
0512 -2400774
0512 -2400737
8601955058



Pathology Report

Lab. No.	: 1287	Date	: 2024-10-26 09:10:14
Patient Name	: Mr. SAJJAN RACHIT KUMAR	Guardian Name	:
Age/Sex	: 38 Years/Male	Address	: OM PURWA KANPUR,
Referred By	: SELF		
	0		

Test Name	Observed Values	Unit	Normal Values
Biochemistry			
blood sugar (pp)	99.46	1	
BLOOD S/F	73.77	mg/dl	70-100
Haematology			
ESR-Wintrobe (Erythrocyte Sedimen	10	mm/hr.	
HbA1C	5.8	g/dl	< 5.6 % Normal 5.7-6.4% Pre-Diabetes >6.5 % Diabetes 6.5-7.0% Good control 7.0-8.0% Poor control >8.0% Bad control
Hormones & Related Test			
T3, T4 (Total) & TSH 3rd Generation			
T3	2.10	.	1.30-3.10nmol/L
T4	88.49	.	66.00-181.00nmol/L
TSH	4.21	.	0.45-4.50MIU/L



Dr. Vishakha Pal
MBBS, DCP (PATH)

Affiliated with CGHS/CAPF/TPA



TAURUS HOSPITAL

(A Unit of Taurus Medicare Pvt. Ltd.)

208. Safipur 1st Ramadevi G. T. Road, Kanpur-208 007



Phone

0512 -2400779

0512 -2400774

0512 -2400737

8601955058

Pathology Report

Lab. No. : 1287	Date : 2024-10-26 09:10:14
Patient Name : Mr. SAJJAN RACHIT KUMAR	Guardian Name :
Age/Sex : 38 Years/Male	Address : OM PURWA KANPUR,
Referred By : SELF	
0	

Test Name	Observed Values	Unit	Normal Values
-----------	-----------------	------	---------------

Clinical

URINE R/M

Colour	STRAW	.	
Appearance	CLEAR	.	
Specific Gravity	1.010	.	1.005-1.030
Ph	6.0	.	4.5-8.0
Protien	Nil	.	Nil
Glucose	Nil	.	Nil
Pus Cells	1-2	/hpf	0-5
Epithelial Cells	1-2	/hpf	0-5
RBC	Nil	/hpf	Nil
Casts	Not Seen	.	Not Seen
Crystals	Not Seen	.	Not Seen



Dr. Vishakha Pal
MBBS, DCP (PATH)

ECG report

ID : 20241026080601

Name : MR. Saijan Rachit Kumar

Gender : M

Age :

Dept :

Bed No :

HR : 69 bpm

PR : 134 ms

QRS : 76 ms

QT/QTc : 336/352 ms

P/QRS/T : 61/26/65°

RV5/SV1 : 1.197/0.658 mv

RV5+SV1 : 1.855 mv

<<Interpretations >>

Sinus rhythm

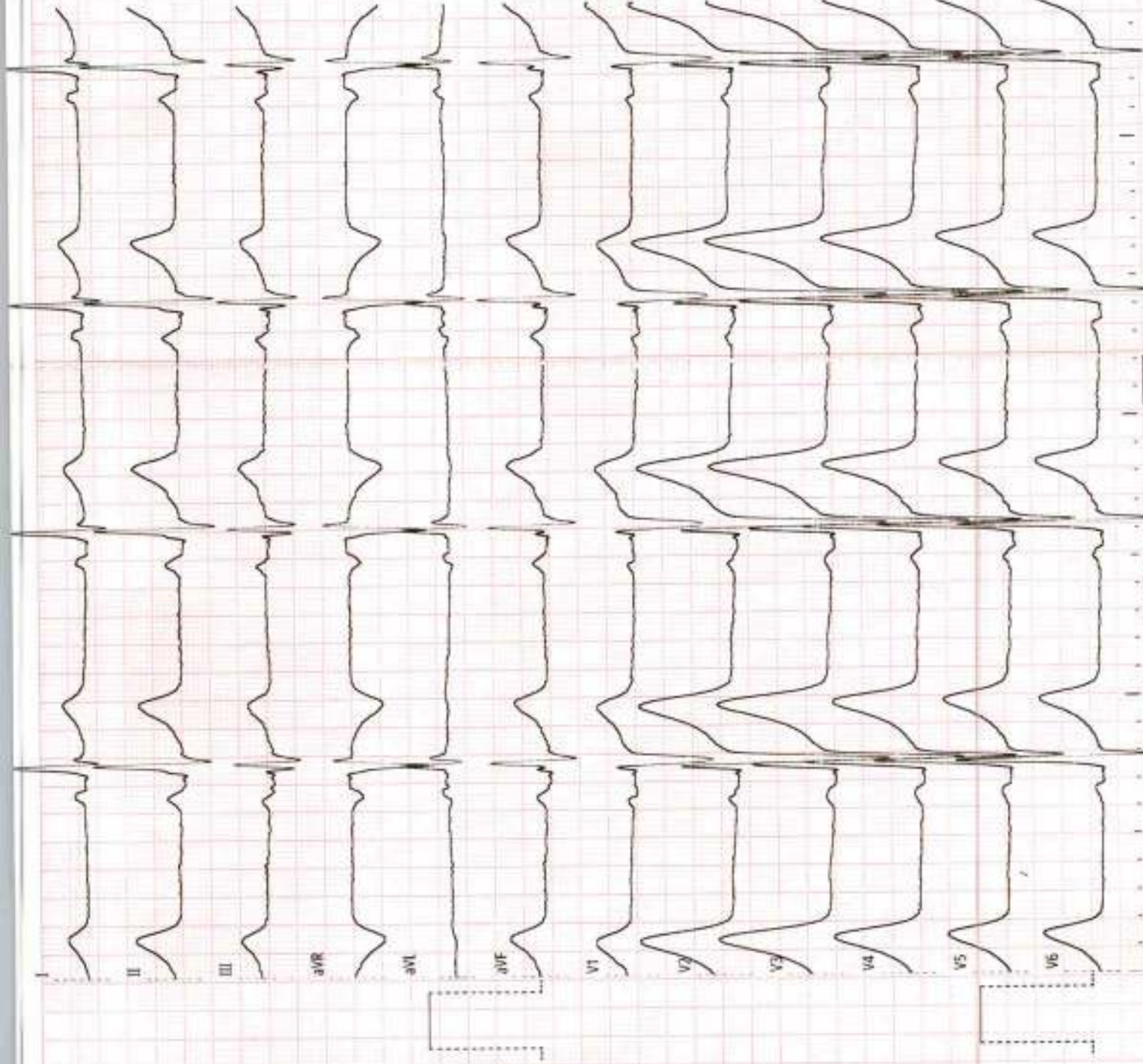
— Interpretation made without knowing

patient's age —

Normal ECG

Confirm and sign:

Examination time: 2024-10-26 08:06:51



0.3Hz - 35Hz - AC 50Hz 50mm/s 20mm/mv 1.0.25 Simultaneous



RAJNI HOSPITAL



A Unit of Shrimati Rajani Dwivedi Charitable Society
1518/5, Daheli Sujapur, By Pass Road, Kanpur-208013
(Near Koyla Nagar Police Chowki)
GST NO:- 09AARTS9188A1ZR

Helpline No.: [

+91 -8004991414

+91 -8004991515

+91 -8004991616

+91 -8933048215

Web : www.rajnihospitalin.com
Email : rajnihospitalknp@gmail.com

Patient Name : Mr. RACHIT KUMAR SAJJAN
Referred By : Dr. SELF
Investigation : USG Whole Abdomen

Age : 38years/M
Date : 26/10/2024

Liver:

- Liver is enlarged in size mea(158mm). with hyper echoic Echogenicity fatty change. No focal or diffuse lesion seen. Hepatic veins appear normal. No dilation of intrahepatic biliary ducts is seen.

Gall bladder:

- Gall bladder is normal in size and show echo free lumen. Wall thickness is within normal limit. No calculus & mass lesion seen in GB.

Portal vein:

- Normal in size (mm) and shows normal appearance.

C.B.D.:

- Normal in size (mm) and shows normal caliber.

Pancreas:

- Pancreas is normal in size. No calcification or mass lesion seen.

Spleen:

- Spleen is normal in size. Splenic vein appears normal. No mass seen.

Right kidney:

- Normal in size (110x51mm) seen in respective renal areas.
- Cortico - medullary differentiation appears to be normal.
- No calculus or mass lesion seen. No hydronephrosis is seen.

P.T.O



RAJNI HOSPITAL

A Unit of Shrimati Rajani Dwivedi Charitable Society
1518/5, Daheli Sujapur, By Pass Road, Kanpur-208013
(Near Koyla Nagar Police Chowki)
GST NO:- 09AARTS9188A1ZR



Helpline No.:

- +91 -8004991414
- +91 -8004991515
- +91 -8004991616
- +91 -8933048215

Web : www.rajnihospitalin
Email : rajnihospitalknp@gmail.com

Left kidney:

- Normal in size (108x45mm) seen in respective renal areas.
- Cortico - medullary differentiation appears to be normal.
- **Single hypo echoic cyst seen in left kidney. It mea(12x12mm).**

Ureter:

- Both ureters are normal.

Urinary bladder:

- Normal in shape and size. Wall thickness is within normal limit.
- No calculus & mass lesion seen.

Prostate:

- Prostate is normal in shape and size. No calculus or mass lesion noted.

Peritoneum/Retroperitoneum:

- **Dilated bowel loops with gas shadow seen in whole abdomen.**
- No ascitis or fluid is seen. No lymphadenopathis seen.

Impression:

- **HEPATOMEGALY WITH FATTY**
- **LEFT RENAL CYST**
- **DILATED BOWEL LOOPS WITH GAS**

ADV: CT- Scan, LFT, KFT Please correlate clinically.

SONOLOGIST



Affiliated with CGHS / CAPF

TOURUS HOSPITAL

(A Unit of Taurus Medicare Pvt. Ltd.)

208, Safipur 1st Ramadevi, G. T. Road, Kanpur-208 007

Ph.: 0512-2400779, 2400774, 2400737, 8601955058 • E-mail: tourushospital@gmail.com



<i>Patient Name</i>	SAJJAN RACHIT KUMAR	<i>Patient ID</i>	261024-1
<i>Age/D.O.B</i>	38 YRS	<i>Gender</i>	M
<i>Ref Doctor</i>	SELF	<i>Date</i>	26 Oct 24

XRAY RADIOGRAPH CHEST - PA

Observations

Soft tissues of the chest wall are normal.
Cardiothoracic ratio is normal.
Both costophrenic angles appear normal.
Visualized thoracic vertebral is normal.
Sternum appears normal.
Both lung fields are clear.

Impression

The study is within normal limits.

Reported By,

Mr. Farid Khan

Dr. Farid Khan

MBBS, MD

Consultant Radiologist

MPMC - 23324



Affiliated with CGHS / CAPF
TOURUS HOSPITAL

(A Unit of Taurus Medicare Pvt. Ltd.)

208, Safipur 1st Ramadevi, G. T. Road, Kanpur-208 007

Ph.: 0512-2400779, 2400774, 2400737, 8601955058 • E-mail: tourushospital@gmail.com



2DECHO

Normal size LA LV, RA RV

• NO RWMA

• NO MRITK IAR

• NO MCLAS

• NO PE / Apical clot

• INC \rightarrow 14 mm
Collapsing \rightarrow 50%
c-Resp.

• LVEF - 60-65%



