

Facilities:

All clinical Biomedical & Hematology Investigations including Bone Marrow Examination
VPT, Podiascan & Complete Foot Care (First Time in Purvanchal)
All Hormonal Investigation by Chemiluminescent Method
Visceral Fat by (AB-140) Ambulatory BP Monitoring
CGMS & Insulin Pump Available
PFT, 2D-ECHO (Color Doppler), Holter, TMT, Cardiac-3 available
VIA, VILI, Colposcopy available
Special Endocrinological Investigation Protocols.

ISO 9001:2008 Certified
Mobile: 9389994334, 9554572190, 9453837595



Panacea Pathology

Clinical Reference Lab

Persistence, Preparedness and Precision
EQAS (CMC Vellore Attached) & IQAS System
पूर्वाचल की सर्वोत्तम गुणवत्ता वाली पैथोलॉजी

PATIENT NAME : VIKAS KUMAR SINGH

AGE/GENDER : 41YRS/MALE

REFD BY DR. : ARCO FEMI HEALTHCARE LTD.

RECEIVED DATE :11-02-2023 (09:00 AM)

SAMPLE : BLOOD & URINE

REPORT DATE :13-02-2023 (02:00 PM)

PATHOLOGY REPORT

COMPLETE BLOOD COUNT (CBC)

TEST	LAB TEST VALUES	NORMAL RANGE
HEMOGRAM		
HEMOGLOBIN (FLOW CYTOMETRY)	14.2	13 – 16 gm/dl
TOTAL LEUCOCYTE COUNT (TLC)	5,600	4000 – 11000
RBC COUNT	5.47	3.5 – 5.5
PCV (HCT)	46.7	37 – 47
MCV	81.3	80 – 95
MCH	24.7	28 – 34
MCHC	30.3	30 – 36
PLATELET COUNT	2,64,000	1,50,000 – 4,00,000
E.S.R. (WINTROBE FIRST HOURS)	12.0	20 mm/1 st hr
DIFFERENTIAL LEUCOCYTE		
NEUTROPHILS	51	40 – 75%
LYMPHOCYTES	37	20 – 45%
EOSINOPHILS	05	1 – 6%
MONOCYTES	07	2 – 8%
BASOPHILS	00	< 2%

RANDOM/FASTING BLOOD SUGER

TEST	LAB TEST VALUES	NORMAL RANGE
RBS/FBS		
RANDOM BLOOD SUGAR	129.0	125-140 mg/dl
FASTING BLOOD SUGER	102.0	70-125 mg/dl

GLYCOSYLATED HEMOGLOBIN (HBA1C)

TEST	LAB TEST VALUES	NORMAL RANGE
HBA1C	6.1	Normal : <5.97 % Good Control : 5.97 – 6.81% Fair Control : 6.81 – 7.65% Poor Control : >7.65%

PAGE 1

Lab Technician

PANACEA HOSPITAL
(A UNIT OF ARCO FEMI HEALTHCARE PVT. LTD.)
REG. NO. 1500
B.36/44, B.S. KABIR NAGAR
DURGAKUND, VARANASI
M.D., Pathology

Timing : 8.00 a.m. to 9.00 p.m. (Sunday 8.00 a.m. to 3.00 p.m.)

This Report is not valid for medico legal purpose

Note: These tests have technical limitations. Clinico-pathological interpretation is necessary. In case of any disparity test may be repeated immediately.

Address : 36/44 FK Kabir Nagar, Durgakund, Varanasi – 221005

Email: dramishra@gmail.com, drpallaviojha@gmail.com Website: panaceahospital.org

ilities:
 All clinical Biomedical & Hematology Investigations
 including Bone Marrow Examination
 VPT, Podiascan & Complete Foot Care (First Time in Purvanchal)
 All Hormonal Investigation by Chemiluminescent Method
 Visceral Fat by (AB-140) Ambulatory BP Monitoring
 CGMS & Insulin Pump Available
 PFT, 2D-ECHO (Color Doppler), Holter, TMT, Cardiac-3 available
 VIA, VILI, Colposcopy available
 Special Endocrinological Investigation Protocols.

ISO 9001:2008 Certified
 Mobile: 9389994334, 9554572190, 9453837595



Panacea Pathology

Clinical Reference Lab

Persistence, Preparedness and Precision
 EQAS (CMC Vellore Attached) & IQAS System
 पूर्वांचल की सर्वोत्तम गुणवत्ता वाली पैथोलॉजी

PATIENT NAME : VIKAS KUMAR SINGH AGE/GENDER : 41YRS/MALE
 REFD BY DR. : ARCO FEMI HEALTHCARE LTD. RECEIVED DATE :11-02-2023 (09:00 AM)
 SAMPLE : BLOOD & URINE REPORT DATE :13-02-2023 (02:00 PM)

PATHOLOGY REPORT

LIPID PROFILE, SERUM

TEST	LAB TEST VALUES	NORMAL RANGE
BLOOD CHEMISTRY		
TOTAL CHOLESTEROL (SERUM)	175.0	Desirable:- < 200 mg/dl Borderline:- 200 – 239 mg/dl High: & gt; 240 mg/dl
TRIGLYCERIDES (SERUM)	164.0	35 – 170 mg/dl
HDL CHOLESTEROL (SERUM)	42.0	35.30 – 79.50 mg/dl
LDL CHOLESTEROL (SERUM)	100.2	& lt; 130 mg/dl
VLDL	32.8	& lt; 40 mg/dl
CHOLESTROL/HDL RATIO	4.1	& lt; 3.0 Low Risk Ratio 3.0 – 5.0 Avg Risk & lt; 5.0 High Risk
LDL/HDL RATIO	0.32	& lt; 3 Ratio

BLOOD GROUP

TEST	LAB TEST VALUES
BLOOD GROUP ABO & RH FACTOR	
BLOOD GROUP	"B"
RH FACTOR	POSITIVE

LIVER PROFILE TEST, SERUM

TEST	LAB TEST VALUES	NORMAL RANGE
BIO CHEMISTRY		
TOTAL BILIRUBIN	0.62	0.0 – 1.1 mg/dl
DIRECT BILIRUBIN	0.22	0.0 – 0.2 mg/dl
INDIRECT BILIRUBIN	0.40	< 0.90 mg/dl
SGOT (AST)	18.6	0 – 52 mg/dl
SGPT (ALT)	22.5	0 – 39 mg/dl
GGT (GYT)	15.4	< 55 U/L

THYROID PROFILE (T3, T4, TSH)

TEST	LAB TEST VALUES	NORMAL RANGE
THYROID FUNCTION TEST		
T3	1.0	0.60 – 1.81 ng/ml
T4	7.46	4.50 – 10.90 ug/dl
TSH	1.05	0.39 – 6.10 uIU/mL

PAGE 2

Lab Technician

Timing : 8.00 a.m. to 9.00 p.m. (Sunday 8.00 a.m. to 3.00 p.m.)

This Report is not valid for medico legal purpose

Note: These tests have technical limitations. Clinico-pathological interpretation is necessary. In case of any disparity test may be repeated immediately.

Address : 36/44 FK Kabir Nagar, Durgakund, Varanasi – 221005

Email: dramishra@gmail.com, drpallaviojha@gmail.com Website: panaceahospital.org

PANACEA HOSPITAL
 (A UNIT OF ARCO FEMI HEALTHCARE PVT. LTD.)
 REG. NO. 1000
 B.36/44, B-4, KABIR NAGAR
 DURGAKUND, VARANASI

M.D., Pathology

Facilities:
 All clinical Biomedical & Hematology Investigations
 including Bone Marrow Examination
 VPT, Podiascan & Complete Foot Care (First Time in Purvanchal)
 All Hormonal Investigation by Chemiluminescent Method
 Visceral Fat by (AB-140) Ambulatory BP Monitoring
 CGMS & Insulin Pump Available
 PFT, 2D-ECHO (Color Doppler), Holter, TMT, Cardiac-3 available
 VIA, VILI, Colposcopy available
 Special Endocrinological Investigation Protocols.

ISO 9001:2008 Certified
 Mobile: 9389994334, 9554572190, 9453837595



Panacea Pathology

Clinical Reference Lab

Persistence, Preparedness and Precision
 EQAS (CMC Vellore Attached) & IQAS System
 पूर्वांचल की सर्वोत्तम गुणवत्ता वाली पैथोलॉजी

PATIENT NAME : VIKAS KUMAR SINGH	AGE/GENDER : 41YRS/MALE
REFD BY DR. : ARCO FEMI HEALTHCARE LTD.	RECEIVED DATE :11-02-2023 (09:00 AM)
SAMPLE : BLOOD & URINE	REPORT DATE :13-02-2023 (02:00 PM)

PATHOLOGY REPORT

RENAL & KIDNEY PROFILE, SERUM

TEST	LAB TEST VALUES	NORMAL RANGE
RENAL FUNCTION TESTS		
BLOOD UREA NITROGEN (BUN)	9.56	10 – 50 mg/dl
SERUM CREATININE	0.91	0.60 – 1.60 mg/dl
URIC ACID	3.92	3.60 – 7.70 mg/dl
ALKALINE PHOSPHATASE (ALP)	72.0	142 – 353 mg/dl
TOTAL PROTIENS	7.56	0 – 39 mg/dl
ALBUMIN	4.12	3.8 – 5.4 mg/dl
SERUM GLOBULIN	3.44	2.1 – 3.5 mg/dl
CALCIUM	9.2	8.80 – 10.20
PHOSPHORUS	3.04	2.50 – 5.00
SERUM SODIUM NA+	140.6	135.00 – 155.00 mEq/Ltr
SERUM POTASIUM K+	4.32	3.60 – 5.50 mEq/Ltr
ICALCIUM	1.24	1.10 – 1.35 mmol/L
SERUM CHLORIDE CL+	105.9	98.00 – 110.00 mEq/Ltr

URINE ROUTINE EXAMINATION

TEST	LAB TEST VALUES	NORMAL RANGE
PHYSICAL EXAMINATION		
QUANTITY	30	ML
COLOUR	STRAW	PALE YELLOW
APPEARANCE	CLEAR	CLEAR
SPECIFIC GRAVITY	1.010	1.01 – 1.03
PH	5.5	4.7 – 7.5
CHEMICAL EXAMINATION		
GLUCOSE	Not Detected	Not Detected
PROTEIN	NIL	Not Detected
MICROSCOPIC EXAMINATION		
PUS CELLS	1-2	0-5
RBC	Not Detected	Not Detected
EPITHELIAL CELLS	1-2	0-5
CASTS	Not Detected	Not Detected
CRYSTALS	Not Detected	Not Detected
BACTERIA	Not Detected	Not Detected

----- End of Report -----

Lab Technician

PANACEA HOSPITAL
 (A UNIT OF AAROHAN HEALTHCARE PVT. LTD.)
 REG. NO. 1500
 B.36/44, KABIR NAGAR
 DURGAKUND, VARANASI

Timing : 8.00 a.m. to 9.00 p.m. (Sunday 8.00 a.m. to 3.00 p.m.)

This Report is not valid for medico legal purpose

Note: These tests have technical limitations. Clinico-pathological interpretation is necessary. In case of any disparity test may be repeated immediately.

Address : 36/44 FK Kabir Nagar, Durgakund, Varanasi – 221005

Email: dramishra@gmail.com, drpallaviojha@gmail.com Website: panaceahospital.org



PANACEA HOSPITAL

B 36/44 F.K KABIR NAGAR, DURGAKUND
TOLLFREE NO-18001233070.
Whatsapp No - 8795832852
www.piire.org



OP Slip

Print Date : 11-Feb-2023 12:01PM



UHID No :- UD-22230003588	OP No :- OP-22230013330	OP Date :- 11 Feb 2023 12:01PM
Patient Name :- Mr VIKASH KUMAR SINGH BOB	Age/Sex :- 42 Y/Male	Mobile No :- 8840189830
Father :- VISHWANATH PRASAD SINGH	Department :- DIABETES, ENDOCRINOLOGY & METABOLIC PHYSICIAN	
Pay Type :- Cash	Consultant :- Dr ASHUTOSH MISHRA (MD(MEDICINE), IMS, BHU)	
Token No :- NOR. - 10	Paid/Bal :- 0.00 /500.00	
Patient Type :- Normal		
Address :- N 16/12-S, KOLHUA VINAYAK, varanasi		

BP :- 130/80 **Rx**
 height :- 173
 Weight (kg) :- 76.7
 BMI :- 26.7

SBP: 95
 PR: 79.

Pre-Diabetes
 OA
 (P/O SSA)

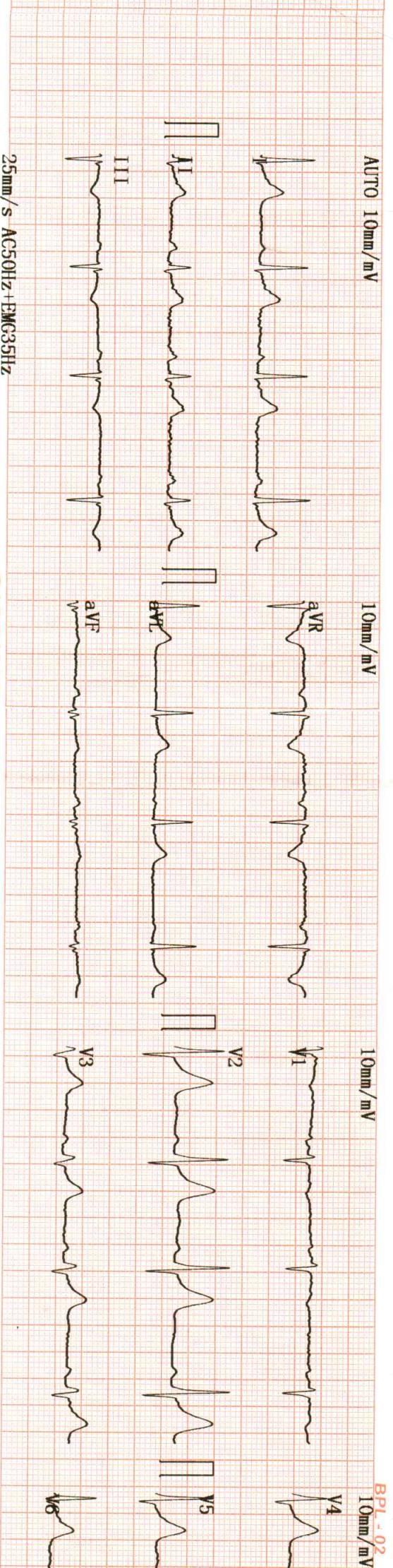
Diet & Exer

- ES. Diabetomas (10) ON
- ES. Tofaunb (5.0)
- ES. Metx (7.5) / Robut (5.0)
 (Mon) (Tue)

PTA 1 month

AdW
 o US guided PPD
 o Xray knee joint AD
 CAP. HLAB27.

Printed By : Mr NITIN YADAV
 Created By : Mr NITIN YADAV



CARDIART

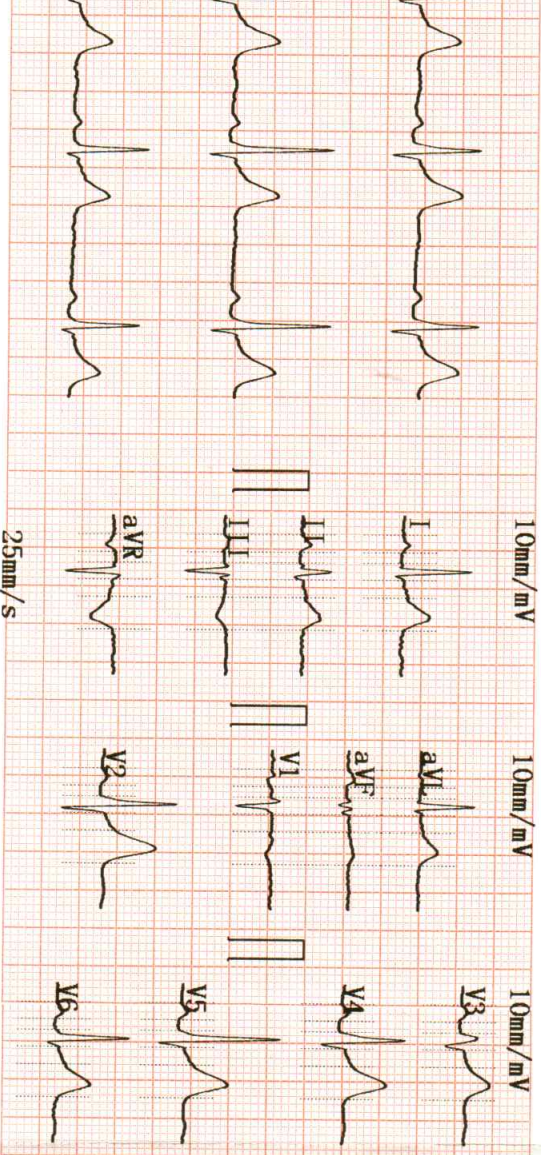
AUTO 10mm/mV

10mm/mV

10mm/mV

BPL-02
10mm/mV

25mm/s AC50Hz+EMG35Hz



CARDIART

2023-02-11 14:19

ID : _____

Name : Venkash Kumar Singh

Sex : M

Height : _____

SYS : _____

DIA : _____

HR [bpm] : 70

PR Interval [ms] : 154

P Duration [ms] : 96

QRS Duration [ms] : 91

T Duration [ms] : 176

QT/QTc [ms] : 362/392

P/QRS/T Axis [deg] : 53.1/-1.3/20.3

R (V5)/S (V1) [mV] : 1.35/0.46

R (V5)+S (V1) [mV] : 1.80

<< Conclusions >>

Normal Sinus Rhythm.
Middling Left axis deviation.

Weight : 88 kg **Report need physician confirm**

Physician _____

Pallavi
DR. PALLAVI MISERA
MBBS,MD (GENERAL MEDICINE)
MCI Reg. No. 5203



Call Now - 1800-123-3070

PANACEA HOSPITAL

A shelter for many hearts A Home for many lives

(An ISO 9001:2008 Certified Organisation)

Lab Attached with CMC Vellore Under EQAS Scheme


Name	MR.VIKASH KUMAR SINGH	Sex /Age	30/M	Date	11/02/2023
Ref. by	Dr.Pallavi Mishra(MD)	BSA - m ²		Echo window	fair


Echo - Cardiography

MITRAL VALVE Doppler	AML - normal morphology MV Flow - E - 0.5 A-0.3 E/A=1.35	PML - normal morphology MVA - 3.0 cm ² Mitral Regurgitation - No
TRICUSPID VALVE Doppler	Normal TV Flow -No	Tricuspid Regurgitation - No
PULMONARY VALVE Doppler	Normal PV Flow -No	Pulmonary Regurgitation - No
AORTIC VALVE Doppler	Trileaflet-No AV Flow - no	Aortic Regurgitation - no
MEASUREMENT	Aorta - 26.8 (20-38) mm IVS ed - 12.6 (6 -12) mm LVID ed - 34.3 (35 - 55) mm LVPW ed - 13.1 (6 -12) mm OA - 7 (> 5) mm	LA - 36.6 (24-32) mm IVS es -18.3 (6 - 12) mm LVID es - 23.4 (24 - 40) mm LVPW es - 17.1 (6 -12) mm EPSS - 6 (< 9) mm

CONCLUSION All cardiac chamber dimensions are WNL
No valvular abnormalities
Good LV systolic function present Modified Simpson's method (4C, 2C) (LVEF-61%)
No diastolic dysfunction present (E/A = 1.35) by tissue Doppler (E/e'=6.2)
No RWMA
No pericardial effusion
Intact IAS / IV
No PAH
No intra cardiac mass /thrombus /vegetation

IMPRESSION Normal Echocardiogram

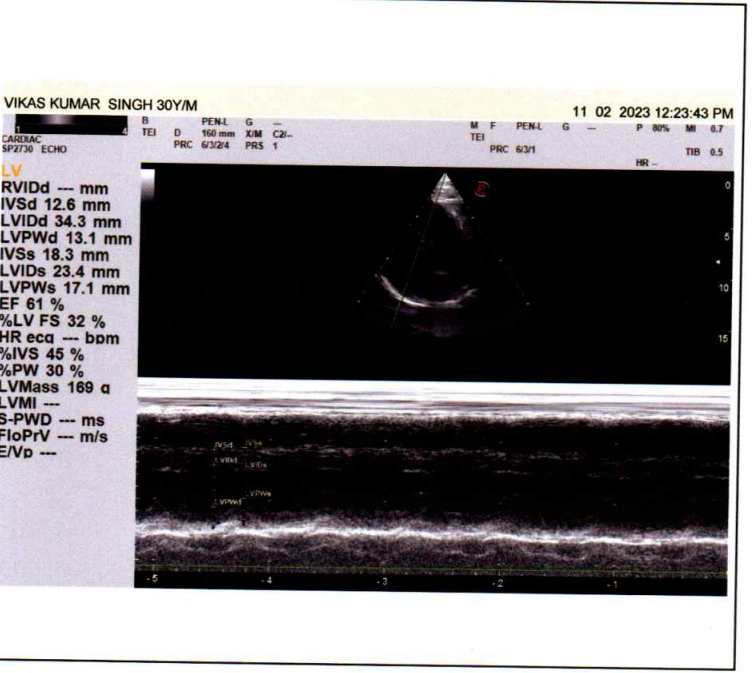
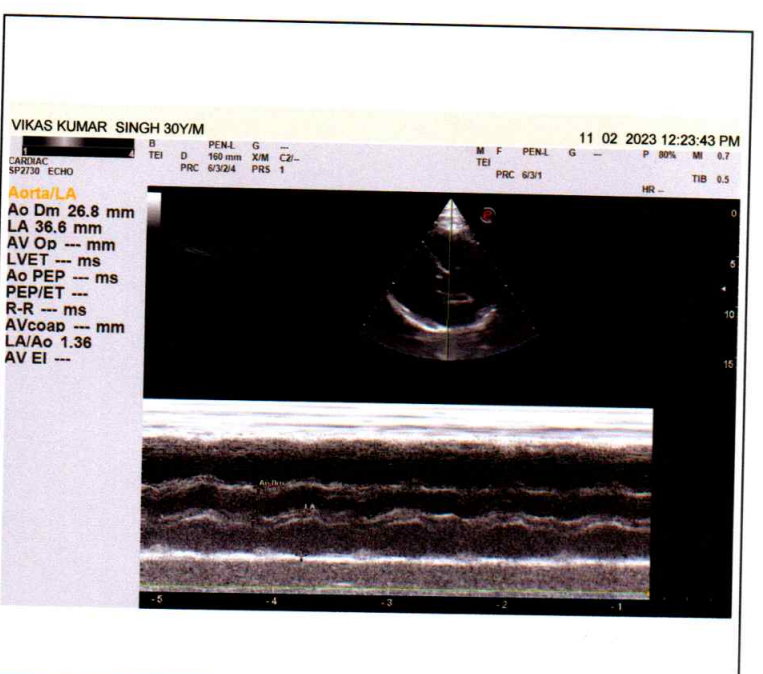
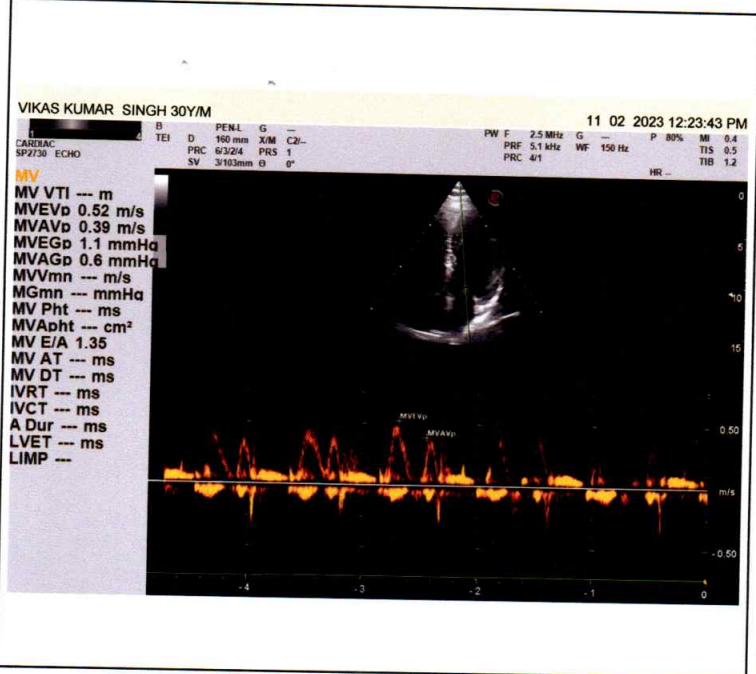
Niraj Mishra
Physician Assistant
(PIIRE)


DR. PALLAVI MISHRA
MBBS, MD (GENERAL MEDICINE)
MCI Reg. No. 52033
Dr. Pallavi Mishra
MBBS, MD (MED) Lucknow
Echocardiography Specialist, MIAE
Non-invasive cardiologist
Women Cardiologist
Diabetocardiologist

Address : Kabir Nagar (Near Sanjay Shiksha Niketan), Durgakund, Varanasi

Mobile : 9554572190 / 9453837595 / Recpn. 9389994334

E-mail : dramishra@gmail.com, drpallaviojha@gmail.com, Website: www.piire.org





PANACEA HOSPITAL

A shelter for many hearts A Home for many lives

(An ISO 9001:2008 Certified Organisation)

Lab Attached with CMC Vellore Under EQAS Scheme

NAME: MR. VIKASH KUMAR SINGH

AGE/SEX: 30 YRS / MALE

REF BY: DR. ASHUTOSH MISHRA (MD)

DATE: 11/02/2023

ULTRA SOUND WHOLE ABDOMEN REPORT

Liver: Normal in shape and size (14.0 cm) and shows mildly increased echogenicity. Margins are smooth and regular. No focal lesion seen.

Gall bladder: Partially distended with normal wall thickness and echo-free lumen.

CBD diameter Visualized part normal in course & caliber.

Pancreas: Normal in size, shape & echogenicity. Margins are smooth & regular. No diffuse/ focal lesion seen. Pancreatic tail obscured.

Spleen: Normal in size, shape & echogenicity. Margins are smooth & regular. No diffuse / focal lesion seen. Splenic vessels at hilum is normal.

Kidney: Both normal in size, shape, echogenicity & position. Cortical-medullary differentiation is maintained. Pelvicalyceal system normal. No calculus/mass lesion seen. No hydronephrosis/ hydroureter seen. No suprarenal mass lesion.

Address : Kabir Nagar (Near Sanjay Shiksha Niketan), Durgakund, Varanasi

Mobile : 9554572190 / 9453837595 / Recpn. 9389994334

E-mail : dramishra@gmail.com, drpallaviojha@gmail.com, Website: www.piire.org



PANACEA HOSPITAL

A shelter for many hearts A Home for many lives

(An ISO 9001:2008 Certified Organisation)

Lab Attached with CMC, Vellore Under EQAS Scheme

Urinary bladder: Normally distended, wall thickness is normal.

No echogenic foci lumen or diverticula seen.

Both VUJ appears normal.

No E.R. calculus / mass lesion seen.

Prostate: Normal in size, shape, & echogenicity.

No calcification or focal cystic lesion seen.

Capsular margins are smooth and regular.

Seminal vesicles appear normal in size, shape & echogenicity.

No diffuse /focal lesion seen.

Others: No free fluid in peritoneal cavity.

No free fluid in bilateral pleural cavity.

IMPRESSION:

- *Grade I fatty liver.*

Please correlate clinically and further investigations.

Pallavi
DR. PALLAVI MISHRA

MBBS MD(MED) Lucknow

Echocardiography specialist, MIAE

Non invasive cardiologist

Women cardiologist

Radiologist

Dr. Tusharika Rai

MBBS MS

NIRAJ MISHRA

(Physician Assistant)

(PIIRE)

Address : Kabir Nagar (Near Sanjay Shiksha Niketan), Durgakund, Varanasi

Mobile : 9554572190 / 9453837595 / Recpn. 9389994334

E-mail : dramishra@gmail.com, drpallaviojha@gmail.com, Website: www.piire.org

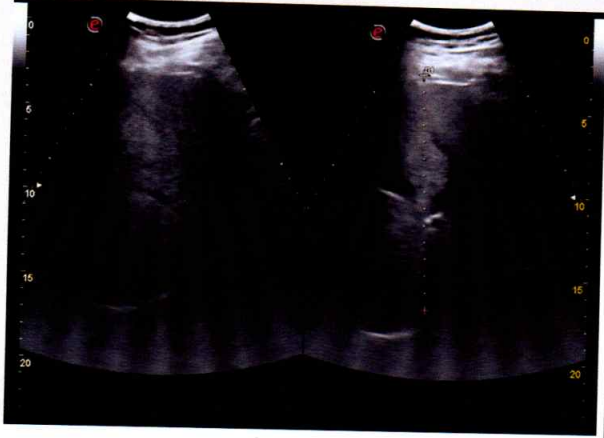
VIKAS KUMAR SINGH 30Y/M

11 02 2023 12:28:35 PM

ABDOMINAL AC2541 ABD
TEI D 211 mm X/M C2/-
PRC 19/2/3/5 PRS 4

P 60% MI 0.8

D1
140.3 mm



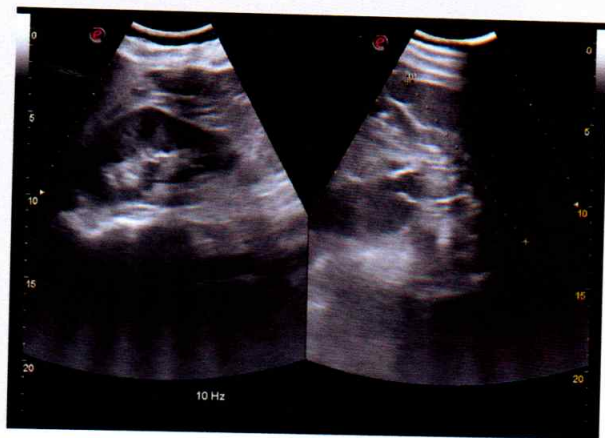VIKAS KUMAR SINGH 30Y/M

11 02 2023 12:28:35 PM

ABDOMINAL AC2541 ABD
TEI D 211 mm X/M C2/-
PRC 19/2/3/5 PRS 4

P 60% MI 0.8

D1
120.7 mm

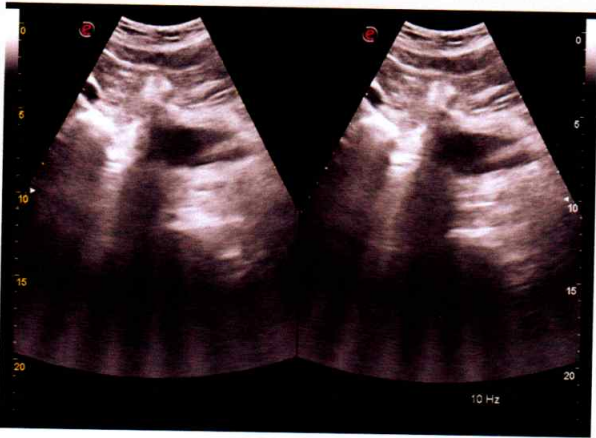


VIKAS KUMAR SINGH 30Y/M

11 02 2023 12:28:35 PM

ABDOMINAL AC2541 ABD
TEI D 211 mm X/M C2/-
PRC 19/2/3/5 PRS 4

P 60% MI 0.8





Call Now - 1800-123-3070

PANACEA HOSPITAL

A shelter for many hearts A Home for many lives

(An ISO 9001:2008 Certified Organisation)

Lab Attached with CMC Vellore Under EQAS Scheme

NAME: MR. VIKASH KUMAR SINGH

AGE/SEX: 30 YRS / MALE

REF BY: DR. ASHUTOSH MISHRA (MD)

DATE: 11/02/2023

X-RAY CHEST PA

BOTH LUNG FIELDS AND PLEURAE:

Both lungs show normal bronchovascular pattern.

Right & left hila are normal

No focal mass or calcification is seen

There is no evidence of any fluid in the both the pleural cavities.

Both domes of diaphragms are normal in position.

MEDIASTINUM:

Trachea is central in position.

Cardiac silhouette is of normal size and configuration.

No evidence of pericardial effusion.

No significant lymphadenopathy is seen.

Visualized skeleton is normal.

NO SIGNIFICANT RADIOGRAPHIC ABNORMALITY.

REPORTED BY

DR. Rahul Kumar Tiwari

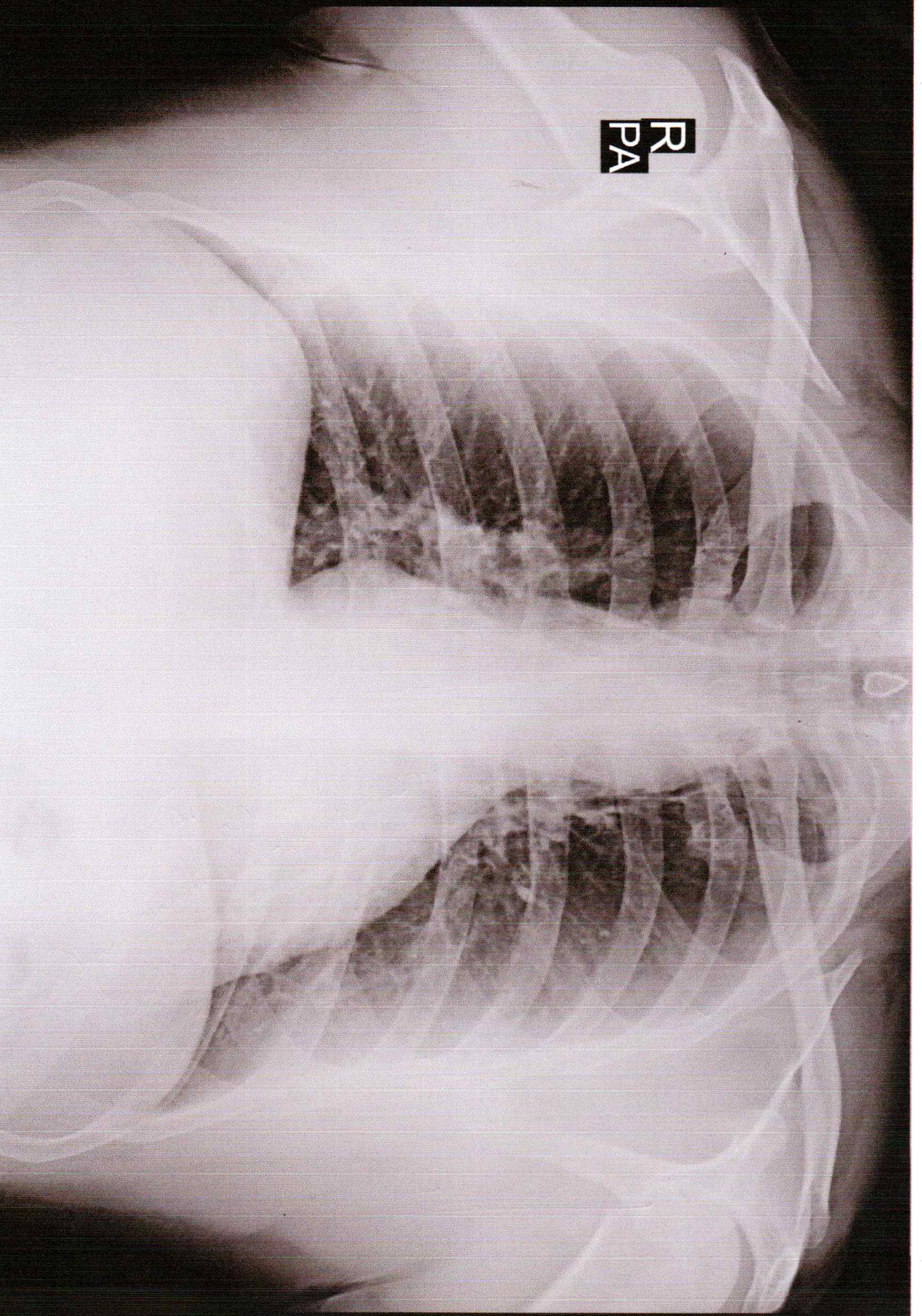
MBBS, MD (Radio Diagnosis)

Reg.No. 57557

Address : Kabir Nagar (Near Sanjay Shiksha Niketan), Durgakund, Varanasi

Mobile : 9554572190 / 9453837595 / Recpn. 9389994334

E-mail : dramishra@gmail.com, drpallaviojha@gmail.com, Website: www.piire.org



VIKASH KUMAR SINGH BOB 42Y1M 3588 O CHEST P.A. 11-Feb-23 12:56 PM

PANACEA HOSPITAL, KABIR NAGAR, DURGAKUND, VARANASI