


NABH ACCREDITED
PRAKASH
EYE HOSPITAL & LASER CENTRE

Dr. AMIT GARG

M.B.B.S., D.N.B. (Oph.)
I-Lasik (Femto) Bladefree Topical Micro Phaco
& Medical Retina Specialist
Ex. Micro phaco Surgeon
Venu Eye Institute & Research Centre, New Delhi

Name Shubham Agrawal Age/Sex 30 / Male C/o Date 13/03/2022

cf. - Routine checked
M/- Nil.



Accredited Eye Hospital in Western U.P.

First NABH ECO

प्रकाश आँखों का अस्पताल एवं लेजर सेंटर



Website: www.prakasheyehospital.in
Facebook: <http://www.prakasheyehospital.in>

Counsellor 9837066186
7535832832
Manager 7895517715
OT 7302222373

निकट नई सड़क, गढ़ रोड, मेरठ।
Timings Morning : 10.00 am to 2.00 pm.
Evening : 5.00 pm to 8.00 pm.
Sunday : 10.00 am to 2.00 pm.
Near Naj Sarak, Garh Road, Meerut.



भारत सरकार
Government of India

भारतीय विशिष्ट पहचान प्राधिकरण
Unique Identification Authority of India

नामांकन क्रमांक / Enrollment No.: 0648/00569/09668


To
शुभम अग्रवाल
Shubham Agrawal
S/O Pradeep Kumar Agrawal,
490/10/3
MANGAL PANDEY NAGAR
VTC: Meerut,
PO: L. L. R. M. Med.college,
District: Meerut,
State: Uttar Pradesh,
PIN Code: 250004,
Mobile: 9997795277

05/03/2012

23570557



UA066269190IN



आपका आधार क्रमांक / Your Aadhaar No. :

8801 0792 6180

मेरा आधार, मेरी पहचान



भारत सरकार
Government of India



शुभम अग्रवाल
Shubham Agrawal
जन्म तिथि / DOB : 19/02/1992
पुरुष / MALE

05/03/2012

8801 0792 6180

मेरा आधार, मेरी पहचान

Shubham Agrawal

DR. MONIKA GARG
M.B.B.S. M.D. (P)
GARG PATHOLOGY

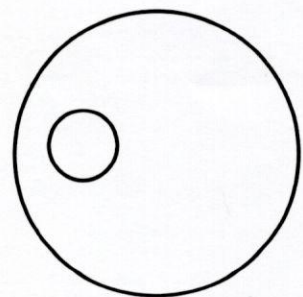
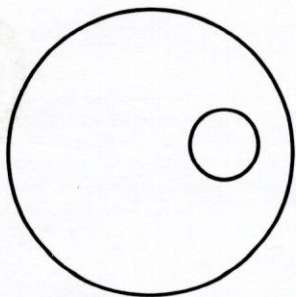
Vn $\left\{ \begin{array}{l} R \ 6/24P \\ L \ 6/12P \end{array} \right.$

PH $\left\{ \begin{array}{l} R \ 6/6 \\ L \ 6/6 \end{array} \right.$


IOP $\left\{ \begin{array}{l} R \ 19 \text{ mmHg} \\ L \ 16 \text{ mmHg} \end{array} \right.$

	RIGHT EYE				LEFT EYE			
	Sph.	Cyl.	Axis	Vision	Sph.	Cyl.	Axis	Vision
Distance	$\overline{+1.50}$	—		6/6	$\overline{-1.00}$	—		6/6
Near	—	—		N6	—	—		N6

(Colour vision Normal)



Dr. AMIT GARG
 M.B.B.S D.N.B.
 Garg Path. Meerut

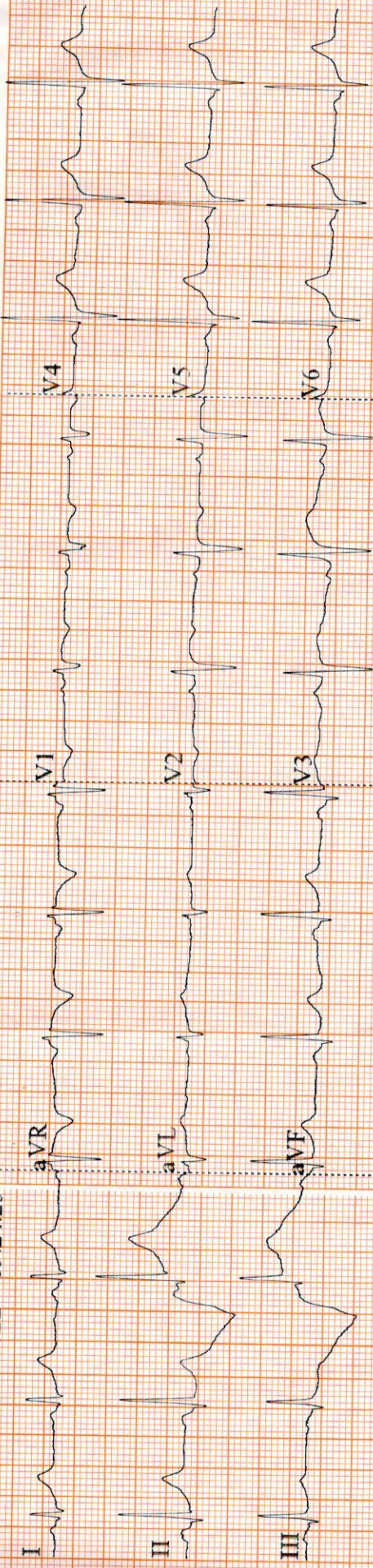


S. Agrawal

Mar 13, 2022 9:10:40 AM
Kalyan Nagar
Meerut
Uttar Pradesh

Dr. MONIKA GARG

ID: I77 13-03-2022 09:24:25



0.67~35Hz AC50 25mm/s 10mm/mV ♥73 V1.0 SEMIP V1.7
HEARIDPRINT

ID: 177

Male
 30Years
 cm

kPa

kg

HR : 78 bpm
 P : 104 ms
 PR : 131 ms
 QRS : 86 ms
 QT/QTc : 361/411 ms
 P/QRS/T : 59/71/43 °
 RV5/SV1 : 1.473/0.284 mV

Diagnosis Information:
 Sinus Rhythm
 Normal ECG

[Handwritten Signature]

Report Confirmed by:

DR. MONIKA GARG
 M.B.B.S. M.D. (Pathology)
 GARG PATHOLOGY

DATE	13.03.2022	REF. NO.	13369		
PATIENT NAME	SHUBHAM AGARWAL	AGE	30 YRS	SEX	M
INVESTIGATION	X-RAY CHEST PA VIEW	REF. BY	GARG (PATHOLOGY)		

REPORT

- Trachea is central in position.
- **Both lung show mildly prominent broncho vascular marking.**
- Cardiac size is within normal limits.
- Both costophrenic angles are clear.
- Both domes of diaphragm are normal in contour and position.

IMPRESSION

Both lung show mildly prominent broncho vascular marking.

Dr. P.D. Sharma
M.B.B.S., D.M.R.D. (VIMS & RC)
Consultant Radiologist and Head

1. Impression is a professional opinion & not a diagnosis
2. All modern machines & procedures have their limitations. if there is variance clinically this examination may be repeated or reevaluated by other investigations
Ps. All congenital anomalies are not picked upon ultrasounds.
3. Suspected typing errors should be informed back for correction immediately.
4. Not for medico-legal purpose. Identity of the patient cannot be verified.