


12

Name : Mr. Pravin Mahalava	Age : 30 Y	UHID :CVIM.0000235458
Address : pune	Sex : M	
Plan : ARCOFEMI MEDIWHEEL MALE AHC CREDIT PAN INDIA OP AGREEMENT		OP Number :CVIMOPV586963
		Bill No :CVIM-OCR-62385
		Date : 27.01.2024 09:08

Sno	Service Type/ServiceName	Department
1	ARCOFEMI - MEDIWHEEL - FULL BODY ANNUAL PLUS MALE - 2D ECHO - PAN INDIA - FY2324	
1	URINE GLUCOSE(FASTING)	
2	GAMMA GLUTAMYL TRANSFERASE (GGT)	
3	HbA1c, GLYCATED HEMOGLOBIN	
4	D ECHO	
5	LIVER FUNCTION TEST (LFT)	
6	X RAY CHEST PA	
7	GLUCOSE, FASTING	
8	HEMOGRAM + PERIPHERAL SMEAR	
9	DIET CONSULTATION	
10	FITNESS BY GENERAL PHYSICIAN	
11	DIET CONSULTATION	
12	COMPLETE URINE EXAMINATION	
13	URINE GLUCOSE(POST PRANDIAL)	
14	PERIPHERAL SMEAR	
15	ECG	
16	BLOOD GROUP ABO AND RH FACTOR	
17	LIPID PROFILE	
18	BODY MASS INDEX (BMI)	
19	OPHTHAL BY GENERAL PHYSICIAN	
20	RENAL PROFILE/RENAL FUNCTION TEST (RFT/KFT)	
21	ULTRASOUND - WHOLE ABDOMEN	
22	THYROID PROFILE (TOTAL T3, TOTAL T4, TSH)	
23	DENTAL CONSULTATION	
24	GLUCOSE, POST PRANDIAL (PP), 2 HOURS (POST MEAL)	

CERTIFICATE OF MEDICAL FITNESS

This is to certify that I have conducted the clinical examination

of Pravin Mahadava on 27/11/24

After reviewing the medical history and on clinical examination it has been found that he/she is

	Tick
<ul style="list-style-type: none">• Medically Fit	<input checked="" type="checkbox"/>
<ul style="list-style-type: none">• Fit with restrictions/recommendations <p>Though following restrictions have been revealed, in my opinion, these are not impediments to the job.</p> <p>1.....</p> <p>2.....</p> <p>3.....</p> <p>However the employee should follow the advice/medication that has been communicated to him/her.</p> <p>Review after _____</p>	
<ul style="list-style-type: none">• Currently Unfit. <p>Review after _____ recommended</p>	
<ul style="list-style-type: none">• Unfit	

Dr. Archana V.
Medical Officer
The Apollo Clinic, (Location)

This certificate is not meant for medico-legal purposes

Dr. Archana V. MBBS
Registration No. 103429

Date : 27-01-2024

Department : GENERAL

MR NO : CVIM.0000235458

Doctor :

Name : Mr. Pravin Mahadava

Registration No :

Age/ Gender : 30 Y / Male

Qualification :

Consultation Timing: 09:06

Height : 178	Weight : 75	BMI : 24	Waist Circum : 94
Temp : 97	Pulse : 80	Resp : 18	B.P : 110/70

General Examination / Allergies History

Clinical Diagnosis & Management Plan

O/E :

PE

CNS - NERVOUS

MS - NERVOUS

P/A - soft & (+)

(N) Bowel Habits

CNS - NERVOUS.

NO peripheral signs (+)

- NO specific complaints.
- NIK/26 DM/HTN/CAD
- family H/O - nil.

- Tests:
- Serum acid
 - Urine Panel.

Dr. Archana V. MBBS
Registration No. 103429


Doctor Signature

Follow up date:

ENT
HND

Height : 178	Weight : 75	BMI : 24	Waist Circum : 94
Temp : 97.5	Pulse : 80	Resp : 18	B.P : 110/70

General Examination / Allergies
History

Clinical Diagnosis & Management Plan

ENT]
HND

Follow up date:

Doctor Signature

Apollo Clinic, Viman Nagar

Nyati Millenium Premises, Cooperative Society Limited, Shop No. S1 & Stilt Floor,
Building "C", Viman Nagar, Pin: 411014 | Phone: (020) 2663 4331/32/34

Follow us  /ApolloClinicIndia  /ApolloClinics

BOOK YOUR APPOINTMENT TODAY!

Whatsapp Number : 970 100 3333

Toll Number : 1860 500 7788

Website : www.apolloclinic.com

EYE EXAMINATION

DATE: 27/1/20

NAME: Mr. Rameshappa Narsimha

AGE: 30

CORPORATE:

	Right Eye	Left Eye
Distant vision	6/6	6/6
Near vision	N/6	N/6
Color vision	Normal	Normal
Fundus examination	Normal	Normal
Intraocular pressure	Normal	Normal
Slit lamp exam.	Normal	Normal

[Handwritten Signature]

Impression - Normal Eye Check Up.

(Ophthalmology)

The Apollo Clinic
DR. M. D. ALAVAND
MBBS, D.O.M.S.
Consulting Eye Surgeon
Reg. No. - 36319



30 Years

MALE

27-08-99 9:34:04 AM

Rate 57
 PR 145
 QRSD 103
 QT 430
 QTc 419

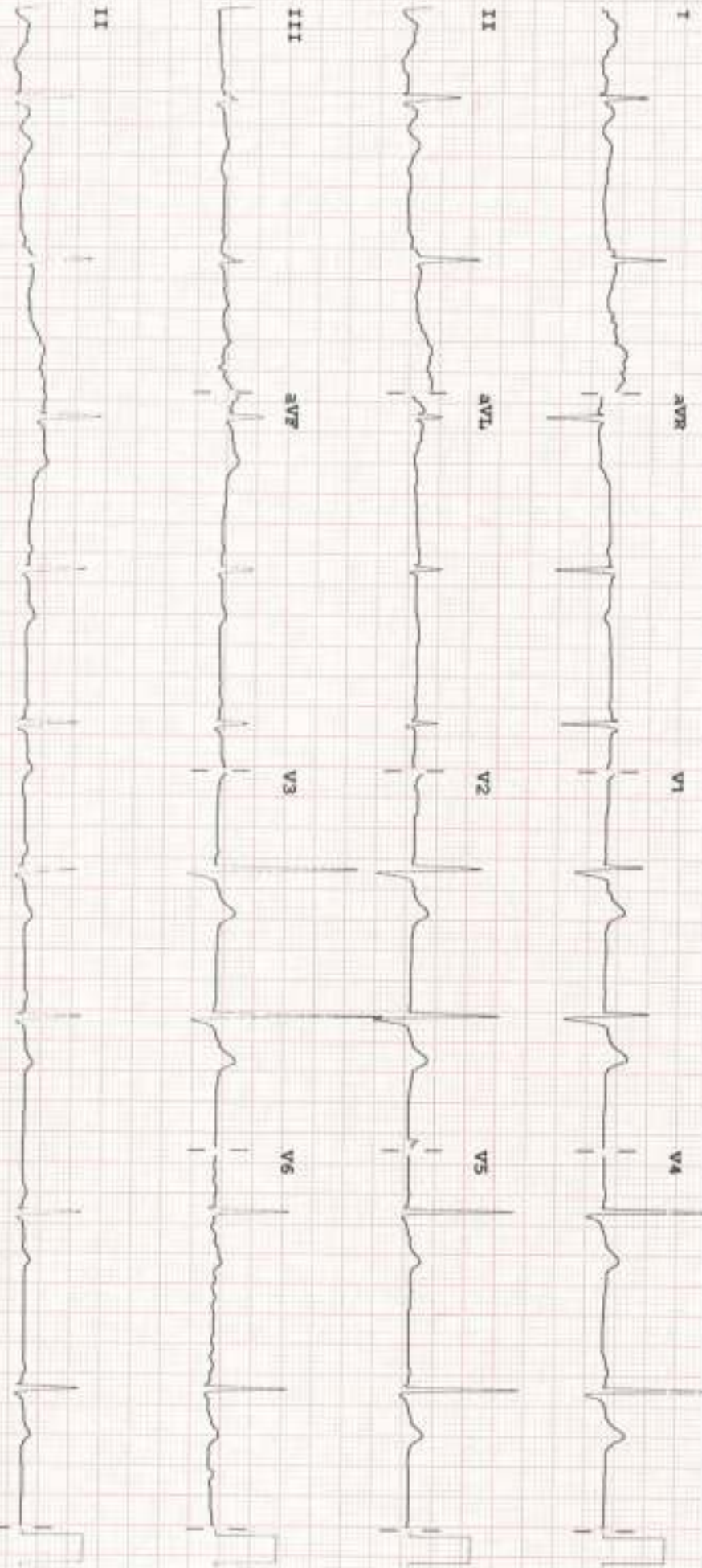
--AXIS--
 P 48
 QRS 56
 T 69

Stimulus rhythm
 Baseline vander in lead(s) II, aVR, V2, V3, V4, V5, V6

normal p axis, V-rate 50-99

- NORMAL ECG -

Unconfirmed Diagnosis



Device:

Speed: 25 mm/sec
 Lead: 10 mm/mV
 Chest: 10.0 mm/mV

F 50-0.50-40 Hz W

PH100B CL

PHILIPS

NECHROG KORTNA



Certificate No: MC-5697

Patient Name : Mr.PRAVIN MAHADAVA	Collected : 27/Jan/2024 09:34AM
Age/Gender : 30 Y 10 M 9 D/M	Received : 27/Jan/2024 12:58PM
UHID/MR No : CVIM.0000235458	Reported : 27/Jan/2024 02:03PM
Visit ID : CVIMOPV586963	Status : Final Report
Ref Doctor : Dr.SELF	Sponsor Name : ARCOFEMI HEALTHCARE LIMITED
Emp/Auth/TPA ID : 320605	

DEPARTMENT OF HAEMATOLOGY

ARCOFEMI - MEDIWHEEL - FULL BODY ANNUAL PLUS MALE - 2D ECHO - PAN INDIA - FY2324

PERIPHERAL SMEAR , WHOLE BLOOD EDTA

RBC's are Normocytic Normochromic,
WBC's are normal in number and morphology
Platelets are Adequate
No Abnormal cells/hemoparasite seen.



Sneha Shah
Dr Sneha Shah
MBBS, MD (Pathology)
Consultant Pathologist
SIN No:BED240019705

This test has been performed at Apollo Health and Lifestyle Ltd- Sadashiv Peth Pune, Diagnostics Lab



Certificate No: MC-5687

Patient Name : Mr.PRAVIN MAHADAVA	Collected : 27/Jan/2024 09:34AM
Age/Gender : 30 Y 10 M 9 D/M	Received : 27/Jan/2024 12:58PM
UHID/MR No : CVIM.0000235458	Reported : 27/Jan/2024 02:03PM
Visit ID : CVIMOPV586963	Status : Final Report
Ref Doctor : Dr.SELF	Sponsor Name : ARCOFEMI HEALTHCARE LIMITED
Emp/Auth/TPA ID : 320605	

DEPARTMENT OF HAEMATOLOGY

ARCOFEMI - MEDIWHEEL - FULL BODY ANNUAL PLUS MALE - 2D ECHO - PAN INDIA - FY2324

Sneha Shah

Dr Sneha Shah
MBBS, MD (Pathology)
Consultant Pathologist
SIN No:BED240019705



This test has been performed at Apollo Health and Lifestyle Ltd- Sadashiv Peth Pune, Diagnostics Lab



Certificate No: MC-5697

Patient Name : Mr.PRAVIN MAHADAVA	Collected : 27/Jan/2024 09:34AM
Age/Gender : 30 Y 10 M 9 D/M	Received : 27/Jan/2024 12:58PM
UHID/MR No : CVIM.0000235458	Reported : 27/Jan/2024 02:56PM
Visit ID : CVIMOPV586963	Status : Final Report
Ref Doctor : Dr.SELF	Sponsor Name : ARCOFEMI HEALTHCARE LIMITED
Emp/Auth/TPA ID : 320605	

DEPARTMENT OF HAEMATOLOGY

ARCOFEMI - MEDIWHEEL - FULL BODY ANNUAL PLUS MALE - 2D ECHO - PAN INDIA - FY2324

Test Name	Result	Unit	Bio. Ref. Range	Method
BLOOD GROUP ABO AND RH FACTOR , WHOLE BLOOD EDTA				
BLOOD GROUP TYPE	AB			Microplate Hemagglutination
Rh TYPE	Positive			Microplate Hemagglutination



DR. Sanjay Ingle
M.B.B.S, M.D(Pathology)
Consultant Pathologist

SIN No:BED240019705

This test has been performed at Apollo Health and Lifestyle Ltd- Sadashiv Peth Pune, Diagnostics Lab
Apollo Health and Lifestyle Limited (CIN - U80110PG2000PLC115010)

Regd. Office: 1-10-66K2, Ashoka Rajghatpathi Chambers, 5th Floor, Bagampet, Hyderabad, Telangana - 500 016 |
www.apolloh.com | Email: info@apolloh.com, Ph No: 040-4964 7777, Fax No: 4964 7744

APOLLO CLINICS NETWORK

Hyderabad | 05 Ban Nagar | Charita Nagar | Kamalapur | Nallakota | Bagampet | Marikonda | Uppal | Andhra Pradesh | Vizag (Sri Hanuman Pet) | Karnataka: Bangalore (Koramangala) | Bellary | Electronics City | Feroz Town | HSR Layout | Yeshi





Certificate No: MC-5687

Patient Name : Mr.PRAVIN MAHADAVA	Collected : 27/Jan/2024 01:25PM
Age/Gender : 30 Y 10 M 9 D/M	Received : 27/Jan/2024 04:02PM
UHID/MR No : CVIM.0000235458	Reported : 27/Jan/2024 04:49PM
Visit ID : CVIMOPV586963	Status : Final Report
Ref Doctor : Dr.SELF	Sponsor Name : ARCOFEMI HEALTHCARE LIMITED
Emp/Auth/TPA ID : 320605	

DEPARTMENT OF BIOCHEMISTRY

ARCOFEMI - MEDIWHEEL - FULL BODY ANNUAL PLUS MALE - 2D ECHO - PAN INDIA - FY2324

Test Name	Result	Unit	Bio. Ref. Range	Method
GLUCOSE, FASTING , NAF PLASMA	95	mg/dL	70-100	HEXOKINASE

Comment:

As per American Diabetes Guidelines, 2023

Fasting Glucose Values in mg/dL	Interpretation
70-100 mg/dL	Normal
100-125 mg/dL	Prediabetes
≥126 mg/dL	Diabetes
<70 mg/dL	Hypoglycemia

- Note:**
- The diagnosis of Diabetes requires a fasting plasma glucose of $>$ or $=$ 126 mg/dL and/or a random / 2 hr post glucose value of $>$ or $=$ 200 mg/dL on at least 2 occasions.
 - Very high glucose levels ($>$ 450 mg/dL in adults) may result in Diabetic Ketoacidosis & is considered critical.

Test Name	Result	Unit	Bio. Ref. Range	Method
GLUCOSE, POST PRANDIAL (PP), 2 HOURS , SODIUM FLUORIDE PLASMA (2 HR)	90	mg/dL	70-140	HEXOKINASE

Comment:

It is recommended that FBS and PPBS should be interpreted with respect to their Biological reference ranges and not with each other.

Conditions which may lead to lower postprandial glucose levels as compared to fasting glucose levels may be due to reactive hypoglycemia, dietary meal content, duration or timing of sampling after food digestion and absorption, medications such as insulin preparations, sulfonylureas, amylin analogues, or conditions such as overproduction of insulin.



DR. Senjay Ingle
M.B.B.S, M.D.(Pathology)
Consultant Pathologist

SIN No: PLP1412172

This test has been performed at Apollo Health and Lifestyle Ltd- Sadashiv Peth Pune, Diagnostics Lab
Apollo Health and Lifestyle Limited (CIN - URS118RG2000PLC115011)

Regd Office: 1-10-4092, Ashoka Nagar, 5th Floor, Begumpet, Hyderabad, Telangana - 500 016 |
www.apollo.com | Email ID: emp@apollo.com, Ph No: 9848947777, Fax No: 40047744

Hyd: Mitulim Premises, Cooperative Society Limited, Shop No. 51 & 5th Floor, Building 'C', Viman Nagar, Pune, Maharashtra, India - 411004



APOLLO CLINICS NETWORK

Hyderabad | Hyderabad GIC Ras Nagar | Chanda Nagar | Narayana | Nallakonda | Nizampet | Marolundhi | Uppal | Andhra Pradesh: Visakhapatnam | Karnataka: Bangalore (Basavanagudi) | Bellary | Electronics City | Feroz Town | HSR Layout | Indir

Certificate No: MC-5697

Patient Name : Mr.PRAVIN MAHADAVA	Collected : 27/Jan/2024 09:34AM
Age/Gender : 30 Y 10 M 9 D/M	Received : 27/Jan/2024 12:57PM
UHID/MR No : CVIM.0000235458	Reported : 27/Jan/2024 03:33PM
Visit ID : CVIMOPV586963	Status : Final Report
Ref Doctor : Dr.SELF	Sponsor Name : ARCOFEMI HEALTHCARE LIMITED
Emp/Auth/TPA ID : 320605	

DEPARTMENT OF BIOCHEMISTRY

ARCOFEMI - MEDIWHEEL - FULL BODY ANNUAL PLUS MALE - 2D ECHO - PAN INDIA - FY2324

Test Name	Result	Unit	Bio. Ref. Range	Method
HBA1C (GLYCATED HEMOGLOBIN) , WHOLE BLOOD EDTA				
HBA1C, GLYCATED HEMOGLOBIN	5.4	%		HPLC
ESTIMATED AVERAGE GLUCOSE (eAG)	108	mg/dL		Calculated

Comment:


Reference Range as per American Diabetes Association (ADA) 2023 Guidelines:

REFERENCE GROUP	HBA1C %
NON DIABETIC	<5.7
PREDIABETES	5.7 – 6.4
DIABETES	≥ 6.5
DIABETICS	
EXCELLENT CONTROL	6 – 7
FAIR TO GOOD CONTROL	7 – 8
UNSATISFACTORY CONTROL	8 – 10
POOR CONTROL	>10

Note: Dietary preparation or fasting is not required.

- HbA1C is recommended by American Diabetes Association for Diagnosing Diabetes and monitoring Glycemic Control by American Diabetes Association guidelines 2023.
- Trends in HbA1C values is a better indicator of Glycemic control than a single test.
- Low HbA1C in Non-Diabetic patients are associated with Anemia (Iron Deficiency/Hemolytic), Liver Disorders, Chronic Kidney Disease. Clinical Correlation is advised in interpretation of low Values.
- Falsely low HbA1c (below 4%) may be observed in patients with clinical conditions that shorten erythrocyte life span or decrease mean erythrocyte age. HbA1c may not accurately reflect glycemic control when clinical conditions that affect erythrocyte survival are present.
- In cases of Interference of Hemoglobin variants in HbA1C, alternative methods (Fructosamine) estimation is recommended for Glycemic Control
 - HbF >25%
 - Homozygous Hemoglobinopathy.
(Hb Electrophoresis is recommended method for detection of Hemoglobinopathy)

Page 6 of 15


 Dr Sneha Shah
 MBBS, MD (Pathology)
 Consultant Pathologist
 SIN No: EDT240008394

This test has been performed at Apollo Health and Lifestyle Ltd- Sadashiv Peth Pune, Diagnostics Lab



Certificate No: MC-5697

Patient Name : Mr.PRAVIN MAHADAVA	Collected : 27/Jan/2024 09:34AM
Age/Gender : 30 Y 10 M 9 DIM	Received : 27/Jan/2024 01:19PM
UHID/MR No : CVIM.0000235458	Reported : 27/Jan/2024 04:57PM
Visit ID : CVIMOPV586963	Status : Final Report
Ref Doctor : Dr.SELF	Sponsor Name : ARCOFEMI HEALTHCARE LIMITED
Emp/Auth/TPA ID : 320605	

DEPARTMENT OF BIOCHEMISTRY

ARCOFEMI - MEDIWHEEL - FULL BODY ANNUAL PLUS MALE - 2D ECHO - PAN INDIA - FY2324

Test Name	Result	Unit	Bio. Ref. Range	Method
LIVER FUNCTION TEST (LFT) , SERUM				
BILIRUBIN, TOTAL	0.59	mg/dL	0.3-1.2	DPD
BILIRUBIN CONJUGATED (DIRECT)	0.14	mg/dL	<0.2	DPD
BILIRUBIN (INDIRECT)	0.45	mg/dL	0.0-1.1	Dual Wavelength
ALANINE AMINOTRANSFERASE (ALT/SGPT)	12.79	U/L	<50	IFCC
ASPARTATE AMINOTRANSFERASE (AST/SGOT)	15.5	U/L	<50	IFCC
ALKALINE PHOSPHATASE	76.92	U/L	30-120	IFCC
PROTEIN, TOTAL	7.41	g/dL	6.6-8.3	Biuret
ALBUMIN	4.62	g/dL	3.5-5.2	BROMO CRESOL GREEN
GLOBULIN	2.79	g/dL	2.0-3.5	Calculated
A/G RATIO	1.66		0.9-2.0	Calculated

Comment:

LFT results reflect different aspects of the health of the liver, i.e., hepatocyte integrity (AST & ALT), synthesis and secretion of bile (Bilirubin, ALP), cholestasis (ALP, GGT), protein synthesis (Albumin)

Common patterns seen:

1. Hepatocellular Injury:

- AST – Elevated levels can be seen. However, it is not specific to liver and can be raised in cardiac and skeletal injuries.
- ALT – Elevated levels indicate hepatocellular damage. It is considered to be most specific lab test for hepatocellular injury. Values also correlate well with increasing BMI.
- Disproportionate increase in AST, ALT compared with ALP. • Bilirubin may be elevated.
- AST: ALT (ratio) – In case of hepatocellular injury AST: ALT > 1 In Alcoholic Liver Disease AST: ALT usually >2. This ratio is also seen to be increased in NAFLD, Wilson's diseases, Cirrhosis, but the increase is usually not >2.

2. Cholestatic Pattern:

- ALP – Disproportionate increase in ALP compared with AST, ALT.
- Bilirubin may be elevated. • ALP elevation also seen in pregnancy, impacted by age and sex.
- To establish the hepatic origin correlation with GGT helps. If GGT elevated indicates hepatic cause of increased ALP.

3. Synthetic function impairment:

- Albumin- Liver disease reduces albumin levels. • Correlation with PT (Prothrombin Time) helps.

Page 8 of 15



DR. Sanjay Ingle
M.B.B.S., M.D (Pathology)
Consultant Pathologist

SIN No: SE04610772

This test has been performed at Apollo Health and Lifestyle Ltd- Sadashiv Peth Pune, Diagnostics Lab
Apollo Health and Lifestyle Limited (CIN - U85110TG2000PLC115819)

Regd. Office: 1-10-66/52, Ashoka Raghupathi Chambers, 5th Floor, Begumpet, Hyderabad, Telangana - 500 016 |
www.apolloclinic.com | Email: Dr.sanjay@apollohd.com, Ph No: 040-4904 7777, Fax No: 4904 7744

APOLLO CLINICS NETWORK

Hyderabad | Hyderabad (AI) | Bani Nagar | Chennai | Bangalore | Kolkata | Vizag | Anandhra Pradesh | Vizag (Sri Venkateswara) | Karnataka: Bangalore (Basavanagudi) | Bellary | Electronics City | Feroz Nagar | HSR Layout | India



1860 500 778

www.apolloclinic.com



Certificate No: MC-5657

Patient Name	: Mr.PRAVIN MAHADAVA	Collected	: 27/Jan/2024 09:34AM
Age/Gender	: 30 Y 10 M 9 D/M	Received	: 27/Jan/2024 01:19PM
UHID/MR No	: CVIM.0000235458	Reported	: 27/Jan/2024 04:57PM
Visit ID	: CVIMOPV586963	Status	: Final Report
Ref Doctor	: Dr.SELF	Sponsor Name	: ARCOFEMI HEALTHCARE LIMITED
Emp/Auth/TPA ID	: 320605		

DEPARTMENT OF BIOCHEMISTRY

ARCOFEMI - MEDIWHEEL - FULL BODY ANNUAL PLUS MALE - 2D ECHO - PAN INDIA - FY2324

DR. Sanjay Ingle
M.B.B.S., M.D (Pathology)
Consultant Pathologist

SIN No: SE04610772

This test has been performed at Apollo Health and Lifestyle Ltd- Sadashiv Peth Pune, Diagnostics Lab
Apollo Health and Lifestyle Limited | CIN - U85110TG2000PLC1158195

Regd. Office: T-1D 48/62, Ashoka Raghupathi Chambers, 5th Floor, Ring Road, Hyderabad, Telangana - 500 014 |
www.apollohld.com | Email: info.apollo@apollohld.com, Ph No: 9440 4994 7777, Fax No: 4994 7744

APOLLO CLINICS MEDICALS

Locations: Hyderabad (M. Ban Nagar) | Charba Nagar | Kamalapur | Nallakunta | Nizampet | Madhavaram | Uppal | Andhra Pradesh: Vijay Durga Prasad Prasad Kaminika | Bangalore (Banashanagar) | Bellary | Durgam Cheruvu | Floor Town | HSR Layout | India





Certificate No: MC-5697

Patient Name : Mr.PRAVIN MAHADEVA	Collected : 27/Jan/2024 09:34AM
Age/Gender : 30 Y 10 M 9 D/M	Received : 27/Jan/2024 01:19PM
LHID/MR No : CVIM.0000235458	Reported : 27/Jan/2024 04:57PM
Visit ID : CVIMOPV586963	Status : Final Report
Ref Doctor : Dr.SELF	Sponsor Name : ARCOFEMI HEALTHCARE LIMITED
Emp/Auth/TPA ID : 320605	

DEPARTMENT OF BIOCHEMISTRY

ARCOFEMI - MEDIWHEEL - FULL BODY ANNUAL PLUS MALE - 2D ECHO - PAN INDIA - FY2324

Test Name	Result	Unit	Bio. Ref. Range	Method
GAMMA GLUTAMYL TRANSPEPTIDASE (GGT) , SERUM	15.43	U/L	<55	IFCC



DR. Sanjay Ingle
M.B.B.S, M.D(Pathology)
Consultant Pathologist

SIN No:SE04610772

This test has been performed at Apollo Health and Lifestyle Ltd- Sadashiv Peth Pune, Diagnostics Lab
Apollo Health and Lifestyle Limited (CIN - U05130TG2009PLC115810)

Legal Office: 1-18/60/62, Ashoka Bhagwanthi Chambers, 5th Floor, Bagamatti, Hyderabad, Telangana - 500 016 |
www.apollohd.com | Email ID: enquiry@apollohd.com, Ph No: 040-4804 7777, Fax No: 4804 7744

Nyati Bhiksham Prashant, Cooperative Society
Limited, Shop No 31 & 32nd Floor, Building 'C',
Western Nagar, Pune, Maharashtra, India - 411014





Certificate No: MC-5697

Patient Name : Mr.PRAVIN MAHADAVA	Collected : 27/Jan/2024 09:34AM
Age/Gender : 30 Y 10 M 9 DM	Received : 27/Jan/2024 03:51PM
UHID/MR No : CVIM.0000235458	Reported : 27/Jan/2024 04:06PM
Visit ID : CVIMOPV586963	Status : Final Report
Ref Doctor : Dr.SELF	Sponsor Name : ARCOFEMI HEALTHCARE LIMITED
Emp/Auth/TPA ID : 320605	

DEPARTMENT OF CLINICAL PATHOLOGY

ARCOFEMI - MEDIWHEEL - FULL BODY ANNUAL PLUS MALE - 2D ECHO - PAN INDIA - FY2324

Test Name	Result	Unit	Bio. Ref. Range	Method
URINE GLUCOSE(POST PRANDIAL)	NEGATIVE		NEGATIVE	Dipstick

DR. Sanjay Ingle
M.B.B.S, M.D(Pathology)
Consultant Pathologist

SIN No:UPP016319

This test has been performed at Apollo Health and Lifestyle Ltd- Sadashiv Peth Pune, Diagnostics Lab

Apollo Health and Lifestyle Limited | CIN - 1801107G2000PLC115819

Regd. Office: 1-10-40/92, Arkhika Rajbhagathi Chambers, 5th Floor, Begumpet, Hyderabad, Telangana - 500 016 |
www.apollohd.com | Email: @enquiry@apollohd.com, Ph No: 944-4904 7777, Fax No: 4904 7744

APOLLO CLINICS NETWORK

Locations: Hyderabad | 15 Raj Nagar | Clarks Road | Kharjapur | Anikurata | Nizampet | Marikonda | Uppal | Andhra Pradesh: Waag (Veerabhadra Puram) Karnataka: Bangalore (Basavanaguda) | Bellandur | Electronic City | Truster Town | MSR Layout | India



Patient Name : Mr. Pravin Mahadava Age : 30 Y M
UHID : CVIM.0000235458 OP Visit No : CVIMOPV586963
Reported on : 27-01-2024 11:04 Printed on : 27-01-2024 18:26
Adm/Consult Doctor : Ref Doctor : SELF

DEPARTMENT OF RADIOLOGY

X-RAY CHEST PA

X-RAY CHEST PA

Trachea appears normal.

Both the lung fields are clear.

Cardiac shadows appear apparently normal.

Both domes of diaphragm appear normal.

Both costophrenic angles are clear.

Bony thoracic cage shows no deformity. Visualised bones appear normal.

Soft tissues appear normal.

Impression: Essentially Normal Study.

Printed on:27-01-2024 11:04

---End of the Report---

Preeti
Dr. PREETI P KATHE
DMRE, MD, DNB
Radiology

Apollo Health and Lifestyle Limited

(CN - UB5110TG2000PLC115819)

Regd. Office: 1-10-60/62, Ashoka Raghupathi Chambers, 5th Floor, Begumpet, Hyderabad, Telangana - 500 016.

Ph No: 040-4904 7777, Fax No: 4904 7744 | Email ID: enquiry@apollohi.com | www.apollohi.com

APOLLO CLINICS NETWORK MAHARASHTRA

Pune (Aundh) | Kharadi | Nigdi Pradhikaran | Viman Nagar | Wanowrie

Online appointments: www.apolloclinic.com

Patient Name	: Mr. Pravin Mahadava	Age	: 30 Y M
UHID	: CVIM.0000235458	OP Visit No	: CVIMOPV586963
Reported on	: 27-01-2024 11:56	Printed on	: 27-01-2024 18:26
Adm/Consult Doctor	:	Ref Doctor	: SELF

DEPARTMENT OF RADIOLOGY

ULTRASOUND - WHOLE ABDOMEN

Liver appears normal in size and echotexture. No focal lesion is seen. PV and CBD normal. No dilatation of the intrahepatic biliary radicals.

Gall bladder is well distended. No evidence of calculus. Wall thickness appears normal. No evidence of periGB collection. No evidence of focal lesion is seen.

Spleen appears normal. No focal lesion seen. Splenic vein appears normal.

Pancreas appears normal in echopattern. No focal/mass lesion/calcification. No evidence of peripancreatic free fluid or collection. Pancreatic duct appears normal.

Both the kidneys appear normal in size, shape and echopattern. Cortical thickness and CM differentiation are maintained. No calculus / hydronephrosis seen on either side.

Urinary Bladder is well distended and appears normal. No evidence of any wall thickening or abnormality. No evidence of any intrinsic or extrinsic bladder abnormality detected.

Prostate is normal in size and echo texture. No evidence of necrosis/calcification seen.

Bowel loops and Retroperitoneum appear normal. Aorta and IVC appear normal. No abnormal lymphadenopathy noted.

IMPRESSION:-

No significant abnormality detected.

(The sonography findings should always be considered in correlation with the clinical and other investigation finding where applicable.) It is only a professional opinion, Not valid for medico legal purpose.

Patient Name : Mr. Pravin Mahadava
UHID : CVIM.0000235458
Reported on : 27-01-2024 11:56
Adm/Consult Doctor :

Age : 30 Y M
OP Visit No : CVIMOPV586963
Printed on : 27-01-2024 18:26
Ref Doctor : SELF

Printed on:27-01-2024 11:56

---End of the Report---

Preeti

Dr. PREETI P KATHE
DMRE, MD, DNB
Radiology

NO SAMPLE GIVEN

TO,
APOLLO CLINIC
VIMAN NAGAR

Dear sir / madam,

I am Pravin M. Nandkule working at

Company Name mediswheel

Have not given the 2D - Echo Sample do not wish given it.

I AGREE _____

UHID =

Pravin M. Nandkule
SIGN -