



भारत सरकार  
GOVERNMENT OF INDIA



Neelam Kaur  
Year of Birth: 1991  
Female



7961 9008 3107



**आधार** - आम आदमी का अधिकार



भारतीय विशिष्ट पहचान प्राधिकरण  
UNIQUE IDENTIFICATION AUTHORITY OF INDIA

Address:

D/O Mahesh Kumar, vil.pipal wai dhani  
post.bhorki via gudha goji, Bhorki, Bhorki,  
Jhunjhunun, Rajasthan - 333032




**सर्वे श्रेष्ठ**  
**सर्वप्रथम के सोम**  
 Name: Suresh  
 Year of Birth: 1981  
 Gender: Female

7961 9008 3107



सर्वत - सप्त सित्ती वर सप्तसप्त

  
**Rajasthan Diagnostic & Medical Research Centre**  
 Jhunjhunu

2062555368  
 @95555368


**राजस्थान डायग्नोस्टिक & मेडिकल रिसर्च सेंटर**  
**RAJASTHAN DIAGNOSTIC & MEDICAL RESEARCH CENTRE**

Address:  
 D-10, Market Square, 1st floor, 1st door,  
 post box no. 206255, Jhunjhunu, District,  
 Rajasthan, India-328022



16.11.2024 10:53:27  
RAJASTHANI DIAGNOSTIC CENTRE  
Sandra Nagar  
Jhunjhunu

Location:  
Room:  
Order Number:  
Indication:  
Medication 1:  
Medication 2:  
Medication 3:

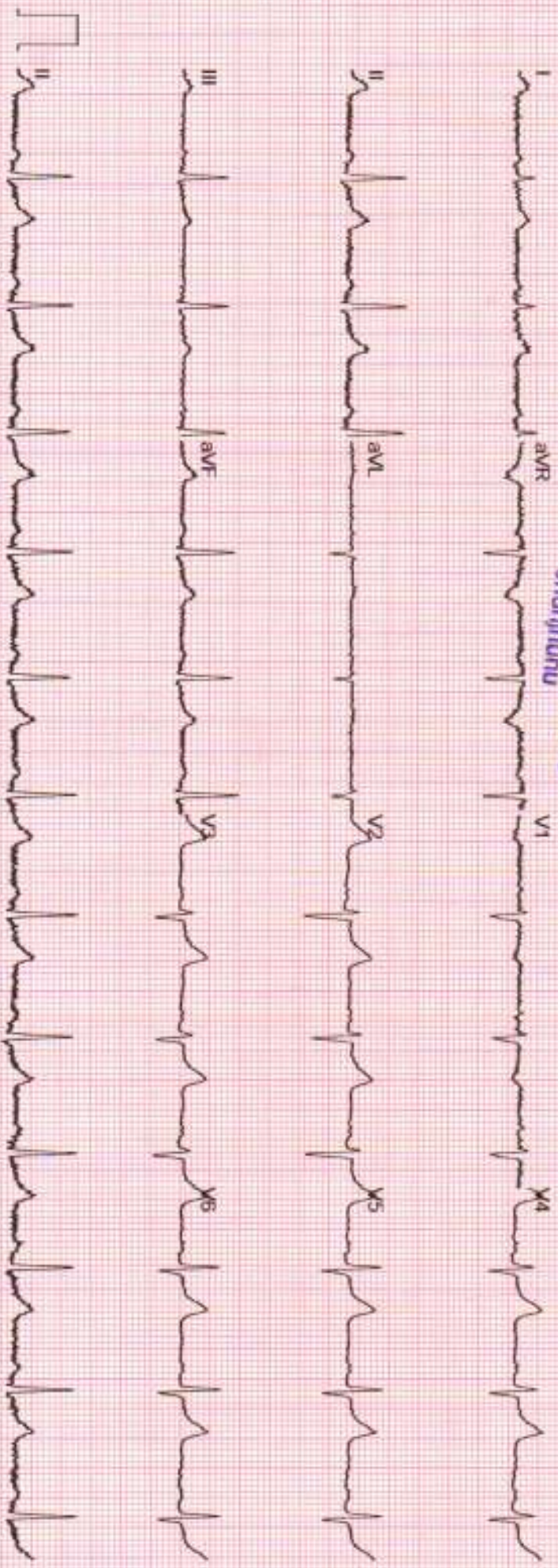
Female

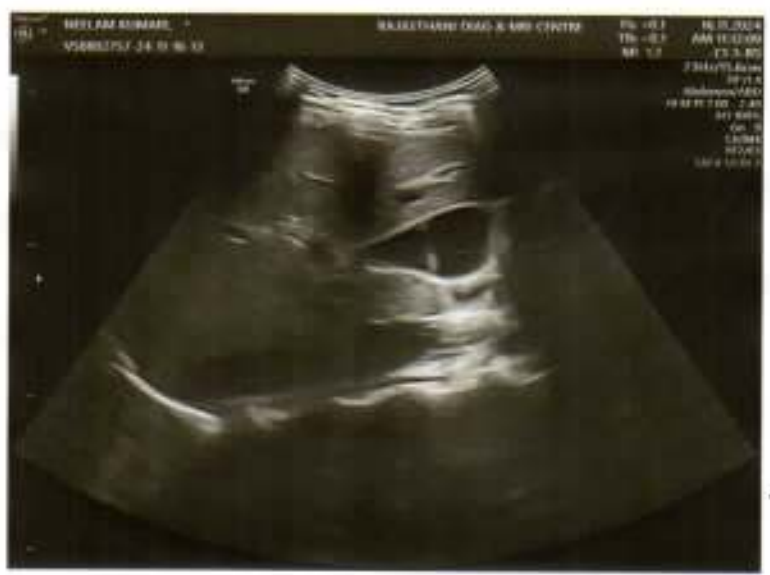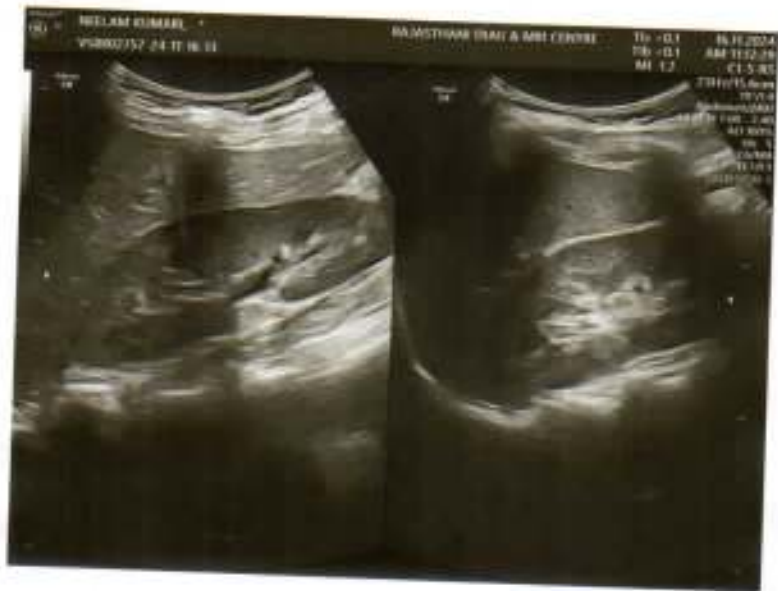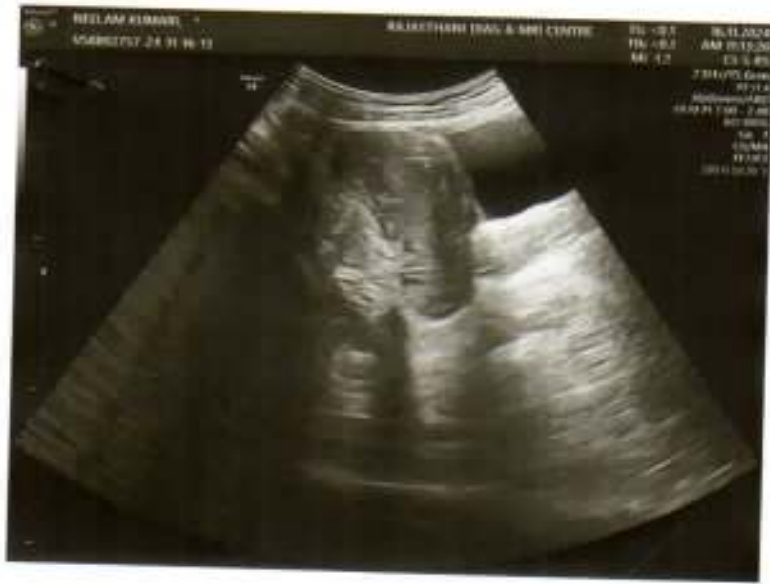Normal sinus rhythm  
Normal ECG

Technician  
Ordering Ph  
Referring Ph  
Attending Ph

QRS	76 ms
QT / QTd Baz	414 / 456 ms
PR	158 ms
P	98 ms
RR / PP	816 / 821 ms
P / QRS / T	56 / 77 / 63 degrees

*[Signature]*  
Rajasthan Diagnostic &  
Medical Research Centre  
Jhunjhunu







# RAJSTHANI DIAGNOSTIC & MR CENTRE

## FULLY COMPUTERISED PATHOLOGY LABORATORY

MRI

CT SCAN

TMT

SONOGRAPHY

X-RAY

ECG

MAMOGRAPHY

NAME	NEELAM KUMARI	AGE-	SEX: F
REF/BY:	BOB HEALTH CHECKUP	DATE	16-Nov-24

### ULTRASONOGRAPHY WHOLE ABDOMEN

**Liver:** is normal in size, shape and echotexture. No IHBR dilatation is seen. No focal mass seen. Portal vein and hepatic veins are normal in diameter. Common bile duct is normal in diameter and lumen is clear.

**Gall bladder:** is normal in size shape, location with echo free lumen. Wall thickness is normal. No echogenic shadow suggestive of calculus is seen. No focal mass or lesion is seen.

**Pancreas:** is normal in size, shape and echotexture. No focal mass or lesion is detected. Pancreatic duct is not dilated.

**Rt. Kidney:** is normal in size, shape, position and echotexture. Corticomedullary differentiation is well maintained. No evidence of definite calculus/ hydronephrosis is seen.

**Lt. Kidney:** is normal in size, shape, position and echotexture. Corticomedullary differentiation is well maintained. No evidence of definite calculus/ hydronephrosis is seen.

**Spleen:** is normal in size, regular in shape and echo texture. No focal lesion is seen. Splenic vessels are normal.

**Urinary Bladder:** is well distended. Outline of bladder is regular. Wall thickness is normal. No focal mass is seen. No echogenic shadow suggestive of calculus is seen.

**Uterus:** is normal in size, regular in shape and outline. Uterus is anteverted and ante flexed. Endometrium is normal in thickness. No sonolucent or echogenic mass lesion seen.

**Adenexa:** Both adenexal regions are seen normal. No focal mass or lesion is seen. Bilateral ovaries are normal in appearance.

No evidence of ascites is seen. No significant Lymphadenopathy is seen. No obvious bowel pathology is seen. Retroperitoneum including aorta, IVC are unremarkable.

### IMPRESSION:

❖ NORMAL SONOGRAPHY STUDY.

Advised: clinicopathological correlation

DR. ANUSHA MAHALAWAT  
MD RADIOLOGIST

Dr. Anusha Mahalawat  
MD (Radiodiagnosis)  
(RMC. 38742/25457)



THIS REPORT IS NOT VALID FOR MEDICO LEGAL PURPOSE





# RAJASTHANI DIAGNOSTIC & MR CENTRE

FULLY COMPUTERISED PATHOLOGY LABORATORY

MRI

CT SCAN

TMT

SONOGRAPHY

X-RAY

ECG

MAMOGRAPHY

Patient ID		Patient Name	NEELAM KUMARI
Age	33 Yrs	Date	16-Nov-24
Gender	FEMALE	Ref Doctor	SELF

## CHEST X RAY (PA VIEW)

### OBSERVATION:

Both lung fields appear clear.

Both costo-phrenic angles appear clear.

Cardiothoracic ratio is normal.

Both domes of diaphragm appear normal.

Thoracic soft tissue and skeletal system appear unremarkable.

### IMPRESSION:

➤ No Significant abnormality is noted.

ADVICE: Please Correlate Clinically.

*This Report is not valid for any medico legal purpose. This report is prepared on the basis of digital DICOM images transmitted via internet without identification of patient, not on the films or plates provided to the patient.*

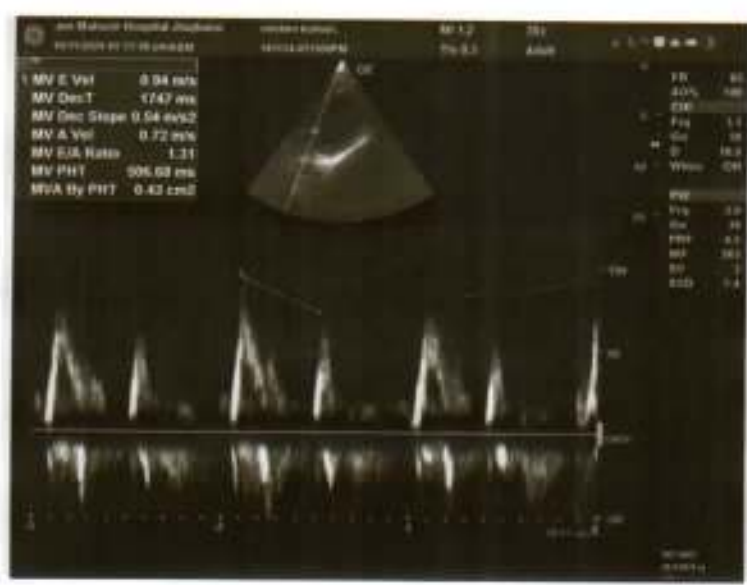
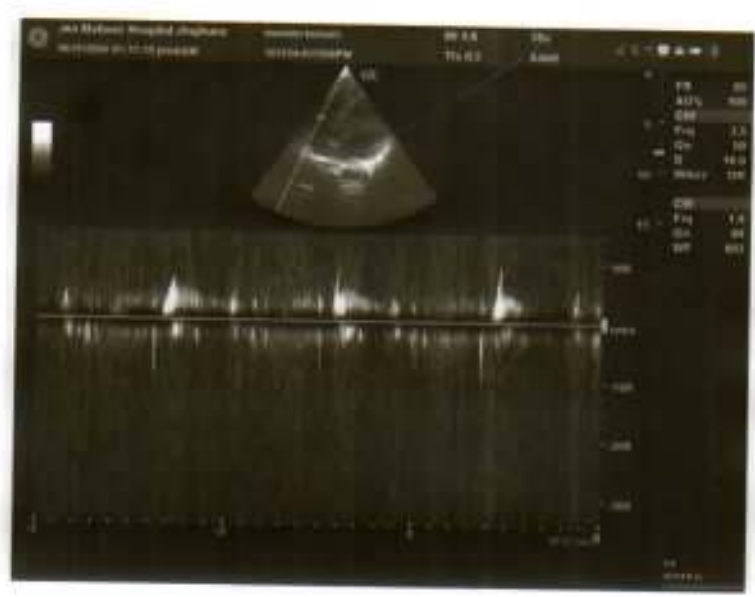
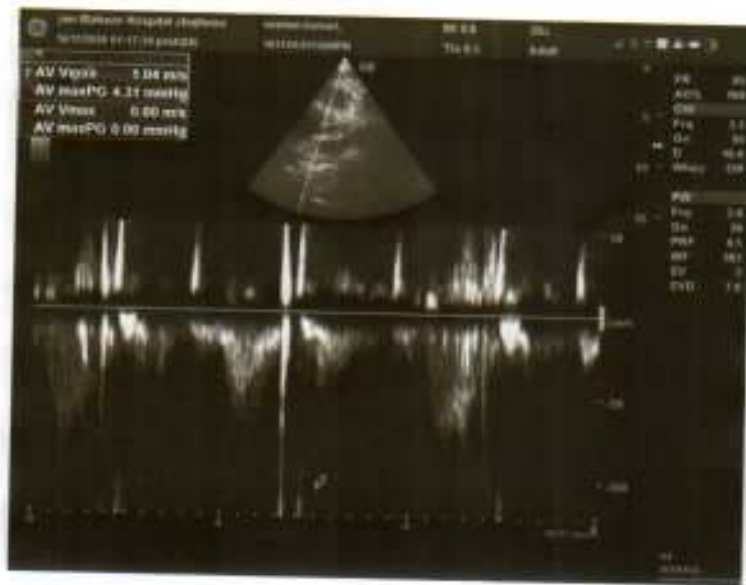
DR. BALAJI BALIRAM KALE  
MBBS, DMRD, DNB (Radiodiagnosis)  
Registration number - 2015063398

Disclaimer: - It is an online interpretation of medical imaging based on clinical data. All modern machines/procedures have their own limitation. If there is any clinical discrepancy, this investigation may be repeated or reassessed by other tests.



THIS REPORT IS NOT VALID FOR MEDICO LEGAL PURPOSE

B-110, Indra Nagar, Jhunjhunu (Raj.) Ph. No. 01592-294977







Name	: NEELAM KUMARI	Father/Husband	: VIJAY SINGH	IPD/OPD status	: OPD
Age/Sex	: 32 Y/Female	Reg. No.	: OutSide	Category	: CASH
Consultant	: M. S. MEEL	Accession No.	: 20241116024	Bed No.	: -
		BILL NO	: 2403160925	Date	: 16/11/2024 11:58:36 AM

## TRANSTHORACIC ECHO-DOPPLER TEST REPORT

### MITRAL VALVE-

**Morphology** AML-Normal/Thickening/Calcification/Flutter/Restricted mobility/SAM/Doming.  
PML-Normal/Thickening/Calcification/Prolapse/Fixed/Restricted Mobility/Flutter.

**Doppler- Normal/Abnormal**

Mitral E/A Velocity= 94/72 (cm/sec).

Mitral Regurgitation

Absent/Trace/Mild/Moderate/Severe.

Mitral Stenosis

Absent/Present.

### TRICUSPID VALVE-

**Morphology -Normal/Atresia/Thickening/Calcification/Prolapse/Doming.**

**Doppler- Normal/Abnormal**

Tricuspid Regurgitation

Absent/Trace/Mild/Moderate/Severe.

Tricuspid Stenosis

Absent/Present.

### PULMONARY VALVE-

**Morphology -Normal/Atresia/Thickening/Doming/Vegetation.**

**Doppler- Normal/Abnormal**

Pulmonary Velocity = 79 (cm/sec)

Pulmonary Regurgitation

Absent/Trace/Mild/Moderate/Severe.

Pulmonary Stenosis

Absent/Present.

### AORTIC VALVE-

**Morphology -Normal/Thickening/Calcification/Flutter/Sclerosis/Doming.**

**No of Cusps- 1/2/3.**

**Doppler- Normal/Abnormal**

Aortic Velocity = 104 (cm/sec)

Aortic Regurgitation

Absent/Trace/Mild/Moderate/Severe.

Aortic Stenosis

Absent/Present.

Aorta = 2.6cm (2.0 - 3.7cm)

Left-Atrium = 4.5 cm (1.9 - 4.0 cm)

LV measurement

Diastole

Systole

IVS

0.6 cm (0.6-1.1cm)

0.9 cm

LVID

5.4 cm (3.7-5.6cm)

3.5 cm (2.2 - 4.0 cm)

LVPW

1.06 cm (0.6-1.1cm)

1.09 cm

LV

Normal/Enlarged/Clear/Thrombus/Hypertrophy.

Contraction Normal/Reduced.

Regional wall motion abnormality : Present/Absent.

LA Normal/Enlarged/Clear/Thrombus.

RA Normal/Enlarged/Clear/Thrombus.

RV Normal/Enlarged/Clear/Thrombus.



# MAHAVIR HOSPITAL

Health & Hygiene

D-15, Indira Nagar, Subhash Marg, JHUNJHUNU (Raj.)



Tel. : 01592-232361  
9680960962

MAHAVIR HOSPITAL

## COMMENTS & SUMMARY-

**ECHO window-Good/Fair/Poor.**

No regional wall motion abnormality seen, LVEF=55%.

Normal cardiac chamber dimensions seen.

Mild MR, trace TR, no PAH,

Normal systolic function.

Normal diastolic function.

No I/C clot/vegetation.

Intact IAS/IVS & No CoA, no pericardial effusion.

Dr M S Meel  
MD Medicine  
Senior Physician

Dr Pallavi Choudhary  
MD Paediatrics  
Consultant



This report is not valid for medico-legal purposes.  
No Part of this report should be reproduced for any purpose

( कृपया अपनी पुरानो रिपोर्ट साथ लावे )

यह रिपोर्ट केवल चिकित्सा के लिए है। इसे कानून के उद्देश्यों के लिए प्रयोग नहीं किया जा सकता है।  
कृपया अपनी पुरानी रिपोर्ट साथ लाएं।



# MAHAVIR HOSPITAL

Health & Hygiene

D-15, Indira Nagar, Subhash Marg, JHUNJHUNU (Raj.)



Tel. : 01592-232361  
9680960962

MAHAVIR HOSPITAL

## COMMENTS & SUMMARY-

**ECHO window-Good/Fair/Poor.**

No regional wall motion abnormality seen, LVEF=55%.

Normal cardiac chamber dimensions seen.

Mild MR, trace TR, no PAH.

Normal systolic function.

Normal diastolic function.

No I/C clot/vegetation.

Intact IAS/IVS & No CoA, no pericardial effusion.

Dr M S Meel  
MD Medicine  
Senior Physician

Dr Pallavi Choudhary  
MD Paediatrics  
Consultant



This report is not valid for medico-legal purposes.

No Part of this report should be reproduced for any purpose

( कृपया अपनी पुरानी रिपोर्ट साथ लावें )

यह रिपोर्ट केवल चिकित्सा के लिए है। इसे कानून के उद्देश्यों के लिए प्रयोग नहीं किया जाना चाहिए।



# RAJASTHANI DIAGNOSTIC & MRI CENTRE



FULLY COMPUTERISED PATHOLOGY LABORATORY

MRI CT SCAN TMT SONOGRAPHY X-RAY ECG MAMOGRAPHY

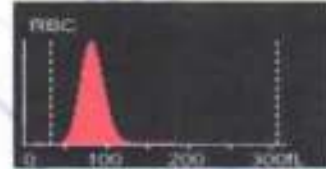
NABL CERTIFICATE NO.  
MC-5346

## Hematology Analysis Report

First Name: NEELAM KUMARI  
Last Name: Sample Type:  
Gender: Female Department:  
Age: 33 Year Med Rec. No.:

Sample ID: 7  
Test Time: 16/11/2024 11:12  
Diagnosis:

Parameter	Result		Ref. Range	Unit
1 WBC	4.07		4.00-10.00	10 <sup>3</sup> /uL
2 Neu%	43.6	L	50.0-70.0	%
3 Lym%	46.3	H	20.0-40.0	%
4 Mon%	7.8		3.0-12.0	%
5 Eos%	1.8		0.5-5.0	%
6 Bas%	0.5		0.0-1.0	%
7 Neu#	1.77	L	2.00-7.00	10 <sup>3</sup> /uL
8 Lym#	1.89		0.80-4.00	10 <sup>3</sup> /uL
9 Mon#	0.32		0.12-1.20	10 <sup>3</sup> /uL
10 Eos#	0.07		0.02-0.50	10 <sup>3</sup> /uL
11 Bas#	0.02		0.00-0.10	10 <sup>3</sup> /uL
12 RBC	4.01		3.50-5.50	10 <sup>6</sup> /uL
13 HGB	9.8	L	11.0-16.0	g/dL
14 HCT	35.0	L	37.0-54.0	%
15 MCV	87.4		80.0-100.0	fL
16 MCH	24.5	L	27.0-34.0	pg
17 MCHC	28.1	L	32.0-36.0	g/dL
18 RDW-CV	14.2		11.0-16.0	%
19 RDW-SD	51.7		35.0-56.0	fL
20 PLT	262		100-300	10 <sup>3</sup> /uL
21 MPV	10.1		6.5-12.0	fL
22 PDW	12.0		9.0-17.0	fL
23 PCT	0.266		0.108-0.282	%
24 P-LCR	36.9		11.0-45.0	%
25 P-LCC	97	H	30-90	10 <sup>3</sup> /uL



*Mamta Khuteta*  
Dr. Mamta Khuteta  
M.D. (Path.)  
RMC No : 4720/16260

Submitter: Operator: admin Approver:  
Draw Time: 16/11/2024 11:11 Received Time: 16/11/2024 11:11 Validated Time:  
Report Time: 17/11/2024 12:48 Remarks:

\*The Report is responsible for this sample only. If you have any questions, please contact us in 24 hours



THIS REPORT IS NOT VALID FOR MEDICO LEGAL PURPOSE





# RAJASTHANI DIAGNOSTIC & MRI CENTRE



## FULLY COMPUTERISED PATHOLOGY LABORATORY

MRI CT SCAN TMT SONOGRAPHY X-RAY ECG MAMOGRAPHY

NABL CERTIFICATE NO.  
MC-5346

Patient Name: <b>NEELAM KUMARI</b> Sr. No. : <b>15746</b> Patient ID No.: <b>11831</b> Age : <b>33</b> Gender : <b>FEMALE</b> Ref. By Dr : <b>MEDI-WHEEL HEALTH CHECKUP</b>		Registered on : <b>16-11-2024 11:11 AM</b> Collected On : <b>16-11-2024 11:11 AM</b> Received On : <b>16-11-2024 11:11 AM</b> Reported On : <b>17-11-2024 12:49 PM</b> Bar Code  LIS Number <b>7 0 4 8</b>
---	---	--

### LIPID PROFILE COMPLETE

Test Name	Observed Values	Units	Reference Intervals
Cholesterol <small>(Method: CHOD-PAP)</small>	169.00	mg/dL	Adults- Desirable: <200 Borderline: 200-239 High: >239 Children- Desirable: <170 Borderline: 170-199 High: >199
HDL Cholesterol	45.00	mg/dL	35-88
Triglycerides <small>(Method: GPO)</small>	114.00	mg/dL	Recommended triglycerides levels for adults: Normal <161 High: 161-199 Hypertriglycerdemic: 200-499 Very high: >499
LDL Cholesterol	101.20	mg/dL	0-150
VLDL Cholesterol	22.80	mg/dL	0-35
TC/HDL Cholesterol Ratio	3.76	Ratio	2.5-5
LDL/HDL Ratio	2.25	Ratio	1.5-3.5

### HAEMATOLOGY

Test Name	Observed Values	Units	Reference Intervals
ESR (Erythrocyte Sedimentation Rate)	15	mm/hr	20
BLOOD GROUPING (ABO & Rh )	A+ Positive		

*Ashish Sethi*  
Dr. Ashish Sethi  
Consultant Biochemist



PATHOLOGIST

*Hansi Shrivastava*  
Dr. Hansi Shrivastava  
MD (Path)  
Senior Pathologist

PATHOLOGIST



This Reports is Not Valid For Medico Legal Purposes. \* Identification and name of person is not our responsibility.  
No part of this report should be re-used. THIS REPORT IS NOT VALID FOR MEDICO LEGAL PURPOSES. Age, sex effect of drug and other relevant factor

**B-110, Indra Nagar, Jhunjhunu (Raj.) Ph. No. 01592-294977**



# RAJASTHANI DIAGNOSTIC & MRI CENTRE



FULLY COMPUTERISED PATHOLOGY LABORATORY

MRI CT SCAN TMT SONOGRAPHY X-RAY ECG MAMOGRAPHY

NABL CERTIFICATE NO  
MC-5346

Patient Name: **NEELAM KUMARI**  
Sr. No. : **15746**  
Patient ID No. : **11831**  
Age : **33** Gender : **FEMALE**  
Ref. By Dr : **MEDI-WHEEL HEALTH CHECKUP**



Registered on : **16-11-2024 11:11 AM**  
Collected On : **16-11-2024 11:11 AM**  
Received On : **16-11-2024 11:11 AM**  
Reported On : **17-11-2024 12:49 PM**  
Bar Code   
LIS Number **7 0 4 0**

## HAEMATOLOGY

### HbA1c(Glycosylated hemoglobin)

Test Name	Observed Values	Units	Reference Intervals
HbA1c(Glycosylated hemoglobin)	5.00	%	< 6.50 Non-Diabetic 6.50 - 7.00 Very Good Control 7.10 - 8.00 Adequate Control 8.10 - 9.00 Suboptimal Control 9.10 - 10.00 Diabetic Poor Control > 10.00 Very Poor Control
eAG (Estimated Average Glucose)	96.80	mg/dL	
eAG (Estimated Average Glucose)	5.37	mmol/L	

Method : Fluorescence Immunoassay Technology

Sample Type : EDTA Blood

Test Performed by:-

Fully Automated (EM 200 ) ERBA MANNHEIM.


#### Remarks :

Glycosylated Hemoglobin Testing is Recommended for both (a) Checking Blood Sugar Control in People who might be Pre-Diabetic. (b) Monitoring Blood Sugar Control in patients in more elevated levels, termed Diabetes Mellitus. The American Diabetic Association suggests that the Glycosylated Hemoglobin Test be Performed atleast Two Times in Year in Patients with Diabetes that are meeting Treatment Goals (and That have stable glycemic Control) and Quarterly in Patients with Diabetes whos therapy has changed or that are not meeting Glycemic Goals.

Glycosylated Hemoglobin measurement is not appropriate where there has been change in diet or Treatment within 6 Weeks. Hence people with recent Blood Loss, Hemolytic Aneamia, or Genetic Differences in the Hemoglobin Molecule (Hemoglobinopathy) such as Sickle-cell Disease and other Conditions, as well as those that have donated Blood recently, are not suitable for this Test.

  
Dr. Ashish Sethi  
Consultant Biochemist

**24/7**  
EMERGENCY SERVICE  
PATHOLOGIST

  
Dr. Nitesh Gupta  
Consultant Biochemist

PATHOLOGIST



This Reports is Not Valid For Medical Legal Purposes. \*Identification and name of person is not our responsibility.  
No part of this report should be re-used. THIS REPORT IS NOT VALID FOR MEDICO LEGAL PURPOSES. Age, sex effect of drug and other relevant factor

**B-110, Indra Nagar, Jhunjhunu (Raj.) Ph. No. 01592-294977**



# RAJASTHANI DIAGNOSTIC & MRI CENTRE



FULLY COMPUTERISED PATHOLOGY LABORATORY

MRI CT SCAN TMT SONOGRAPHY X-RAY ECG MAMOGRAPHY

NABL CERTIFICATE NO. MC-5346

Patient Name: **NEELAM KUMARI**  
Sr. No. : 15746  
Patient ID No.: 11831  
Age : 33 Gender : FEMALE  
Ref. By Dr : MEDI-WHEEL HEALTH CHECKUP



Registered on : 16-11-2024 11:11 AM  
Collected On : 16-11-2024 11:11 AM  
Received On : 16-11-2024 11:11 AM  
Reported On : 17-11-2024 12:49 PM  
Bar Code :   
LIS Number : 7 8 4 8

### BIO-CHEMISTRY

Test Name	Observed Values	Units	Reference Intervals
Glucose Fasting (Method: GOD-POD)	94.00	mg/dL	Glucose Fasting Cord: 45-96 New born, 1d: 40-60 New born, >1d: 50-80 Child: 60-100 Adult: 74-100 >60 Y: 82-115 >90 Y: 75-121
Blood Sugar PP (Method: GOD-POD)	112.00	mg/dL	Glucose 2 h Postprandial: <120

### KIDNEY FUNCTION TEST

Test Name	Observed Values	Units	Reference Intervals
Blood Urea (Method: Ureaase-GLDH)	24.00	mg/dL	Adults Women < 50 years : 13-40 Women > 50 years : 21-43 Men < 50 years : 19-45 Men > 50 years : 18-55 Children 1-3 years : 11-36 4-13 years : 15-36 13-19 years : 18-45
Creatinine (Method: Spectro-Overasease)	0.89	mg/dL	0.4-1.40
Calcium	9.88	mg/dL	8.5-11
Uric Acid (Method: Uricase-POD)	4.15	mg/dL	2.4-7.2

*Ashish Sehi*  
Dr. Ashish Sehi  
Consultant Biochemist



*Kamini Dahiya*  
Dr. Kamini Dahiya  
M.D. Path.  
D.O. No. 14719/2024



This Reports is Not Valid For Medico Legal Purposes. \* Identification and name of person is not our responsibility. No part of this report should be re-used. THIS REPORT IS NOT VALID FOR MEDICO LEGAL PURPOSES. Age, sex effect of drug and other relevant factor.



# RAJASTHANI DIAGNOSTIC & MRI CENTRE



FULLY COMPUTERISED PATHOLOGY LABORATORY

MRI CT SCAN TMT SONOGRAPHY X-RAY ECG MAMOGRAPHY

NABL CERTIFICATE NO.  
MC-5346

Patient Name: **NEELAM KUMARI**  
Sr. No. : **15746**  
Patient ID No.: **11831**  
Age : **33** Gender : **FEMALE**  
Ref. By Dr. : **MEDI-WHEEL HEALTH CHECKUP**



Registered on : **16-11-2024 11:11 AM**  
Collected On : **16-11-2024 11:11 AM**  
Received On : **16-11-2024 11:11 AM**  
Reported On : **17-11-2024 12:49 PM**  
Bar Code   
LIS Number **7 8 4 6**

## BIO-CHEMISTRY Liver Function Test

Test Name	Observed Values	Units	Reference Intervals
SGOT/AST(Tech.-UV Kinetic)	36.00	U/L	5-40
SGPT/ALT(Tech.-UV Kinetic)	25.00	U/L	5-40
Bilirubin(Total) (Method: BRET)	0.78	mg/dL	Adults: 0-2, Cord < 2 Newborns, premature 0-1 day 1-8, 1-2 days: 6-12, 3-5 days 10-14 Newborns, full term 0-1 day: 2-8, 1-2 days: 6-10, 3-5 days: 4-8
Bilirubin(Direct)	0.15	mg/dL	0-0.3
Bilirubin(Indirect)	0.63	mg/dL	0.1-1.0
Total Protein (Method: BIURET Method)	7.01	g/dL	Adults: 6.4 - 8.3 Premature: 3.6 - 6.0 Newborn: 4.6 - 7.0 1 Week: 4.4 - 7.6 7-12 months: 5.1 - 7.3 1-2 Years: 5.8 - 7.5 > 2 Years: 6.0 - 8.0
Albumin(Tech.-BCG) (Method: BCG)	3.90	gm/dL	0-4 days: 2.8-4.4 4d-14 yrs: 3.8-5.4 14y-18y: 3.2-4.5 Adults 20-60 yrs: 3.5-5.2 60-90 yrs: 3.2-4.6
Globulin(CALCULATION)	3.11	gm/dL	2.5-4.5
A/G Ratio(Tech.-Calculated)	1.25		1.2 - 2.5
Alkaline Phosphatase(Tech.-Pnp Amp Kinetic)	214.00	U/L	108-306

*Ashish Sethi*  
Dr. Ashish Sethi  
Consultant Biochemist



PATHOLOGIST

*Neelam Kumari*  
Dr. Neelam Kumari  
MD (Path)  
MBBS, DNB (Path)



PATHOLOGIST

This Report is Not Valid For Medical Legal Purposes. \* Identification and name of person is not our responsibility.  
No part of this report should be re-used. THIS REPORT IS NOT VALID FOR MEDICO LEGAL PURPOSE. Age, sex effect of drug and other relevant factor

**B-110, Indra Nagar, Jhunjhunu (Raj.) Ph. No. 01592-294977**





# RAJASTHANI DIAGNOSTIC & MRI CENTRE



FULLY COMPUTERISED PATHOLOGY LABORATORY

MRI CT SCAN TMT SONOGRAPHY X-RAY ECG MAMOGRAPHY

NABL CERTIFICATE NO.  
MC-S346

Patient Name: **NEELAM KUMARI**  
Sr. No. : 15746  
Patient ID No.: 11831  
Age : 33 Gender : FEMALE  
Ref. By Dr : MEDI-WHEEL HEALTH CHECKUP



Registered on : 16-11-2024 11:11 AM  
Collected On : 16-11-2024 11:11 AM  
Received On : 16-11-2024 11:11 AM  
Reported On : 17-11-2024 12:49 PM  
Bar Code   
LIS Number : 7 8 4 8

## THYROID HORMONES T3,T4,TSH (THYROID PROFILE)

Test Name	Observed Values	Units	Reference Intervals
T3 (Total Triiodothyronine)	0.89	ng/mL	0.6 - 1.8 ng/mL
T4 (Total Thyroxine)	8.50	µg/dL	4.60-12.50 µg/dL
TSH (Thyroid Stimulating Hormone)	1.69	µIU/mL	0.35-5.50

Sample Type : Serum

Test Performed by:-

Fully Automated Chemi Luminescent Immuno Assay (ARCHITECT- i1000 PLUS ) Abbott USA

Remarks :

Primary malfunction of the Thyroid gland may result in excessive (hyper) or Low (hypo) release of T3 or T4. In addition, as TSH directly affect thyroid function, malfunction of the pituitary or the hypothalamus influences the thyroid gland activity

Disease in any portion of the thyroid-pituitary-hypothalamus system may influence the level of T3 and T4 in the blood. In Primary Hypothyroidism, TSH levels are significantly elevated, while in secondary and tertiary hypothyroidism, TSH levels may be low. In addition, in Euthyroid sick syndrome, multiple alterations in serum thyroid function test findings have been recognized.

  
Dr. Ashish Sethi  
Consultant Biochemist

**24/7**  
EMERGENCY SERVICE  
PATHOLOGIST

  
Dr. Anurag Gupta  
MD, DNB (Gen. Med.)  
MBBS, DGO, DCH, DDM

PATHOLOGIST



This Reports is Not Valid For Medico Legal Purpose. Identification and name of person is not our responsibility.  
No part of this report should be reproduced in any form without the prior written permission of the laboratory. THIS REPORT IS NOT VALID FOR MEDICO LEGAL PURPOSE. Age, sex effect of drug and other relevant factor.

**B-110, Indra Nagar, Jhunjhunu (Raj.) Ph. No. 01592-294977**



# RAJASTHANI DIAGNOSTIC & MRI CENTRE




FULLY COMPUTERISED PATHOLOGY LABORATORY

MRI CT SCAN TMT SONOGRAPHY X-RAY ECG MAMOGRAPHY

NABL CERTIFICATE NO.  
MC-5346

Patient Name: **NEELAM KUMARI**  
Sr. No. : 15746  
Patient ID No.: 11831  
Age : 33 Gender : **FEMALE**  
Ref. By Dr : **MEDI-WHEEL HEALTH CHECKUP**



Registered on : 16-11-2024 11:11 AM  
Collected On : 16-11-2024 11:11 AM  
Received On : 16-11-2024 11:11 AM  
Reported On : 17-11-2024 12:49 PM  
Bar Code   
LIS Number 7 6 4 0

## URINE EXAMINATION URINE COMPLETE

Test Name	Observed Values	Units	Reference Intervals
<b>PHYSICAL</b>			
Quantity	20	ml	
Colour	Pale Yellow		
Appearance / Transparency	Clear		
Specific Gravity	1.020		
PH	6.0		4.5-8.5
<b>CHEMICAL</b>			
Reaction	Acidic		
Albumin	trace		
Urine Sugar	Nil		
<b>MICROSCOPIC</b>			
Red Blood Cells	Nil	/h.p.f.	
Pus Cells	3-5	/h.p.f.	
Epithelial Cells	1-2	/h.p.f.	
Crystals	Nil	/h.p.f.	
Casts	Nil	/h.p.f.	
Bactria	Nil	/h.p.f.	
Others	Nil	/h.p.f.	
Test Name	Observed Values	Units	Reference Intervals
URINE SUGAR FASTING	Nil		
URINE SUGAR PP	Nil		

<<< END OF REPORT >>>

>>> Results relate only to the sample as received. Kindly correlate with clinical condition. <<<

Note: This report is not valid for medico legal purposes.

Dr. Ashish Sethi  
Consultant Biochemist

**24/7**  
EMERGENCY SERVICE  
PATHOLOGIST

Ujjwal Health  
24x7 Service  
2024

PATHOLOGIST 

This Reports is Not Valid For Medico Legal Purpose and Identification and name of person is not our responsibility.

No part of this report should be reproduced for any purpose. Interpret result after considering Age, sex effect of drug and other relevant factor.

**B-110, Indra Nagar, Jhunjhunu (Raj.) Ph. No. 01592-294977**