



# PARKLINE DIAGNOSTICS PVT. LTD.

L.G. 3, 4 & 5, Bhuvana Towers, S.D. Road, Secunderabad - 500 003

Tel : +91 40-42038139, 2784 5852, 7995421787, 7093445852

Email parklinediagnostics@gmail.com www.parklinediagnostics.com



NABL Accredited  
Certificate No. MC-2566

## MEDICAL EXAMINATION REPORT

Name	M. Nrusimhadevara Venkate Satya Sandeep		Date	16/9/29
Company	c/o Mediwhel		Reg. No. :	47/7590
Contact No.	9849958926		Sex	M Age: 27
Type	Pre-Emp		Emp. No.:	
	Overseas		Height	176 CM
	Annual	<input checked="" type="checkbox"/>	Weight	90 kg
Remarks	Both physical & lab parameters WNL			
Fitness Status	Medically Fit / Unfit		Physician's Signature Dr. Tennam Sravanthi MBBS Regd.No.05443	

# COMPREHENSIVE MEDICAL EXAMINATION REPORT

NAME Nrusim hadevan Venkata Satya Sandeep

AGE 27 yr.

MARITAL STATUS Single CHILDREN: M      F     

IDENTIFICATION (IF ANY) A mole on back side of right ear

## PAST HISTORY

Any family H/o : High Blood Pressure, Heart Disease, Tuberculosis, Diabetes, Asthma, Cancer

Any Personal H/O Major Illness like : Typhoid..... No .....Jaundice..... No .....Etc.

Any H/o STD ..... No .....Skin infection..... No

H/o Blood Transfusion..... No .....Recent Vaccination.....

H/o Epilepsy..... No .....Giddiness..... No

H/o Surgery..... No .....Fracture in the past..... No

### Any Personal H/O

High Blood Pressure, Heart Disease Tuberculosis, Diabetes, Asthma, Cancer

Drug Abuse, Drug Allergy, Micturition, Bowels, Alcohol, Smoking, Sleep, MC, Wt, Loss/Wt. Gain

Present illness / Medication NIL

## GENERAL EXAMINATION

Conjunctiva:  
Skin:  
Ears:  
Nose:  
Throat & Oral Cavity:

Bone, Joints: Normal  
Nutritional Status: Normal  
Lymph Nodes: N/D  
Edema Feet: No  
Varicose Veins: No

**Distant Vision: Near Vision**

Right Eye: 6/6

With <sup>with glasses</sup> ~~glasses~~ / Without glasses

left Eye: 6/6

with glasses/without glasses

Right Eye: N6

With ~~glasses~~ / Without glasses

left Eye: N6

with ~~glasses~~/without glasses

Colour Vision: Normal

Ophthalmologist's Signature

Right Ear

Hearing:

Rinee's Test :

Weber Test :

Discharge :

Left Ear  
**Dr. Subeksha Natarajan**  
M.B.B.S., (D.O.-Ophthalmology)  
Reg. No. 164784, TNMC

**SYSTEMIC EXAMINATION**

Pulse : 72 bpm

B.P. : 120/80 mmHg

Lungs: A. Shape of Chest Bilateral symmetrical & equal  
B. Breath Sounds. BAZ (+)  
C. Adventitious Sounds. NO

Heart: A. Sounds S<sub>1</sub> S<sub>2</sub> (+)  
B. Murmurs NO

**Nervous System**

Abdomen: A. Liver NPD  
B. Spleen NPD  
C. Piles NO  
D. Any Lump NO

A. Higher Function: }  
B. Cranial Nerves: }  
C. Sensory System: }  
D. Motor System: } NAD  
E. Jerks :

General: A. Hernia NO  
B. Hydrocele NO  
C. Varicocele NO

Breast: Rt. \_\_\_\_\_ Lt. \_\_\_\_\_

# CANDIDATE'S DECLARATION

I hereby solemnly declare that I am not suffering from Asthma, Hypertension, Diabetes, Occult Psychological disorders or any other ailment which can be suppressed without my voluntary declaration.

Date : 16/09/2024

Place :

Sandeep  
Signature

**Note: General Physical Examination and Investigation included in the health check-up have certain limitations and may not be able to detect all latent and asymptomatic diseases. Any new symptoms developing after the health check-up or persisting thereafter should be brought to the attention of the treating physician.**



# PARKLINE DIAGNOSTICS PVT. LTD.

L.G. 3, 4 & 5, Bhuvana Towers, Sarojini Devi Road, Secunderabad - 500 003 Tel : 040 - 4203 8139, 2784 5852  
7995421787, 7093445852 Email : parklinediagnostics@gmail.com...www.parklinediagnostics.com



NABL Accredited  
Certificate No. MC-2566

## ENT EXAMINATION

S. No. 4717590 Emp. No. : \_\_\_\_\_ Date 16/9/24

Name Mr. Nrusimhadwala Venkata Satya Sandeep Age 27 Yrs Sex M/F

### EARS :

Right

Left

EAC : patent, no cerumen. — do.

TM : Intact, pearly white. — do.

TFT : Cone of light (+) Rinne (+) on Weber's-Cantata (+)

### NOSE

: Septu: (N) Bil. Vismata: (N) Dors: (N) antedea

### THROAT

: Oropharynx: (N) Bil. v. c/s (N) primary

### NECK

: (N) Anytrachy bol.

### IMPRESSION :

ENT clinically NAD

Consultant ENT

Dr. D. Hari Krishna Reddy  
MS (ENT)  
Head & Neck Surgeon  
Reg. No: 88379

Name : Nrusimhadevara Venkata Satya Sandeep ..... Sex : M ..... Age : 27 yrs. .....

Date : 16.10.24 .....

OPD No : .....

Spacing in Upper  
anterior & lower  
anterior, Deepbite

(PFO) Noted

Adv. for Orthodontic  
treatment.

  
**Smilesss**   
MULTI SPECIALITY DENTAL CLINIC

Smile Compactly... Not Compactly...  
B.D.S, IMPLANTOLOGIST (USA)  
1-3-1, Rajamudaliar Street, Kalasiguda,  
Secunderabad, Cell : 8977910590,

*Sowmya*



# PARKLINE DIAGNOSTICS PVT. LTD.

L.G. 3, 4 & 5, Bhuvana Towers, Sarojini Devi Road, Secunderabad - 500 003 Tel : 040 - 4203 8139, 2784 5852  
7995421787, 7093445852 Email : parklinediagnostics@gmail.com www.parklinediagnostics.com

## TEST REPORT

Name	: Mr. NRUSIMHADEVARA VENKATA SATYA S	TID	: UMR1969949
Age/Gender	: 27 Years/Male	Registered On	: 16-Sep-2024 09:00 AM
Ref By	: Self	Result On	: 16-Sep-2024 10:25 AM
Reg.No	: BIL4717590	Reported On	: 16-Sep-2024 10:25 AM
Reference	: Medi Wheel		

### DEPARTMENT OF ULTRASOUND Ultrasound Whole Abdomen

**LIVER** : Normal in size and echotexture. No focal lesions.

No IHBD /CBD dilatation. Portal vein is normal in size.

**SPLEEN** : Normal in size and echotexture. No focal lesion seen.

**GALL BLADDER** : Well distended. No sludge / gall stones / sol.  
Gall bladder -Wall thickness is normal.  
No pericholecystic oedema.

**PANCREAS** : Normal in size and echotexture.No calcification / sol.  
Pancreatic duct is normal. No peripancreatic fluid collection.

**RIGHT KIDNEY** : 9.7 x 4.5 cms.  
Normal in size and echotexture.  
Cortical thickness is normal.  
No evidence of calculi / sol.  
Pelvi calyceal system is normal.

**LEFT KIDNEY** : 10.1 x 4.0 cms.  
Normal in size and echotexture.  
Cortical thickness is normal.  
No evidence of calculi / sol.  
Pelvi calyceal system is normal.

**URINARY BLADDER** : Well distended. Normal in contour.  
Wall thickness is normal. No calculus / sol.

**PROSTATE** : Normal in size and echotexture.  
No calcification / sol.  
No pre or para aortic adenopathy / ascites noted.

**IMPRESSION** : Normal Study.

**Clinical correlation.**

\*\*\* End Of Report \*\*\*

Dr. D.J. MOHAN  
MD DMRD  
(Reg No. 8995)  
Consultant Radiologist



# PARKLINE DIAGNOSTICS PVT. LTD.

L.G. 3, 4 & 5, Bhuvana Towers, Sarojini Devi Road, Secunderabad - 500 003 Tel : 040 - 4203 8139, 2784 5852  
7995421787, 7093445852 Email : parklinediagnostics@gmail.com www.parklinediagnostics.com

## TEST REPORT

Name : Mr. NRUSIMHADEVARA VENKATA SATYA S  
Age/Gender : 27 Years/Male  
Ref By : Self  
Reg.No : BIL4717590  
Reference : Medi Wheel

TID : UMR1969949  
Registered On : 16-Sep-2024 09:00 AM  
Result On : 16-Sep-2024 11:52 AM  
Reported On : 16-Sep-2024 11:52 AM

### X-RAY CHEST PA VIEW

Lung fields are clear.

Cardia is normal.

Hila are normal.


C P angles are free.

Bony cage is normal.

Soft tissues are normal.

IMPRESSION : NORMAL CHEST X-RAY

\*\*\* End Of Report \*\*\*

  
Dr. PRAJAKTA SUKHADEVE  
DNB RADIOLOGY  
Reg. No. 68493



N Venkata Satya Sandeep  
Male 27Years

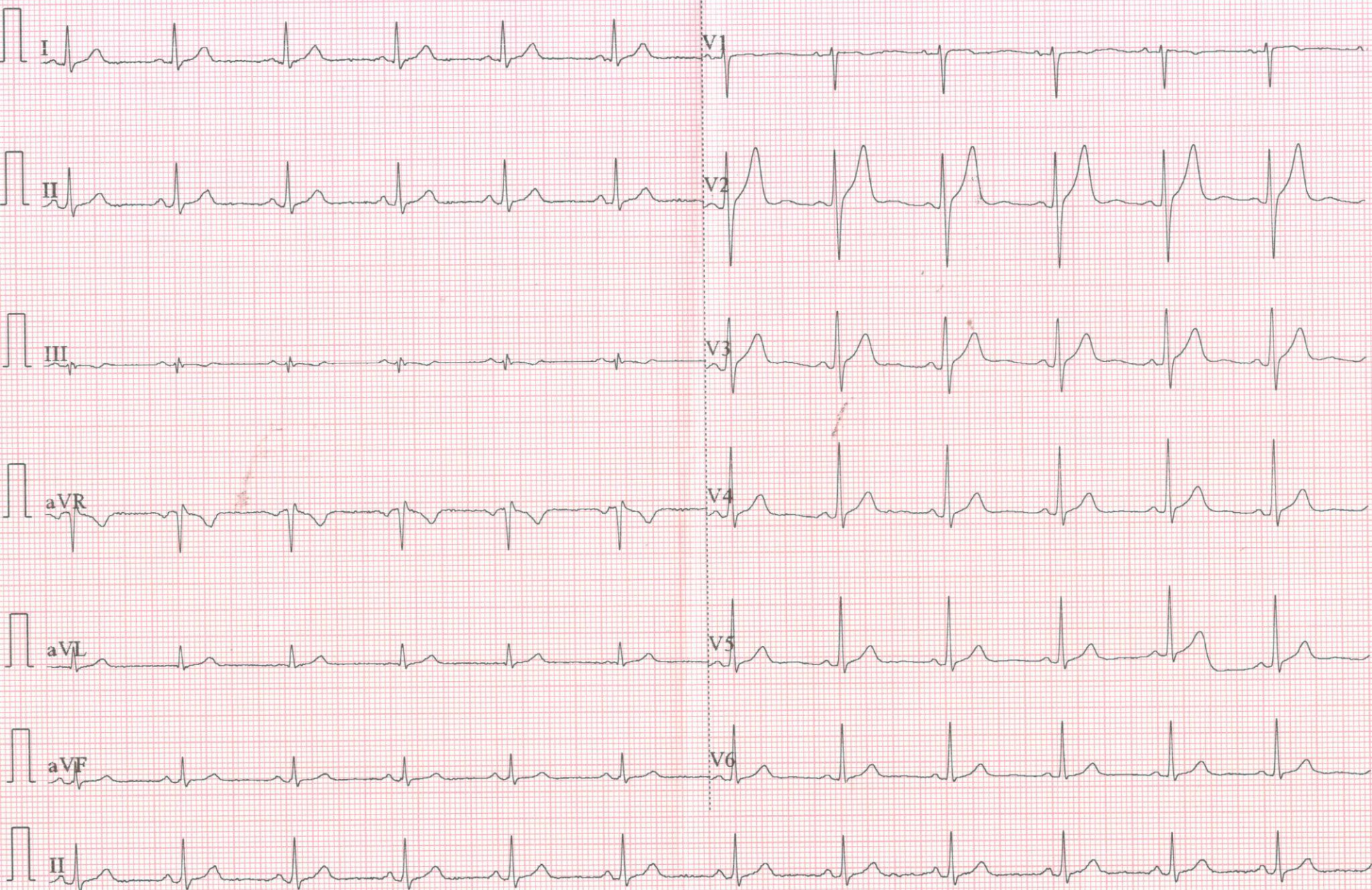
HR : 72 bpm  
P : 102 ms  
PR : 138 ms  
QRS : 87 ms  
QT/QTc : 346/380 ms  
P/QRS/T : 60/32/30 °  
RV5/SV1 : 1.279/0.741 mV

Diagnosis Information:

*cm*  
*P*

**Dr. P. PRASHANT MARUTI**  
DM., Cardiology  
Consultant Interventional Cardiologist  
Reg. No. TSMC/FMR/25860

Report Confirmed by:



**PATIENT SUMMARY REPORT**

**PARKLINE DIAGNOSTICS PVT.LTD**

ID : 4717590  
NAME : **MR N VENKATA SATYA SANDEEP**  
AGE / SEX : 27 / MALE

HEIGHT (cm) : 176  
WEIGHT (kg) : 80  
PROTOCOL : BRUCE

REF. BY : MEDIWHEEL  
DONE BY : DR PRASHANT P  
TECHNICIAN : G.M.SURESH

CASE HISTORY :  
MEDICATION :  
OBJECT OF TEST : Routine Check Up.  
RISK FACTOR : None.  
ACTIVITY : Very Active.  
OTHER INVESTIGATION : E C G  
REASON FOR TERMINATION : THR ACHIEVED  
EXERCISE TOLERANCE : Good (> 10 METS).  
EXERCISE INDUCED ARRHYTHMIAS : No.  
HAEMO RESPONSE : Normal.  
CHRONO RESPONSE : Normal.  
FINAL IMPRESSION :  
EXTRA COMMENTS :

*Tmt is Negative*

**Dr. P. PRASHANT MARUTI**  
DM., Cardiology  
Consultant Interventional Cardiologist  
Reg. No. TSMC/FMR/25860

Confirmed By : \_\_\_\_\_

Signature