



भारत सरकार
GOVERNMENT OF INDIA


 कल्पना
 Kalpana
 DOB: 21-07-1981
 Gender: Female




2489 4538 4302
आधार - आम आदमी का अधिकार


Kalpana



भारतीय विशिष्ट पहचान प्राधिकरण
UNIQUE IDENTIFICATION AUTHORITY OF INDIA


W/O: रबिन्द्र नाथ, 538, डीडीए
जनता फ्लैट्स, बदरपुर, बदरपुर,
बदरपुर, कालकाजी, दक्षिण दिल्ली,
दिल्ली, 110044

Address:
W/o: Rabindra Nath, 538, Dda
Janta Flats, Badarpur, Badarpur,
Badarpur, Kalkaji, South Delhi,
Delhi, 110044



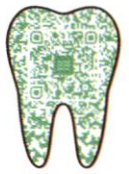 1947
 1800 300 1947

 help@uidai.gov.in

 www.uidai.gov.in

P.O. Box No.1947,
 Bengaluru-560 001

MALIK RADIX HEALTH CARE PVT. LTD.
C-217, C-218, Nirman Vihar,
Delhi-110092
Ph.: 011-49287456, 011-61381379
Regd. No. 607



CONSULTANTS ON PANEL

PAEDIATRICS

Dr Ravi Malik (MBBS, MD)
Dr Harit Prasad (MBBS, MD, Pdi)
Dr Ritu Jain (MBBS, MD)

GYNAECOLOGY

Dr Renu Malik (MBBS, MD)
Dr Meena Malhotra (MBBS, MD)
Dr Rajni (MBBS, MD)
Dr Manju Gupta (MBBS, MS)
Dr Vaishali Saini (MBBS, DGO)
Dr Rupam Arora (MBBS, MD)

DENTAL

Dr Shruti Malik (BDS, MDS)
Dr Annu Saini (BDS, MDS)
Dr Rachit Thukral (BDS, MDS)
Dr Mohit Mangla (BDS, MDS)
Dr Tarun Mittal (BDS, MDS)
Dr Geetika Sharma (BDS)
Dr Shilpa Verma (BDS)

CHILD GASTROENTEROLOGY

Dr S. K Mittal (MBBS, MD)

MEDICINE

Dr A S Talwar (MBBS, MD)
Dr Sunny Uppal (MBBS, MD)
Dr Surendra Rajpal (MBBS, MD)

RESPIRATORY MEDICINE /PULMONOLOGY

Dr Abhinav Bhanot (MBBS, DNB)

LAPAROSCOPY SURGERY

Dr Jayajain (MBBS, MS)
Dr Deepak Saran (MBBS, MS)
Dr Pradeep Saini (MBBS, MS)
Dr G. S Garg (MBBS, MS)

ORTHOAEDICS

Dr Vikas Bhardwaj (MBBS, MS ORTHO, DNB)
Dr Prabhakar Aggarwal (MBBS, MS ORTHO)
Dr KB Tiwari (MBBS, MS ORTHO)
Dr Deepak Kumar Arora (MBBS, MS ORTHO)

EYE/OPTHALMOLOGY

Dr Nidhi Gupta (MBBS, MS, DNB, PGDM)
Dr Himanshu Singh Pundir (MBBS, MS)

ENT

Dr Sharad Kumar Singhi (MBBS, MS)
Dr Prateek Sharma (MBBS, MS)
Dr Ashok Singh (MBBS, MS)
Dr A K Lahiri (MBBS, MS)

RADIOLOGY(ULTRASOUND)

Dr K K Sinha (MBBS, DNRB)
Dr T K Vohra (MBBS, MD)
Dr Rajesh Malhotra (MBBS, MD)
Dr Ashish Tomar (MBBS, MD)

PATHOLOGY

Dr Reema Dahiya (MBBS, MD PATH)
Dr Meenu Aggarwal (MBBS, MD PATH)

ANAESTHESIA

Dr Rajesh Dhall (MBBS, MD)
Dr Rakesh Atrey (MBBS, MD)
Dr R K Arora (MBBS, MD)
Dr Swaraj Garg (MBBS, MD)

DERMATOLOGY

Dr Niharika Jha (MBBS, MD)

PLASTIC & COSMETIC SURGERY

Dr Ayush Jain (MBBS, MS, MCH)

PAEDIATRIC SURGERY

Dr Dharmendra Singh (MBBS, MS, M.Ch)
Dr Satish Aggarwal (MBBS, MS, M.Ch)

PAEDIATRIC NEPHROLOGY

Dr A S Vasudev (MD, Dip.in. Paed.)

NEPHROLOGY

Dr Javed (MBBS, MD, Nephro)

CARDIOLOGY

Dr Nishant Tyagi (MBBS, MD)

NEUROLOGY

Dr Amit Batra (MBBS, MD)

GASTROENTEROLOGY

Dr Deepak Lahoti (MBBS, MD)
Dr Nareesh Aggarwal (MBBS, MD)
Dr Ashok Goyal (MBBS, MD)
Dr Ankur Singhal (MBBS, MD)

UROLOGY

Dr Nikhil Sharma (MBBS, Mch)
Dr Ankur Singhal (MBBS, MD)

PSYCHIATRY

Dr Mohit Sharma (MBBS, MD)

PHYSIOTHERAPY

Dr Kirti Dwivedi
Dr Ravi Kumar

NUTRITIONIST

Dr Deepika Kohli
Dr Sakshi Rana

CLINICAL PSYCHOLOGIST

Dr. Sanika Singh

Dr. Shruti Malik

BDS, MDS (Endodontics)

+91-9899561092

**Timings : 10:00 am. to 2:00 pm.
6:00 pm. to 8:30 pm.**

CLINICAL EXAMINATION:-

1. TMJ:-

Routine dental check up.

2. DENTAL STATUS:

M/H - Nothing relevant

- a. Caries Teeth :
- b. Fracture Teeth :
- c. Root Stumps :
- d. Gingivitis :
- e. Periodontitis : o/e.
- f. Impacted Teeth :
- g. Malaligned Teeth :

Reported.

Stains (+)
Calculus (+)

Missing 6

3. ORAL LESIONS:-

4. DIAGNOSIS:-

ALV

Oral prophylaxis

5. TREATMENT PLANNING:

6. FOLLOW UP:-

3

Referral To Other Consultant: Yes/ No

If Yes, please mention the Name:

Periogard mouthwash - BS
3 months

Doctor's Signature Annu

Facilities Available :

- ★ MULTI-SPECIALITY HOSPITAL ★ MODULAR FULLY EQUIPPED OT ★ NURSERY ★ LAPROSCOPIC SURGERY
- ★ 24X7 EMERGENCY ★ OPG ★ DENTAL ★ 24X7 DIAGNOSTICS ★ LABOUR ROOM ★ ECHO ★ EEG ★ DIGITAL X-RAY ★ CT SCAN
- ★ ECG ★ ULTRASOUND ★ RICU/ICU ★ ALL SPECIALITY OPD ★ PLASTIC & COSMETIC SURGERY ★ DIALYSIS ★ PHARMACY

Kalpana

ID: 9268240676

42years Female

Vent. rate 72 bpm
 QRS duration 82 ms
 QT/QTc 374/409 ms
 PR interval 114 ms
 P duration 84 ms
 RR interval 833 ms
 P-R-T axes -23 53 27

MAC600 1.02

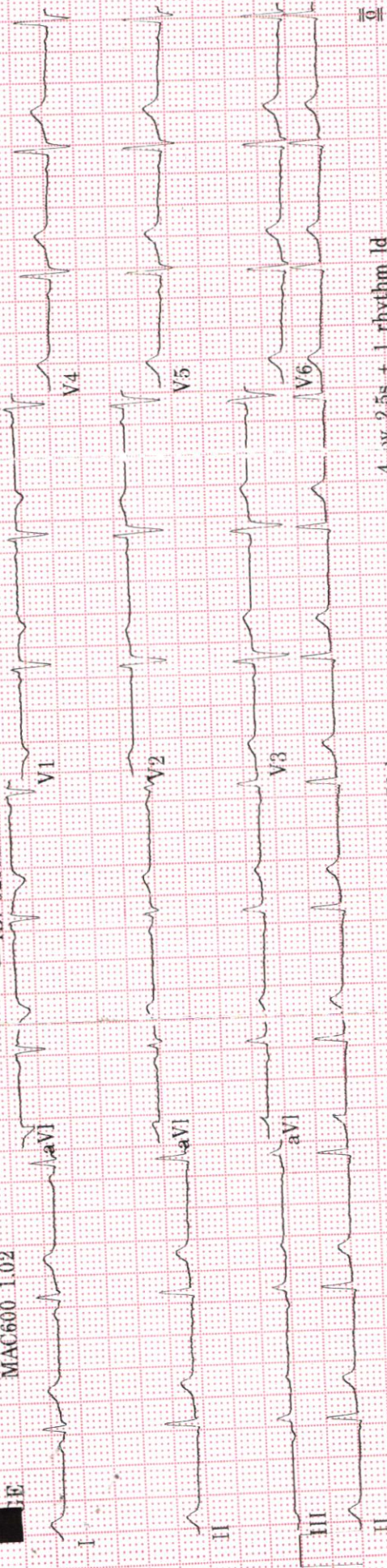
12SL™ v239

Handwritten signature

Mar-2024 9:20:04

ID: 9268240676

MAC600 1.02



72 bpm

50Hz

10.0 mm/mV

25.0 mm/s

0.16-20Hz

4-ly 2.5s + 1 rhythm ld

Malik Radix HealthCare.

ELECTROCARDIOGRAM

Name: MRS. KALPANA Age & Sex: 42 YR/ FEMALE Ref By: MEDIWHEEL Date: 11/03/2024

ECG FINDINGS:

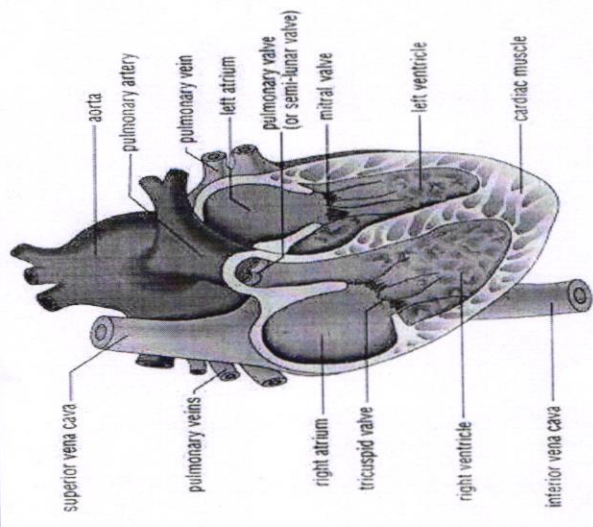
Rate 72 bpm Rhythm Sinus Mechanism Normal


Axis Normal P Wave Normal PR Interval 0.11/Sec

QRS Complex Normal QT Interval Normal Q Wave Normal

ST Segment Normal T Wave Normal

Conclusion Sinus Rhythm, Normal Axis, WNL



Doctors Signature  **Dr. SHEIKH NAZIR AHMED**
M.D. "Physician"
PGDCC
DMC-46499



LAB REPORT

Reg. Date	11/03/2024	Patient Id	2403110003	DOB.	21/07/1981
Name	MRS. KALPANA	Gender	F	Perm. ID	
Age	42 Yrs. 7 Mn. 21 Day	Panel	MEDIWHEEL	Reported	11/03/2024 18:20.39
Ref. By	MEDIWHEEL				

Test Name	Result	Units	Ref. Range
MEDIWHEEL AHC STARTER FEMALE			
<u>HAEMATOLOGY</u>			

COMPLETE HAEMOGRAM

HAEMOGLOBIN (HB%)	12.5	gm/dl	12 - 15
TOTAL LEUCOCYTE COUNT (TLC)	4,200	/cumm	4000 - 11000

DIFFERENTIAL LEUCOCYTE COUNT (DLC)

NEUTROPHIL	54	%	40 - 80
LYMPHOCYTE	27	%	28 - 55
MONOCYTE	12	%	02 - 10
EOSINOPHIL	07	%	01 - 06
BASOPHIL	0	%	0 - 0

ESR (WESTEGREN'S METHOD)	22	mm/1st hr.	0 - 15
R B C COUNT	4.23	Millions/cmm	4.247 - 5.4
P.C.V / HAEMATOCRIT	39.0	%	35 - 45
M C V	92.2	fl.	80 - 100
M C H	29.6	Picogram	27.0 - 31.0
M C H C	32.1	gm/dl	33 - 37
PLATELET COUNT	1.36	Lakh/cu mm	1.50 - 4.50
BLOOD GROUP ABO	" A "		
RH TYPING	Positive		
BLOOD SUGAR FASTING	85.32	mg/dl	70 - 100

THYROID PROFILE

Free T3 ELFA	2.98	ng/ml	02 - 04
Free T4 ELFA	1.12	ug/dl	0.8 - 2.7
TSH Serum/ELFA	1.180	uIU/ml	

Checked by : _____
 Page 1 Contd...2

If test results are alarming or unexpected, patient is advised to contact the laboratory immediately for possible remedial action.

Facilities Available

- Multispeciality Hospital - 24 Hours Emergency - X-Ray/ ECG/ Ultrasound/ CT Scan - Dental- Fully Equipped Operation Theatre
- Fully Functional Lab - 24/7 Casualty/ ICU-Nursery 24/7 Pharmacy - Labour Room - All Speciality OPD - Laproscopic Surgery - ECHO - Plastic Surgery



LAB REPORT

Reg. Date	11/03/2024	Patient Id	2403110003	DOB.	21/07/1981
Name	MRS. KALPANA	Gender	F	Perm. ID	
Age	42 Yrs. 7 Mn. 21 Day	Panel	MEDIWHEEL	Reported	11/03/2024 18:20:39
Ref. By	MEDIWHEEL				

Test Name	Result	Units	Ref. Range
			0.25 - 5.50 uIU/ml

Interpretation

Clinical Use

- Diagnose Hypothyroidism and Hyperthyroidism
- Monitor T4 replacement or T4 suppressive Therapy
- Quantify TSH levels in the subnormal range

Increased Levels : Primary Hypothyroidism Subclinical Hypothyroidism, TSH dependent, Thyroid Hormone Resistance.

Decreased Levels : Grave's Disease, Autonomous Thyroid Hormone Secretion. TSH Deficiency

LIPID PROFILE

TOTAL CHOLESTEROL	117.30	mg/dL	130.0 - 200.0 (<200)
TRIGLYCERIDES	89.70	mg/dL	80.5 - 150.0 (<150)
H D L CHOLESTEROL DIRECT	54.46	mg/dL	42.0 - 60.0 (<40->59)
V L D L	17.9	mg/dL	4.0 - 30. (23-45)
L D L CHOLESTEROL	44.9	mg/dL	50.0 - 150.0 (50-150)
TOTAL CHOLESTEROL / HDL RATIO	2.2		3.3 - 5.1
LDL / HDL CHOLESTEROL RATIO	0.8		1.5 - 3.5

LIVER FUNCTION TEST (LFT)

BILIRUBIN TOTAL	1.00	mg/dl	0.2 - 1.2
CONJUGATED (D. BILIRUBIN)	0.32	mg/dl	0.00 - 0.3
UNCONJUGATED (I.D.BILIRUBIN)	0.68	mg/dl	0.2 - 0.9

Checked by : -----
Page 2 Contd...3

If test results are alarming or unexpected, patient is advised to contact the laboratory immediately for possible remedial action.

Facilities Available

- Multispeciality Hospital - 24 Hours Emergency - X-Ray/ ECG/ Ultrasound/ CT Scan - Dental- Fully Equipped Operation Theatre
- Fully Functional Lab - 24/7 Casualty/ ICU-Nursery 24/7 Pharmacy - Labour Room - All Speciality OPD - Laproscopic Surgery - ECHO - Plastic Surgery



LAB REPORT

Reg. Date	11/03/2024	Patient Id	2403110003	DOB.	21/07/1981
Name	MRS. KALPANA	Gender	F	Perm. ID	
Age	42 Yrs. 7 Mn. 21 Day	Panel	MEDIWHEEL	Reported	11/03/2024 18:20:39
Ref. By	MEDIWHEEL				

Test Name	Result	Units	Ref. Range
SGOT / AST	13.40	IU/L	0 - 35
SGPT / ALT	13.7	IU/L	0 - 35
ALKALINE PHOSPHATASE	100.10	U/L	64 - 306
TOTAL PROTEIN	8.43	gm/dl	6.0 - 8.3
ALBUMIN	4.71	gm/dl	3.2 - 5.0
GLOBULIN	3.72	gm/dl	2.5 - 5.6
A/G RATIO	1.27		0.9 - 2.0
GAMMA GT	20.14	IU/L	0.0 - 35.0
SERUM CREATININE	1.00	mg/dl	0.6 - 1.2
SERUM URIC ACID	3.85	mg/dl	2.4 - 6.0
BLOOD UREA NITROGEN (BUN)	8.25	mg/dl	6.0 - 21.0
BUN/CREAT RATIO	8.25	mg/dl	10 - 20

Urine Routine Examination

PHYSICAL EXAMINATION

QUANTITY	20	ml.	
COLOUR	Yellow		Pale Yellow
TRANSPARENCY	Clear		
SPECIFIC GRAVITY	1.010		
PH	6.0		

CHEMICAL EXAMINATION

ALBUMIN	Nil
SUGAR	Nil

MICROSCOPIC EXAMINATION

PUS CELLS	2-3	/HPF
RBC'S	Nil	/HPF
CASTS	Nil	

Checked by : -----
 Page 3 Contd...4

If test results are alarming or unexpected, patient is advised to contact the laboratory immediately for possible remedial action.

Facilities Available

- Multispeciality Hospital - 24 Hours Emergency - X-Ray/ ECG/ Ultrasound/ CT Scan - Dental- Fully Equipped Operation Theatre
- Fully Functional Lab - 24/7 Casualty/ ICU-Nursery 24/7 Pharmacy - Labour Room - All Speciality OPD - Laproscopic Surgery - ECHO - Plastic Surgery



LAB REPORT

Reg. Date	11/03/2024	Patient Id	2403110003	DOB.	21/07/1981
Name	MRS. KALPANA	Gender	F	Perm. ID	
Age	42 Yrs. 7 Mn. 21 Day	Panel	MEDIWHEEL	Reported	11/03/2024 18:20:39
Ref. By	MEDIWHEEL				

Test Name	Result	Units	Ref. Range
CRYSTALS	NIL		
EPITHELIAL CELLS	4-6	/HPF	
BACTERIA	Nil		
OTHERS	Nil		

Dr. Reema Dahiya
DR. REEMA DAHIYA
 M.B.B.S, MD (Path.)
 Checked by: _____
 Malik Radix Healthcare Pvt. Ltd.
 C-217, C-218, Nirman Vihar, Delhi-92

DR. MEENU AGGARWAL
 M.B.B.S, MD (Path.)

If test results are alarming or unexpected, patient is advised to contact the laboratory immediately for possible remedial action.

Facilities Available

- Multispeciality Hospital - 24 Hours Emergency - X-Ray/ ECG/ Ultrasound/ CT Scan - Dental- Fully Equipped Operation Theatre
- Fully Functional Lab - 24/7 Casualty/ ICU-Nursery 24/7 Pharmacy - Labour Room - All Speciality OPD - Laproscopic Surgery - ECHO - Plastic Surgery



NAME	MRS KALPANA	AGE	42 Y/F
REFD. BY.	HEALTH CHECK UP	DATE	11.03.24

Ultrasound Examination of Whole Abdomen & Pelvis:

Liver: Liver is normal in size (12.5 cm) with normal outlines and shows normal parenchymal echotexture. No focal lesion is seen. IHBR & portal radicles are normal.

Gallbladder: Gallbladder is well distended. No evidence of cholecystitis or cholelithiasis seen. Common bile duct is normal in course & caliber.

Pancreas: Pancreas shows normal size, outlines & echotexture. No focal lesion is seen. MPD is not dilated.

Spleen: Spleen shows normal size (9.2cm), outline & echotexture.

Kidneys: Kidneys show normal size, shape, position & echotexture. No calculus/ hydronephrosis or SOL is seen in kidneys. Cortico- medullary differentiation and cortical thickness is normal on both sides.

Right kidney measures –10.1 X 4.2 cm

Left kidney measures – 9.9 X 5.3 cm

Great abdominal vessels are normal.

No ascites seen.

No para-aortic lymph nodes seen.

Urinary bladder: Urinary bladder is well distended. Walls and lumen appear normal.

Uterus is normal in size outline and echotexture. No focal lesion is seen. Endometrium is central and measures 7.6 mm. Cervix appears normal.

Both adnexa appear unremarkable.

IMPRESSION: Normal study

Dr Shreyash Tiwary MD (Rad- diag)

Regn. No. DMC 85802

RADIOLOGIST :

Facilities Available

