


8, 9, 12

Name : Mrs. ASHA T V Address : MYSORE Plan : ARCOFEMI MEDIWHEEL FEMALE AHC CREDIT PAN INDIA OP AGREEMENT	Age : 40 Y Sex : F	UHID :CMYS.0000059976  OP Number :CMYSOPV123227 Bill No :CMYS-OCR-22601 Date : 09.03.2024 08:15
---	---	---

Sno	Service Type/ServiceName	Department
1	ARCOFEMI - MEDIWHEEL - FULL BODY ANNUAL PLUS CHECK ADVANCED - FEMALE - 2D ECHO - PAN INDIA - FY2324	
✓1	GAMMA GLUTAMYL TRANSFERASE (GGT)	
2	2 D ECHO → P.	
✓3	LIVER FUNCTION TEST (LFT)	
✓4	GLUCOSE, FASTING	
✓5	HEMOGRAM + PERIPHERAL SMEAR	
• 6	GYNAECOLOGY CONSULTATION ⓧ	
7	DIET CONSULTATION ⓧ	
✓8	COMPLETE URINE EXAMINATION	
✓9	URINE GLUCOSE(POST PRANDIAL)	HC 157
✓10	PERIPHERAL SMEAR	
✓11	ECG	WG 1019
• 12	LBC PAP TEST- PAPSURE ⓧ	SP → 130/80
✓13	RENAL PROFILE/RENAL FUNCTION TEST (RFT/KFT)	
14	DENTAL CONSULTATION	
✓15	GLUCOSE, POST PRANDIAL (PP), 2 HOURS (POST MEAL)	
✓16	URINE GLUCOSE(FASTING)	
✓17	SONO MAMOGRAPHY - SCREENING → ⓧ	
18	HbA1c, GLYCATED HEMOGLOBIN	
✓19	X-RAY CHEST PA	
20	ENT CONSULTATION → P.	
21	FITNESS BY GENERAL PHYSICIAN → P.	
✓22	BLOOD GROUP ABO AND RH FACTOR	
✓23	LIPID PROFILE	
✓24	BODY MASS INDEX (BMI)	
25	OPHTHAL BY GENERAL PHYSICIAN	
✓26	ULTRASOUND - WHOLE ABDOMEN → ⓧ	
✓27	THYROID PROFILE (TOTAL T3, TOTAL T4, TSH)	


CERTIFICATE OF MEDICAL FITNESS

This is to certify that I have conducted the clinical examination

of Mrs Asha. on 09/03/24

After reviewing the medical history and on clinical examination it has been found that he/she is

	Tick
<ul style="list-style-type: none"> • Medically Fit 	✓
<ul style="list-style-type: none"> • Fit with restrictions/recommendations <p>Though following restrictions have been revealed, in my opinion, these are not impediments to the job.</p> <p>1.....</p> <p>2.....</p> <p>3.....</p> <p>However the employee should follow the advice/medication that has been communicated to him/her.</p> <p>Review after _____</p>	
<ul style="list-style-type: none"> • Currently Unfit. Review after _____ recommended 	
<ul style="list-style-type: none"> • Unfit 	

Dr. 
Medical Officer
The Apollo Clinic, Mysore.

Apollo Clinic
1st Floor,
Kalidasa Road, Mysore - 02
Ph : 0821-4006040/41

This certificate is not meant for medico-legal purposes

Apollo Health and Lifestyle Limited

(CIN - U85110TG2000PLC115819)

Regd. Office: 1-10-60/62, Ashoka Raghupathi Chambers, 5th Floor, Begumpet, Hyderabad, Telangana - 500 016.

Ph No: 040-4904 7777, Fax No: 4904 7744 | Email ID: enquiry@apollohl.com | www.apollohl.com

APOLLO CLINICS NETWORK KARNATAKA

Bangalore (Basavanagudi | Bellandur | Electronic City | Fraser Town | HSR Layout | Indira Nagar | JP Nagar | Kundalahalli | Koramangala | Sarjapur Road) Mysore (VV Mohalla)

Online appointments: www.apolloclinic.com

TO BOOK AN APPOINTMENT

 **1860 500 7788**

Date : 09-03-2024
MR NO : CMYS.0000059976
Name : Mrs. ASHA TV
Age/ Gender : 40 Y / Female

Department : GENERAL
Doctor : *D. Vinod HB*
Registration No : 670224
Qualification : M B B - S - N (M)

Consultation Timing: 08:14

Height: 57	Weight: 101.9	BMI:	Waist Circum: 20
Temp:	Pulse: 70/1	Resp: 20/1	B.P: 130/80

General Examination /
Allergies History

*CS
RS
P/A/N HB*

Clinical Diagnosis & Management Plan

Adh
T- OXRA - MET - 10/500 - (20)
+ 500

T- ALT - D₃. 60k once - (5)
a week

*HB
SPAS*

HB Acc 6-5

Follow up date :

[Signature]
Doctor Signature

Apollo Clinic
23, 1st Floor,
Kalidasa Road, Mysore - 02
Ph : 0821-4006040/41

Date : 09-03-2024 Department : GENERAL [optical]
 MR NO : CMYS.0000059976 Doctor :
 Name : Mrs. ASHA T V Registration No :
 Age/ Gender : 40 Y / Female Qualification :

Consultation Timing: 08:14

Height : 157	Weight : 101.9	BMI :	Waist Circum :
Temp :	Pulse :	Resp :	B.P : 130/80

General Examination /
Allergies History

Clinical Diagnosis & Management Plan

Vision RT LT
 far 6/12 6/9
 Near N-24 N-24
 Color - (2) (2)

Follow up date :


Doctor Signature

Apollo Clinic
 # 23, 1st Floor,
 Kalidasa Road, Mysore - 02
 Ph : 0821-4006040/41

Date : 09-03-2024
 MR NO : CMYS.0000059976
 Name : Mrs. ASHA T V
 Age/ Gender : 40 Y / Female

Department : GENERAL
 Doctor :
 Registration No :
 Qualification :

Consultation Timing: 08:14

Height : 57	Weight : 101.9	BMI :	Waist Circum :
Temp :	Pulse :	Resp :	B.P : 130/80

General Examination / Allergies History

Clinical Diagnosis & Management Plan

m1 → 16 yrs Pa2 - Both US.

PH → ACS
 AH → DM +

mH → regular ydls.
 HMB - many yrs.

tuberculosis

scan → fatty liver,
 mammogram -

cholelithiasis, bulch
 uterus ± small
 fibroids.
 normal.

adu: - TAB PAUSE MF
 AF 1-0-1 x 3day

(6) :
 (dummy smudges)

- TAB. PANTOLID DSR
 BF 1-0-0 (5)

- regular walk
 - low wt | low fat diet.

Follow up date :

Doctor Signature
Apollo Clinic
 # 23, 1st Floor,
 Kalidasa Road, Mysore - 02
 Ph : 0821-4006040/41

Date : 09-03-2024
MR NO : CMYS.0000059976
Name : Mrs. ASHA TV
Age/ Gender : 40 Y / Female

Department : GENERAL
Doctor :

Registration No : *Dr Praveen Kumar R*
Qualification : *MS (ENT)*

Consultation Timing: 08:14

Height : <i>151</i>	Weight : <i>101.9</i>	BMI :	Waist Circum :
Temp :	Pulse :	Resp :	B.P : <i>130/80</i>

General Examination /
Allergies History

Clinical Diagnosis & Management Plan

Come for recurrent hearing disorder

Ear Bilateral Tinnitus - @

nose - nasal mucus @

oral cavity & oropharynx - @

neck @

AS hearing

Follow up date :

Doctor Signature

Apollo Clinic
23, 1st Floor,
Kalidasa Road, Mysore - 02
Ph : 0821-4006040/41

Date : 09-03-2024
 MR NO : CMYS.0000059976
 Name : Mrs. ASHA TV
 Age/ Gender : 40 Y / Female

Department : GENERAL Dietetics
 Doctor : Madhura . B.P

Registration No :
 Qualification : M.Sc Nutrition & Dietetics
 PhD*

Consultation Timing: 08:14

TBW - 54 kg

Height : 157	Weight : 101.9	BMI : 41 kg/m ²	Waist Circum :
Temp :	Pulse :	Resp :	B.P : 130/80


General Examination /
 Allergies History

Hb - 11.4
 ESR - 28
 FBS - 134
 PPBS - 172
 HSA/C - 6.5%
 HDL - 31
 NON HDL - 145
 LDL - 117.74
 chol/HDL - 5.68

Clinical Diagnosis & Management Plan

- Δ^s - Fatty liver, cholelithiasis
- Advised low fat, diabetic diet with fiber rich foods.
 - Avoid fruits like Mango, papaya, Jackfruit, custard apple & sug banana.
 - Avoid root vegetables like potato, sweet potato, Yam & Arbi.
 - Dietary guideline chart is given.

Follow up date :

Doctor Signature :  B.P
 9/3/2024
Apollo Clinic
 # 23, 1st Floor,
 Kalidasa Road, Mysore - 02
 Ph : 0821-4006040/41

Department- Dietetics


Name- Madhura B P

Qualification- M.Sc Nutrition & Dietetic

PhD*

- Do not skip any of the meals, take small frequent meals.
- Include all variety of seasonal fruits, vegetables and green leafy vegetables on regular basis.
- Include nuts like Almond, Walnuts and [dry-fruits like dried dates and raisins - weekly once/twice]
- Include seeds like Flax seeds, Pumpkin seeds, Sunflower seeds, Sesame seeds and watermelon seeds- 1 teaspoon each and dry roasted.
- Avoid 5 white slow poisons like Sugar, Salt, Maida, Baking soda and creams.
- Cooking oil- ½ litre/person/month.
- Use combination of oils like Rice bran oil, Groundnut oil, Sesame oil, Mustard oil/ Coconut oil and Ghee. Change the oil every month or 2 months. But do not mix the oils.
- Drink at least 2-3 liters of water in a day.
- Skimmed or toned milk can be used on regular basis. Since it's a rich source of protein and low in calories.
- Avoid Butter, Vanaspati and Dalda.
- Avoid deep-fried foods, Biscuits, Cookies, Bakery products, Pastries, Papad, packed and processed foods, chocolates, Alcohol, caffeine and carbonated beverages.
- Avoid junk foods like Pizza and Burger.

Dietician signature


9/3/2024

Patient's Name : Mrs. Asha T V	Age & Sex; 40Yrs /Female
Date : 09.03.2024	UHID No:59976

2D ECHOCARDIOGRAPHY STUDY

Impression:

- Normal chambers and valves
- No regional wall motion abnormality
- Normal left ventricular systolic function. EF 67 %
- No clots. No pericardial effusion
-

Findings

Left Ventricle:	No RWMA
Right Ventricle	Normal
Left Atrium	Normal
Right Atrium	Normal
Aorta	Normal
Pulmonary Artery	Normal
IAS	Intact
IVS	Intact
Valves	Normal
Pericardium	Normal
Doppler	Normal

Apollo Health and Lifestyle Limited

ICMR - UBS110TG2000PLC1158191
Regd. Office - 110-6D 62, Ashoka Raghupathi Chambers, 5th Floor, Begumpet, Hyderabad, Telangana - 500 016
Ph. No. (041) 4614 7777 | Fax No. 4604 7744 | Email ID: enquiry@apollohl.com | www.apollohl.com

APOLLO CLINICS NETWORK KARNATAKA
Bangalore | Basavanagudi | Bellandur | Electronic City | Fraser Town | MSR Layout | Indira Nagar | JP Nagar | Kundalahalli |
Rajarajagala | Sarjapur Road | Mysore (VV Mahalla)

Online appointments: www.apolloclinic.com

TO BOOK AN APPOINTMENT

 **1860|500 7788**

Patient's Name : Mrs. Asha T V	Age & Sex; 40Yrs /Female
Date : 09.03.2024	UHD No:59976

Measurements

AO : 2.7 cm
 LA : 2.8 cm

 RV : 2.9 cm
 LVIDd : 5.11 cm
 LVIDs : 3.17 cm
 IVSd : 0.89 cm
 IVSs : 1.33 cm
 PWd : 1.14 cm
 PWs : 1.40 cm
 EF : 67.0 %
 FS : 37.0 %

Doppler

MV	TV	AV	PV
E 0.95 m/s	E --- m/s	V max 1.62 m/s	V max 1.20 m/s
A: 0.79 m/s	A --- m/s		

Dr. GURU PRASAD. B. V, MBBS, PGDCC
CONSULTANT – NON-INVASIVE CARDIOLOGY

Dr. GURU PRASAD. B. V
 MBBS, PGDCC (CARDIO)
 CLINICAL CRT (ECG PR) PGCC, CCEBDM
 Clinical Master, Bangalore, www.CardioLink.in

Apollo Health and Lifestyle Limited

KR No. UB5110TG2BKA0PLE11581W
 Apollo Office: 1-10-840-82, Aashika Raghupathi Chambers, 5th Floor, Begumpet, Hyderabad, Telangana - 500 016
 Tel: +91 080 456 7777 Fax: +91 080 456 7766 | Email: enquiry@apollohlt.com | www.apollohlt.com

APOLLO CLINICS NETWORK BARNATARA

Bangalore: [Srinivasareddy] | Bellary: [K. Srinivas Reddy] | Electronic City: [Fraser Town] | HSR Layout: [Indira Nagar] | JP Nagar: [Kundalahalli]
 Mysore: [Srinivas Reddy] | Mysore: [SV Mahalingam]

Online: apolloappointments.com | apollohlt.com

TO BOOK AN APPOINTMENT

1860 500 7788

Patient Name: Mrs. Asha TV	Date : 09.03.2024	Referring Doctor: Dr. Self
Age / Sex: 40 Yrs Female	UHID NO: 59976	Location : OP
ULTRASONOGRAPHY- BREAST		

RIGHT BREAST: It is normal in echopattern. No e/o focal nodular or mass lesions seen. No e/o calcifications. The skin over the breast is normal. Nipple and areola are normal. The subcutaneous, mammary and retro mammary zones are normal.

LEFT BREAST: It is normal in echopattern. No e/o focal nodular or mass lesions seen. No e/o calcifications. The skin over the breast is normal. Nipple and areola are normal. The subcutaneous, mammary and retro mammary zones are normal.

No e/o axillary lymphadenopathy.

IMPRESSION: NORMAL STUDY.

Pradeep
Dr. Pradeep Kumar C N, DNB.
Consultant Radiologist.

Apollo Health and Lifestyle Limited

ICR - 48331072200PLC 115619

Regd Office: 1-10-60-02, Anand Rajhuzarthy Chambers, 5th Floor, Begumpet, Hyderabad, Telangana - 500 018
Ph No: 944 4834 7777 Fax No: 4834 7744 | Email: enquiry@apolloh.com | www.apolloh.com

APOLLO CLINIC'S NETWORK KARNATAKA

Bangalore: Basavanaguda | Bellandur | Electronic City | Flower Town | HSR Layout | Indira Nagar | JP Nagar | Kandraiahalli |
Koramangala | Sarjapur Road | Mysore (VV Mohalla)

Online appointments: www.apolloh.com

TO BOOK AN APPOINTMENT

1860 500 7788

Patient Name : Mrs. ASHA T V
UHID : CMYS.0000059976
Reported on : 09-03-2024 15:44
Adm/Consult Doctor :

Age : 40 Y F
OP Visit No : CMYSOPV123227
Printed on : 09-03-2024 15:44
Ref Doctor : SELF

DEPARTMENT OF RADIOLOGY

X-RAY CHEST PA

Both lung fields and hila are normal .
No obvious active pleuro-parenchymal lesion seen .
Both costophrenic and cardiophrenic angles are clear .
Both diaphragms are normal in position and contour .
Thoracic wall and soft tissues appear normal.

IMPRESSION :NORMAL STUDY .

Pradeep

Printed on:09-03-2024 15:44

---End of the Report---

Dr. PRADEEP KUMAR C N
MBBS DNB(RADIOLOGY)
Radiology

Apollo Health and Lifestyle Limited

ICPN: U63110TG2000PLC115819

Regd Office: T-10-60/62, Ashoka Rajgupta Chambers, 5th Floor, Begumpet, Hyderabad, Telangana - 500 016

Ph: No: 040 4904 7777 Fax: No: 4904 7744 | Email: enquiry@apollohi.com | www.apollohi.com

APOLLO CLINICS NETWORK KARNATAKA

Bangalore | Basavanagudi | Bellandur | Electronic City | Fraser Town | HSR Layout | Indra Nagar | JP Nagar | Kundalahalli | Koramangala | Sarjapur Road | Mysore (VV Mohalla)

Online appointments: www.apolloclinic.com

TO BOOK AN APPOINTMENT

1860 500 7788

Informed Consent/Declaration For Test Exclusion

Patient Name: Mr. Ashu TV Age: 40 yrs

UHID Number: 59976

Please tick and sign the relevant part

I certify that I will skip LBC Test from my own.

No refund is provided for the above excluded test and i have been informed about the same.

Patient signature: [Signature] Date: 09/03/24

Witness signature: [Signature] Date: 09/03/24

Apollo Clinic
23, 1st Floor,
Kallidasa Road, Mysore - 02
Ph: 0821-4006040/41

ID: 59976

09-03-2024 09:33:59 AM

MRS ASHA T V

Female 40Years

157cm 101kg 130/80 mmHg

Diagnosis Information:

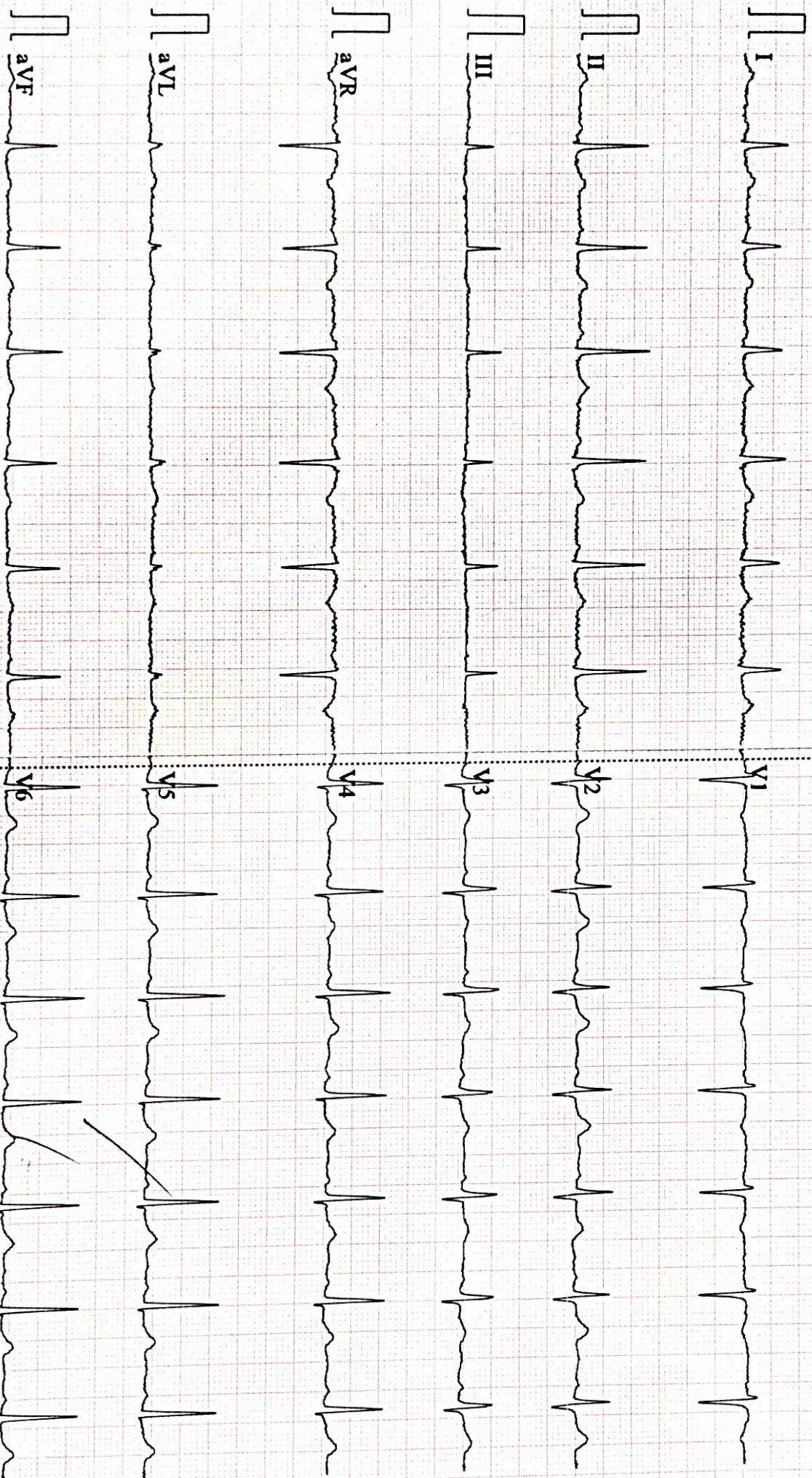
Unconfirmed Report.

Apollo Clinic

23, 1st Floor,

Kalidasa Road, Mysore - 07

Ph : 0821-4005040/41



0.5~45Hz AC50 25mm/s 10mm/mV 2*5.0s

80 CARDIART

8 D V1.43 Glasgow V28.6.0

APOLLO CLINIC MYSURU

Patient Name: Mrs. Asha T V	Date : 09.03.2024	Referring Doctor: Dr .Self
Age / Sex: 40 Yrs/Female	UHID NO: 59976	Location : OP
ULTRASONOGRAPHY- ABDOMEN & PELVIS		

LIVER: It is increased in size and echotexture. No focal lesions seen. IHBR are not dilated. CBD and Portal vein are normal.

GALL BLADDER: It is contracted and calculus measuring 13 mm.

SPLEEN: It is normal in size, outline and echopattern. No e/o focal lesions.

PANCREAS: It is normal.

RIGHT KIDNEY: It measures 119x48 mm with parenchymal thickness of 16 mm. It is normal in size, outline and echotexture. No e/o calculus or hydronephrosis seen.

LEFT KIDNEY: It measures 113x56 mm with parenchymal thickness of 15 mm. It is normal in size, outline and echotexture. No e/o calculus or hydronephrosis seen.

URINARY BLADDER: It is well distended. The UB wall is normal. No calculi seen.

UTERUS: It is anteverted ,bulky and measures 75x55x66 mm with ET=13 mm. It is normal in outline and echotexture. Multiple small hypoechoic lesions of 3-4 mm seen.


Rt. OVARY: It measures 25x31 mm. It is normal. No mass lesion seen.

Lt. OVARY: It measures 31x31 mm. It is normal. No mass lesion seen.

RIF: No evidence of focal collection or mass lesion seen. Appendix is not visualized.

OTHERS: No e/o free fluid in the abdomen. No e/o lymphadenopathy. No e/o gut wall thickening. No mass lesion seen in the abdomen.

IMPRESSION: FATTY LIVER; CHOLELITHIASIS; BULKY UTERUS-WITH SMALL FIBROIDS.


Dr. Pradeep Kumar C N, DNB
Consultant Radiologist.

Apollo Health and Lifestyle Limited

(CIN: U85110TG2000PLC115819)

Regd. Office: 1-10-60 E2, Ashoka Raghupathi Chambers, 5th Floor, Begumpet, Hyderabad, Telangana - 500 016

Ph. No: 040 4904 7777. Fax No: 4904 7744 | Email ID: enquiry@apollohl.com | www.apollohl.com

APOLLO CLINICS NETWORK KARNATAKA

Bangalore (Bakavanagudi | Bellandur | Electronic City | Fraser Town | HSR Layout | Indira Nagar | JP Nagar | Kundalahalli | Koramangala | Sarjapur Road) | Mysore (VV Mohalla)

Online appointments: www.apolloclinic.com

TO BOOK AN APPOINTMENT

 **1860 500 7788**