

If the examinee is suffering from an acute life threatening situation, you may be obliged to disclose the result of the medical examination to the examinee.

1. Name of the examinee	:	Mr./Mrs./Ms:	<u>JOHI</u>
2. Mark of Identification	:	(Mole/Scar/any other (specify location)):	
3. Age/Date of Birth	:	Gender:	<u>F/M</u> <u>50</u>
4. Photo ID Checked	:	(Passport/Election Card/PAN Card/Driving Licence/Company ID)	

PHYSICAL DETAILS:

a. Height (cms)	b. Weight (Kgs)	c. Girth of Abdomen (cms)
d. Pulse Rate <u>54</u> (/Min)	e. Blood Pressure:	Systolic <u>120</u> Diastolic <u>80</u>
	1 st Reading	
	2 nd Reading	

FAMILY HISTORY:

Relation	Age if Living	Health Status	If deceased, age at the time and cause
Father			
Mother			
Brother(s)			
Sister(s)			

HABITS & ADDICTIONS: Does the examinee consume any of the following?

Tobacco in any form	Sedative	Alcohol
<u>-</u>		

PERSONAL HISTORY

- a. Are you presently in good health and entirely free from any mental or Physical impairment or deformity. If No, please attach details. **Y/N** ✓
- b. Have you undergone/been advised any surgical procedure? **Y/N** ✓
- c. During the last 5 years have you been medically examined, received any advice or treatment or admitted to any hospital? **Y/N** ✓
- d. Have you lost or gained weight in past 12 months? **Y/N** ✓

Have you ever suffered from any of the following?

- Psychological Disorders or any kind of disorders of the Nervous System? **Y/N** ✓
- Any disorders of Respiratory system? **Y/N** ✓
- Any Cardiac or Circulatory Disorders? **Y/N** ✓
- Enlarged glands or any form of Cancer/Tumour? **Y/N** ✓
- Any Musculoskeletal disorder? **Y/N** ✓
- Any disorder of Gastrointestinal System? **Y/N** ✓
- Unexplained recurrent or persistent fever, and/or weight loss **Y/N** ✓
- Have you been tested for HIV/HBsAg / HCV before? If yes attach reports **Y/N** ✓
- Are you presently taking medication of any kind? **Y/N** ✓

- Any disorders of Urinary System? Y/N ✓
- Any disorder of the Eyes, Ears, Nose, Throat or Mouth & Skin Y/N ✓

FOR FEMALE CANDIDATES ONLY

- a. Is there any history of diseases of breast/genital organs? Y/N ✓
- b. Is there any history of abnormal PAP Smear/Mammogram/USG of Pelvis or any other tests? (If yes attach reports) Y/N ✓
- c. Do you suspect any disease of Uterus, Cervix or Ovaries? Y/N ✓
- d. Do you have any history of miscarriage/abortion or MTP Y/N ✓
- e. For Parous Women, were there any complication during pregnancy such as gestational diabetes, hypertension etc Y/N ✓
- f. Are you now pregnant? If yes, how many months? Y/N ✓

CONFIDENTIAL COMMENTS FROM MEDICAL EXAMINER

- Was the examinee co-operative? Y/N ✓
- Is there anything about the examinee's health, lifestyle that might affect him/her in the near future with regard to his/her job? Y/N ✓
- Are there any points on which you suggest further information be obtained? Y/N ✓
- Based on your clinical impression, please provide your suggestions and recommendations below;

Low Risk Set

- Do you think he/she is **MEDICALLY FIT** or **UNFIT** for employment.

MEDICAL EXAMINER'S DECLARATION

I hereby confirm that I have examined the above individual after verification of his/her identity and the findings stated above are true and correct to the best of my knowledge.

Name & Signature of the Medical Examiner : *[Signature]*

Seal of Medical Examiner :

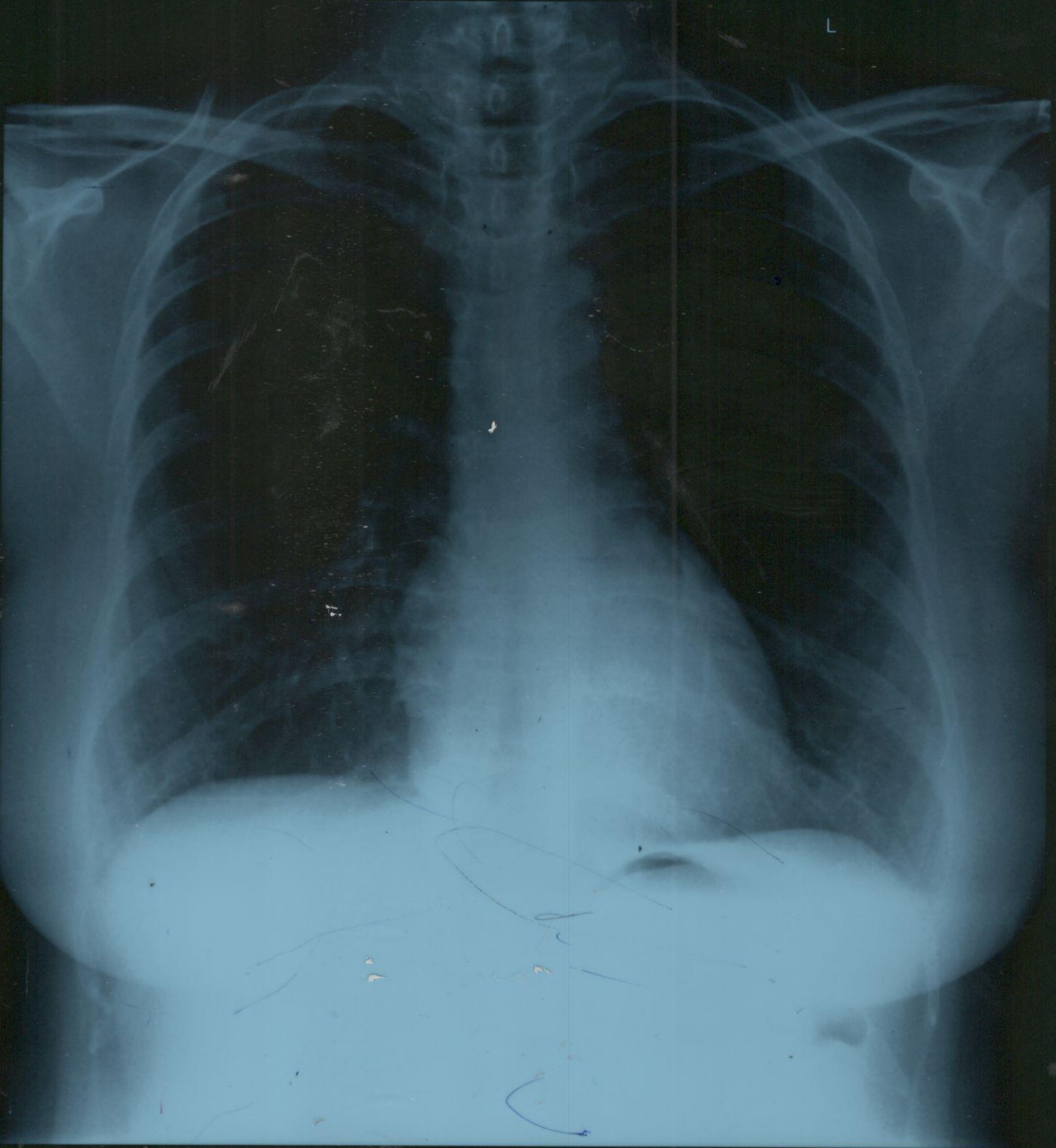
Name & Seal of DDRC SRL Branch :

Date & Time :

Dr. P.V AJITHKUMAR
 MD, MSc (Diabetes) MPhil
 Professor, Consultant Diabetologist
 & Clinical Epidemiologist
 Reg : No. 20366, Dept. of Diabetology
 Sree Gokulam Medical College, Trivandrum-695607

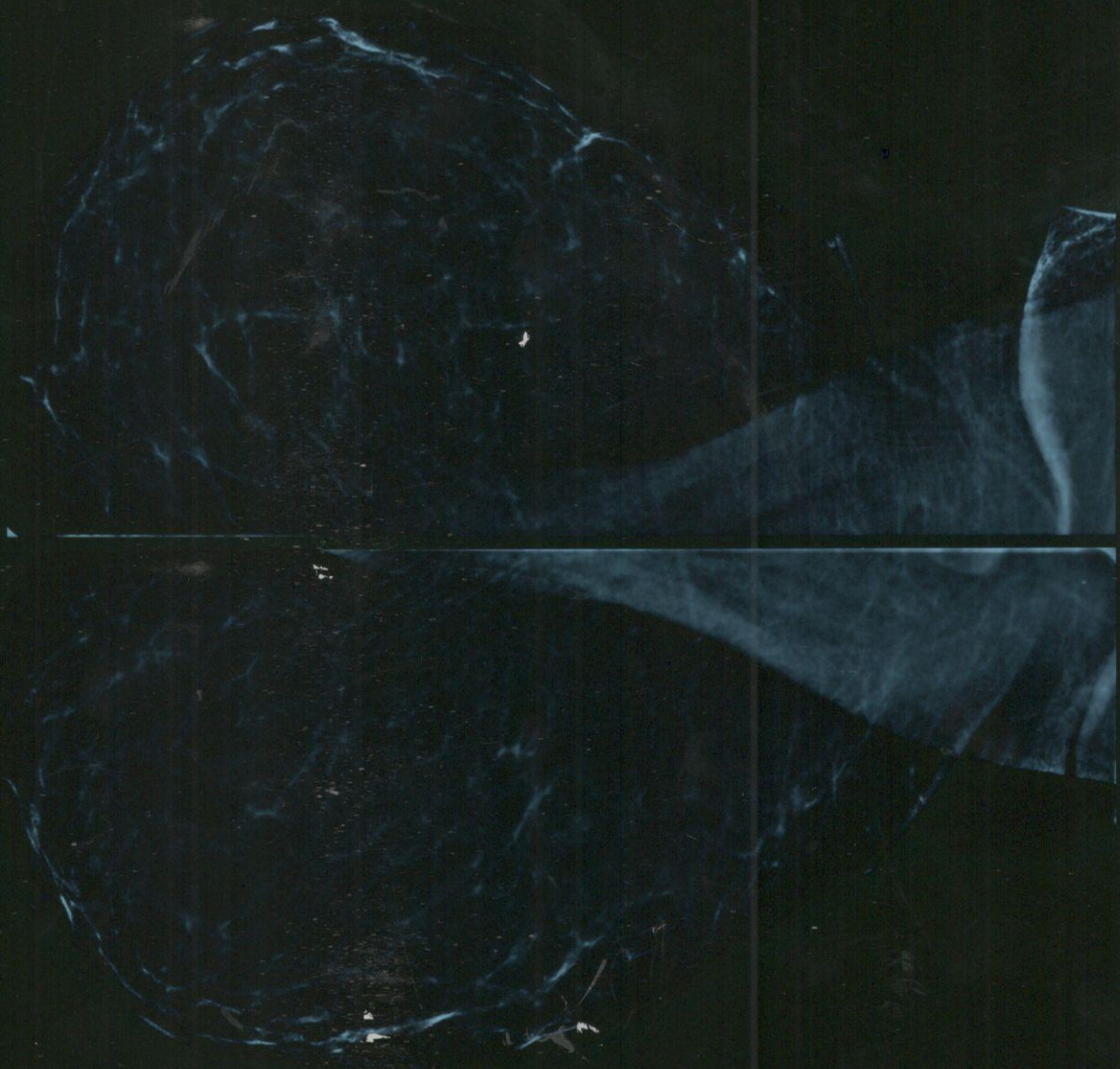
DDRC agilus Pathlabs Limited.

Corp. Office : Express House, Second Floor, Opp. Pothys Silks, Banerjee Road, Kaloor -682017
 Contact :- 93334 93334, Web :- www.ddrcagilus.com Email :- info.ddrc@agilus.in



DDRC AGILUS
MRS. JOTHI PARAMESWARAN NAIR 50Y F 3/23/2024 CHEST- PA XC008533 v

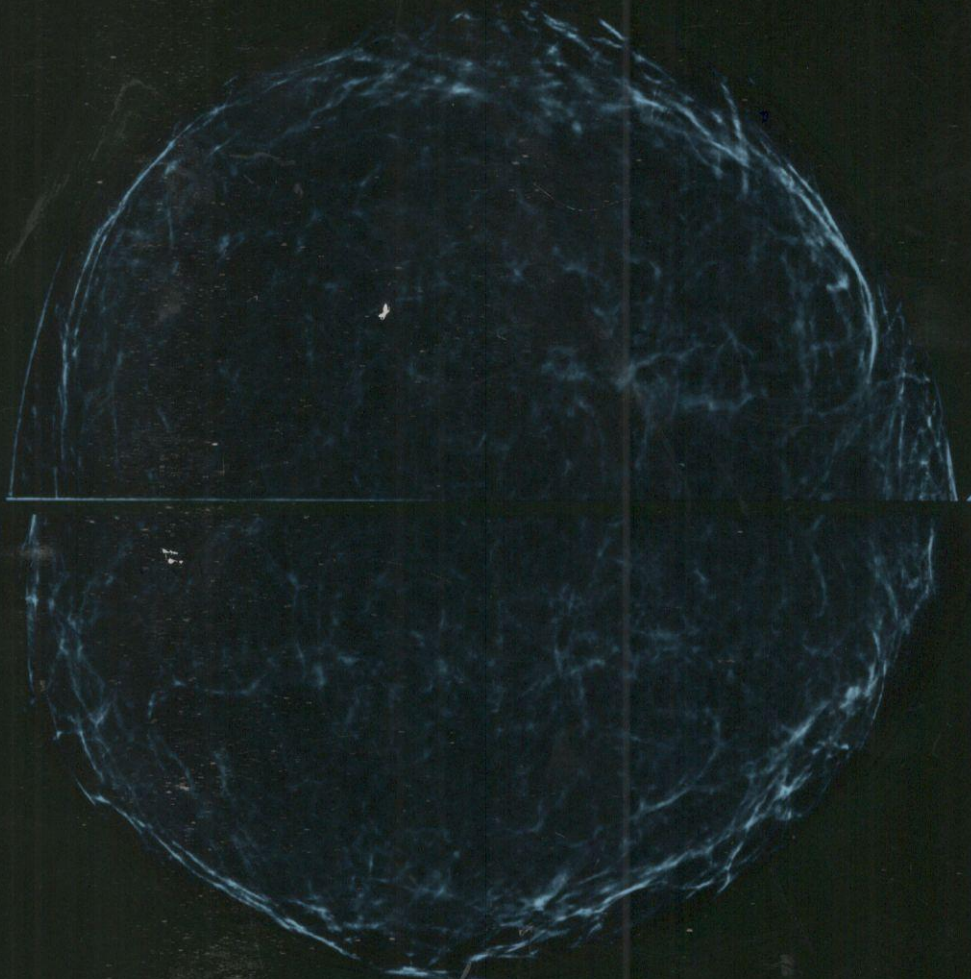
R-mi



L-mlo

MRS JOTHI PARAMESWARAN NAIR
DDRC, AGILUS
50Y F 3/23/2024 MAMMOGRAPHY-MLO XC008533 V

R-cc



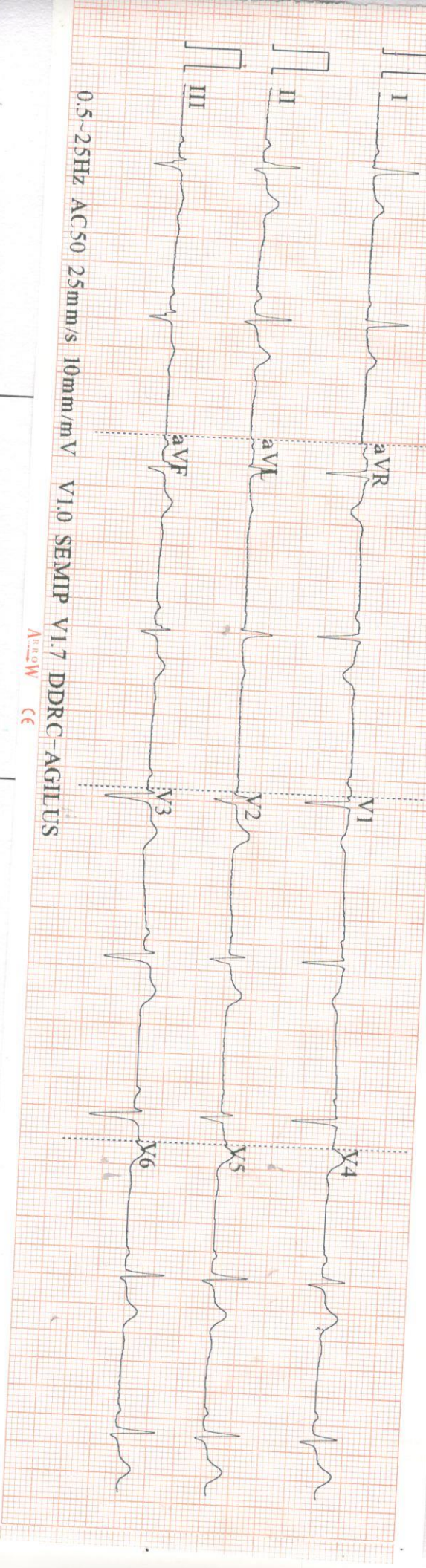
L-cc

DDRC AGILUS

MRS. JOTHI PARAMESWARAN NAIR 50Y F 3/23/2024 MAMMOGRAPHY-CC XC008533 V

Standard	L I	L II	L III	L III Inspiration

ID: 008533 23-03-2024 10:02:42 AM



Arrow CE

ID: 008533

Female
50 Years
cm

Diagnosis Information:

kg / mmHg

Mr Jothi Subramanian Ram

HR	:	53	bpm
P	:	105	ms
PR	:	165	ms
QRS	:	95	ms
QT/QTc	:	421/396	ms
P/QRST	:	65/5/52	ms
RV5/SV1	:	0.677/0.755	mV

Report Confirmed by:



V1

V2

V3

6

Standard

Acc no: 4182XC008533	Name: Mrs. Jothi Parameswaran Nair	Age: 50 y	Sex: Female	Date: 23.03.24
----------------------	------------------------------------	-----------	-------------	----------------

RADIOLOGY DIVISION

US SCAN WHOLE ABDOMEN (TAS ONLY)

LIVER is normal in size (13.5 cm). Margins are regular. **Hepatic parenchyma shows mildly increased echogenicity.** No focal lesions seen. No dilatation of intrahepatic biliary radicles. CBD is not dilated. Portal vein is normal in caliber.

GALL BLADDER is distended and lumen clear. No calculi / polyp noted. Wall thickness is normal. No pericholecystic fluid seen.

SPLEEN is normal in size (7.9 cm) and parenchymal echotexture. No focal lesion seen.

PANCREAS Head and body visualized, appears normal in size and parenchymal echotexture. Pancreatic duct is not dilated.

RIGHT KIDNEY is normal in size (8.4 x 3.8 cm) and shows normal parenchymal echotexture. Cortico medullary differentiation is maintained. Parenchymal thickness is normal. No echogenic focus with shadowing suggestive of renal calculi seen. No dilatation of pelvicalyceal system seen. Ureter is not dilated. Perinephric spaces are normal.

LEFT KIDNEY is normal in size (9 x 4.1 cm) and shows normal parenchymal echotexture. Cortico medullary differentiation is maintained. Parenchymal thickness is normal. No echogenic focus with shadowing suggestive of renal calculi seen. No dilatation of pelvicalyceal system seen. Ureter is not dilated. Perinephric spaces are normal.

PARAAORTIC AREA obscured by bowel air. Excessive bowel gas noted.

URINARY BLADDER is distended, normal in wall thickness, lumen clear.

UTERUS measures 3.3 x 6.6 x 4.2 cm, myometrial echopattern normal. No focal lesions seen. Endometrial thickness is mm.

Larger right adnexal simple cyst measuring 5.2 x 3 cm, adjacent to the right ovary.

Both ovaries are normal. Right ovary measures 2.3 x 1 cm. Left ovary measures 2.9 x 1 cm. No fluid in pouch of Douglas.

No ascites or pleural effusion.

CONCLUSION:-

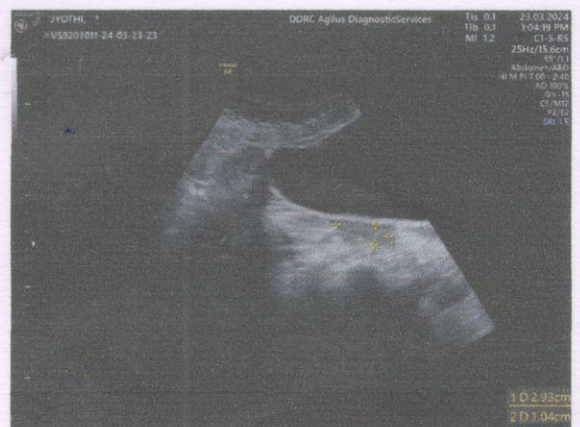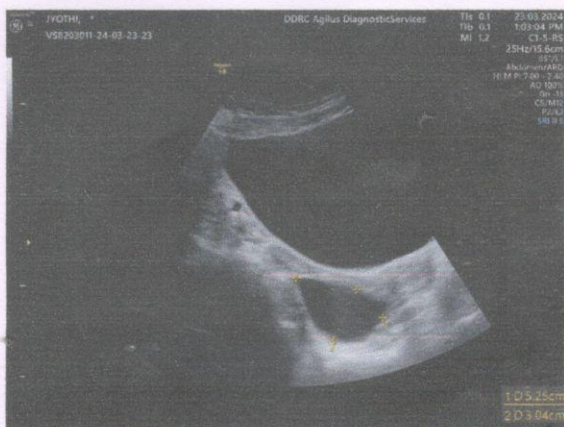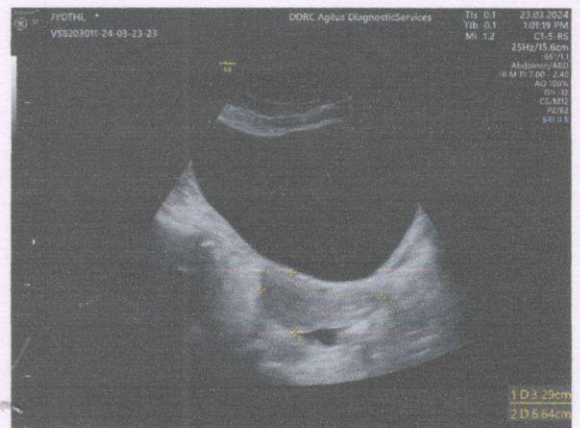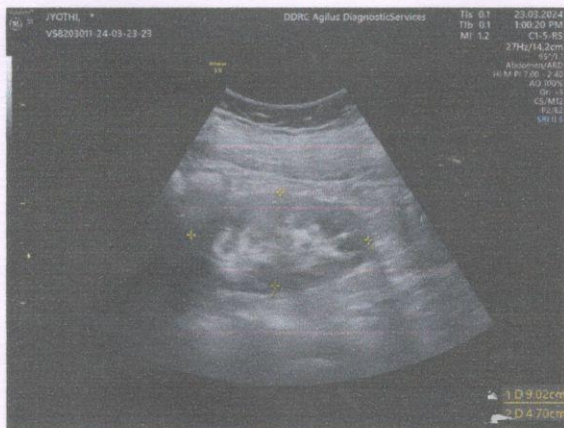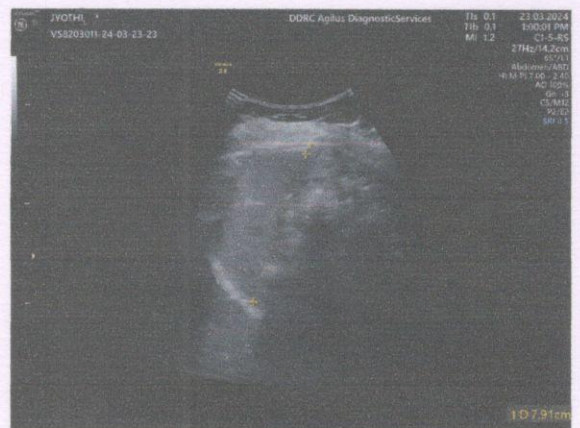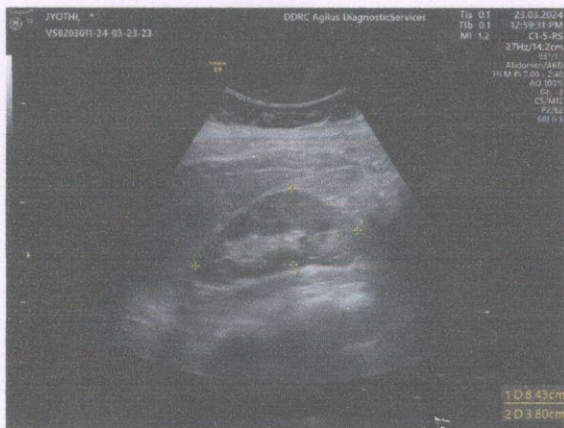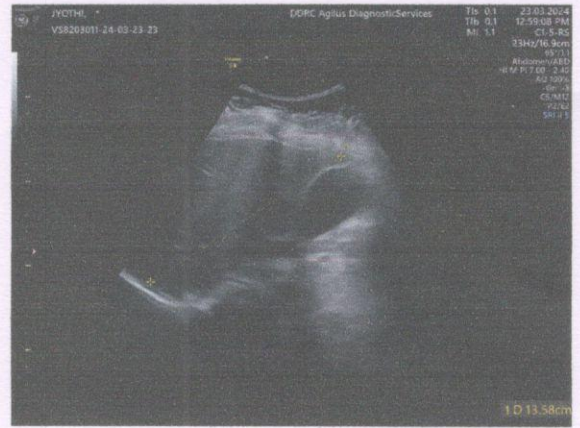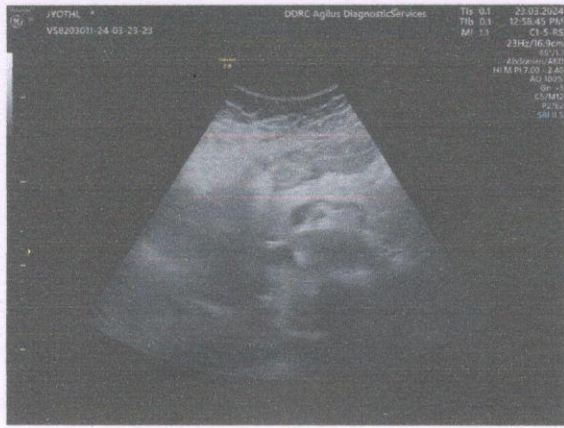- **Grade I fatty liver.**
- **Right para ovarian cyst.**


Dr. John MD
Consultant radiologist.

*Thanks for referral. Your feedback will be appreciated.
(Please bring relevant investigation reports during all visits)
Because of technical and technological limitations complete accuracy cannot be assured on imaging.
Suggested correlation with clinical findings and other relevant investigations consultations, and if required repeat imaging recommended in the event of controversies. AR*

DDRC agilus Pathlabs Limited.

Corp. Office : Express House, Second Floor, Opp. Pothys Silks, Banerjee Road, Kaloor -682017
Contact :- 93334 93334, Web :- www.ddrcagilus.com Email :- info.ddrc@agilus.in



MAMMOGRAM REPORT

RADIOLOGY DIVISION

Acc no:4182XC008533	Name: Mrs.Jothi Parameswaran Nair	Age:50 y	Sex: Female	Date: 23.03.24
---------------------	-----------------------------------	----------	-------------	----------------

Views Examined: CRANIOCAUDAL AND MEDIOLATERAL OBLIQUE

Craniocaudal and mediolateral oblique views of both breasts show predominantly fibro glandular tissue density

Both breasts are symmetrical.

No architectural distortion.

No mass lesion seen on both sides.

No abnormal clusters of micro calcification.

No significant axillary lymph nodes seen.

USG shows:

Normal parenchymal echotexture on both sides.

No focal hypoechoic or cystic areas seen.

No dilatation of intra mammary ducts.

Retroareolar and axillary regions on both sides are normal.

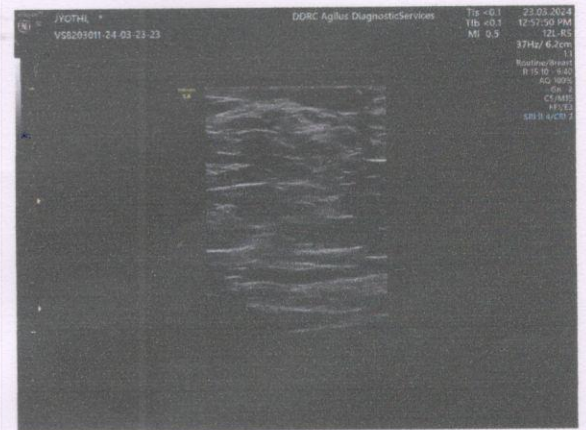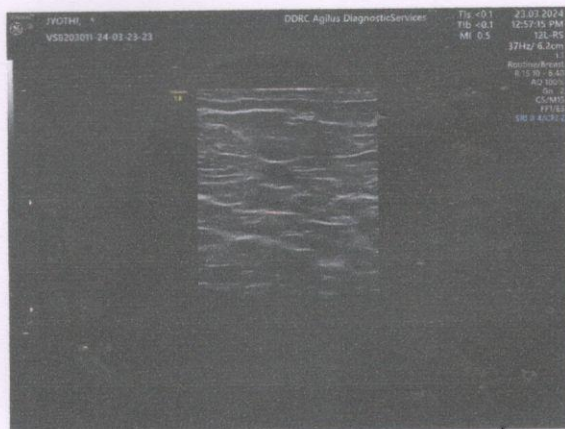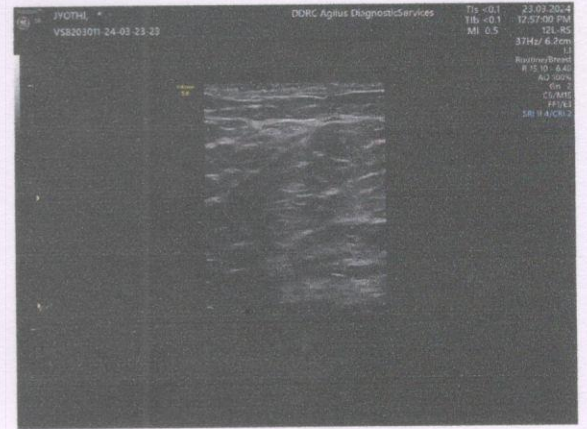
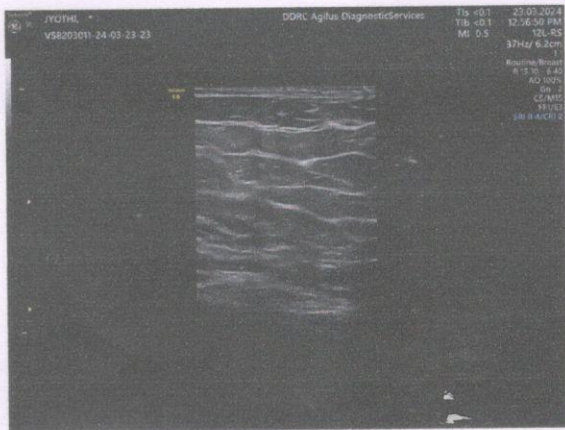
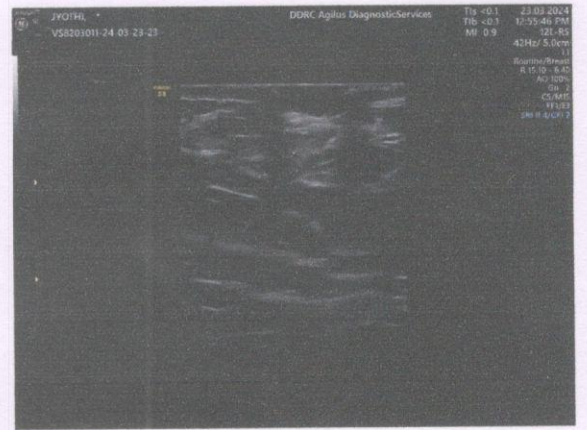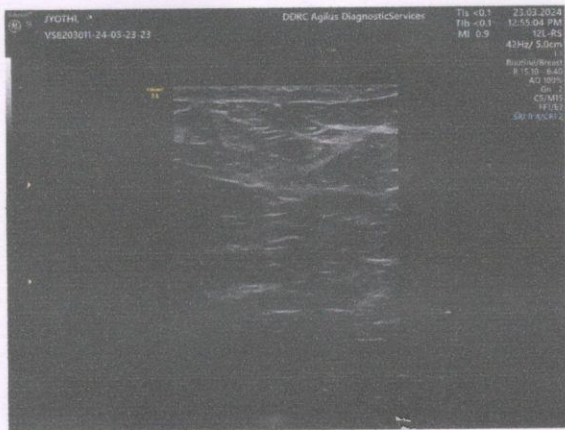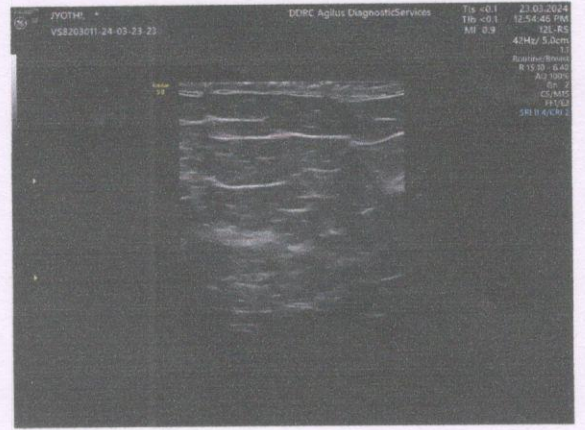
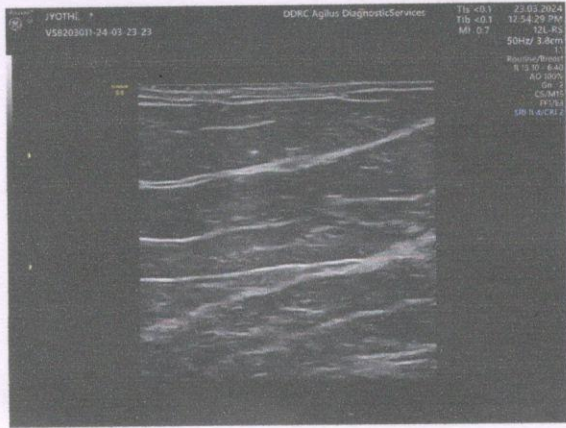CONCLUSION:-

➤ **No mass lesion, architectural distortion or calcification seen.**

BIRADS – Final assessment Category 1.


Dr. John MD
Consultant radiologist.

*Thanks, your feedback will be appreciated.
(Please bring relevant investigation reports during all visits).*



ECHO REPORT

RADIOLOGY DIVISION

SRD No :4182XC008533	Name:JOTHI PARAMESWARAN NAIR	Age:50Y	Sex:F	Date: 23/03/24
--------------------------------	-------------------------------------	----------------	--------------	-----------------------

Left Ventricle:-

	Diastole	Systole
IVS	1.09cm	1.20cm
LV	4.11cm	2.66cm
LVPW	1.15cm	1.20cm

EF -65% **FS- 35%**

AO	LA
3.18cm	3.39cm

PV - 0.76m/s
AV - 1.34m/s
MVE - 0.98m/s
MVA - 0.75m/s
E/A - 1.32

IMPRESSION:-

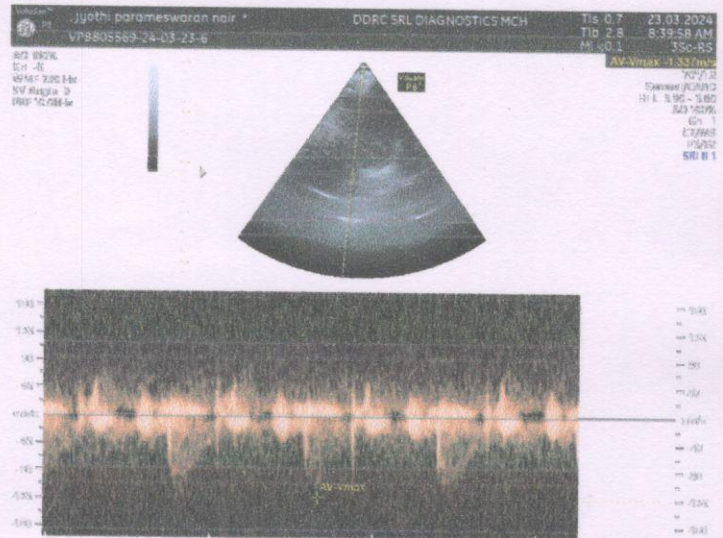
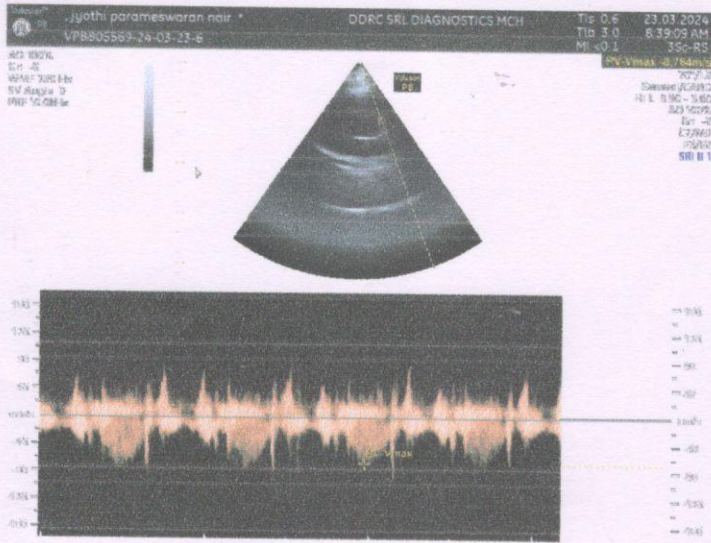
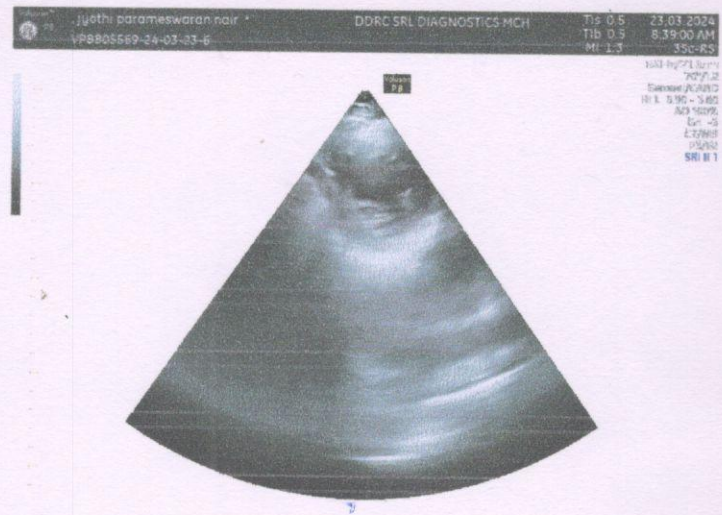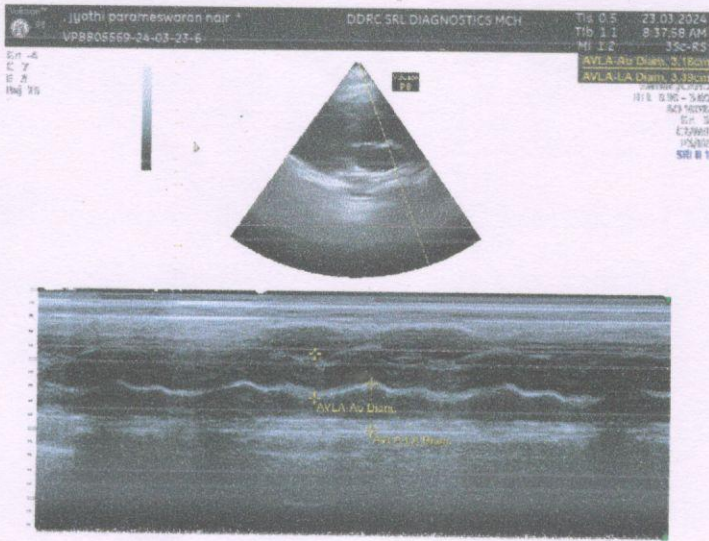
- Normal chambers dimension
- No RWMA
- Good LV systolic function
- Good RV function
- No diastolic dysfunction
- No AS,AR,MR,MS,TR,PAH
- IAS/IVS intact.No clots/effusion/coarctation

Dr. SAJITH. K
MD,DNB
CONSULTANT CARDIOLOGIST
Reg.No: 19436


Consultant Cardiologist



DDRC **agilus** Pathlabs Limited.



PATIENT NAME : JOTHI PARAMESWARAN NAIR

REF. DOCTOR : SELF

CODE/NAME & ADDRESS : CA00010147 -

MEDIWHEEL ARCOFEMI HEALTHCARE LIMITED
F701A, LADO SARAI, NEW DELHI, SOUTH DELHI,
DELHI,
SOUTH DELHI 110030
8800465156

ACCESSION NO : 4182XC008533

PATIENT ID : JOTHF0502744182

CLIENT PATIENT ID:

ABHA NO :

AGE/SEX : 50 Years Female

DRAWN :

RECEIVED : 23/03/2024 08:24:01

REPORTED : 27/03/2024 07:44:56

Test Report Status **Final**

Results

Units

MEDIWHEEL HEALTH CHECKUP ABOVE 40(F)2DECHO**ECG WITH REPORT****REPORT****REPORT GIVEN****2D - ECHO WITH COLOR DOPPLER****REPORT****REPORT GIVEN****USG ABDOMEN AND PELVIS****REPORT****REPORT GIVEN****CHEST X-RAY WITH REPORT****REPORT****REPORT GIVEN****MAMMOGRAPHY -BOTH****REPORT****REPORT GIVEN****HAEMATOMOLOGY****MEDIWHEEL HEALTH CHECKUP ABOVE 40(F)2DECHO****GLYCOSYLATED HEMOGLOBIN(HBA1C), EDTA WHOLE BLOOD**

HBA1C	5.5	Non-diabetic Adult < 5.7	%
		Pre-diabetes 5.7 - 6.4	

Nisha

DR NISHA UNNI, MBBS,MD
(RD),DNB (Reg.No:50162)
Consultant Radiologist

Vaishali

DR.VAISHALI RAJAN, MBBS DCP
(Pathology)
(Reg No - TCC 27150)
HOD - HAEMATOMOLOGY

Meera

DR. MEERA B S MBBS, MD
Biochemistry (Reg No - TCMC
53376)
CONSULTANT BIOCHEMIST



View Details



View Report

Page 1 Of 9

PERFORMED AT :

DDRC AGILUS PATHLABS LIMITED
ASTER SQUARE BUILDING, ULLOOR,
MEDICAL COLLEGE P.O
TRIVANDRUM, 695011
KERALA, INDIA
Tel : 93334 93334, Fax : CIN - U85190MH2006PTC161480
Email : customercare.ddrc@agilus.in



Patient Ref. No. 66600008306336

PATIENT NAME : JOTHI PARAMESWARAN NAIR

REF. DOCTOR : SELF

CODE/NAME & ADDRESS : CA00010147 -

MEDIWHEEL ARCOFEMI HEALTHCARE LIMITED
F701A, LADO SARAI, NEW DELHI, SOUTH DELHI,
DELHI,
SOUTH DELHI 110030
8800465156

ACCESSION NO : **4182XC008533**

PATIENT ID : JOTHF0502744182

CLIENT PATIENT ID:

ABHA NO :

AGE/SEX : 50 Years Female

DRAWN :

RECEIVED : 23/03/2024 08:24:01

REPORTED : 27/03/2024 07:44:56

Test Report Status	Final	Results	Units
--------------------	-------	---------	-------

MEAN PLASMA GLUCOSE	111.2	Diabetes diagnosis: > or = 6.5 Therapeutic goals: < 7.0 Action suggested : > 8.0 (ADA Guideline 2021) < 116.0	mg/dL
---------------------	-------	---	-------

BLOOD COUNTS, EDTA WHOLE BLOOD

HEMOGLOBIN	12.1	12.0 - 15.0	g/dL
RED BLOOD CELL COUNT	4.70	3.80 - 4.80	mil/ μ L
WHITE BLOOD CELL COUNT	3.78 Low	4.0 - 10.0	thou/ μ L
PLATELET COUNT	186	150 - 410	thou/ μ L

RBC AND PLATELET INDICES

HEMATOCRIT	38.0	36.0 - 46.0	%
MEAN CORPUSCULAR VOL	80.9 Low	83.0 - 101	fL
MEAN CORPUSCULAR HGB.	25.7 Low	27.0 - 32.0	pg
MEAN CORPUSCULAR HEMOGLOBIN CONCENTRATION	31.8	31.50 - 34.50	g/dL
RED CELL DISTRIBUTION WIDTH	13.9	11.60 - 14.0	%
MENTZER INDEX	17.2		
MEAN PLATELET VOLUME	8.7	6.80 - 10.90	fL

WBC DIFFERENTIAL COUNT

SEGMENTED NEUTROPHILS	58	40.0 - 80.0	%
LYMPHOCYTES	34	20.0 - 40.0	%
MONOCYTES	6	2.0 - 10.0	%
EOSINOPHILS	2	1.0 - 6.0	%
BASOPHILS	0	0.0 - 1.0	%
ABSOLUTE NEUTROPHIL COUNT	2.19	2.0 - 7.0	thou/ μ L



DR. VAISHALI RAJAN, MBBS DCP
(Pathology)
(Reg No - TCC 27150)
HOD - HAEMATOLOGY



DR. MEERA B S MBBS, MD
Biochemistry (Reg No - TCMC
53376)
CONSULTANT BIOCHEMIST

Page 2 Of 9



View Details



View Report

PERFORMED AT :

DDRC AGILUS PATHLABS LIMITED
ASTER SQUARE BUILDING, ULLOOR,
MEDICAL COLLEGE P.O
TRIVANDRUM, 695011
KERALA, INDIA
Tel : 93334 93334, Fax : CIN - U85190MH2006PTC161480
Email : customercare.ddrc@agilus.in



Patient Ref. No. 66600008306336

PATIENT NAME : JOTHI PARAMESWARAN NAIR

REF. DOCTOR : SELF

CODE/NAME & ADDRESS : CA00010147 -
 MEDIWHEEL ARCOFEMI HEALTHCARE LIMITED
 F701A, LADO SARAI, NEW DELHI,SOUTH DELHI,
 DELHI,
 SOUTH DELHI 110030
 8800465156

ACCESSION NO : **4182XC008533**
PATIENT ID : JOTHF0502744182
CLIENT PATIENT ID:
ABHA NO :

AGE/SEX : 50 Years Female
DRAWN :
RECEIVED : 23/03/2024 08:24:01
REPORTED : 27/03/2024 07:44:56

Test Report Status	Final	Results	Units	
ABSOLUTE LYMPHOCYTE COUNT		1.30	1.0 - 3.0	thou/ μ L
ABSOLUTE MONOCYTE COUNT		0.24	0.20 - 1.0	thou/ μ L
ABSOLUTE EOSINOPHIL COUNT		0.08	0.02 - 0.50	thou/ μ L
ABSOLUTE BASOPHIL COUNT		0.00		thou/ μ L
NEUTROPHIL LYMPHOCYTE RATIO (NLR)		1.7		

ERYTHROCYTE SEDIMENTATION RATE (ESR),EDTA BLOOD

SEDIMENTATION RATE (ESR) **27 High** 0 - 20 mm at 1 hr

SUGAR URINE - POST PRANDIAL

SUGAR URINE - POST PRANDIAL NOT DETECTED NOT DETECTED

SUGAR URINE - FASTING

SUGAR URINE - FASTING NOT DETECTED NOT DETECTED

IMMUNOHAEMATOLOGY

MEDIWHEEL HEALTH CHECKUP ABOVE 40(F)2DECHO

ABO GROUP & RH TYPE, EDTA WHOLE BLOOD

ABO GROUP TYPE A
 RH TYPE POSITIVE

METHOD : COLUMN AGGLUTINATION TECHNOLOGY

Interpretation(s)

DR.VAISHALI RAJAN, MBBS DCP
(Pathology)
(Reg No - TCC 27150)
HOD - HAEMATOLOGY

DR. MEERA B S MBBS, MD
Biochemistry (Reg No - TCMC
53376)
CONSULTANT BIOCHEMIST



View Details



View Report

PERFORMED AT :

DDRC AGILUS PATHLABS LIMITED
 ASTER SQUARE BUILDING, ULLOOR,
 MEDICAL COLLEGE P.O
 TRIVANDRUM, 695011
 KERALA, INDIA
 Tel : 93334 93334, Fax : CIN - U85190MH2006PTC161480
 Email : customercare.ddrc@agilus.in



PATIENT NAME : JOTHI PARAMESWARAN NAIR

REF. DOCTOR : SELF

CODE/NAME & ADDRESS : CA00010147 -

MEDIWHEEL ARCOFEMI HEALTHCARE LIMITED
F701A, LADO SARAI, NEW DELHI, SOUTH DELHI,
DELHI,
SOUTH DELHI 110030
8800465156

ACCESSION NO : 4182XC008533

PATIENT ID : JOTHF0502744182

CLIENT PATIENT ID:

ABHA NO :

AGE/SEX : 50 Years Female

DRAWN :

RECEIVED : 23/03/2024 08:24:01

REPORTED : 27/03/2024 07:44:56

Test Report Status **Final**

Results

Units

ABO GROUP & RH TYPE, EDTA WHOLE BLOOD-Blood group is identified by antigens and antibodies present in the blood. Antigens are protein molecules found on the surface of red blood cells. Antibodies are found in plasma. To determine blood group, red cells are mixed with different antibody solutions to give A,B,O or AB.

Disclaimer: "Please note, as the results of previous ABO and Rh group (Blood Group) for pregnant women are not available, please check with the patient records for availability of the same."

The test is performed by both forward as well as reverse grouping methods.

BIO CHEMISTRY

MEDIWHEEL HEALTH CHECKUP ABOVE 40(F)2DECHO

BLOOD UREA NITROGEN (BUN), SERUM

BLOOD UREA NITROGEN 7 Adult(<60 yrs) : 6 to 20 mg/dL

BUN/CREAT RATIO

BUN/CREAT RATIO 7.4

CREATININE, SERUM

CREATININE 0.94 18 - 60 yrs : 0.6 - 1.1 mg/dL


GLUCOSE, POST-PRANDIAL, PLASMA


GLUCOSE, POST-PRANDIAL, PLASMA 131
Diabetes Mellitus : > or = 200. mg/dL
Impaired Glucose tolerance/
Prediabetes : 140 - 199.
Hypoglycemia : < 55.

GLUCOSE FASTING, FLUORIDE PLASMA

FBS (FASTING BLOOD SUGAR) 101
Diabetes Mellitus : > or = 126. mg/dL
Impaired fasting Glucose/
Prediabetes : 101 - 125.
Hypoglycemia : < 55.

Page 4 Of 9


DR. MEERA B S MBBS, MD
Biochemistry (Reg No - TCMC
53376)
CONSULTANT BIOCHEMIST


DR. VAISHALI RAJAN, MBBS DCP
(Pathology)
(Reg No - TCC 27150)
HOD - HAEMATOLOGY



View Details



View Report

PERFORMED AT :

DDRC AGILUS PATHLABS LIMITED
ASTER SQUARE BUILDING, ULLOOR,
MEDICAL COLLEGE P.O
TRIVANDRUM, 695011
KERALA, INDIA
Tel : 93334 93334, Fax : CIN - U85190MH2006PTC161480
Email : customercare.ddrc@agilus.in



Patient Ref. No. 66600008306336

PATIENT NAME : JOTHI PARAMESWARAN NAIR

REF. DOCTOR : SELF

CODE/NAME & ADDRESS : CA00010147 -

MEDIWHEEL ARCOFEMI HEALTHCARE LIMITED
F701A, LADO SARAI, NEW DELHI, SOUTH DELHI,
DELHI,
SOUTH DELHI 110030
8800465156

ACCESSION NO : **4182XC008533**

PATIENT ID : JOTHF0502744182

CLIENT PATIENT ID:

ABHA NO :

AGE/SEX : 50 Years Female

DRAWN :

RECEIVED : 23/03/2024 08:24:01

REPORTED : 27/03/2024 07:44:56

Test Report Status **Final**

Results

Units

LIVER FUNCTION TEST WITH GGT

BILIRUBIN, TOTAL	1.14	General Range : < 1.1	mg/dL
BILIRUBIN, DIRECT	0.42 High	General Range : < 0.3	mg/dL
BILIRUBIN, INDIRECT	0.72	General Range : < 0.85	mg/dL
TOTAL PROTEIN	7.0	Ambulatory : 6.4 - 8.3 Recumbant : 6 - 7.8	g/dL
ALBUMIN	4.6	20-60yrs : 3.5 - 5.2	g/dL
GLOBULIN	2.4	General Range : 2 - 3.5 Premature Neonates : 0.29 - 1.04	g/dL
ALBUMIN/GLOBULIN RATIO	1.9	General Range : 1.1 - 2.5	RATIO
ASPARTATE AMINOTRANSFERASE (AST/SGOT)	21	Adults : < 33	U/L
ALANINE AMINOTRANSFERASE (ALT/SGPT)	19	Adults : < 34	U/L
ALKALINE PHOSPHATASE	129	Adult (<60yrs) : 35 - 105	U/L
GAMMA GLUTAMYL TRANSFERASE (GGT)	8	Adult (female) : < 40	U/L

TOTAL PROTEIN, SERUM


TOTAL PROTEIN	7.0	Ambulatory : 6.4 - 8.3 Recumbant : 6 - 7.8	g/dL
---------------	-----	---	------

URIC ACID, SERUM

URIC ACID	3.8	Adults : 2.4-5.7	mg/dL
-----------	-----	------------------	-------

BIOCHEMISTRY - LIPID**MEDIWHEEL HEALTH CHECKUP ABOVE 40(F)2DECHO**

Page 5 Of 9


DR. MEERA B S MBBS, MD
Biochemistry (Reg No - TCMC
53376)
CONSULTANT BIOCHEMIST



View Details



View Report

PERFORMED AT :

DDRC AGILUS PATHLABS LIMITED
ASTER SQUARE BUILDING, ULLOOR,
MEDICAL COLLEGE P.O
TRIVANDRUM, 695011
KERALA, INDIA
Tel : 93334 93334, Fax : CIN - U85190MH2006PTC161480
Email : customercare.ddrc@agilus.in



Patient Ref. No. 66600008306336

PATIENT NAME : JOTHI PARAMESWARAN NAIR **REF. DOCTOR : SELF**
CODE/NAME & ADDRESS : CA00010147 -
 MEDIWHEEL ARCOFEMI HEALTHCARE LIMITED
 F701A, LADO SARAI, NEW DELHI, SOUTH DELHI,
 DELHI,
 SOUTH DELHI 110030
 8800465156
ACCESSION NO : 4182XC008533
PATIENT ID : JOTHF0502744182
CLIENT PATIENT ID:
ABHA NO :
AGE/SEX : 50 Years Female
DRAWN :
RECEIVED : 23/03/2024 08:24:01
REPORTED : 27/03/2024 07:44:56

Test Report Status	Final	Results	Units
--------------------	-------	---------	-------

LIPID PROFILE, SERUM

CHOLESTEROL	208	Desirable : < 200 Borderline : 200-239 High : >or= 240	mg/dL
TRIGLYCERIDES	75	Normal : < 150 High : 150-199 Hypertriglyceridemia : 200-499 Very High : > 499	mg/dL
HDL CHOLESTEROL	60	General range : 40-60	mg/dL
LDL CHOLESTEROL, DIRECT	140	Optimum : < 100 Above Optimum : 100-129 Borderline High : 130-159 High : 160-189 Very High : >or= 190	mg/dL
NON HDL CHOLESTEROL	148	Desirable : < 130 Above Desirable : 130 -159 Borderline High : 160 - 189 High : 190 - 219 Very high : > / = 220	mg/dL
VERY LOW DENSITY LIPOPROTEIN CHOL/HDL RATIO	15.0 3.5	</= 30.0 Low Risk : 3.3 - 4.4 Average Risk : 4.5 - 7.0 Moderate Risk : 7.1 - 11.0 High Risk : > 11.0	mg/dL
LDL/HDL RATIO	2.3	Desirable/Low Risk - 0.5-3 Borderline/Moderate Risk- 3.1-6 High Risk- >6.0	

HISTOPATHOLOGY

MEDIWHEEL HEALTH CHECKUP ABOVE 40(F)2DECHO

CYTOLOGY - CS (PAP SMEAR)

DR. MEERA B S MBBS, MD
Biochemistry (Reg No - TCMC 53376)
CONSULTANT BIOCHEMIST

DR. ALISHA ALIYAR MBBS, M.D
Pathology(Reg No: TCMC62966)
CONSULTANT PATHOLOGIST



View Details



View Report

PERFORMED AT :

DDRC AGILUS PATHLABS LIMITED
 ASTER SQUARE BUILDING, ULLOOR,
 MEDICAL COLLEGE P.O
 TRIVANDRUM, 695011
 KERALA, INDIA
 Tel : 93334 93334, Fax : CIN - U85190MH2006PTC161480
 Email : customercare.ddrc@agilus.in



Patient Ref. No. 66600008306336

PATIENT NAME : JOTHI PARAMESWARAN NAIR

REF. DOCTOR : SELF

CODE/NAME & ADDRESS : CA00010147 -

MEDIWHEEL ARCOFEMI HEALTHCARE LIMITED
F701A, LADO SARAI, NEW DELHI, SOUTH DELHI,
DELHI,
SOUTH DELHI 110030
8800465156

ACCESSION NO : **4182XC008533**

PATIENT ID : JOTHF0502744182

CLIENT PATIENT ID:

ABHA NO :

AGE/SEX : 50 Years Female

DRAWN :

RECEIVED : 23/03/2024 08:24:01

REPORTED : 27/03/2024 07:44:56

Test Report Status **Final**

Results

Units

CYTOLOGY - CS (PAP SMEAR)

CERVICAL CYTOLOGY REPORT (2014) BETHESDA SYSTEM.

CR No:471/3/24

SPECIMEN TYPE : Conventional pap smear.

SPECIMEN ADEQUACY : Satisfactory for evaluation. Transformation zone component present.

GENERAL CATEGORIZATION : Negative for intraepithelial lesion / malignancy.

INTERPRETATION /RESULT : Negative for intraepithelial lesion / malignancy.

OTHER MALIGNANT NEOPLASM : Nil


EDUCATIONAL NOTES & SUGGESTIONS: Nil

SPECIALISED CHEMISTRY - HORMONE**MEDIWHEEL HEALTH CHECKUP ABOVE 40(F)2DECHO****THYROID PANEL, SERUM**

T3	97.90	Adult : 80-200	ng/dL
T4	8.66	Adults : 4.5-12.1	µg/dl
TSH 3RD GENERATION	1.360	Non-Pregnant : 0.4-4.2	µIU/mL
		Pregnant Trimester-wise :	
		1st : 0.1 - 2.5	
		2nd : 0.2 - 3	
		3rd : 0.3 - 3	



DR. MEERA B S MBBS, MD
Biochemistry (Reg No - TCMC
53376)
CONSULTANT BIOCHEMIST



DR. VAISHALI RAJAN, MBBS DCP
(Pathology)
(Reg No - TCC 27150)
HOD - HAEMATOLOGY

Page 7 Of 9



View Details



View Report

PERFORMED AT :

DDRC AGILUS PATHLABS LIMITED
ASTER SQUARE BUILDING, ULLOOR,
MEDICAL COLLEGE P.O
TRIVANDRUM, 695011
KERALA, INDIA
Tel : 93334 93334, Fax : CIN - U85190MH2006PTC161480
Email : customercare.ddrc@agilus.in



Patient Ref. No. 66600008306336

PATIENT NAME : JOTHI PARAMESWARAN NAIR

REF. DOCTOR : SELF

CODE/NAME & ADDRESS : CA00010147 -
 MEDIWHEEL ARCOFEMI HEALTHCARE LIMITED
 F701A, LADO SARAI, NEW DELHI, SOUTH DELHI,
 DELHI,
 SOUTH DELHI 110030
 8800465156

ACCESSION NO : 4182XC008533
PATIENT ID : JOTHF0502744182
CLIENT PATIENT ID:
ABHA NO :

AGE/SEX : 50 Years Female
DRAWN :
RECEIVED : 23/03/2024 08:24:01
REPORTED : 27/03/2024 07:44:56

Test Report Status	Final	Results	Units
--------------------	-------	---------	-------

CLINICAL PATH - URINALYSIS

MEDIWHEEL HEALTH CHECKUP ABOVE 40(F)2DECHO

PHYSICAL EXAMINATION, URINE

COLOR	PALE YELLOW
APPEARANCE	CLEAR

CHEMICAL EXAMINATION, URINE

PH	7.0	4.7 - 7.5
SPECIFIC GRAVITY	1.003	1.003 - 1.035
PROTEIN	NEGATIVE	NOT DETECTED
GLUCOSE	NEGATIVE	NOT DETECTED
KETONES	NEGATIVE	NOT DETECTED
BLOOD	NEGATIVE	NOT DETECTED
BILIRUBIN	NEGATIVE	NOT DETECTED
UROBILINOGEN	NORMAL	NORMAL
METHOD : DIPSTICK		
NITRITE	NEGATIVE	NOT DETECTED

MICROSCOPIC EXAMINATION, URINE

RED BLOOD CELLS	NOT DETECTED	NOT DETECTED	/HPF
WBC	0-1	0-5	/HPF
EPITHELIAL CELLS	0-1	0-5	/HPF
CASTS	NEGATIVE		
CRYSTALS	NEGATIVE		
REMARKS	NIL		

METHOD : AUTOMATED ANALYSER, MICROSCOPY

DR.VAISHALI RAJAN, MBBS DCP
 (Pathology)
 (Reg No - TCC 27150)
 HOD - HAEMATOLOGY



View Details



View Report

PERFORMED AT :

DDRC AGILUS PATHLABS LIMITED
 ASTER SQUARE BUILDING, ULLOOR,
 MEDICAL COLLEGE P.O
 TRIVANDRUM, 695011
 KERALA, INDIA
 Tel : 93334 93334, Fax : CIN - U85190MH2006PTC161480
 Email : customercare.ddrc@agilus.in



Patient Ref. No. 66600008306336

PATIENT NAME : JOTHI PARAMESWARAN NAIR
REF. DOCTOR : SELF
CODE/NAME & ADDRESS : CA00010147 -

 MEDIWHEEL ARCOFEMI HEALTHCARE LIMITED
 F701A, LADO SARAI, NEW DELHI, SOUTH DELHI,
 DELHI,
 SOUTH DELHI 110030
 8800465156

ACCESSION NO : 4182XC008533
PATIENT ID : JOTHF0502744182
CLIENT PATIENT ID:
ABHA NO :
AGE/SEX : 50 Years Female
DRAWN :
RECEIVED : 23/03/2024 08:24:01
REPORTED : 27/03/2024 07:44:56
Test Report Status Final
Results
Units
****End Of Report****

 Please visit www.srlworld.com for related Test Information for this accession


DR.VAISHALI RAJAN, MBBS DCP
(Pathology)
(Reg No - TCC 27150)
HOD - HAEMATOLOGY

Page 9 Of 9



View Details



View Report

PERFORMED AT :

 DDRC AGILUS PATHLABS LIMITED
 ASTER SQUARE BUILDING, ULLOOR,
 MEDICAL COLLEGE P.O
 TRIVANDRUM, 695011
 KERALA, INDIA
 Tel : 93334 93334, Fax : CIN - U85190MH2006PTC161480
 Email : customercare.ddrc@agilus.in

Patient Ref. No. 66600008306336

NAME : MRS.JYOTHI PARAMESWARAN NAIR	AGE:50/F	DATE: 23/03/2024
-------------------------------------	----------	------------------

CHEST X-RAY REPORT

CHEST X-RAY PA VIEW : Trachea central
 No cardiomegaly
 Normal vascularity
 No parenchymal lesion.
 Costophrenic and cardiophrenic angles clear

➤ **IMPRESSION** : Normal Chest Xray

ELECTRO CARDIOGRAM : NSR:-53/minute
 No evidence of ischaemia

➤ **IMPRESSION** : Normal Ecg.




Dr. SERIN LOPEZ. MBBS
 Reg. No. 77656
 MEDICAL OFFICER
 DDRC AGILUS PATHLABS LTD.
 Aster Square, Medical College. P.O, TVM

Company name: **MEDIWHEEL**

DR SERIN LOPEZ MBBS
 Reg No 77656
DDRC AGILUS PATHLABS LTD