

**HEALTH CHECK UP**

Name : Raj Kumar

Date : 23-3-24

Age : 55

Sex : Male / Female

Marital status : Married / Single

**PERSONAL HISTORY**

Habits : Smoking / Tobacco & Snuff / Alcohol No

Drug allergy if any : Nil

Medical : HTN Medicines

Surgical : Nil

Height 171 cm Weight 73 Kg. BP..... Pulse .....

Vision : Rt ..... Lt. .... With Spectacles ..... Rt. .... Lt. ....

Colour Vision : Normal / Abnormal Near Vision .....

**FAMILY HISTORY**

Father ..... Mother ..... Siblings .....

CVS : Heart Sound ..... Normal Murmurs ..... Absent Thrills ..... Absent

RS : Rate ..... /mt Breath sounds ..... Normal Adventitious ..... Absent

ABDOMEN : Tenderness ..... Absent Rigidity ..... Absent Bowel sound ..... Normal

Liver ..... NAD Kidney ..... NAD Hernia ..... Absent

CNS : Cranial Nerves ..... NAD Sensory System..... NAD Motor System..... NAD

ENT ..... NAD

Remarks

**Dr. Bharti Jeswani**  
MBBS

**Dr. Seema Kale**  
MBBS, MD

**Dr. S. K. Suri**  
MBBS

**Dr. Meenakshi**  
MBBS

HOME SAMPLE COLLECTION FACILITY AVAILABLE

Licensee : Bharti Medicare Pvt. Ltd. The Apollo Clinic, C-70, Major Sudesh Kumar Marg, Opp. Madhav Park, Near Main Market, Rajouri Garden, New Delhi-110 027  
Phone : (011) 2591 8222 / 8333 / 8444, 9811061009, E-mail : rajourigarden@theapolloclicin.com, Website : www.apolloclicinrajourigarden.com

MSME UAM NO. : DL11E0021531



ID: 241

raj kumar

Male 55Years

171cm 73kg 120/70 mmHg

Req. No. :

Room No. : 5

23-03-2024 12:41:54

HR : 70 bpm

P : 122 ms

PR : 158 ms

QRS : 104 ms

QT/QTcBz : 364/393 ms

P/QRS/T : 76/93/61 °

RV5/SV1 : 1.568/0.240 mV

Diagnosis Information:

Sinus rhythm

Rightward axis

Borderline ECG

Report Confirmed by:

V1

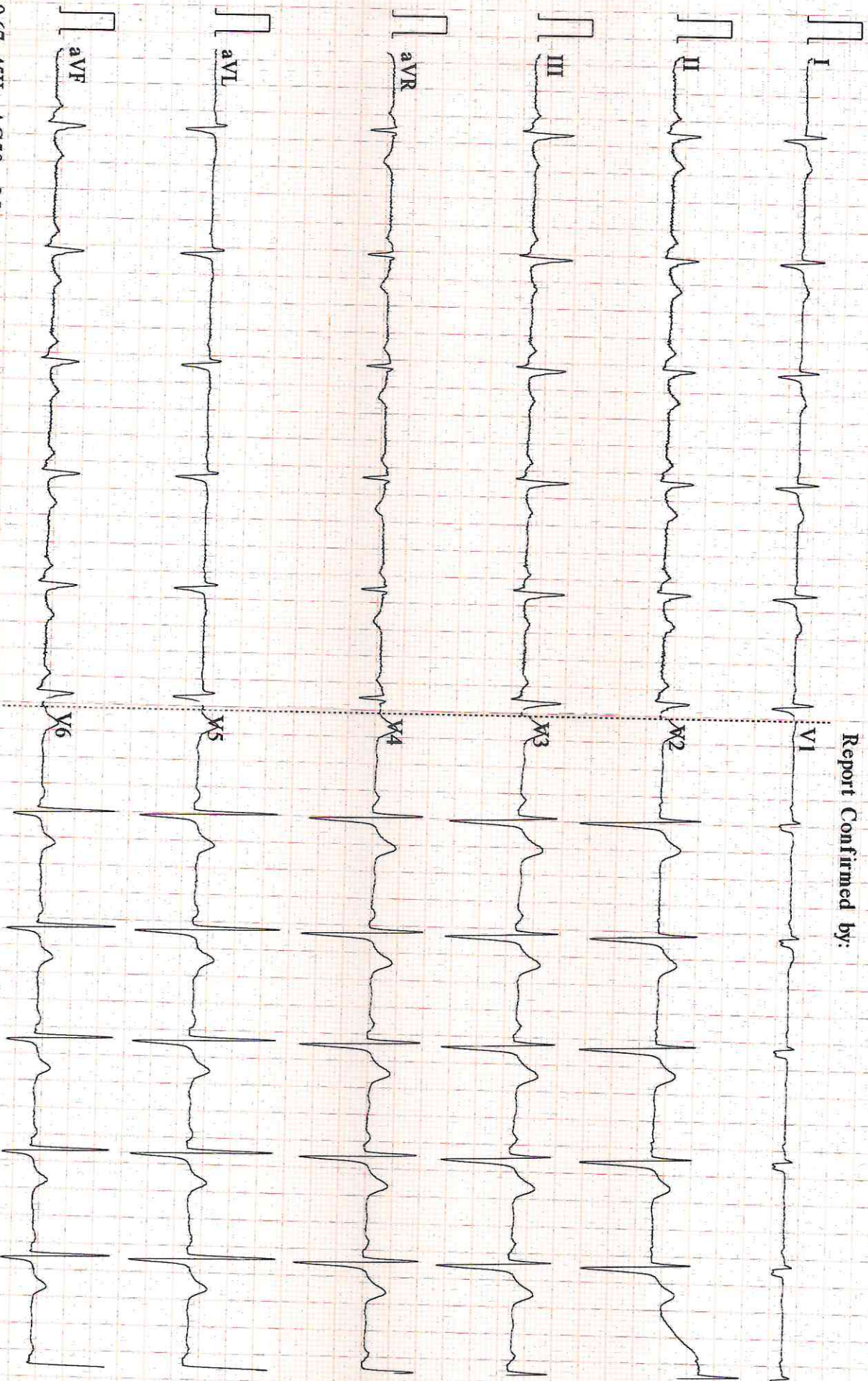
X2

X3

X4

X5

X6



I, Rajkumar working in Union Bank of India. I am not interested/willing to give Stool Test.

Rajkumar  
23/03/2024

• CLINICAL CORRELATION IS ESSENTIAL FOR FINAL DIAGNOSIS. • IF THE TESTS RESULTS ARE UNEXPECTED PLEASE CONTACT THE LABORATORY.  
• ALL THE CONGENITAL ANOMOLIES IN THE FETUS MAY NOT BE DIAGNOSED IN ULTRASONOGRAPHY. • THIS REPORT IS NOT VALID FOR MEDICOLEGAL PURPOSE.

Licensee : Bharti Medicare Pvt. Ltd. The Apollo Clinic, C-70, Major Sudesh Kumar Marg, Opp. Madhav Park, Near Main Market, Rajouri Garden, New Delhi-110 027  
Phone : (011) 2591 8222 / 8333 / 8444, 9811061009, E-mail : rajourigarden@theapolloclinic.com, Website : www.apolloclinicrajourigarden.com

**MSME UAM NO. : DL11E0021531**



NAME: MR RAJ KUMAR  
REF

AGE: 55 / Sex / M  
DATE 23/03 /2024

**ECHO ADULT (COLOUR DOPPLER)**

DIMENSIONS			NORMAL	DIMENSIONS			NORMAL
Ao (ed)	38.0 mm		(1.5 cm/m <sup>2</sup> )	IVS (Ed)	09.0 mm		(0.6-1.2cm)
LA (es)	37.0 mm		(1.5 cm/m <sup>2</sup> )	LVPW (Ed)	09.0 mm		(.6-1.1cm)
RVID (ed)	Normal		(0.9cm/m <sup>2</sup> )	EF	60.0 %		(0.62-0.85)
LVID (ed)	49.0 mm		(2.6-3.4 cm/m <sup>2</sup> )	FS	30.0		
LVID (es)	29.0 mm						


**MORPHOLOGICAL DATA**

Mitral Valve	Normal	Interatrial Septum	Normal
Aortic Valve	Normal	Interventricular Septum	Normal
Tricuspid Valve	Normal	Pulmonary Artery	Normal
Pulmonary Valve	Normal	Aorta	Normal
Right Ventricle	Normal	Right Atrium	Normal
Left Ventricle	Normal	Left Atrium	Normal
Pericardium	Normal		

Colour Doppler Normal, NO PAH, IVC NORMAL, LV DIASTOLIC FUNCTION NORMAL

Wall motion Normal

IMPRESSION : NORMAL STUDY

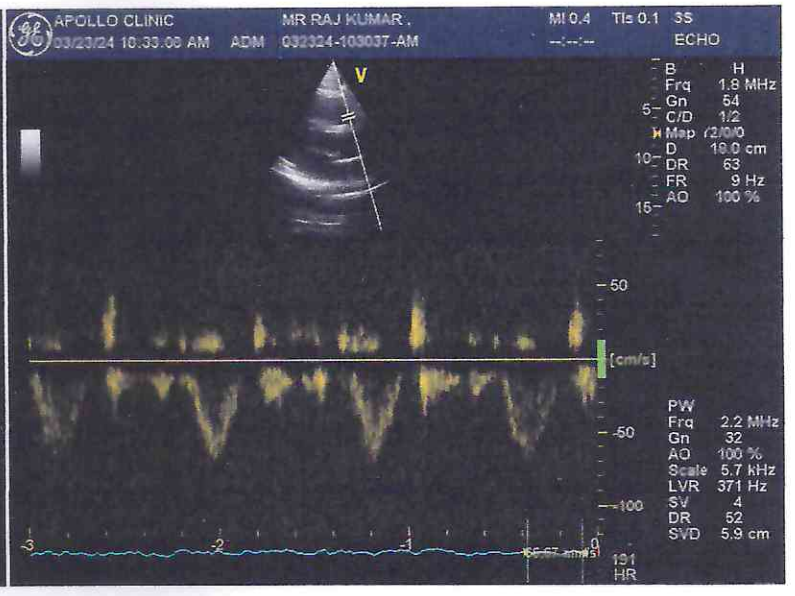
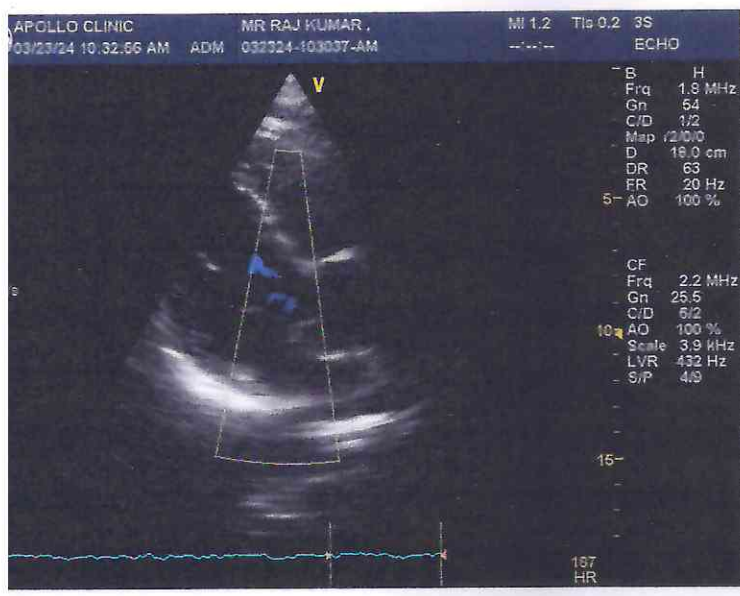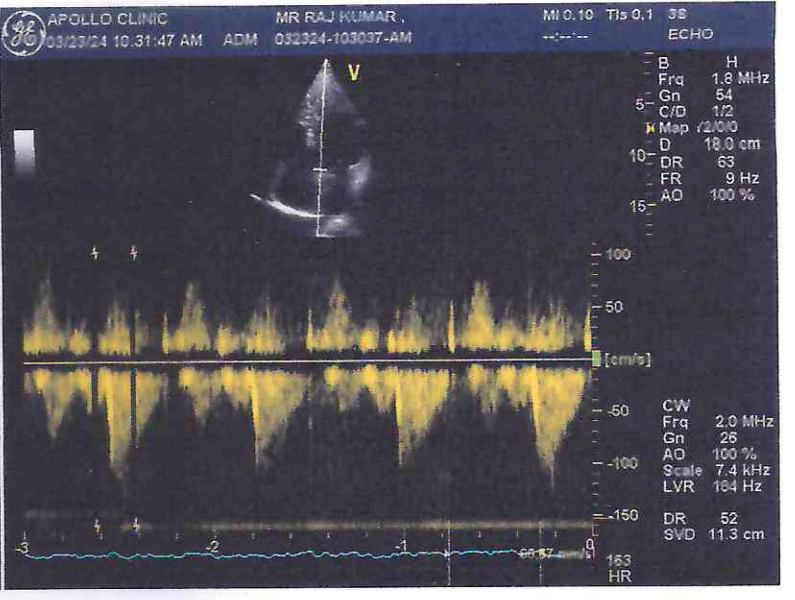
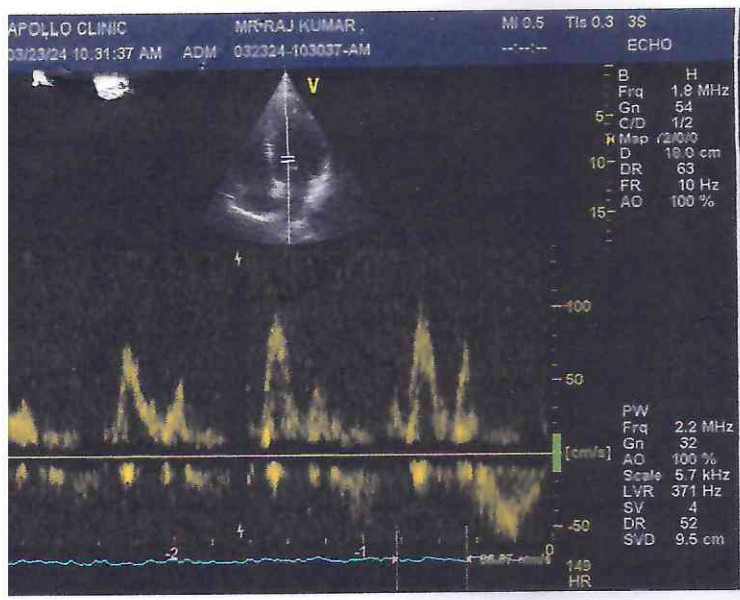


**DR SEEMA KALE MD**  
SEN. (PHYSICIAN)

• CLINICAL CORRELATION IS ESSENTIAL FOR FINAL DIAGNOSIS. • IF THE TESTS RESULTS ARE UNEXPECTED PLEASE CONTACT THE LABORATORY.  
• ALL THE CONGENITAL ANAMOLIES IN THE FETUS MAY NOT BE DIAGNOSED IN ULTRASONOGRAPHY. • THIS REPORT IS NOT VALID FOR MEDICOLEGAL PURPOSE.

Licensee : Bharti Medicare Pvt. Ltd. The Apollo Clinic, C-70, Major Sudesh Kumar Marg, Opp. Madhav Park, Near Main Market, Rajouri Garden, New Delhi-110 027  
Phone : (011) 2591 8222 / 8333 / 8444, 9811061009, E-mail : rajourigarden@theapolloclicin.com, Website : www.apolloclicinrajourigarden.com

**MSME UAM NO. : DL11E0021531**



**Patient Name** : Mr. Raj Kumar  
**UHID/MR No.** : FRAJ.0000244423  
**Visit Date** : 23-03-2024 08:40  
**Sample Collected on** : 23-03-2024 08:48  
**Sample No** : WHB1383411  
**Ref Doctor** : SELF  
**Emp/Auth/TPA ID** : 33443  
**Sponsor Name** : MEDIWHEELS HEALTH CARE

**Age / Gender** : 55Y/Male  
**OP Visit No** : FRAJOPV119978  
**Reported on** : 26-03-2024 11:20  
**Specimen** : Whole Blood (Edta)

**Pres Doctor:** :


## DEPARTMENT OF LABORATORY MEDICINE

TEST NAME	RESULT	BIOLOGICAL REFERENCE INTERVALS	UNITS
<b>COMPLETE BLOOD COUNT</b>			
Hb (Haemoglobin) Method: Non Cyanide	13.7	13 - 18	gm/dl
PCV/Haematocrit Method: RBC pulse height detect	43.4	40 - 50	%
ESR. Method: Westergren's Method	09	0 - 20	mm/1st Hr
TLC Method: DC Detection Method	6700	4000 - 10000	/cumm.
RBC COUNT. Method: DC Detection Method	4.5*	5 - 6	Million/cmm
PLATELET COUNT Method: DC Detection Method	1.52	1.5 - 4.1	lakh/cumm.
MCV Method: Derived	96.4	77 - 98	fl
MCH Method: Derived	30.5	27 - 32	pg
MCHC Method: Derived	31.6	31.5 - 34.5	gm/dl
NEUTROPHIL Method: Microscopy	70	40 - 70	%
LYMPHOCYTE Method: Microscopy	27	20 - 40	%
EOSINOPHIL Method: Microscopy	01	1.0 - 6.0	%
MONOCYTE Method: Microscopy	02	2.0 - 10.0	%
<b>BLOOD GROUP AND RH TYPE</b>			
ABO Group	O		
RH	Positive		

End of the report

Results are to be correlated clinically

Lab Technician / Technologist  
Sogita

  
 Dr. Prashant Purwar  
 MBBS, DCP  
 Consultant Pathologist

• CLINICAL CORRELATION IS ESSENTIAL FOR FINAL DIAGNOSIS. • IF THE TESTS RESULTS ARE UNEXPECTED PLEASE CONTACT THE LABORATORY.  
 • ALL THE CONGENITAL ANAMOLIES IN THE FETUS MAY NOT BE DIAGNOSED IN ULTRASONOGRAPHY. • THIS REPORT IS NOT VALID FOR MEDICOLEGAL PURPOSE.

Licensee : Bharti Medicare Pvt. Ltd. The Apollo Clinic, C-70, Major Sudesh Kumar Marg, Opp. Madhav Park, Near Main Market, Rajouri Garden, New Delhi-110 027  
 Phone : (011) 2591 8222 / 8333 / 8444, 9811061009, E-mail : rajourigarden@theapolloclinic.com, Website : www.apolloclinicrajourigarden.com

MSME UAM NO. : DL11E0021531



Patient Name : Mr. Raj Kumar  
 UHID/MR No. : FRAJ.0000244423  
 Visit Date : 23-03-2024 08:40  
 Sample Collected on : 23-03-2024 08:48  
 Ref Doctor : SELF  
 Emp/Auth/TPA ID : 33443  
 Sponsor Name : MEDIWHEELS HEALTH CARE

Age / Gender : 55Y/Male  
 OP Visit No : FRAJOPV119978  
 Reported on : 24-03-2024 13:02  
 Specimen : Plasma(Fluoride)  
 Pres Doctor: :

DEPARTMENT OF LABORATORY MEDICINE

TEST NAME	RESULT	BIOLOGICAL REFERENCE INTERVALS	UNITS
<b>GLUCOSE - ( FASTING )</b>			
GLUCOSE - ( FASTING ) Method: (GOD-POD).	109	70 - 110	mg/dL
<b>GLUCOSE - ( POST PRANDIAL )</b>			
GLUCOSE - ( POST PRANDIAL ) Method: (GOD-POD)	145*	70-140	mg/dl
<b>GLYCOSYLATED HEMOGLOBIN (HBA1C)</b>			
GLYCOSYLATED HEMOGLOBIN (HBA1C) - WHOLE BLOOD Method: BORONATE AFFINITY	6.0	4.2 - 6.0	%
<b>LIPID PROFILE TEST (PACKAGE)</b>			
CHOLESTEROL Method: CHOD - PAP	171	Desirable < 200 Borderline High : 200-239 High : > 240	mg/dl
Triglyceride Method: GPO-PAP	134	50-200	mg/dl
HDL Method: DIRECT	56.1*	30 - 50	mg/dl
LDL Method: DIRECT	88.1	60 - 100	mg/dl
VLDL Method: Calculated	26.8	<40	mg/dl
CHOLESTEROL / HDL RATIO Method: Calculated.	3.0	0 - 4.5	
<b>Thyroid Profile 2(Free T4, Free T3 And TSH)</b>			
Serum FT3	4.0	3.2 - 5.9	pmol/l
Serum FT4	13.9	10.6 - 21.0	pmol/l
Serum TSH	1.7	0.38 - 5.0	uIU/ml

End of the report

Results are to be correlated clinically

Lab Technician / Technologist  
Yogita

Dr. Prashant Purwar  
MBBS, DCP  
Consultant Pathologist

• CLINICAL CORRELATION IS ESSENTIAL FOR FINAL DIAGNOSIS. • IF THE TESTS RESULTS ARE UNEXPECTED PLEASE CONTACT THE LABORATORY.  
 • ALL THE CONGENITAL ANOMOLIES IN THE FETUS MAY NOT BE DIAGNOSED IN ULTRASONOGRAPHY. • THIS REPORT IS NOT VALID FOR MEDICOLEGAL PURPOSE.

Licensee : Bharti Medicare Pvt. Ltd. The Apollo Clinic, C-70, Major Sudesh Kumar Marg, Opp. Madhav Park, Near Main Market, Rajouri Garden, New Delhi 110 027  
 Phone : (011) 2591 8222 / 8333 / 8444, 0811061009, E-mail : rajourigarden@theapolloclinic.com, Website : www.apolloclinicrajourigarden.com

MSME UAM NO. : DL11E0021531

**Patient Name** : Mr. Raj Kumar  
**UHID/MR No.** : FRAJ.0000244423  
**Visit Date** : 23-03-2024 08:40  
**Sample Collected on** : 23-03-2024 08:48  
**Ref Doctor** : SELF  
**Emp/Auth/TPA ID** : 33443  
**Sponsor Name** : MEDIWHEELS HEALTH CARE

**Age / Gender** : 55Y/Male  
**OP Visit No** : FRAJOPV119978  
**Reported on** : 24-03-2024 13:03  
**Specimen** : Serum  
**Pres Doctor:** :


**DEPARTMENT OF LABORATORY MEDICINE**

TEST NAME	RESULT	BIOLOGICAL REFERENCE INTERVALS	UNITS
<b>LIVER FUNCTION TEST (PACKAGE)</b>			
BILIRUBIN - TOTAL. Method: Jendrassik	0.91	0.1 - 1.3	mg/dl
Bilirubin (Direct)-Serum Method: Diazo.	0.28	0 - 0.3	mg/dl
A/G Method: Calculated	1.6	1.0 - 2.0	
BILIRUBIN - INDIRECT. Method: Calculated.	0.63	<1.1	
SGOT /AST Method: IFCC (With P5P)	25.7	0 - 35	U/L
SGPT/ALT Method: IFCC (With P5P)	22.9	0 - 45	U/L
ALKALINE PHOSPHATE Method: AMP BUFFER	80.4	30 - 117	U/L
GGT. Method: SZAZ	12.1	10 - 50	U/L
TOTAL PROTEIN Method: Biuret	7.3	5.8-8.0	g/dl
ALBUMIN Method: BCG	4.5	3.7-5.2	g/dl
GLOBULIN Method: Calculated	2.8	2.5 - 3.5	mg/dL

**End of the report**

*Results are to be correlated clinically*

Lab Technician / Technologist  
Yogita

  
**Dr. Prashant Purwar**  
 MBBS, DCP  
 Consultant Pathologist

**CLINICAL CORRELATION IS ESSENTIAL FOR FINAL DIAGNOSIS. IF THE TESTS RESULTS ARE UNEXPECTED PLEASE CONTACT THE LABORATORY. ALL THE CONGENITAL ANAMOLIES IN THE FETUS MAY NOT BE DIAGNOSED IN ULTRASONOGRAPHY. THIS REPORT IS NOT VALID FOR MEDICOLEGAL PURPOSE.**

**Licensee** : Bharti Medicare Pvt. Ltd. The Apollo Clinic, C-70, Major Sudesh Kumar Marg, Opp. Madhav Park, Near Main Market, Rajouri Garden, New Delhi 110 027  
 Phone : (011) 2591 8222 / 8333 / 8444, 9811061009, E-mail : rajourigarden@theapolloclinic.com, Website : www.apolloclinicrajourigarden.com

**MSME UAM NO. : DL11E0021531**



**Patient Name** : Mr. Raj Kumar  
**UHID/MR No.** : FRAJ.0000244423  
**Visit Date** : 23-03-2024 08:40  
**Sample Collected on** : 23-03-2024 08:48  
**Ref Doctor** : SELF  
**Emp/Auth/TPA ID** : 33443  
**Sponsor Name** : MEDIWHEELS HEALTH CARE

**Age / Gender** : 55Y/Male  
**OP Visit No** : FRAJOPV119978  
**Reported on** : 24-03-2024 13:04  
**Specimen** : Serum  
**Pres Doctor:** :


**DEPARTMENT OF LABORATORY MEDICINE**

TEST NAME	RESULT	BIOLOGICAL REFERENCE INTERVALS	UNITS
<b>KFT - RENAL PROFILE-SERUM</b>			
UREA Method: Urease	17.1	10-50	mg/dl
Creatinine Method: Jaffe	1.0	0.5 - 1.3	mg/dl
Uric Acid Method: Uricase	4.9	3.5 - 7.2	mg/dl
Sodium(Na) Method: ISE	136.0	136 - 142	mmol/L
Potassium(K) Method: ISE	3.8	3.8 - 5.0	mmol/L
Chloride(Cl) Method: ISE	97.8	95 - 103	mmol/L
Calcium. Method: OCPC	9.9	9.2 - 11.0	mg/dl
Phosphorus Method: Molybdate UV	2.8	2.3 - 4.7	mg/dl

**End of the report**

*Results are to be correlated clinically*

Lab Technician / Technologist  
Yogita

  
Dr. Prashant Purwar  
MBBS, DCP  
Consultant Pathologist

**CLINICAL CORRELATION IS ESSENTIAL FOR FINAL DIAGNOSIS. • IF THE TESTS RESULTS ARE UNEXPECTED PLEASE CONTACT THE LABORATORY. • ALL THE CONGENITAL ANAMOLIES IN THE FETUS MAY NOT BE DIAGNOSED IN ULTRASONOGRAPHY. • THIS REPORT IS NOT VALID FOR MEDICOLEGAL PURPOSE.**

Licensee : Bharti Medicare Pvt. Ltd. The Apollo Clinic, C-70, Major Sudesh Kumar Marg, Opp. Madhav Park, Near Main Market, Rajouri Garden, New Delhi-110 027  
 Phone : (011) 2591 8222 / 8333 / 8444, 9811061009, E-mail : rajourigarden@theapolloclinic.com, Website : www.apolloclinicrajourigarden.com

**MSME UAM NO. : DL11E0021531**





Patient Name : Mr. Raj Kumar  
 JHID/MR No. : FRAJ.0000244423  
 Visit Date : 23-03-2024 08:40  
 Sample Collected on : 23-03-2024 08:48  
 Ref Doctor : SELF  
 Emp/Auth/TPA ID : 33443  
 Sponsor Name : MEDIWHEELS HEALTH CARE

Age / Gender : 55Y/Male  
 OP Visit No : FRAJOPV119978  
 Reported on : 24-03-2024 09:32  
 Specimen : Urine  
 Pres Doctor: :

**DEPARTMENT OF LABORATORY MEDICINE**

**URINE ROUTINE EXAMINATION**


**URINE EXAMINATION TEST REPORT**

Test Name	Observed Value	Unit	Reference Range
<b>Urine R/M Examination</b>			
Quantity	35	ml.	
Colour	Pale Yellow		Pale Yellow
Transparency	Clear		Clear
Urine Specific Gravity	1.015		1.005 - 1.030
Dipstick			
pH	6.0		5.5 - 7.5
Dipstick / pH paper			
<b>Chemical Examination</b>			
Protein	Nil		Nil
Dipstick/Heat & acetic acid			
Sugar	Nil		Nil
Dipstick/Benedicts reagent			
<b>Microscopic Examination</b>			
WBC's	2-3	/HPF	1-2
RBC'S	Nil	/HPF	Nil
Casts	Nil	/HPF	Nil
Crystals	Nil		Nil
Epithelial Cells	Occasional	/HPF	1-2
Bacteria	Nil	/HPF	Nil

**End of the report**

*Results are to be correlated clinically*

Lab Technician / Technologist  
 Prashant

  
 Dr. Prashant Purwar  
 MBBS, DCP  
 Consultant Pathologist

**CLINICAL CORRELATION IS ESSENTIAL FOR FINAL DIAGNOSIS. • IF THE TESTS RESULTS ARE UNEXPECTED PLEASE CONTACT THE LABORATORY. ALL THE CONGENITAL ANOMALIES IN THE FETUS MAY NOT BE DIAGNOSED IN ULTRASONOGRAPHY. • THIS REPORT IS NOT VALID FOR MEDICOLEGAL PURPOSE.**

Licensee : Bharti Medicare Pvt. Ltd. The Apollo Clinic, C-70, Major Sudesh Kumar Marg, Opp. Madhav Park, Near Main Market, Rajouri Garden, New Delhi-110 027  
 Phone : (011) 2591 8222 / 8333 / 8444, 9811061009, E-mail : rajourigarden@theapolloclinic.com, Website : www.apolloclinicrajourigarden.com

**MSME UAM NO. : DL11E0021531**

Patient Name : RAJ KUMAR	MR No	: FRAJ0000
Age/Sex : 55Y/M	Visit No	: FRAJOPV
Pres Doctor :	Bill Date	: 23.03.2024
Ref.by :	Report Date	: 23.03.2024

**ULTRASOUND WHOLE ABDOMEN**

**LIVER:** Liver is normal in shape, size and echotexture. No focal intra-hepatic lesion detected. Intra-hepatic biliary radicals are not dilated. Portal vein is normal in calibre.

**GALL BLADDER:** Gall bladder is well visualized. Its wall thickness is normal. No calculus or mass lesion is seen in gall bladder. Common bile duct is normal (not dilated).

**PANCREAS:** Pancreas appears normal in size and echopattern.

**SPLEEN:** Spleen appears normal in size and echopattern.

**KIDNEYS:** Both kidneys are normal in position, size and outline. Cortico-medullary differentiation of both kidneys is maintained. Central sinus echoes are compact. No calculus / hydronephrosis seen.

Visualised parts of retroperitoneum do not show any lymphadenopathy.


**URINARY BLADDER:** Urinary bladder is well distended and shows clear contents. Prevoid urine volume ~ 148.92 ml, Postvoid urine volume ~100 ml

**PROSTATE:** Prostate is enlarged in size 4.5 x 4.2 x 4.2 cm (vol ~ 43.3 ml).

No free fluid detected.

**IMPRESSION:- PROSTRATOMEGALY.**

To be correlate clinically.

**Dr. Shailza Minocha**   
Consultant Radiologist.

**Disclaimer:** Renal calculi less than 5mm could be missed on an Ultrasound. NCCT KUB is the modality of choice for the same.

• CLINICAL CORRELATION IS ESSENTIAL FOR FINAL DIAGNOSIS. • IF THE TESTS RESULTS ARE UNEXPECTED PLEASE CONTACT THE LABORATORY.  
• ALL THE CONGENITAL ANAMOLIES IN THE FETUS MAY NOT BE DIAGNOSED IN ULTRASONOGRAPHY. • THIS REPORT IS NOT VALID FOR MEDICOLEGAL PURPOSE.

Licensee : Bharti Medicare Pvt. Ltd. The Apollo Clinic, C-70, Major Sudesh Kumar Marg, Opp. Madhav Park, Near Main Market, Rajouri Garden, New Delhi-110 027  
Phone : (011) 2591 8222 / 8333 / 8444, 9811061009, E-mail : rajourigarden@theapolloclinic.com, Website : www.apolloclinicrajourigarden.com

**MSME UAM NO. : DL11E0021531**



Patient Name : Mr Raj Kumar	MR No	: FRAJ0000
Age/Sex : 55Y/M	Visit No	: FRAJOPV
Pres Doctor :	Bill Date	: 23.03.2024
Ref.by :	Report Date	: 23.03.2024


---

**X-RAY CHEST PA VIEW**

- Both lungs fields do not show any active parenchymal lesion.
- Both costophrenic angles are normal.
- B/L hila appear normal in size & density.
- Both domes of diaphragm are normal.
- Cardiac silhouette appears normal.
- Visualised soft tissues and bony cage appear normal.

**IMPRESSION:- NORMAL STUDY.**

To be correlate clinically.

  
**Dr. Ranul Gera**  
Consultant Radiologist.

• CLINICAL CORRELATION IS ESSENTIAL FOR FINAL DIAGNOSIS. • IF THE TESTS RESULTS ARE UNEXPECTED PLEASE CONTACT THE LABORATORY.  
• ALL THE CONGENITAL ANOMALIES IN THE FETUS MAY NOT BE DIAGNOSED IN ULTRASONOGRAPHY. • THIS REPORT IS NOT VALID FOR MEDICOLEGAL PURPOSE.

Licensee : Bharti Medicare Pvt. Ltd. The Apollo Clinic, C-70, Major Sudesh Kumar Marg, Opp. Madhav Park, Near Main Market, Rajouri Garden, New Delhi-110 027  
Phone : (011) 2591 8222 / 8333 / 8444, 9811061009, E-mail : rajourigarden@theapolloclinic.com, Website : www.apolloclinicrajourigarden.com

**MSME UAM NO. : DL11E0021531**