

CITY LAB

(clinical laboratory)

Dr Madkaikar's City hospital

"Ashirwad bldg, 1st floor ,

opp meenaxi hotel,

Isidor Baptista road,

Margao- Goa 403601

Ph. : 2714354

NAME: Mr. Vasant Vithal Shet Parkar

38yrs/M

Date: 23-03-2024

REF. BY: MEDI WHEEL

BLOOD BIOCHEMISTRY

TEST	PATIENT'S VALUE	NORMAL RANGE
Fasting Blood Glucose	74.0 mg./dl	70-110 mg./dl
Post Prandial Glucose	88.0 mg./dl	Upto 145 mg./dl
RFT		
Blood Urea	35.0 mg./dL	14-40mg./dL
Serum Creatinine	1.2 mg./dL	0.5-1.4mg./dL
Serum Uric Acid	3.2 mg./dL	M: 2.4-7.0 F: 2.4-6.0mg./dL
BUN	16.3 mg./dl	5-25 mg/dl
LFT		
Total Bilirubin	0.7 mg./dL	0.2-1.0 mg./dL
Direct Bilirubin	0.1 mg./dL	0.1-0.2 mg./dL
Indirect Bilirubin	0.6 mg./dL	Up to 0.8 mg/dl
S.G.P.T	21.0 Units/L	0-49 units/L
S.G.O.T	28.0 Units/L	0-46 units/L
Alkaline Phosphatase	166.0 Units/L	108-306 units/L
Total Protein	6.7 gm./dL	6-8 gm.dL
Albumin	4.1 gm./dL	3.5-5.5gm./dL
Globulin	2.6 gm./dL	1.8-3.6gm/dL
A/G	1.5	1.2-2.1
LIPID PROFILE		
Serum Cholesterol	194.0 mg./dL	25- 260 mg./dL
Serum Triglycerides	130.0 mg./dL	M:60-165 F:40 140mg./dL
HDL Cholesterol	39.0 mg./dL	M:30-63 F: 35- 75 mg./dL
LDL Cholesterol	129.0 mg./dL	Upto 145 mg./dl
Total Chol/HDL Chol Ratio	4.9	2-5
LDL Chol/HDL Chol Ratio	3.3	Up to 3.5



Dr. Shet Sunayana Sudhir
M.D. (Path.)
Reg. No. GMC 3311

Pathologist/Analyst

CITY LAB

(clinical laboratory)

Dr Madkaikar's City hospital
"Ashirwad bldg, 1st floor ,
opp meenaxi hotel,
Isidor Baptista road,
Margao- Goa 403601
Ph. : 2714354

NAME: Mr. Vasant Vithal Shet Parkar

38yrs/M

Date: 23-03-2024

REF. BY: MEDI WHEEL

COMPLETE HAEMOGRAM

		MALE	FEMALE
Haemoglobin	14.0 gm%	(13.0-18)	(11.5-16.5)
PCV	48.0 cc%	(40-50)	(37-47)
ESR(westergren's method)	10 mm/hr	(up to 15)	(up to 20)
R.B.C COUNT	5.8 millions/cmm	(4.5-6.0)	(4.0-5.5)

Erthrocytes Indices

MCH	38 pg	27-32
MCHC	34 %	32-36
MCV	90 cu-microns	82-92
Platelet Count	3,11,000 cells/cmm	(150,000-500,000)
Total W.B.C Count	8,100 /cmm	(4,000-10,000)

Differential Count

Neutrophils	62 %	(50-70)
Lymphocytes	32 %	(20-50)
Eosinophils	04 %	(0-8)
Basophils	00 %	(0-2)
Monocytes	02 %	(0-8)



Dr. Shet Sunayana Sudhir
M.D. (Path.)
Reg. No. GMC 3311
Pathologist/Analyst

CITY LAB

(clinical laboratory)

Dr Madkaikar's City hospital
"Ashirwad bldg, 1st floor ,
opp meenaxi hotel,
Isidor Baptista road,
Margao- Goa 403601
Ph. : 2714354

NAME: Mr. Vasant Vithal Shet Parkar

38yrs/M

Date: 23-03-2024

REF. BY: MEDI WHEEL

EXAMINATION OF URINE

PHYSICAL EXAMINATION

Colour ... Pale yellow

Odour ... Ammonical

Appearance Clear

pH. 6.5

Sp. Gravity ...1.030

Deposits ...Nil

CHEMICAL EXAMINATION

Albumin ... Absent

Sugar ... Absent

Ketone bodies ...Nil

BilirubinNil

Occult Blood ... Nil

Urobilinogen.... Nil

MICROSCOPIC EXAMINATION

Pus cells/HPF 1-2

R.B.C.s /HPF Nil

Epithelial Cells/HPF ... 1-2

Crystals/HPFNil

Casts/HPFNil

OTHER FINDINGS : Nil



Dr. Shet Sunayana Sudhir
M.D. (Path.)
Reg. No. GMC 3311

Pathologist/Analyst

CITY LAB

(Clinical laboratory)

Dr Madkaikar's City hospital
"Ashirwad bldg, 1st floor ,
opp meenaxi hotel,
Isidor Baptista road,
Margao- Goa 403601
Ph. : 2714354

NAME: Mr. Vasant Vithal Shet Parkar

38yrs/M

Date: 23-03-2024

REF. BY: MEDI WHEEL

General Examination & Lifestyle

Height: 159cms

Weight: 55kgs BMI : 21.8

B.P: 120/80mHg Diet : Mix

Pulse Rate: 75per min

Personal H/o: 1) illness, fracture, operation, hospitalization, Hypertension, Diabetes and IHD : No

Past/ Family H/o: Diabetes, TB, Asthma, Hypertension, Allergy and IHD : No

System Examination

CVS: Normal RS : Normal

CNS: Normal

Abdomen: Normal

Others

Hernia: Nil

Varicose Veins: Nil

Extremities: Nil

Deformities: Nil

Skin: Normal



Dr. Shet Sunayana Sudhir
M.D. (Path.)
Reg. No. GMC 3311

Pathologist/Analyst

CITY LAB

(Clinical laboratory)

Dr Madkaikar's City hospital
"Ashirwad bldg, 1st floor ,
opp meenaxi hotel,
Isidor Baptista road,
Margao- Goa 403601
Ph. : 2714354

NAME: Mr. Vasant Vithal Shet Parkar

38yrs/M

Date: 23-03-2024

REF. BY: MEDI WHEEL

THYROID FUNCTION TEST

<u>Investigation</u>	<u>Observed Value</u>	<u>Ref. Range</u>	<u>Unit</u>
T3	185	80 - 200	ng/dL
T4	5.2	4.8-12.7	µg/dl
TSH	4.08	0.55 – 4.78	µIU/ml

Sample : Serum.

Method : FULLY AUTOMATED ELFA METHOD



Dr. Shet Sunayana Sudhir
M.D. (Path.)
Reg. No. GMC 3311

Pathologist/Analyst

CITY LAB

(Clinical laboratory)

Dr Madkaikar's City hospital
"Ashirwad bldg, 1st floor ,
opp meenaxi hotel,
Isidor Baptista road,
Margao- Goa 403601
Ph. : 2714354

NAME: Mr. Vasant Vithal Shet Parkar

38yrs/M

Date: 23-03-2024

REF. BY: MEDI WHEEL

TEST	RESULT	UNITS	NORMAL RANGE
GLYCOSYLATED HB (HbA1c) (A.B.G – 124 mg/dl)	6.1	%	Normal : Up to 6% Good control : 6-7 % Fair control : 7-8 % Unsatisfactory: 8-10 % Poor control : > 10

EYE CHECKUP :

- Far Vision : Right Eye- 6/6 Left Eye- 6/6
- Near Vision : Right Eye – N/5 Left Eye-N/6
- Color Vision: Normal.

HEMATOLOGY

TEST	PATIENT'S VALUE	REFERANCE RANGE
BLOOD GROUP	'B' Rh- "POSITIVE"	



Dr. Shet Sunayana Sudhir
M.D. (Path.)
Reg. No. GMC 3311
Pathologist/Analyst

CITY LAB

(Clinical laboratory)

Dr Madkaikar's City hospital
"Ashirwad bldg, 1st floor ,
opp meenaxi hotel,
Isidor Baptista road,
Margao- Goa 403601
Ph. : 2714354

NAME: Mr. Vasant Vithal Shet Parkar

38 yrs/M

Date: 23-03-2024

REF. BY: MEDI WHEEL

X-RAY Chest PA

Lungs are clear.

Hilar and the mediastinal shadows are normal.

Pleura, the c.p angles are clear.

Cardiac aortic Silhouette is normal

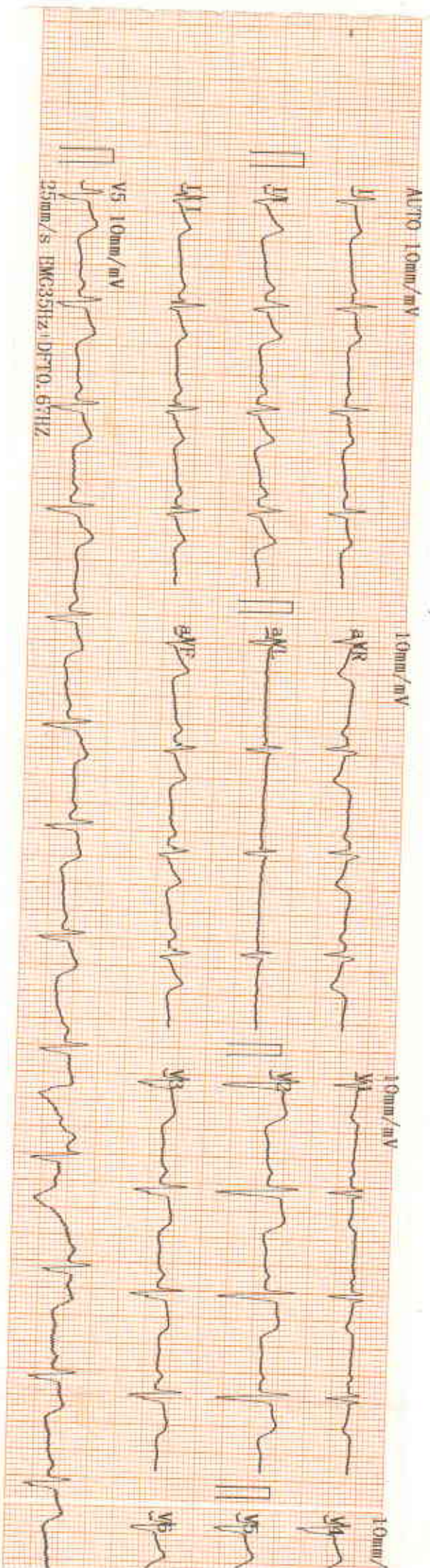
Soft tissues of the chest wall and Bony cage are normal.

Impression: Normal



A handwritten signature in blue ink that reads "Francis A." with a horizontal line underneath.

Dr. Francis Almeida
M.B.B.S. D.M.R.D. (30M) F.C.P.S. (CPS)
Consultant Radiologist
Reg. No. 1553 GMC



10mm/mV

2024-03-23 11:04

<< Conclusions >>

ID : _____
 Name : VASANT
 Sex : Male Age : 38
 Height : _____ cm Weight : _____ kg
 SYS : _____ mmHg
 DIA : _____ mmHg

HR	:	75	bpm
PR Interval	:	130	ms
P Duration	:	120	ms
QRS Duration	:	116	ms
T Duration	:	184	ms
QT/QTc	:	379/422	ms
P/QRS/T Axis	:	72.2/75.6/58.2	deg
R (V5) / S (V1)	:	0.00/0.20	mV
R (V5) / S (V1)	:	0.20	mV

Normal Sinus Rhythm
 QRS low voltage.
 Cardiac electric axis normal.
 No Completeness Right Bundle branch block.

DR. SUDHIR SHET

M.D.
 CONSULTANT PHYSICIAN
 Reg. No.: GMC 3176

Physician

