

HEALTH CHECK UP

Name : Nisha Pal

Date : 29/3/24

Age : 419

Sex : Male / Female

Marital status : Married / Single

PERSONAL HISTORY

Habits : Smoking / Tobacco & Snuff / Alcohol NO

Drug allergy if any :

Medical : Nil

Surgical :

Height 162 cm Weight 65 Kg. BP 110/70/60 mmHg Pulse 70 mt

Vision : Rt 6/6 Lt 6/6 With Spectacles Rt 6/6 Lt 6/6

Colour Vision : Normal / Abnormal Near Vision NG / RG

FAMILY HISTORY

Father Mother Siblings

CVS : Heart Sound Normal Murmurs Absent Thrills Absent

RS : Rate /mt Breath sounds Normal Adventitious Absent

ABDOMEN : Tenderness Absent Rigidity Absent Bowel sound Normal

Liver NAD Kidney NAD Hernia Absent

CNS : Cranial Nerves NAD Sensory System NAD Motor System NAD

ENT NAD

Remarks

Dr. Bharti Jeswani
MBBS

Dr. Seema Kale
MBBS, MD

Dr. S. K. Suri
MBBS

Dr. Meenakshi
MBBS

HOME SAMPLE COLLECTION FACILITY AVAILABLE

Licensee : Bharti Medicare Pvt. Ltd. The Apollo Clinic, C-70, Major Sudesh Kumar Marg, Opp. Madhav Park, Near Main Market, Rajouri Garden, New Delhi-110 027
Phone : (011) 2591 8222 / 8333 / 8444, 9811061009, E-mail : rajourigarden@theapolloclinic.com, Website : www.apolloclinicrajourigarden.com

MSME UAM NO. : DL11E0021531

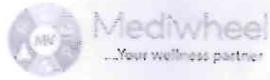
Health Check up Booking Request(UBOIE4584), Beneficiary Code-177801



Mediwheel
to me, customercare

Thu, Mar 21, 1:43 PM (8 days ago)

Reply



011-41195959

Dear Apollo Bharti Apollo Bharti Medicare Pvt. Ltd.

We have received a booking request with the following details. Provide your confirmation by clicking on the Yes button.

You confirm this booking? Yes No

Name : RICHA PAL

Contact Details : 9953763942

Hospital Package Name : Mediwheel Full Body Health Checkup Female Above 40

Location : C70, Opp. Madhav Park, Major Sudesh Kumar Marg
-110027

Appointment Date : 29-03-2024

Member Information		
Booked Member Name	Age	Gender
RICHA PAL	41 year	Female

Tests included in this Package -

- Mammography
- Stool Test
- Gynae Consultation
- Thyroid Profile
- ESR
- Blood Glucose (Fasting)
- General Physician Consultation
- TMT OR 2D ECHO
- Blood Group
- Blood Glucose (Post Prandial)
- Chest X-ray
- ECG
- USG Whole Abdomen
- Eye Check-up consultation
- Urine Sugar Fasting
- Urine Sugar PP
- Dental Consultation
- Urine analysis
- CBC
- Lipid Profile
- Kidney Profile
- Liver profile

richa pal

Female 41Years

cm kg / mmHg

Req. No. :

Room No. :

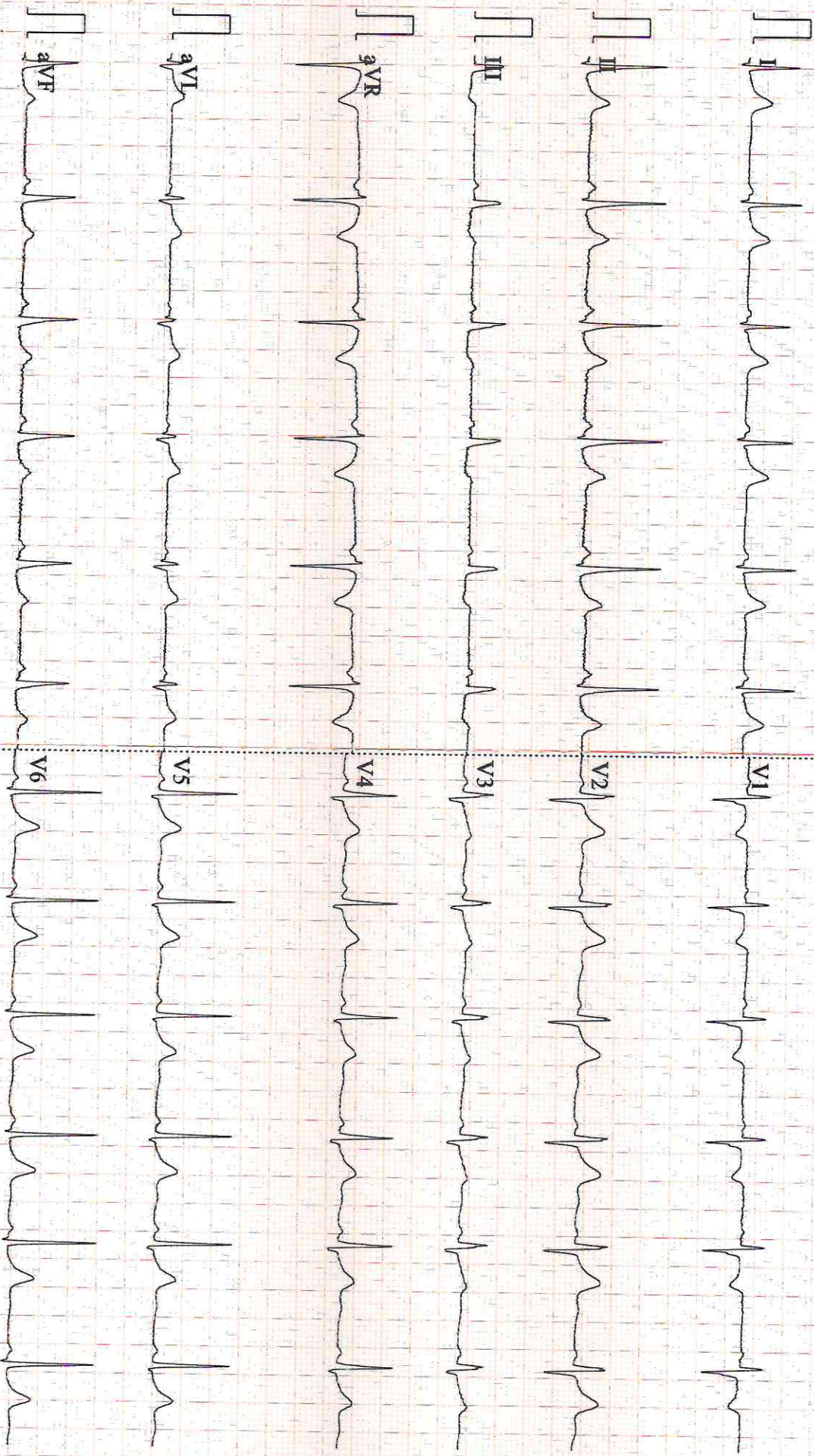
Diagnosis Information:


Sinus rhythm

Normal ECG

HR	: 70	bpm
P	: 96	ms
PR	: 118	ms
QRS	: 86	ms
QT/QTcBz	: 386/417	ms
P/QRS/T	: 53/54/24	°
RV5/SV1	: 1.324/0.639	mV

Report Confirmed by:





Medicaid

APOLLO CLINIC C-70 RAJOURI GARDEN

Last Name: PAL
First Name: RICHA
ID: 2903
Date: 29/03/2024
Predicted: ERS 93

Date of Birth: 05/04/1982
Sex: Female
Ethnic Corr.: 100%
Description:
Comments:

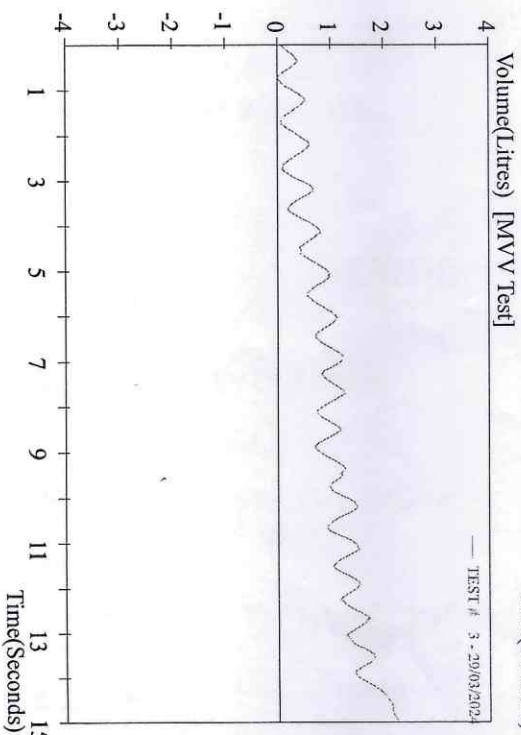
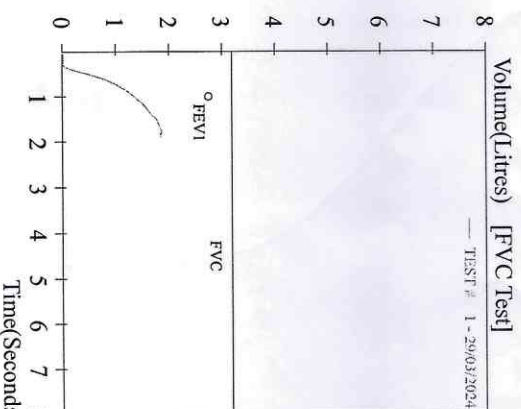

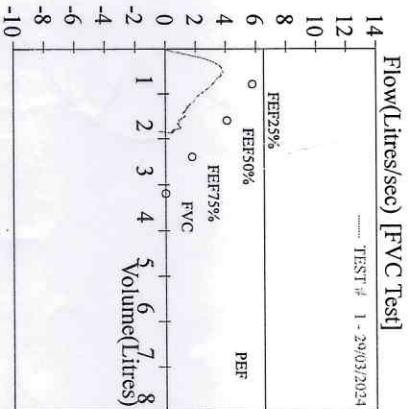


Age: 41
Weight (Kg): 65
Height (cm): 162
BSA (m2): 1.69
Smoke: no

Spirometry Results

Parameter	Pred	Pre	%Pred
FVC	(L) 3.19	1.98	62
FEV5	(L) -----	0.55	---
FEV1	(L) 2.75	1.45	53
PEFR	(L/s) 6.54	3.85	59
PIFR	(L/s) -----	0.45	---
FEF25-75	(L/s) 3.52	2.24	64
FEF 25%	(L/s) 5.77	3.85	67
FEF 50%	(L/s) 4.08	2.56	63
FEF 75%	(L/s) 1.76	1.14	65
FEV1/FVC	(%) 81.12	73.23	90
FVC Time	(Sec) -----	1.74	---
SVC	(L) 3.18	0.71	22
ERV	(L) -----	0.21	---
IRV	(L) -----	0.11	---
VE	(L/min) -----	15.6	---
Rf	(1/min) -----	40	---
Ti	(sec) -----	0.75	---
Te	(sec) -----	0.75	---
Vt	(L) -----	0.39	---
Vt/Ti	(L/s) -----	0.52	---
Ti/Ttot	(sec) -----	0.5	---
IC	(L) -----	0.5	---
MVV	(L/min) 102.76	12.75	12
MRF	(1/min) -----	25	---
MVt	(L) -----	0.51	---
MVVt	(sec) -----	15.38	---
EIA	(Years) 40	92	---

Pre Medication Report Indicates
ESA Obstruction(PEF<70%PredPEF or FEF<70%PredFEF)



The stool test included in my medical check-up package has not ~~be~~ been done by me. I am willing to skip the said test as per my own wish.

Richahal
(Richa Paul)
9953763942

• CLINICAL CORRELATION IS ESSENTIAL FOR FINAL DIAGNOSIS. • IF THE TESTS RESULTS ARE UNEXPECTED PLEASE CONTACT THE LABORATORY.
• ALL THE CONGENITAL ANOMOLIES IN THE FETUS MAY NOT BE DIAGNOSED IN ULTRASONOGRAPHY. • THIS REPORT IS NOT VALID FOR MEDICOLEGAL PURPOSE.

Licensee : Bharti Medicare Pvt. Ltd. The Apollo Clinic, C-70, Major Sudesh Kumar Marg, Opp. Madhav Park, Near Main Market, Rajouri Garden, New Delhi-110 027
Phone : (011) 2591 8222 / 8333 / 8444, 📞 9811061009, E-mail : rajourigarden@theapolloclinic.com, Website : www.apolloclinicrajourigarden.com

MSME UAM NO. : DL11E0021531

NAME: MS RICHA PAL
REF

AGE: 41 / Sex / F
DATE 29/03 /2024

ECHO ADULT (COLOUR DOPPLER)

DIMENSIONS	NORMAL	DIMENSIONS	NORMAL
Ao (ed) 31.0 mm	(1.5 cm/m ²)	IVS (Ed) 08.9 mm	(0.6-1.2cm)
LA (es) 31.0 mm	(1.5 cm/m ²)	LVPW (Ed) 08.5 mm	(.6-1.1cm)
RVID (ed) Normal	(0.9cm/m ²)	EF	65.0 % (0.62-0.85)
LVID (ed) 43.0 mm	(2.6-3.4 cm/m ²)	FS	30.0
LVID (es) 27.0 mm			


MORPHOLOGICAL DATA

Mitral Valve	Normal	Interatrial Septum	Normal
Aortic Valve	Normal	Interventricular Septum	Normal
Tricuspid Valve	Normal	Pulmonary Artery	Normal
Pulmonary Valve	Normal	Aorta	Normal
Right Ventricle	Normal	Right Atrium	Normal
Left Ventricle	Normal	Left Atrium	Normal
Pericardium	Normal		

Colour Doppler Normal , NO PAH, IVC NORMAL, LV DIASTOLIC FUNCTION NORMAL

Wall motion Normal

IMPRESSION : NORMAL STUDY

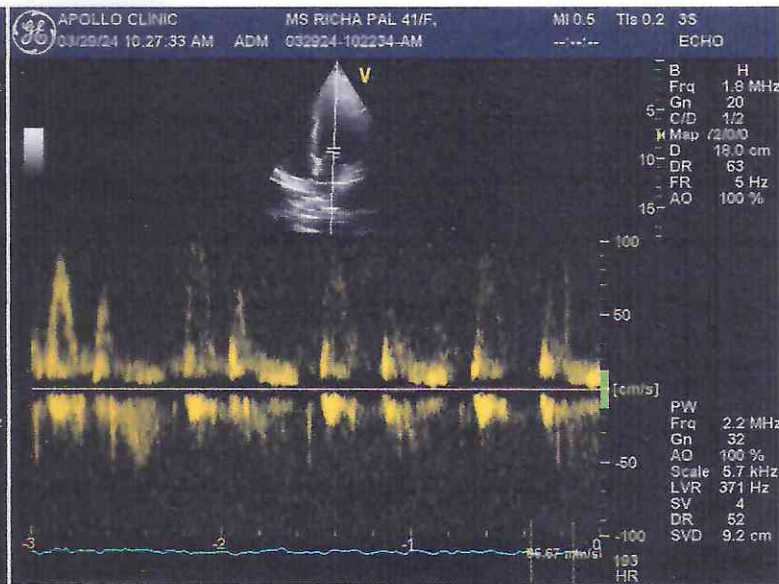
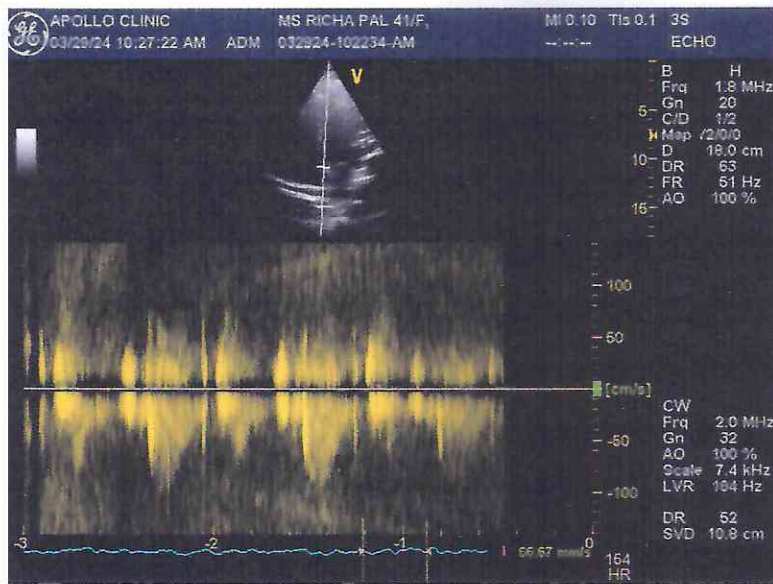
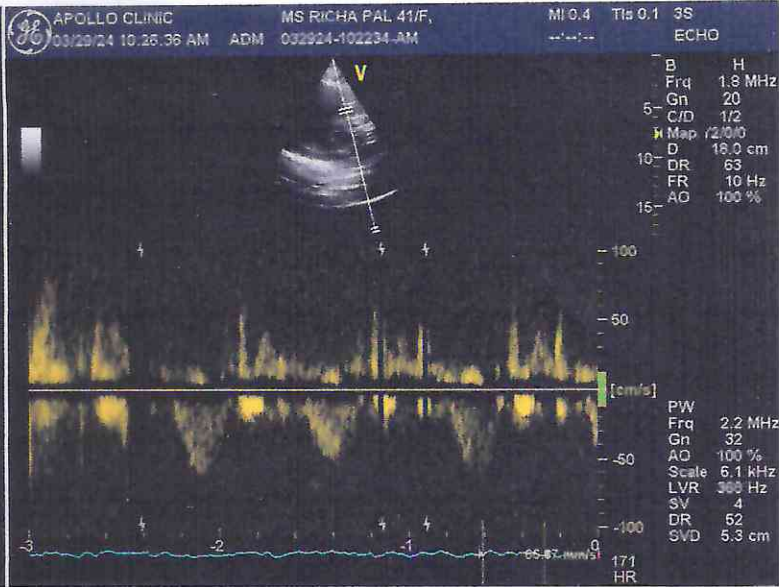
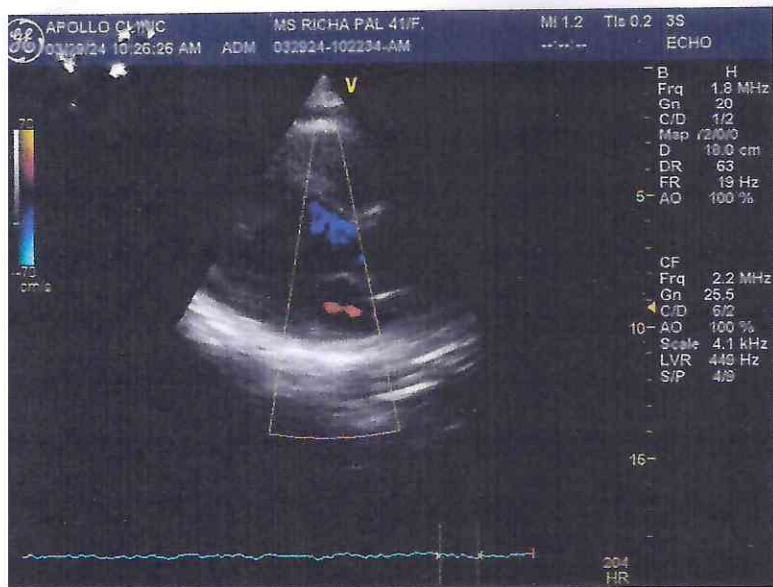


DR SEEMA KALE MD
SEN. (PHYSICIAN)

• CLINICAL CORRELATION IS ESSENTIAL FOR FINAL DIAGNOSIS. • IF THE TESTS RESULTS ARE UNEXPECTED PLEASE CONTACT THE LABORATORY.
• ALL THE CONGENITAL ANOMOLIES IN THE FETUS MAY NOT BE DIAGNOSED IN ULTRASONOGRAPHY. • THIS REPORT IS NOT VALID FOR MEDICOLEGAL PURPOSE.

Licensee : Bharti Medicare Pvt. Ltd. The Apollo Clinic, C-70, Major Sudesh Kumar Marg, Opp. Madhav Park, Near Main Market, Rajouri Garden, New Delhi-110 027
Phone : (011) 2591 8222 / 8333 / 8444, 9811061009, E-mail : rajourigarden@theapolloclinic.com, Website : www.apolloclinicrajourigarden.com

MSME UAM NO. : DL11E0021531



Patient Name : Mrs. Richa Pal
 UHID/MR No. : FRAJ.0000244814
 Visit Date : 29-03-2024 10:10
 Sample Collected on : 29-03-2024 10:24
 Sample No : WHB1389232
 Ref Doctor : SELF
 Emp/Auth/TPA ID : 3243243
 Sponsor Name : MEDIWHEELS HEALTH CARE

Age / Gender : 41Y/Female
 OP Visit No : FRAJOPV120369
 Reported on : 29-03-2024 15:55
 Specimen : Whole Blood (Edta)
 Pres Doctor: :


DEPARTMENT OF LABORATORY MEDICINE

TEST NAME	RESULT	BIOLOGICAL REFERENCE INTERVALS	UNITS
COMPLETE BLOOD COUNT			
Hb (Haemoglobin) Method: Non Cyanide	10.6*	11 - 15	gm/dl
PCV/Haematocrit Method: RBC pulse height detect	34.2*	36 - 46	%
ESR. Method: Westergren's Method	12	0 - 20	mm/1st Hr
TLC Method: DC Detection Method	5500	4000 - 10000	/cumm.
RBC COUNT. Method: DC Detection Method	4.08	3.8 - 4.8	Million/cmm
PLATELET COUNT Method: DC Detection Method	2.58	1.5 - 4.1	lakh/cumm.
MCV Method: Derived	84.0	77 - 98	fl
MCH Method: Derived	26.1*	27 - 32	pg
MCHC Method: Derived	31.0*	31.5 - 34.5	gm/dl
NEUTROPHIL Method: Microscopy	56	40 - 70	%
LYMPHOCYTE Method: Microscopy	38	20 - 40	%
EOSINOPHIL Method: Microscopy	04	1.0 - 6.0	%
MONOCYTE Method: Microscopy	02	2.0 - 10.0	%
BLOOD GROUP AND RH TYPE			
ABO Group	A		
RH	Positive		

End of the report

Results are to be correlated clinically

Lab Technician / Technologist
 Surinder


 Dr. Prashant Purwar
 MBBS, DCP
 Consultant Pathologist

• CLINICAL CORRELATION IS ESSENTIAL FOR FINAL DIAGNOSIS. • IF THE TESTS RESULTS ARE UNEXPECTED PLEASE CONTACT THE LABORATORY.
 • ALL THE CONGENITAL ANAMOLIES IN THE FETUS MAY NOT BE DIAGNOSED IN ULTRASONOGRAPHY. • THIS REPORT IS NOT VALID FOR MEDICOLEGAL PURPOSE.

Licensee : Bharti Medicare Pvt. Ltd. The Apollo Clinic, C-70, Major Sudesh Kumar Marg, Opp. Madhav Park, Near Main Market, Rajouri Garden, New Delhi-110 027
 Phone : (011) 2591 8222 / 8333 / 8444, 9811061009, E-mail : rajourigarden@theapolloclinic.com, Website : www.apolloclinicrajourigarden.com

MSME UAM NO. : DL11E0021531

Patient Name : Mrs. Richa Pal
UHID/MR No. : FRAJ.0000244814
Visit Date : 29-03-2024 10:10
Sample Collected on : 29-03-2024 12:02
Sample No : PLF1329343
Ref Doctor : SELF
Emp/Auth/TPA ID : 3243243
Sponsor Name : MEDIWHEELS HEALTH CARE

Age / Gender : 41Y/Female
OP Visit No : FRAJOPV120369
Reported on : 29-03-2024 18:42
Specimen : Plasma(Fluoride)
Pres Doctor: :


DEPARTMENT OF LABORATORY MEDICINE

TEST NAME	RESULT	BIOLOGICAL REFERENCE INTERVALS	UNITS
GLUCOSE - (FASTING)			
GLUCOSE - (FASTING) Method: (GOD-POD).	81	70 - 110	mg/dL
GLUCOSE - (POST PRANDIAL)			
GLUCOSE - (POST PRANDIAL) Method: (GOD-POD)	135	70-140	mg/dl
GLYCOSYLATED HEMOGLOBIN (HBA1C)			
GLYCOSYLATED HEMOGLOBIN (HBA1C) - WHOLE BLOOD Method: BORONATE AFFINITY	5.6	4.2 - 6.0	%
Note: Good Control : 6.0-7.0 Bad Control : 7.0-8.0 Poor Control : >8.0			
LIPID PROFILE TEST (PACKAGE)			
CHOLESTEROL Method: CHOD - PAP	187	Desirable < 200 Borderline High : 200-239 High : > 240	mg/dl
Triglyceride Method: GPO-PAP	93	50-200	mg/dl
HDL Method: DIRECT	56.8	30 - 70	mg/dl
LDL Method: DIRECT	111.6*	60 - 100	mg/dl
VLDL Method: Calculated	18.6	<40	mg/dl
CHOLESTEROL / HDL RATIO Method: Calculated.	3.2	0 - 4.5	

End of the report

Results are to be correlated clinically

Lab Technician / Technologist
Suriinder


 Dr. Prashant Purwar
 MBBS, DCP
 Consultant Pathologist

• CLINICAL CORRELATION IS ESSENTIAL FOR FINAL DIAGNOSIS. • IF THE TESTS RESULTS ARE UNEXPECTED PLEASE CONTACT THE LABORATORY.
 • ALL THE CONGENITAL ANAMOLIES IN THE FETUS MAY NOT BE DIAGNOSED IN ULTRASONOGRAPHY. • THIS REPORT IS NOT VALID FOR MEDICOLEGAL PURPOSE.

Licensee : Bharti Medicare Pvt. Ltd. The Apollo Clinic, C-70, Major Sudesh Kumar Marg, Opp. Madhav Park, Near Main Market, Rajouri Garden, New Delhi-110 027
 Phone : (011) 2591 8222 / 8333 / 8444, 9811061009, E-mail : rajourigarden@theapolloclicin.com, Website : www.apolloclicinrajourigarden.com

MSME UAM NO. : DL11E0021531

Patient Name : Mrs. Richa Pal
UHID/MR No. : FRAJ.0000244814
Visit Date : 29-03-2024 10:10
Sample Collected on : 29-03-2024 10:24
Sample No : SR01890761
Ref Doctor : SELF
Emp/Auth/TPA ID : 3243243
Sponsor Name : MEDIWHEELS HEALTH CARE

Age / Gender : 41Y/Female
OP Visit No : FRAJOPV120369
Reported on : 29-03-2024 18:43
Specimen : Serum
Pres Doctor: :


DEPARTMENT OF LABORATORY MEDICINE

TEST NAME	RESULT	BIOLOGICAL REFERENCE INTERVALS	UNITS
LIVER FUNCTION TEST (PACKAGE)			
BILIRUBIN - TOTAL. Method: Jendrassik	0.72	0.1 - 1.3	mg/dl
Bilirubin (Direct)-Serum Method: Diazo.	0.24	0 - 0.3	mg/dl
A/G Method: Calculated	1.3	1.0 - 2.0	
BILIRUBIN - INDIRECT. Method: Calculated.	0.48	<1.1	mg/dl
SGOT /AST Method: IFCC (With P5P)	28.7	0 - 35	U/L
SGPT/ALT Method: IFCC (With P5P)	22.9	0 - 45	U/L
ALKALINE PHOSPHATE Method: AMP BUFFER	56.1	30 - 117	U/L
GGT. Method: SZAZ	18.7	10 - 50	U/L
TOTAL PROTEIN Method: Biuret	7.3	5.8-8.0	g/dl
ALBUMIN Method: BCG	4.2	3.7-5.2	g/dl
GLOBULIN Method: Calculated	3.1	2.5 - 3.5	mg/dL

End of the report

Results are to be correlated clinically

Lab Technician / Technologist
Surinder


 Dr. Prashant Purwar
 MBBS, DCP
 Consultant Pathologist

• CLINICAL CORRELATION IS ESSENTIAL FOR FINAL DIAGNOSIS. • IF THE TESTS RESULTS ARE UNEXPECTED PLEASE CONTACT THE LABORATORY.
 • ALL THE CONGENITAL ANAMOLIES IN THE FETUS MAY NOT BE DIAGNOSED IN ULTRASONOGRAPHY. • THIS REPORT IS NOT VALID FOR MEDICOLEGAL PURPOSE.

Licensee : Bharti Medicare Pvt. Ltd. The Apollo Clinic, C-70, Major Sudesh Kumar Marg, Opp. Madhav Park, Near Main Market, Rajouri Garden, New Delhi-110 027
 Phone : (011) 2591 8222 / 8333 / 8444, 9811061009, E-mail : rajourigarden@theapolloclinic.com, Website : www.apolloclinicrajourigarden.com

MSME UAM NO. : DL11E0021531

Patient Name : Mrs. Richa Pal
 UHID/MR No. : FRAJ.0000244814
 Visit Date : 29-03-2024 10:10
 Sample Collected on : 29-03-2024 10:24
 Sample No : SR01890761
 Ref Doctor : SELF
 Emp/Auth/TPA ID : 3243243
 Sponsor Name : MEDIWHEELS HEALTH CARE

Age / Gender : 41Y/Female
 OP Visit No : FRAJOPV120369
 Reported on : 29-03-2024 18:44
 Specimen : Serum
 Pres Doctor :


DEPARTMENT OF LABORATORY MEDICINE

TEST NAME	RESULT	BIOLOGICAL REFERENCE INTERVALS	UNITS
KFT - RENAL PROFILE-SERUM			
UREA Method: Urease	14.5	10-50	mg/dl
Creatinine Method: Jaffe	0.95	0.5 - 1.3	mg/dl
Uric Acid Method: Uricase	2.8	2.6 - 6	mg/dl
Sodium(Na) Method: ISE	139.7	136 - 142	mmol/L
Potassium(K) Method: ISE	4.0	3.8 - 5.0	mmol/L
Chloride(Cl) Method: ISE	98.6	95 - 103	mmol/L
Calcium Method: OCPC	9.0*	9.2 - 11.0	mg/dl
Phosphorus Method: Molybdate UV	2.6	2.3 - 4.7	mg/dl
Thyroid Profile 2(Free T4, Free T3 And TSH)			
Serum FT3	4.1	3.2 - 5.9	pmol/l
Serum FT4	12.5	10.6 - 21.0	pmol/l
Serum TSH	3.0	0.38 - 5.0	uIU/ml

End of the report

Results are to be correlated clinically

Lab Technician / Technologist
 Surinder


 Dr. Prashant Purwar
 MBBS, DCP
 Consultant Pathologist

• CLINICAL CORRELATION IS ESSENTIAL FOR FINAL DIAGNOSIS. • IF THE TESTS RESULTS ARE UNEXPECTED PLEASE CONTACT THE LABORATORY.
 • ALL THE CONGENITAL ANOMALIES IN THE FETUS MAY NOT BE DIAGNOSED IN ULTRASONOGRAPHY. • THIS REPORT IS NOT VALID FOR MEDICOLEGAL PURPOSE.

Licensee : Bharti Medicare Pvt. Ltd. The Apollo Clinic, C-70, Major Sudesh Kumar Marg, Opp. Madhav Park, Near Main Market, Rajouri Garden, New Delhi-110 027
 Phone : (011) 2591 8222 / 8333 / 8444, 9811061009, E-mail : rajourigarden@theapolloclicin.com, Website : www.apolloclicinrajourigarden.com

MSME UAM NO. : DL11E0021531

Patient Name : Mrs. Richa Pal
 UHID/MR No. : FRAJ.0000244814
 Visit Date : 29-03-2024 10:10
 Sample Collected on : 29-03-2024 12:02
 Sample No : UR1043686
 Ref Doctor : SELF
 Emp/Auth/TPA ID : 3243243
 Sponsor Name : MEDIWHEELS HEALTH CARE

Age / Gender : 41Y/Female
 OP Visit No : FRAJOPV120369
 Reported on : 29-03-2024 15:12
 Specimen : Urine
 Pres Doctor: :

DEPARTMENT OF LABORATORY MEDICINE

URINE ROUTINE EXAMINATION

URINE EXAMINATION TEST REPORT

Test Name	Observed Value	Unit	Reference Range
Urine R/M Examination			
Quantity	30	ml.	
Colour	Pale Yellow		Pale Yellow
Transparency	Clear		Clear
Urine Specific Gravity	1.010		1.005 - 1.030
Dipstick			
pH	6.5		5.5 - 7.5
Dipstick / pH paper			
Chemical Examination			
Protein	Nil		Nil
Dipstick/Heat & acetic acid			
Sugar	Nil		Nil
Dipstick/Benedicts reagent			
Microscopic Examination			
Pus Cells	1-2	/HPF	1-2
RBC'S	Nil	/HPF	Nil
Casts	Nil	/HPF	Nil
Crystals	Nil		Nil
Epithelial Cells	2-3	/HPF	1-2
Bacteria	Nil	/HPF	Nil

End of the report

Results are to be correlated clinically

Lab Technician / Technologist
 Dr. Prashant


 Dr. Prashant Purwar
 MBBS, DCP
 Consultant Pathologist

• CLINICAL CORRELATION IS ESSENTIAL FOR FINAL DIAGNOSIS. • IF THE TESTS RESULTS ARE UNEXPECTED PLEASE CONTACT THE LABORATORY.
 • ALL THE CONGENITAL ANAMOLIES IN THE FETUS MAY NOT BE DIAGNOSED IN ULTRASONOGRAPHY. • THIS REPORT IS NOT VALID FOR MEDICOLEGAL PURPOSE.

Licensee : Bharti Medicare Pvt. Ltd. The Apollo Clinic, C-70, Major Sudesh Kumar Marg, Opp. Madhav Park, Near Main Market, Rajouri Garden, New Delhi-110 027
 Phone : (011) 2591 8222 / 8333 / 8444, 9811061009, E-mail : rajourigarden@theapolloclinic.com, Website : www.apolloclinicrajourigarden.com

MSME UAM NO. : DL11E0021531

Patient Name :Richa Pal	MR No	: FRAJ0000
Age/Sex : 41 Y/F	Visit No	: FRAJOPV
Pres Doctor :	Bill Date	: 29.03.2024
Ref.by :	Report Date	: 29.03.2024

MAMMOGRAPHY

(Craniocaudal and mediolateral oblique views were taken for bilateral breasts with optimal compression technique.)

Bilateral breasts show heterogenously dense fibroglandular tissue obscuring the underlying parenchyma(ACR TYPE C).

No definite space occupying lesion is noted in either breast.

No microcalcification is seen in either breast.

No architectural distortion is noted.

Nipples are normal in position and no nipple retraction is noted.

No definite skin thickening is noted on either side.

IMPRESSION : No definite space occupying lesion is noted in either breast. In view of dense fibroglandular tissue, correlation with sonomammogram can be done in case of obscured lesions.

To be correlate clinically.

BIRADS-0


Dr. Manish Kumar
Consultant Radiologist.

• CLINICAL CORRELATION IS ESSENTIAL FOR FINAL DIAGNOSIS. • IF THE TESTS RESULTS ARE UNEXPECTED PLEASE CONTACT THE LABORATORY.
• ALL THE CONGENITAL ANAMOLIES IN THE FETUS MAY NOT BE DIAGNOSED IN ULTRASONOGRAPHY. • THIS REPORT IS NOT VALID FOR MEDICOLEGAL PURPOSE.

Licensee : Bharti Medicare Pvt. Ltd. The Apollo Clinic, C-70, Major Sudesh Kumar Marg, Opp. Madhav Park, Near Main Market, Rajouri Garden, New Delhi-110 027
Phone : (011) 2591 8222 / 8333 / 8444, 9811061009, E-mail : rajourigarden@theapolloclinic.com, Website : www.apolloclinicrajourigarden.com

MSME UAM NO. : DL11E0021531

Patient Name : Mrs Richa Pal	MR No	: FRAJ0000
Age/Sex : 41Y/F	Visit No	: FRAJOPV
Pres Doctor :	Bill Date	: 29.03.2024
Ref.by :	Report Date	: 29.03.2024

X-RAY CHEST PA VIEW

- Both lungs fields do not show any active parenchymal lesion.
- Both costophrenic angles are normal.
- B/L hila appear normal in size & density.
- Both domes of diaphragm are normal.
- Cardiac silhouette appears normal.
- Visualised soft tissues and bony cage appear normal.

IMPRESSION:- NORMAL STUDY.

To be correlate clinically.


Dr. Rahul Gera
Consultant Radiologist.

• CLINICAL CORRELATION IS ESSENTIAL FOR FINAL DIAGNOSIS. • IF THE TESTS RESULTS ARE UNEXPECTED PLEASE CONTACT THE LABORATORY.
• ALL THE CONGENITAL ANAMOLIES IN THE FETUS MAY NOT BE DIAGNOSED IN ULTRASONOGRAPHY. • THIS REPORT IS NOT VALID FOR MEDICOLEGAL PURPOSE.

Licensee : Bharti Medicare Pvt. Ltd. The Apollo Clinic, C-70, Major Sudesh Kumar Marg, Opp. Madhav Park, Near Main Market, Rajouri Garden, New Delhi-110 027
Phone : (011) 2591 8222 / 8333 / 8444, 9811061009, E-mail : rajourigarden@theapolloclinic.com, Website : www.apolloclinicrajourigarden.com

MSME UAM NO. : DL11E0021531