


भारत सरकार
GOVERNMENT OF INDIA


नेहा अरोड़ा
NEHA ARORA
जन्म तिथि / DOB: 01/03/1988
महिला / FEMALE



7570 7825 1014

मेरा आधार, मेरी पहचान

Neha
17/4/24


आधार
भारतीय विशिष्ट पहचान प्राधिकरण
UNIQUE IDENTIFICATION AUTHORITY OF INDIA

Address:
A-5, TAGORE GARDEN
EXT., Tagore Garden S.O,
West Delhi, Delhi - 110027

पता:
ए-5, टैगोर गार्डन एक्सटेंशन, टैगोर गार्डन एस
ए., पश्चिम दिल्ली,
दिल्ली - 110027

7570 7825 1014



1947


help@uidai.gov.in


www.uidai.gov.in

P.O. Box No.1947,
Bengaluru-560 001

Download Date: 28/12/2017

Generation Date: 08/07/2012

MALIK RADIA HEALTH CARE PVT. LTD.
C-217, C-218, Nirman Vihar,
Delhi-110092
Ph.: 011-49287456, 011-61381379
Regd. No. 607



RADIX COSMO DENTAL

(UNIT OF MALIK RADIX HEALTHCARE PVT. LTD.)

C-216, 217, 218, Nirman Vihar, Vikas Marg, Delhi - 110092

Ph. : 011-22508272, 22520249 • M. : 9999254639

E-mail : radixhealthcare@yahoo.co.in • www.radixhealthcare.org



CONSULTANTS ON PANEL

PAEDIATRICS

Dr Ravi Malik (MBBS, MD)
Dr Harit Prasad (MBBS, MD, Pdi)
Dr Ritu Jain (MBBS, MD)

GYNAECOLOGY

Dr Renu Malik (MBBS, MD)
Dr Meena Malhotra (MBBS, MD)
Dr Rajni (MBBS, MD)
Dr Manju Gupta (MBBS, MS)
Dr Vaishali Saini (MBBS, DGO)
Dr Rupam Arora (MBBS, MD)

DENTAL

Dr Shruti Malik (BDS, MDS)
Dr Annu Saini (BDS, MDS)
Dr Rachit Thukral (BDS, MDS)
Dr Mohit Mangla (BDS, MDS)
Dr Tarun Mittal (BDS, MDS)
Dr Geetika Sharma (BDS)
Dr Shilpa Verma (BDS)

CHILD GASTROENTEROLOGY

Dr S. K Mittal (MBBS, MD)

MEDICINE

Dr A S Talwar (MBBS, MD)
Dr Sunny Uppal (MBBS, MD)
Dr Surendra Rajpal (MBBS, MD)

RESPIRATORY MEDICINE / PULMONOLOGY

Dr Abhinav Bhanot (MBBS, DNB)

LAPAROSCOPY SURGERY

Dr Ajay Jain (MBBS, MS)
Dr Deepak Saran (MBBS, MS)
Dr Pradeep Saini (MBBS, MS)
Dr G. S Garg (MBBS, MS)

ORTHOPAEDICS

Dr Vikas Bhardwaj (MBBS, MS ORTHO, DNB)
Dr Prabhat Aggarwal (MBBS, MS ORTHO)
Dr KB Tiwari (MBBS, MS ORTHO)
Dr Deepak Kumar Arora (MBBS, MS ORTHO)

EYE/OPTHALMOLOGY

Dr Nidhi Gupta (MBBS, MS, DNB, PGDM)
Dr Himanshu Singh Pundir (MBBS, MS)

ENT

Dr Sharad Kumar Singhi (MBBS, MS)
Dr Prateek Sharma (MBBS, MS)
Dr Ashok Singh (MBBS, MS)
Dr A K Lahiri (MBBS, MS)

RADIOLOGY (ULTRASOUND)

Dr K K Sinha (MBBS DNB)
Dr T K Vohra (MBBS, MD)
Dr Rajesh Malhotra (MBBS, MD)
Dr Ashish Tomar (MBBS, MD)

PATHOLOGY

Dr Reema Dahiya (MBBS, MD PATH)
Dr Meenu Aggarwal (MBBS, MD PATH)

ANAESTHESIA

Dr Rajesh Dhall (MBBS, MD)
Dr Rakesh Atrey (MBBS, MD)
Dr R K Arora (MBBS, MD)
Dr Swaraj Garg (MBBS, MD)

DERMATOLOGY

Dr Niharika Jha (MBBS, MD)

PLASTIC & COSMETIC SURGERY

Dr Ayush Jain (MBBS, MS, MCh)

PAEDIATRIC SURGERY

Dr Dharmendra Singh (MBBS, MS, M.Ch)
Dr Satish Aggarwal (MBBS, MS, M.Ch)

PAEDIATRIC NEPHROLOGY

Dr A S Vasudev (MD, Dip.in. Paed.)

NEPHROLOGY

Dr Javed (MBBS, MD, Nephro)

CARDIOLOGY

Dr Nishant Tyagi (MBBS, MD)

NEUROLOGY

Dr Amit Batra (MBBS, MD)

GASTROENTEROLOGY

Dr Deepak Lahoti (MBBS, MD)
Dr Naresh Aggarwal (MBBS, MD)
Dr Ashok Goyal (MBBS, MD)
Dr Ankur Singhal (MBBS, MD)

UROLOGY

Dr Nikhil Sharma (MBBS, Mch)

Dr Ankur Singhal (MBBS, MD)

PSYCHIATRY

Dr Mohit Sharma (MBBS, MD)

PHYSIOTHERAPY

Dr Kirti Dawvedi

Dr Ravi Kumar

NUTRITIONIST

Dr Deepika Kohli

Dr Sakshi Rana

CLINICAL PSYCHOLOGIST

Dr. Sarika Singh

Dr. Shruti Malik

BDS, MDS (Endodontics)

(+91-9899561092)

Timings : 10:00 am. to 2:00 pm.
6:00 pm. to 8:30 pm.

CLINICAL EXAMINATION:-

1. TMJ:-

Routine Checkup

2. DENTAL STATUS:

O/E

- a. Caries Teeth :
- b. Fracture Teeth :
- c. Root Stumps :
- d. Gingivitis :
- e. Periodontitis :
- f. Impacted Teeth :
- g. Malaligned Teeth :

Caries $\frac{6}{6}$

Stains +

Calculus +

3. ORAL LESIONS:-

Rp
- Phos-flur Mouthwash - Bd
2 months

4. DIAGNOSIS:-

5. TREATMENT PLANNING:

6. FOLLOW UP:-

Referral To Other Consultant: Yes/ No

If Yes, please mention the Name:

Doctor's Signature Anny

Facilities Available :

- ★ MULTI-SPECIALITY HOSPITAL ★ MODULAR FULLY EQUIPPED OT ★ NURSERY ★ LAPROSCOPIC SURGERY
- ★ 24X7 EMERGENCY ★ OPG ★ DENTAL ★ 24X7 DIAGNOSTICS ★ LABOUR ROOM ★ ECHO ★ EEG ★ DIGITAL X-RAY ★ CT SCAN
- ★ ECG ★ ULTRASOUND ★ RICU/ICU ★ ALL SPECIALITY OPD ★ PLASTIC & COSMETIC SURGERY ★ DIALYSIS ★ PHARMACY

Neha Arora

Alena
12/4/24

ID: 9990061551

7-Apr-2024 11:11:48

ID: 9990061551

MAC600 1.02

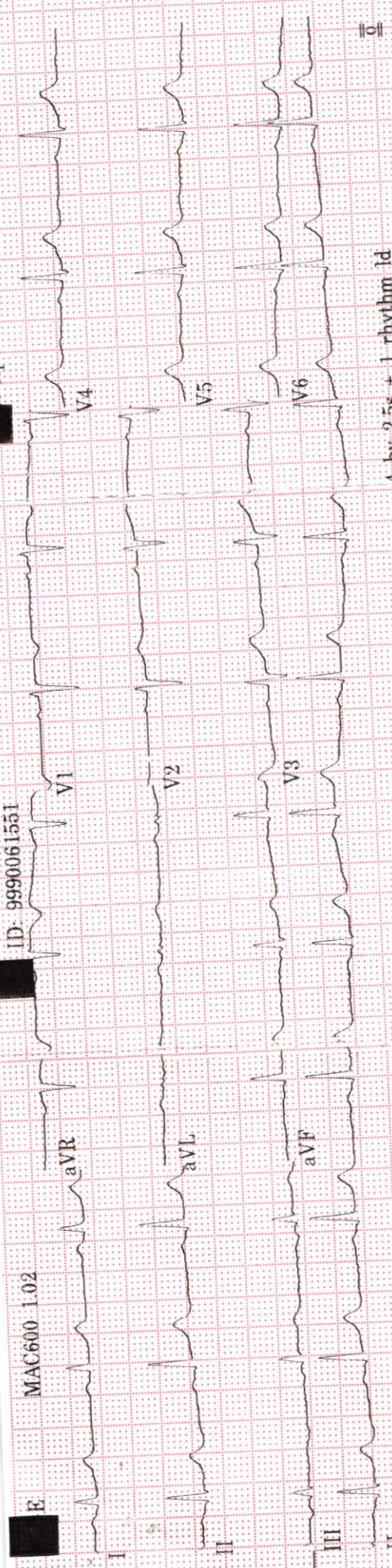
36years Female

MAC600 1.02

MAC600 1.02

Vent. rate	67 bpm
QRS duration	80 ms
QT/QTc	388/409 ms
PR interval	158 ms
P duration	96 ms
RR interval	895 ms
P-R-T axes	9 55 39

MAC600 1.02 12SL™ v239



0.16-20Hz 25.0 mm/s 10.0 mm/mV 50Hz 67 bpm

4 by 2.5s + 1 rhythm ld

Malik Radix HealthCare.

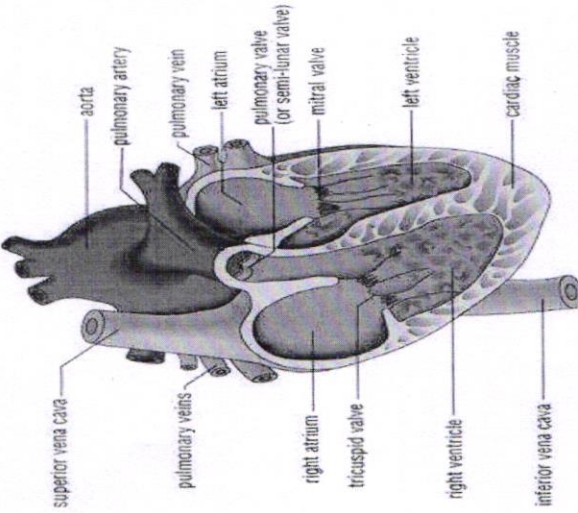
ELECTROCARDIOGRAM

Name: MRS. NEHA ARORA

Age & Sex: 36 YR/ FEMALE

Ref By: MEDIWHEEL

Date: 17/04/2024



ECG FINDINGS:

Rate 67 bpm Rhythm Sinus Mechanism Normal

Axis Normal P Wave Normal PR Interval 0.15/Sec

QRS Complex Normal QT Interval Normal Q Wave Normal

ST Segment Normal T Wave Normal

Conclusion Sinus Rhythm, Normal Axis, WNL.

Doctors Signature _____

Dr. SHEIKH NAZIR AHMED
M.D. "Physician"
PGDCC
DMC-46499



ANNUAL HEALTH CHECK UP

NAME: Neha Agrora

AGE/GENDER: 36 / Female

DATE 17/04/24

W
C
glasses

Heart 156
120

UBI
last checked
6 mth back

Color u:
vsl

Ady

9 Hypertension

Cap Berjomega

(BS)

X (with)

Dr. Neha Gupta
MBBS, MS, DNB
Casualty Ophthalmologist
Malik Radix Healthcare Pvt. Ltd.
DMC No. 121631

Facilities Available

- Multispeciality Hospital - 24 Hours Emergency - X-Ray/ ECG/ Ultrasound/ CT Scan - Dental- Fully Equipped Operation Theatre
- Fully Functional Lab - 24/7 Casualty/ ICU-Nursery 24/7 Pharmacy - Labour Room - All Speciality OPD - Laproscopic Surgery - ECHO - Plastic Surgery



LAB REPORT

Reg. Date	17/04/2024	Patient Id	2404170003	DOB.	
Name	MRS. NEHA ARORA	Gender	F	Perm. ID	
Age	36 Yrs.	Panel	MEDIWHEEL	Reported	17/04/2024 16:06:03
Ref. By	MEDIWHEEL				

Test Name	Result	Units	Ref. Range
-----------	--------	-------	------------

MEDIWHEEL AHC STARTER FEMALE

HAEMATOLOGY

COMPLETE HAEMOGRAM

HAEMOGLOBIN (HB%)	10.4	gm/dl	12 - 15
TOTAL LEUCOCYTE COUNT (TLC)	6,700	/cumm	4000 - 11000

DIFFERENTIAL LEUCOCYTE COUNT (DLC)

NEUTROPHIL	57	%	40 - 80
LYMPHOCYTE	34	%	28 - 55
MONOCYTE	04	%	02 - 10
EOSINOPHIL	05	%	01 - 06
BASOPHIL	00	%	0 - 0

ESR (WESTEGREN'S METHOD)	22	mm/1st hr.	0 - 15
R B C COUNT	5.77	Millions/cmm	4.247 - 5.4
P.C.V / HAEMATOCRIT	34.0	%	35 - 45
M C V	58.9	fl.	80 - 100
M C H	18.0	Picogram	27.0 - 31.0
M C H C	30.6	gm/dl	33 - 37
PLATELET COUNT	2.88	Lakh/cu mm	1.50 - 4.50

BLOOD GROUP ABO	" B "		
RH TYPING	Positive		
BLOOD SUGAR FASTING	85.61	mg/dl	70 - 100

THYROID PROFILE

Free T3 ELFA	3.19	ng/ml	02 - 04
Free T4 ELFA	1.13	ug/dl	0.8 - 2.7
TSH Serum/ELFA	2.860	uIU/ml	

Checked by : _____
 Page 1 Contd...2

If test results are alarming or unexpected, patient is advised to contact the laboratory immediately for possible remedial action.

Facilities Available

- Multispeciality Hospital - 24 Hours Emergency - X-Ray/ ECG/ Ultrasound/ CT Scan - Dental- Fully Equipped Operation Theatre
 - Fully Functional Lab - 24/7 Casualty/ ICU-Nursery 24/7 Pharmacy - Labour Room - All Speciality OPD - Laproscopic Surgery -
 ECHO - Plastic Surgery



LAB REPORT

Reg. Date	17/04/2024	Patient Id	2404170003	DOB.	
Name	MRS. NEHA ARORA	Gender	F	Perm. ID	
Age	36 Yrs.	Panel	MEDIWHEEL	Reported	17/04/2024 16:06:03
Ref. By	MEDIWHEEL				

Test Name	Result	Units	Ref. Range
			0.25 - 5.50 uIU/ml

Interpretation

Clinical Use

- Diagnose Hypothyroidism and Hyperthyroidism
- Monitor T4 replacement or T4 suppressive Therapy
- Quantify TSH levels in the subnormal range

Increased Levels : Primary Hypothyroidism Subclinical Hypothyroidism, TSH dependent, Thyroid Hormone Resistance.

Decreased Levels : Grave's Disease, Autonomous Thyroid Hormone Secretion, TSH Deficiency

LIPID PROFILE

TOTAL CHOLESTEROL	106.60	mg/dL	130.0 - 200.0 (<200)
TRIGLYCERIDES	158.00	mg/dL	80.5 - 150.0 (<150)
H D L CHOLESTEROL DIRECT	47.68	mg/dL	42.0 - 60.0 (<40->59)
V L D L	31.6	mg/dL	4.0 - 30. (23-45)
L D L CHOLESTEROL	27.3	mg/dL	50.0 - 150.0 (50-150)
TOTAL CHOLESTEROL / HDL RATIO	2.2		3.3 - 5.1
LDL / HDL CHOLESTEROL RATIO	0.6		1.5 - 3.5

LIVER FUNCTION TEST (LFT)

BILIRUBIN TOTAL	1.11	mg/dl	0.2 - 1.2
CONJUGATED (D. BILIRUBIN)	0.14	mg/dl	0.00 - 0.3
UNCONJUGATED (I.D.BILIRUBIN)	0.97	mg/dl	0.2 - 0.9

Checked by : -----
 Page 2 Contd...3

If test results are alarming or unexpected, patient is advised to contact the laboratory immediately for possible remedial action.

Facilities Available

- Multispeciality Hospital - 24 Hours Emergency - X-Ray/ ECG/ Ultrasound/ CT Scan - Dental- Fully Equipped Operation Theatre
 - Fully Functional Lab - 24/7 Casualty/ ICU-Nursery 24/7 Pharmacy - Labour Room - All Speciality OPD - Laproscopic Surgery -
 ECHO - Plastic Surgery



LAB REPORT

Reg. Date	17/04/2024	Patient Id	2404170003	DOB.	
Name	MRS. NEHA ARORA	Gender	F	Perm. ID	
Age	36 Yrs.	Panel	MEDIWHEEL	Reported	17/04/2024 16:06:03
Ref. By	MEDIWHEEL				

Test Name	Result	Units	Ref. Range
SGOT / AST	25.10	IU/L	0 - 35
SGPT / ALT	32.6	IU/L	0 - 35
ALKALINE PHOSPHATASE	110.20	U/L	64 - 306
TOTAL PROTEIN	7.76	gm/dl	6.0 - 8.3
ALBUMIN	4.46	gm/dl	3.2 - 5.0
GLOBULIN	3.30	gm/dl	2.5 - 5.6
A/G RATIO	1.35		0.9 - 2.0
GAMMA GT	22.30	IU/L	0.0 - 35.0
SERUM CREATININE	1.00	mg/dl	0.6 - 1.2
SERUM URIC ACID	5.84	mg/dl	2.4 - 6.0
BLOOD UREA NITROGEN (BUN)	10.04	mg/dl	6.0 - 21.0
BUN/CREAT RATIO	10.04	mg/dl	10 - 20
Urine Routine Examination			

PHYSICAL EXAMINATION

QUANTITY	50	ml.	
COLOUR	Pale Yellow		Pale Yellow
TRANSPARENCY	Slightly Turbid		
SPECIFIC GRAVITY	1.020		
PH	6.0		

CHEMICAL EXAMINATION

ALBUMIN	Nil
SUGAR	Nil

MICROSCOPIC EXAMINATION

PUS CELLS	2-3	/HPF
RBC'S	Nil	/HPF
CASTS	Nil	

Checked by : _____
Page 3 Contd...4

If test results are alarming or unexpected, patient is advised to contact the laboratory immediately for possible remedial action.

Facilities Available

- Multispeciality Hospital - 24 Hours Emergency - X-Ray/ ECG/ Ultrasound/ CT Scan - Dental- Fully Equipped Operation Theatre
- Fully Functional Lab - 24/7 Casualty/ ICU-Nursery 24/7 Pharmacy - Labour Room - All Speciality OPD - Laproscopic Surgery - ECHO - Plastic Surgery



LAB REPORT

Reg. Date	17/04/2024	Patient Id	2404170003	DOB.	
Name	MRS. NEHA ARORA	Gender	F	Perm. ID	
Age	36 Yrs.	Panel	MEDIWHEEL	Reported	17/04/2024 16:06:03
Ref. By	MEDIWHEEL				

Test Name	Result	Units	Ref. Range
CRYSTALS	NIL		
EPITHELIAL CELLS	1-2	/HPF	
BACTERIA	Nil		
OTHERS	Nil		

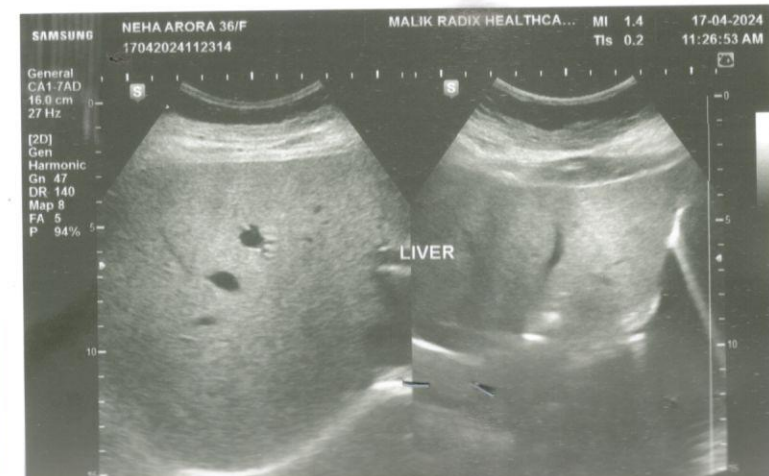
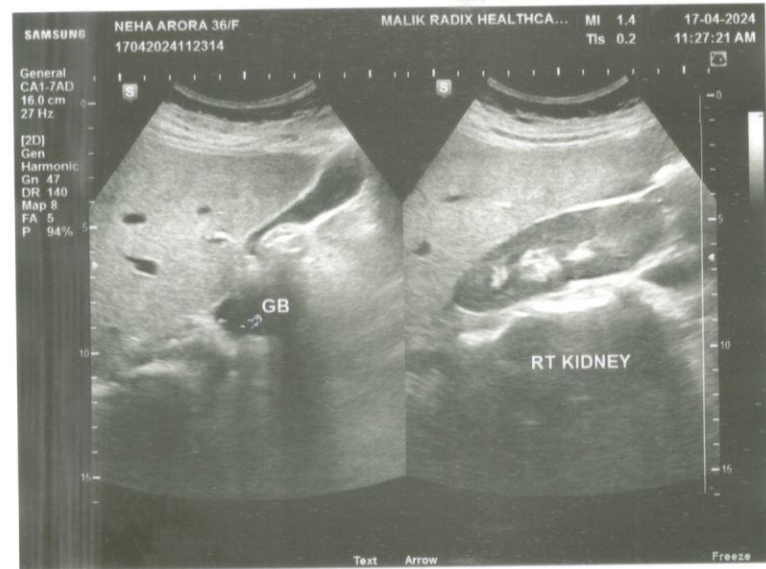
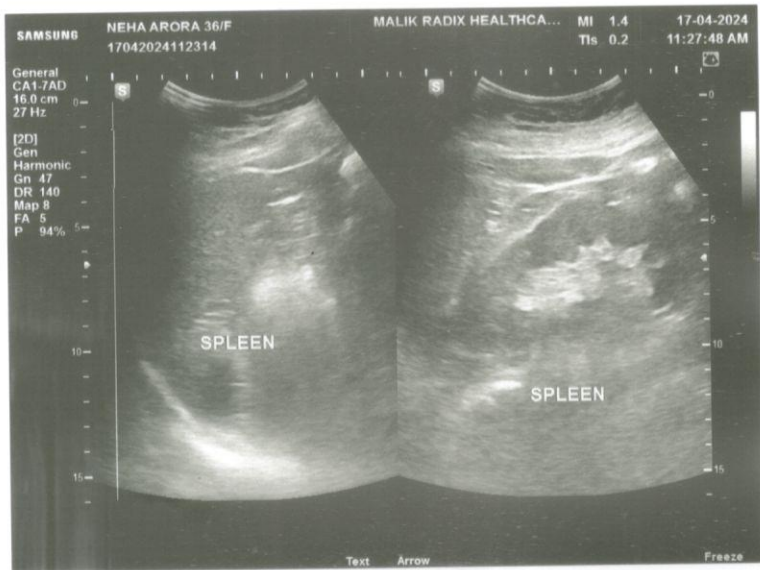
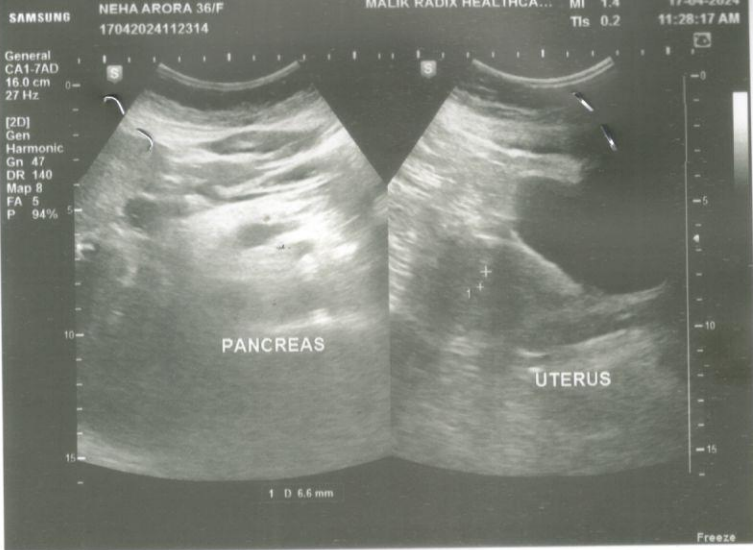
Dr. REEMA DAHIYA
 M.B.B.S, MD (Path)
 DR. REEMA DAHIYA
 M.B.B.S, MD (Path)
 Malik Radix Healthcare Pvt. Ltd.
 C/217, C/218, Vikas Marg, Nirman Vihar,
 New Delhi-110092
 Checked by _____
 Page 4 of 4

DR. MEENU AGGARWAL
 M.B.B.S, MD (Path.)

If test results are alarming or unexpected, patient is advised to contact the laboratory immediately for possible remedial action.

Facilities Available

- Multispeciality Hospital - 24 Hours Emergency - X-Ray/ ECG/ Ultrasound/ CT Scan - Dental- Fully Equipped Operation Theatre
- Fully Functional Lab - 24/7 Casualty/ ICU-Nursery 24/7 Pharmacy - Labour Room - All Speciality OPD - Laproscopic Surgery - ECHO - Plastic Surgery




RADIX
HEALTH
care



Malik Radix Healthcare

C/217, C/218, Vikas Marg, Nirman Vihar, New Delhi-110092
A Unit of Malik Radix Healthcare
Toll Free - 1800-120-5457
Whatsapp No. - 9811550650
E-mail: info@radixhealthcare.org
Website: www.radixhealthcare.org



NAME	MRS NEHA ARORA	AGE	36 Y/F
REFD. BY.	HEALTH CHECK UP	DATE	17.04.24

Ultrasound Examination of Whole Abdomen & Pelvis :

Liver: Liver shows normal parenchymal echotexture. No focal SOL is seen in liver. IHBR & portal radicles are normal.

Gallbladder: Gallbladder shows normal anechoic pattern . No evidence of cholecystitis or cholelithiasis is seen. Common bile duct is normal in course & caliber.

Pancreas: Pancreas shows normal size & echotexture.

Spleen: Spleen shows normal size, outline & echotexture.

Kidneys: Kidneys show normal size, shape, position & echotexture. No calculus, hydronephrosis or SOL is seen in kidneys. Cortico- medullary differentiation and cortical thickness is normal on both sides.

No supra- renal mass seen.

Great abdominal vessels are normal.

Domes of diaphragm are seen to move normally & synchronously in respiration. No supra- or infra diaphragmatic collection is seen.

No ascites or pericardial effusion seen.

No para aortic lymph nodes seen.

Urinary bladder: Urinary bladder shows normal anechoic pattern. No calculus, SOL or diverticulum seen.

Uterus: Uterus is anteverted and normal in size & echotexture. No intrinsic SOL is seen in uterus. Endometrial thickness is 6.6 mm.

Adnexa: Adnexal regions including the ovaries are sonographically normal.

Regards.

Dr Mukesh Koshal MD (Rad- diag)
Regn. No. DMC 10407

RADIOLOGIST :

Facilities Available

- Multispeciality Hospital - 24 Hours Emergency - X-Ray/ ECG/ Ultrasound/ CT Scan - Dental - Fully Equipped Operation Theatre
- Fully Functional Lab - 24/7 Casualty/ ICU-Nursery 24/7 Pharmacy - Labour Room - All Speciality OPD - Laproscopic Surgery
- ECHO - Plastic Surgery