

Health Check up Booking Confirmed Request(22E32828), Package Code-PKG10000477, Beneficiary Code-320188

Mediwheel <wellness@mediwheel.in>
From: healthcare.medicals@gmail.com
To: customercare@mediwheel.in

Mon, Sep 9, 2024 at 11:30



Mediwheel
...Your wellness partner

011-41195959

Hi **Healthcare Medical Centre and Diagnostic**,
The following booking has been confirmed. It is requested to honor the said booking & provide priority services to our client

Hospital Package Name : Mediwheel Full Body Health Checkup Female Above 40

Patient Package Name : Mediwheel Full Body Health Checkup Female Above 40

Hospital Address : 1st Floor Patel House, Rang Bhawan Building, MG Cross Rd, Vile Parle East, Mumbai 400057

Contact Details : 9819670305

Appointment Date : 10-09-2024

Confirmation Status : Booking Confirmed

Preferred Time : 09:00 AM - 09:30 AM

Member Information		
Booked Member Name	Age	Gender
JYOTSNA JAYESH DALAL	68 year	Female

We request you to facilitate the employee on priority.

Thanks,
Mediwheel Team
Please Download Mediwheel App



You have received this mail because your e-mail ID is registered with **Arcofemi Healthcare Limited** This is a system-generated e-mail please don't reply to this message.

Please visit to our Terms & Conditions for more information. Click here to unsubscribe.

आयकर विभाग
INCOME TAX DEPARTMENT



भारत सरकार
GOVT. OF INDIA



नाम / Name
ज्योत्सना जयेश दलाल
JYOTSNA JAYESH DALAL


पिता का नाम / Father's Name
मटवलरल त्रिकामल शाह
MATVERLAL TRIKAMILAL SHAH

जन्म की तारीख /
Date of Birth
23/07/1956

स्थायी लेखा संख्या कार्ड
Permanent Account Number Card

AACPD2636F

हस्ताक्षर / Signature




DR. YOGESH J. MEHTA M.D
Physician & Cardiologist
Reg. No. - 71131

HEALTHCARE
MEDICAL CENTRE AND DIAGNOSTICS
RANG BHAWAN BLDG, MG CROSS RD
VILE PARLE EAST, MUMBAI-400057
MOBILE NO - 8779695778

- COMPU. PATHOLOGY • ALLERGY TESTING
- DIGITAL WHOLE BODY X-RAYS
- DIGITAL 3D SONOGRAPHY
- DIGITAL WHOLE BODY COLOUR DOPPLER
- DIGITAL 2-D ECHO WITH COLOUR DOPPLER
- E.C.G. • LUNG FUNCTION TEST
- MAMMOGRAPHY & BONE MINERAL DENSITOMETRY

- COMPUTERISED STRESS TEST
- DENTAL
- ADVANCED DENTISTRY
- PHYSIOTHERAPY
- AUDIOMETRY & SPEECH THERAPY
- FULL BODY HEALTH CHECK-UPS
- CORPORATE HEALTH CHECKUPS



HEALTHCARE

MEDICAL CENTRE & DIAGNOSTICS

NAME	MRS JYOTSNA DALAL	DATE	DR SIGNATURE
HEIGHT: 141 CM	WEIGHT = 66.6 KG	AGE	10/9/24
REFERRED BY	MEDIWHEEL	SEX	68YRS
PRESENT COMPLAINT: BP SINCE 2YRS /DYSGLIPIDEMIA SINCE 10YRS			
CURRENT MEDICATION = TAB CONCOR 2.5/TAB AMLIP 2.5 /TAB ZENCVAST 20			
PAST HISTORY = TRABECULECTOMY BIL /LFT LEG DVT 20YRS PRIOR			
ALLERGY: NONE HABITS: NONE APPETITE: GOOD			
SLEEP: GOOD BLADDER: NONE BOWEL: NAD			
FAMILY HISTORY = FATHER-DM /PARKINSON(DIED) MOTHER = MI (DIED)			
GYNEC HISTOR = MENOPAUSE SINCE 10 YRS			
<u>GENERAL EXAMINATION:</u> <u>ADVICE-</u>			
P: 68 / MIN BP: 130/60 MM HG			
PALLOR: NO ICTERUS: NO			
OEDEMA: NO OTHERS: NAD			
RS: AEBE NO			
CVS: S1 S2 NORMAL			
PA: NAD			
CNS: NAD			
<u>INVESTIGATION:</u>			

Reduce sugar intake
Exercise daily
T. Livozen o to x 1mth
Repeat HbA1c after 3 mth

DR. Y. J. MEHTA, M.D.
DR. YOGESH J. MEHTA, M.D.
Physician & Cardiologist
Reg. No. - 71131

HEALTHCARE
MEDICAL CENTRE AND DIAGNOSTICS
RANGERS ROAD, VILE PARLE EAST, MUMBAI - 400 057
VILE PARLE EAST, MUMBAI - 400 057
011 5069 778

- COMPU. PATHOLOGY • ALLERGY TESTING
- DIGITAL WHOLE BODY X-RAYS
- DIGITAL 3D SONOGRAPHY
- DIGITAL WHOLE BODY COLOUR DOPPLER
- DIGITAL 2-D ECHO WITH COLOUR DOPPLER
- E.C.G. • LUNG FUNCTION TEST
- MAMMOGRAPHY & BONE MINERAL DENSITOMETRY

- COMPUTERISED STRESS TEST
- DENTAL
- ADVANCED DENTISTRY
- PHYSIOTHERAPY
- AUDIOMETRY & SPEECH THERAPY
- FULL BODY HEALTH CHECK-UPS
- CORPORATE HEALTH CHECKUPS



DENTAL CHECK UP

NAME	MRS JYOSTSNA DALAL	DATE	10/9/24
REFERRED BY	MEDIWHEEL	AGE –	68
		YRS	SEX F

CHIEF COMPLAINT : NONE	
PAST DENTAL HISTORY : CLIP AT UPPER RT MOLAR /LOWER LEFT MOLAR EXTRACTION	
HABITS =NONE	
ORAL EXAMINATION : NO CARIES	
HEALTHY MUCOSA	
NO ULCERS	
NO STAINS	
NO GUM BLEEDING	
TREATMENT :REGULAR ORAL HYGIENE	
USE FLUORIDE TOOTHPASTE AND FLOSS	

HEALTHCARE
MEDICAL CENTRE AND DIAGNOSTICS
RANG ENGLISH ROAD, CHANDS CROSS RD
VILE PARLE EAST, MUMBAI - 400057
MOBILE NO. 8779865778

- COMPU. PATHOLOGY • ALLERGY TESTING
- DIGITAL WHOLE BODY X-RAYS
- DIGITAL 3D SONOGRAPHY
- DIGITAL WHOLE BODY COLOUR DOPPLER
- DIGITAL 2-D ECHO WITH COLOUR DOPPLER
- E.C.G. • LUNG FUNCTION TEST
- MAMMOGRAPHY & BONE MINERAL DENSITOMETRY

- COMPUTERISED STRESS TEST
- DENTAL
- ADVANCED DENTISTRY
- PHYSIOTHERAPY
- AUDIOMETRY & SPEECH THERAPY
- FULL BODY HEALTH CHECK-UPS
- CORPORATE HEALTH CHECKUPS



HEALTHCARE

MEDICAL CENTRE & DIAGNOSTICS

Copyright © The McGraw-Hill Companies, Inc. Permission required for reproduction or display

NAME	MRS JYOTSNA DALAL	DATE	10/09/24
PATIENT ID		AGE	68YRS
REFERRED BY	MEDIWHEEL	SEX	FEMALE

GYNAEC / OBST. CHECK-UP

PRESENT COMPLAINTS: NONE

CURRENT MEDICATION: TAB CONCOR 2.5/TAB AMILIP 2.5

PRESENT MENSTRUAL HISTORY: REGULAR - ONE EPISODE OF OVARIAN CYST BLEEDING AT AGE 56 YRS - MENOPAUSE AT AGE OF =54

GYNAEC HISTORY: MENSES == REGULAR HISTORY

LMP: MENOPAUSE

OBST HISTORY: G4P4A2L2 -FTND

BREAST EXAM: NORMAL CONTOUR, SYMMETRICAL BILATERAL, NO NIPPLE DISCHARGE. NO LUMP

HEALTHCARE
 MEDICAL CENTRE AND DIAGNOSTICS,
 RANG BHAWAN BLDG, MB CROSS RD,
 VILE PARLE EAST, MUMBAI-400057
 MOBILE NO -- 8779865778

- COMPU. PATHOLOGY • ALLERGY TESTING
- DIGITAL WHOLE BODY X-RAYS
- DIGITAL 3D SONOGRAPHY
- DIGITAL WHOLE BODY COLOUR DOPPLER
- DIGITAL 2-D ECHO WITH COLOUR DOPPLER
- E.C.G. • LUNG FUNCTION TEST
- MAMMOGRAPHY & BONE MINERAL DENSITOMETRY

- COMPUTERISED STRESS TEST
- DENTAL
- ADVANCED DENTISTRY
- PHYSIOTHERAPY
- AUDIOMETRY & SPEECH THERAPY
- FULL BODY HEALTH CHECK-UPS
- CORPORATE HEALTH CHECKUPS



OPHTHALMIC REPORT

NAME= Jyotsna Dalal DATE= 10/9/24
 R- NO AGE= 68
 SEX= F

RIGHT EYE LEFT EYE

V.A. WITHOUT GLASSES : 6/9 6/6

V.A. WITH GLASSES : 6/6

SLIT LAMP EXAMINATION: NORMAL

IOP – SCHIOTZ TONOMETER: —

FUNDUS: NORMAL

COLOUR VISION: NORMAL (BE) Normal (BE)

(ISHIHARA CHART)

OCULAR MOVEMENTS: NORMAL (BE)

RETINOSCOPY:

Prescription:

	SPH	CYL	AXIS	SPH	CYL	AXIS
DISTANCE	<u>-0.75</u>			<u>PLANO</u>		
NEAR			<u>+2.25</u>			

CLINICAL IMPRESSION: (N)
 ADVICE: EYE EXERCISE AND DECREASE SCREEN TIME

glasses

DR. PRADEEP RANE
 MEDICAL CENTRE AND DIAGNOSTICS
 RANG BHAWAN BLDG, MG CROSS RD
 VILE PARLE EAST, MUMBAI-400057
 MOBILE NO - 8779885778

- COMPU. PATHOLOGY • ALLERGY TESTING
- DIGITAL WHOLE BODY X-RAYS
- DIGITAL 3D SONOGRAPHY
- DIGITAL WHOLE BODY COLOUR DOPPLER
- DIGITAL 2-D ECHO WITH COLOUR DOPPLER
- E.C.G. • LUNG FUNCTION TEST
- MAMMOGRAPHY & BONE MINERAL DENSITOMETRY

- COMPUTERISED STRESS TEST
- DENTAL
- ADVANCED DENTISTRY
- PHYSIOTHERAPY
- AUDIOMETRY & SPEECH THERAPY
- FULL BODY HEALTH CHECK-UPS
- CORPORATE HEALTH CHECKUPS



HEALTHCARE

MEDICAL CENTRE & DIAGNOSTICS

NAME	MRS JYOTSNA JAYESH DALAL	DATE	10.09.2024
		AGE	68 YRS
REF. BY	ARCOFEMI HEALTHCARE	SEX	FEMALE

X-RAY CHEST (PAVIEW).

The lungs on the either side show equal translucency.

The pleural spaces are normal.

The cardiac size is normal.

The domes of the diaphragms are normal in position, and show smooth outline.

Ribs appear normal.

IMPRESSION :
NO EVIDENCE OF PLEURAL OR PARENCHYMAL PATHOLOGY IS NOTED.

DR.SUDHANSHU SAXENA
CONS.RADIOLOGIST.

Note : Investigations have their limitations. Solitary radiological investigations never confirm the final diagnosis. They only help in diagnosing the disease in correlation to clinical symptoms and other related tests. Please interpret accordingly

- COMPU. PATHOLOGY • ALLERGY TESTING
- DIGITAL WHOLE BODY X-RAYS
- DIGITAL 3D SONOGRAPHY
- DIGITAL WHOLE BODY COLOUR DOPPLER
- DIGITAL 2-D ECHO WITH COLOUR DOPPLER
- E.C.G. • LUNG FUNCTION TEST
- MAMMOGRAPHY & BONE MINERAL DENSITOMETRY

- COMPUTERISED STRESS TEST
- DENTAL
- ADVANCED DENTISTRY
- PHYSIOTHERAPY
- AUDIOMETRY & SPEECH THERAPY
- FULL BODY HEALTH CHECK-UPS
- CORPORATE HEALTH CHECKUPS



NAME	MRS JYOTSNA JAYESH DALAL	DATE	10.09.2024
		AGE	68 YRS
REF. BY	ARCOFEMI HEALTHCARE	SEX	FEMALE

2D-ECHOCARDIOGRAPHY & DOPPLER FINDINGS:

Normal sized LA, RA, RV and LV
 2DEF= 60%
 No hypertrophy seen.
 No evidence of hypokinesia.
 All valves morphologically normal.
 Trivial tricuspid regurgitation seen.
 RVSP= 28mmHg
 No PAH.
 No thrombus/vegetation seen.
 IAS and IVS intact. No shunt lesion seen.
 IVC non dilated with more than 50% inspiratory collapse seen.
 Normal RV function seen.
 TAPSE=2.2cms, MAPSE=1.6cm
 Pericardium normal. No pericardial effusion
 No diastolic dysfunction seen.
 Normal LV systolic function.

M-MODE MEASUREMENT:

LEFT VENTRICULAR	
IVSd	11 mm
IVSs	17 mm
LVIDd	42 mm
LVIDs	22 mm
LVPWd	10 mm
LVPWs	18 mm
EF (Teich)	60 %
% FS	33 %

Cont on page 2....

- COMPU. PATHOLOGY • ALLERGY TESTING
- DIGITAL WHOLE BODY X-RAYS
- DIGITAL 3D SONOGRAPHY
- DIGITAL WHOLE BODY COLOUR DOPPLER
- DIGITAL 2-D ECHO WITH COLOUR DOPPLER
- E.C.G. • LUNG FUNCTION TEST
- MAMMOGRAPHY & BONE MINERAL DENSITOMETRY

- COMPUTERISED STRESS TEST
- DENTAL
- ADVANCED DENTISTRY
- PHYSIOTHERAPY
- AUDIOMETRY & SPEECH THERAPY
- FULL BODY HEALTH CHECK-UPS
- CORPORATE HEALTH CHECKUPS



Copyright © The McGraw-Hill Companies, Inc. Permission required for reproduction or display.

NAME	MRS JYOTSNA JAYESH DALAL	DATE	10.09.2024
		AGE	68 YRS
REF. BY	ARCOFEMI HEALTHCARE	SEX	FEMALE

AORTA		
AO	22 mm	
LA	32 mm	
AVO	18	

MITRAL VALVE	
DE	1.70 cm
EF SLOPE	0.12

DOPPLER STUDY:

PWD left ventricular inflow shows E/ A waves.
 Mitral valve: Dec time= 1175ms, E>A, E/E'=7
 Aortic valve: 6mmHg
 Pulmonary valve: 2.40mmHg
 IVC non dilated with more than 50% inspiratory collapse seen.


DR. DINESH ROHIRA
MBBS, DNB MEDICINE

(a) Anterior view

- COMPU. PATHOLOGY • ALLERGY TESTING
- DIGITAL WHOLE BODY X-RAYS
- DIGITAL 3D SONOGRAPHY
- DIGITAL WHOLE BODY COLOUR DOPPLER
- DIGITAL 2-D ECHO WITH COLOUR DOPPLER
- E.C.G. • LUNG FUNCTION TEST
- MAMMOGRAPHY & BONE MINERAL DENSITOMETRY

- COMPUTERISED STRESS TEST
- DENTAL
- ADVANCED DENTISTRY
- PHYSIOTHERAPY
- AUDIOMETRY & SPEECH THERAPY
- FULL BODY HEALTH CHECK-UPS
- CORPORATE HEALTH CHECKUPS



NAME	MRS JYOTSNA DALAL	DATE	10.06.2024
		AGE	68YRS
REF. BY	MEDIWHEEL	SEX	FEMALE

ABDOMEN & PELVIC SONOGRAPHY

LIVER: Liver is normal in size showing grade I fatty infiltration. There is no evidence of solid or cystic mass lesion. The portal and the hepatic venous system appears normal. No evidence of any intra or extrahepatic biliary radical's dilatation noted.

GALL BLADDER: The Gall bladder is well distended. No evidence of gall stones. No evidence of wall thickening/pericholecystic collection noted. CBD appears normal.

PANCREAS: Pancreas shows homogenous parenchymal echotexture. No focal lesion seen.

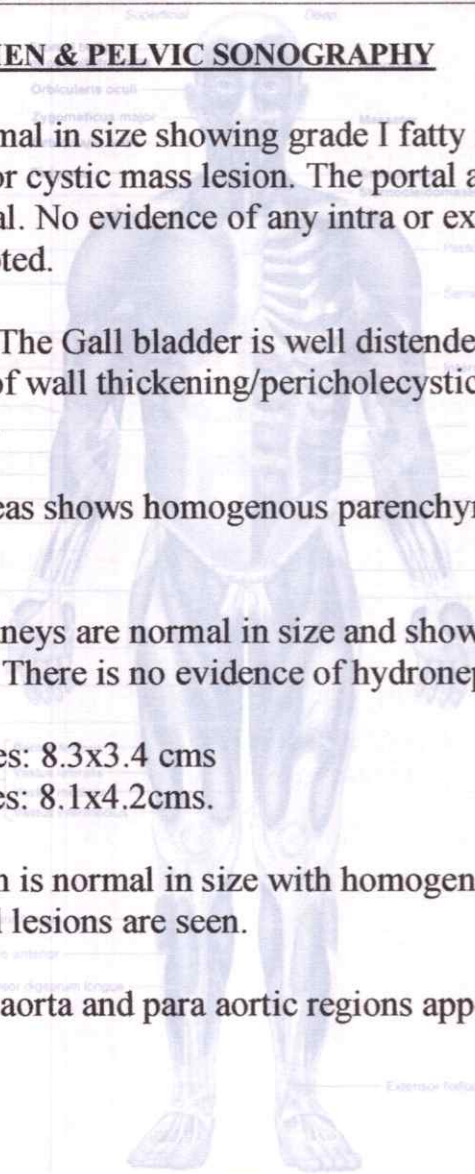
KIDNEYS: Both kidneys are normal in size and shows homogenous cortical echotexture. There is no evidence of hydronephrosis/ focal lesion/calculi noted.

Right kidney measures: 8.3x3.4 cms

Left kidney measures: 8.1x4.2cms.

SPLEEN: The spleen is normal in size with homogenous parenchymal echotexture. No focal lesions are seen.

AORTA: The upper aorta and para aortic regions appear normal.



P.T.O.

- COMPU. PATHOLOGY • ALLERGY TESTING
- DIGITAL WHOLE BODY X-RAYS
- DIGITAL 3D SONOGRAPHY
- DIGITAL WHOLE BODY COLOUR DOPPLER
- DIGITAL 2-D ECHO WITH COLOUR DOPPLER
- E.C.G. • LUNG FUNCTION TEST
- MAMMOGRAPHY & BONE MINERAL DENSITOMETRY

- COMPUTERISED STRESS TEST
- DENTAL
- ADVANCED DENTISTRY
- PHYSIOTHERAPY
- AUDIOMETRY & SPEECH THERAPY
- FULL BODY HEALTH CHECK-UPS
- CORPORATE HEALTH CHECKUPS



NAME	MRS JYOTSNA DALAL	DATE	10.06.2024
		AGE	68YRS
REF. BY	MEDIWHEEL	SEX	FEMALE

URINARY BLADDER: Urinary bladder is well distended. No evidence of calculus or intraluminal mass seen.

UTERUS (TAS):

Uterus is anteverted and atrophic, measures: 5.1x2.2x4.8 cms, vol- 29cc
No evidence of focal lesion.
Endometrial lining measures 5 mm with minimal fluid within.

OVARIES & ADNEXA:

Both ovary is normal in size and shows homogenous echo pattern. No evidence of focal lesion.
Right ovary measures: 2.3x08cm.
Left ovary measures: 2.2x1.1 cm.

No evidence of free fluid.

IMPRESSION:

- **Grade I fatty liver.**
- **No other significant abnormality is seen.**

Dr. Sheetal Thaker

DR. SHEETAL THAKER
CONS.RADIOLOGIST.

Note: Investigations have their limitations. Solitary radiological investigations never confirm the final diagnosis. They only help in diagnosing the disease in correlation to clinical symptoms and other related tests. USG is known to have interobserver variation. Further / Follow-up imaging may be needed in some cases for confirmation of USG findings..Please interpret accordingly.

- COMPU. PATHOLOGY • ALLERGY TESTING
- DIGITAL WHOLE BODY X-RAYS
- DIGITAL 3D SONOGRAPHY
- DIGITAL WHOLE BODY COLOUR DOPPLER
- DIGITAL 2-D ECHO WITH COLOUR DOPPLER
- E.C.G. • LUNG FUNCTION TEST
- MAMMOGRAPHY & BONE MINERAL DENSITOMETRY

- COMPUTERISED STRESS TEST
- DENTAL
- ADVANCED DENTISTRY
- PHYSIOTHERAPY
- AUDIOMETRY & SPEECH THERAPY
- FULL BODY HEALTH CHECK-UPS
- CORPORATE HEALTH CHECKUPS



HEALTHCARE

MEDICAL CENTRE & DIAGNOSTICS

NAME	MRS JYOTSNA DALAL	DATE	10.09.2024
		AGE	68 YRS
REF. BY	MEDIWHEEL	SEX	FEMALE

SONOMAMMOGRAPHY OF BOTH BREASTS

Both breasts revealed predominance of glandular tissue.

No focal solid or cystic lesion is seen in either breasts.

No e/o any axillary lymphadenopathy.

IMPRESSION:

➤ **No significant abnormality is seen.**

suggest follow up

DISCLAIMER : THIS SONOMAMMOGRAPHY WAS DONE AS PER COMPANY PACKAGE. HOWEVER, XRAY MAMMOGRAPHY IS RECOMMENDED IN WOMEN OVER THE AGE OF 40 YRS.

Shaker
DR. SHEETAL THAKER
CONS. RADIOLOGIST.

Note : Investigations have their limitations. Solitary radiological investigations never confirm the final diagnosis. They only help in diagnosing the disease in correlation to clinical symptoms and other related tests. USG is known to have interobserver variation. Further / Follow-up imaging may be needed in some cases for confirmation of USG findings.. Please interpret accordingly.

- COMPU. PATHOLOGY
- DIGITAL X-RAY
- DIGITAL SONOGRAPHY
- DIGITAL COLOR DOPPLER
- 2D ECHO CARDIOGRAPHY
- MAMMOGRAPHY & BONE MINERAL DENSITOMETRY (BMD)
- ECG ■ PFT
- COMPU. TREADMILL TEST
- PHYSIOTHERAPY
- DENTAL
- HEALTH CHECK-UP



MEDICAL CENTRE & DIAGNOSTICS

MRS JYOTSNA JAYESH DALA

ELIC7839 10-Sep-2024



ECC

ELECTROCARDIOGRAM (ECG)

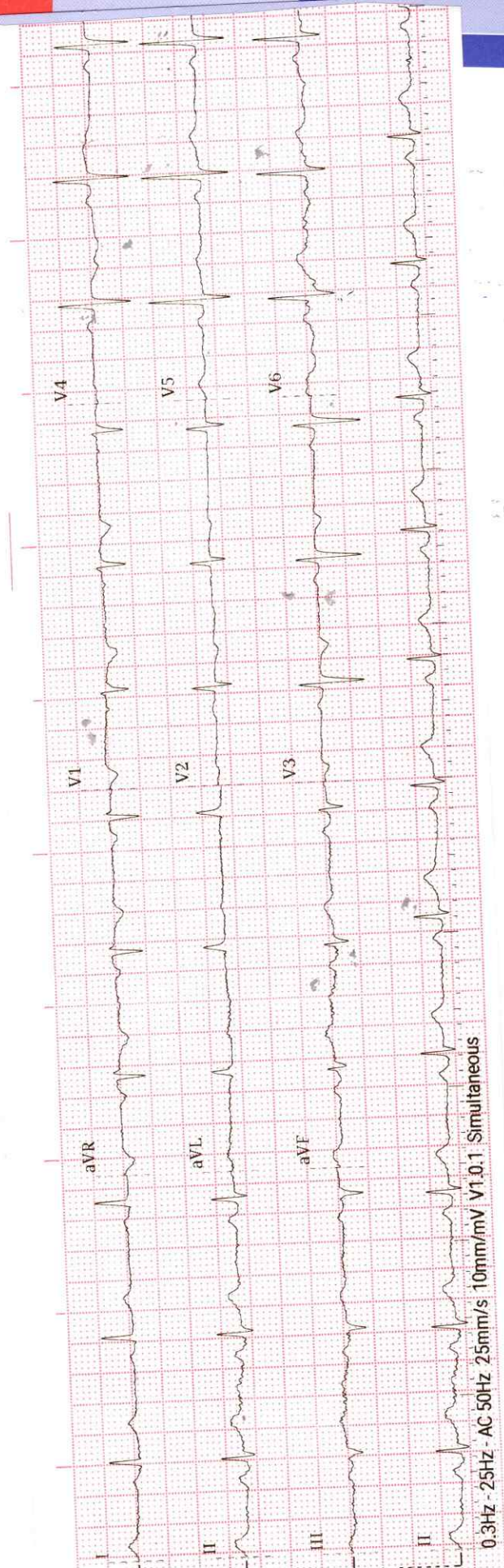
PATIENT MRS JYOTSNA JAYESH DALAL AGE 68 SEX F

REF. BY DR. MEDIWHEEL DATE 10.09.2024

INTERPRETATION: with Normal limits

HEALTHCARE
 MEDICAL CENTRE AND DIAGNOSTICS
 RANG BHAWAN BLDG - MG CROSS RD
 VILE PARLE EAST - MUMBAI-400057
 MOBILE NO. - 87798655778

per done
 DDR. YOGESH J, MEHTA M.D.
 Physician & Cardiologist
 Reg. No. - 71131



Axis : +

P. Waves : N.

PR Interval : H.

Q. Waves : —

QRS Interval : —

ST Segment : N.

T. Waves : H.

QT Interval : —

Extra Systoles : —

History :

B.P. :

Drugs :

Standard : 10 mm

Auricular Rate : 72 / min

Ventricular Rate : 72 / min

Rhythm : regular

Mechanism : Sinus

Voltage : N.

REMARKS & CONCLUSIONS : WNL