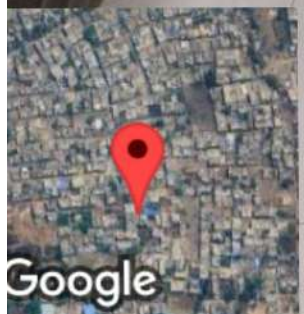


GPS Map Camera



रायपुर, छत्तीसगढ़, भारत  
6J6W+C64, कृष्णा नगर, संतोषी नगर, रायपुर, मथुरेना, छत्तीसगढ़ 492001, भारत  
Lat 21.211079°  
Long 81.64564°  
14/09/24 09:34 AM GMT +05:30

Google



भारत सरकार

Government of India



प्रभा एक्का

PRABHA EKKA

पिता : जुनास तिकी

Father : Junas Tirkey

जन्म तिथि / DOB : 07/12/1965

महिला / Female



7337 9315 4203

आधार - आम आदमी का अधिकार



भारतीय विशिष्ट पहचान प्राधिकरण

Unique Identification Authority of India

पता:

W/O: विलियम एक्का, टी-47/ए,  
सेक्टर १ एक्टेंशन, अवंती विहार, वार्ड  
न-28, तेलीबांधा, रविग्राम, रायपुर,  
छत्तीसगढ़, 492006

Address:

W/O: William Ekka, T-47/A,  
SECTOR 1 EXTENSION, AVANTI  
VIHAR, ward NO-28, Telibandha,  
Ravigram, Raipur, Chhattisgarh,  
492006

7337 9315 4203



1947

1800 300 1947



help@uidai.gov.in

WWW

www.uidai.gov.in



PATIENT NAME .....  
AGE/SEX .....  
REF. BY .....

MRS. EKKA PRABHA  
39 YRS / FEMALE  
BANK OF BARODA

DATE- 14-Sep-24

## **SONOGRAPHY OF THE ABDOMEN + PELVIS**

*PROCEDURE DONE BY ULTRASOUND MACHINE Canon Apilo a450 (4D COLOR DOPPLER)*

- LIVER** : The liver is normal in size, shape & contour with normal echotexture. No evidence of any Focal lesion or mass seen. The intrahepatic biliary ducts are normal. The CBD is normal in course, caliber & contour. Hepatic & portal vein appear normal in morphology.
- GALL BLADDER** : well distended & shows normal wall thickness. No obvious intraluminal calculus.
- PANCREAS** : appears normal in size, shape & echo pattern. Pancreatic duct appears normal.
- SPLEEN** : Spleen is normal size, shape and position. No focal lesion seen.
- KIDNEY** : Right kidney measures ~ 8.9 x 3.9 cm.  
Left kidney measures ~ 9.2 x 3.7 cm.  
Both Kidneys are normal size, shape and position.  
Renal parenchymal echogenicities are normal.  
No evidence of any calculus or pelvicalyceal dilation.
- URINARY BLADDER:** UB is well distended with normal wall thickness. No evidence of mass /calculus.
- UTERUS** : Atrophic.
- RETRO PERITONEUM** : No evidence of lymphadenopathy / mass.
- FREE FLUID** : No free fluid seen in abdomen & peritoneal cavity.

### **IMPRESSION :**

- No significant abnormality detected.

Needs clinical correlation & other investigations.

  
Dr. Hulesh Mandla, MD  
Consultant Radiologist

### **Kindly Note:-**

- The report and films are not valid for medico – legal purpose.
- Please Intimate us if any typing mistakes and send the report for correction within 7 days.
- कृपया अगली बार जांच के लिए आने पर पुराना रिपोर्ट साथ में लावे ।



PATIENT NAME .....  
AGE/SEX .....  
REF. BY .....

MRS. PRABHA EKKA  
39 YRS / FEMALE  
BANK OF BARODA


DATE- 14-Sep-24

## **X-RAY CHEST PA VIEW** **Observation & Impression**

- Bilateral lung fields are clear.
- Both costophrenic angles are normal.
- Bilateral hila are normal.
- The cardiac shadow is normal.
- The bony thorax is normal.

**IMPRESSION** No significant abnormality is seen.

*Needs clinical correlation & other investigations.*

  
Dr. Hulesh Mandle, MD  
Consultant Radiologist  
DR. HULESH MANDLE  
M.P.S., and  
USMC-223104

Investigations have their limitation, solitary radiological / pathological and other investigations never confirm the final diagnosis of disease. They only help in diagnosing the disease in correlation to symptom and other related test please interpret accordingly.

**Note-**

1. The report & film are not valid for medico-legal purpose.
2. Please intimate us if any typing mistakes & send the report for correction within 7 days.

# सभ्यता डेन्टल केयर SABHYATA DENTAL CARE



डॉ. घनश्याम राव सहारे  
बी.डी.एस. (GDC Raipur)  
(दंत रोग विशेषज्ञ)  
मो. 6232195768  
Regd. No. CGDC/12/G/1126

उपलब्ध सुविधाएँ :

दांतों की सफाई

दर्द रहित दांत निकालना

दांतों में मसाला भरना

पायरिया का ईलाज

दांतों के जड़ का ईलाज (RCT)

दांतों के बीच गेप भरना

बच्चों के सड़े दांतों का ईलाज

बत्तीसी बनवाना

फिक्स दांत बनवाना

दांतों में कैप लगवाना

टेढ़े मेढ़े दांतों का ईलाज

मुंह के कैंसर का ईलाज

एक्स-रे सुविधा

आपात एवं दुर्घटना उपचार

Rx Prabha Ikka,

Date 14/9/24,

C/C - pt C/O sensitivity,

O/E - Generalised Attrition,

PDH - RCT  $\bar{}$  35, 36,

PMH - Diabetes Mellitus since 11 years,

Habit - NRH,

O/E - Generalised Attrition

• Ungual caries  $\bar{}$  11, 12,

• proximal caries  $\bar{}$  46.

Ad - Restoration  $\bar{}$  11, 12, 46,

(Rx)

• toothpaste Sensodyne.

• M10 Sensodyne.



तरुण सखी बाजार के पास, पुराना धमतरी रोड, कृष्णा नगर (संतोषी नगर) रायपुर (छ.ग.)



# रामकथा

आँख, कान, नाक, गला एवं मल्टीस्पेशियलिटी हॉस्पिटल  
24 घंटे आपातकालीन चिकित्सा सेवा उपलब्ध

MRS. PRABHA EKTA  
WILKINSON - 5871

Uo Routine ENT  
Check up

Date  
14/09/24

Exam both - dry tympanic membrane normal

Nose both clear

throat clear

Neck - NTH

Clinical ENT - normal

Good

TAT

HWK + W

→ W

to the

Patient:

MRS EKKA PRABHA

58 year / F

..... cm / ..... kg

HR 66/min

Axis: P 39°  
QRS 54°  
T 65°

SINUS RHYTHM

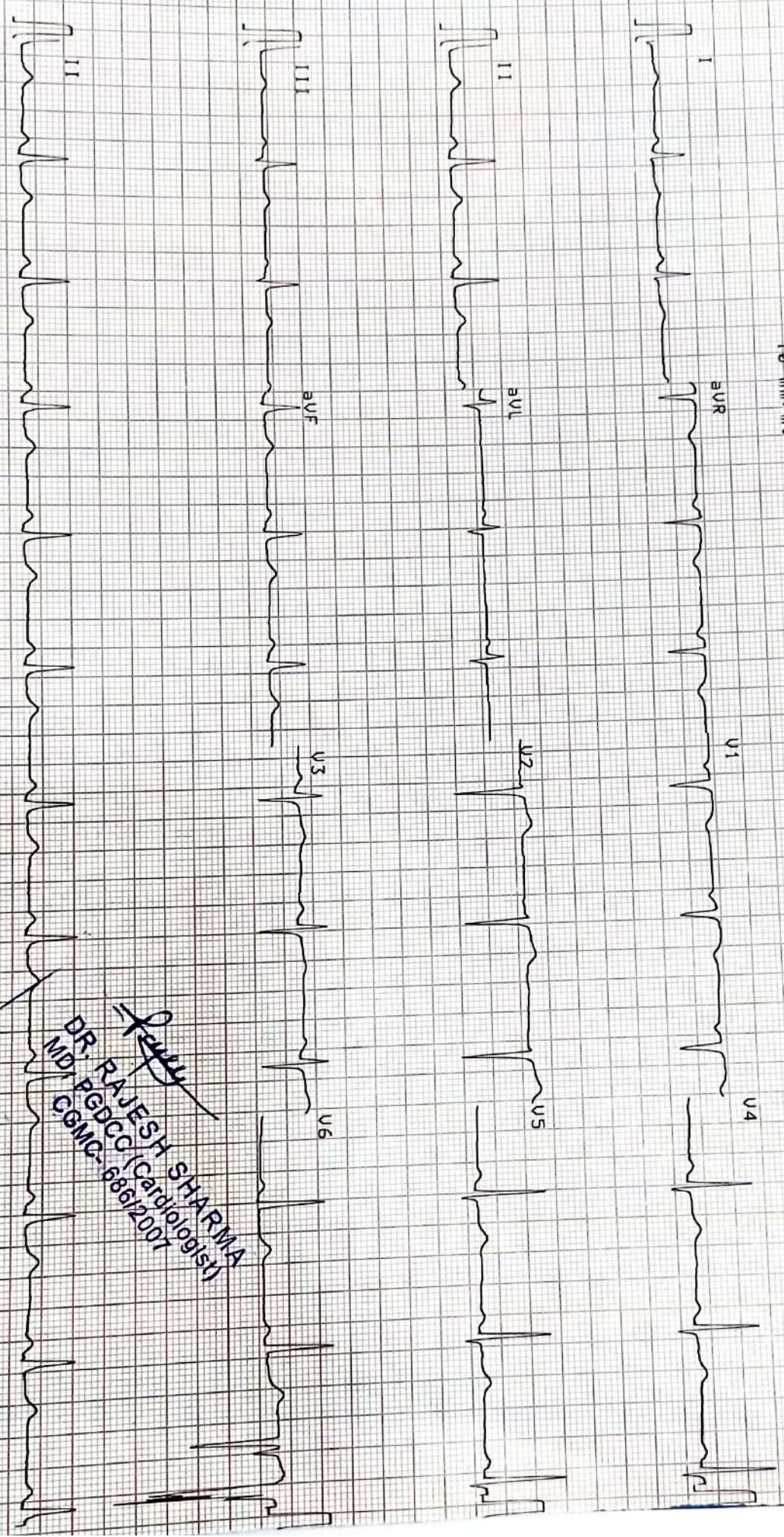
UNCONFIRMED REPORT

Intervals:

RR	906 ms
P	102 ms
PR	144 ms
QRS	76 ms
QT	396 ms
QTc	417 ms

10 mm/mV

10 mm/mV



*[Signature]*  
**DR. RAJESH SHARMA**  
 MD, PGDCC (Cardiologist)  
 CGMC-686/2007

*[Signature]*  
 25/09/2024

25 mm/s

0.05-35Hz F50 SSF 585 Fr 13-SEP-24 21:56:46 RT-2p1u5 4.14 (C) SCHILLER AG RT-2p1u5 4.14





PATIENT NAME .....  
AGE/SEX .....  
REF. BY .....

MRS. PRABHA EKKA  
39 YRS / FEMALE  
BANK OF BARODA

DATE- 14-Sep-24

## COLOUR DOPPLER ECHOCARDIOGRAPHY

PROCEDURES: M-MODE/2D/DOPPLER/COLOUR/CONTRAST.

### MEASUREMENTS:

AO	~	2.7 CMS
LA	~	3.4 CMS.
LVDd	~	4.0 CMS.
LVDs	~	2.3 CMS.
IVSd	~	1.0 CMS.
LVPWd	~	1.0 CMS.

### DOPPLER

E	~	0.7 M/SEC.
A	~	1 M/SEC.
AO	~	1.3 M/SEC.

- NORMAL LV AND RV SIZE AND FUNCTION
- NORMAL PERICARDIUM. NO PERICARDIAL EFFUSION.
- NORMAL PA & AORTA.

### OPINION:-

- ☞ NORMAL CHAMBER SIZE.
- ☞ NO RWMA.
- ☞ GOOD LV SYSTOLIC FUNCTION.
- ☞ EF 60%
- ☞ NO CLOT/MASS

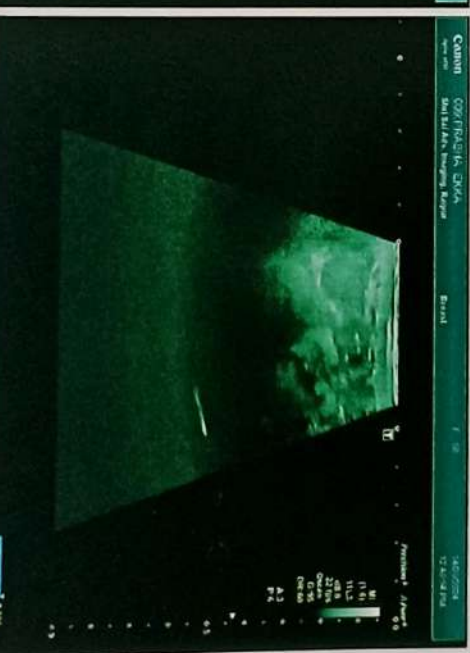
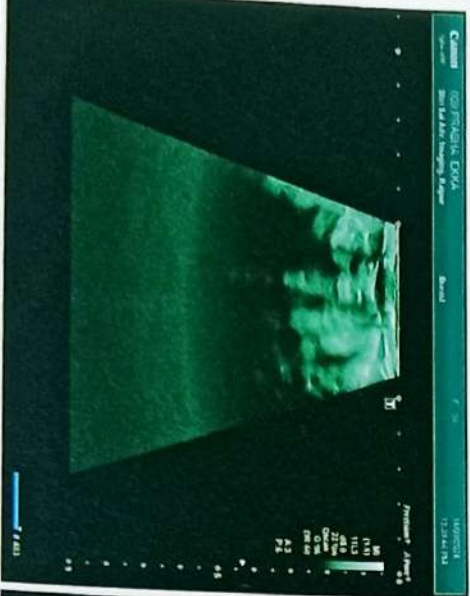
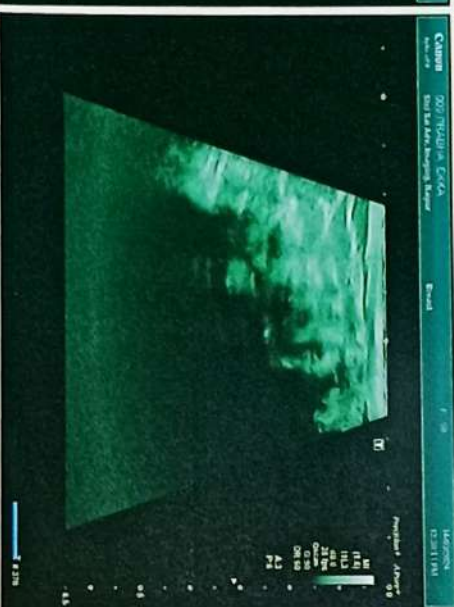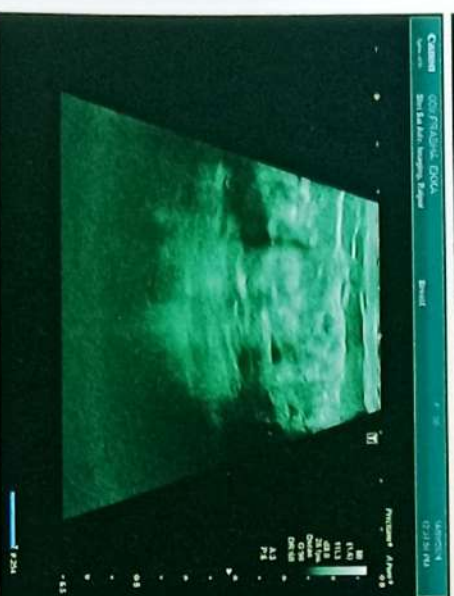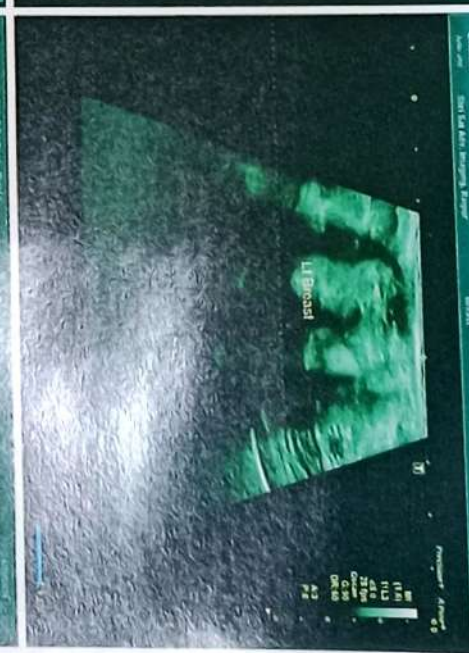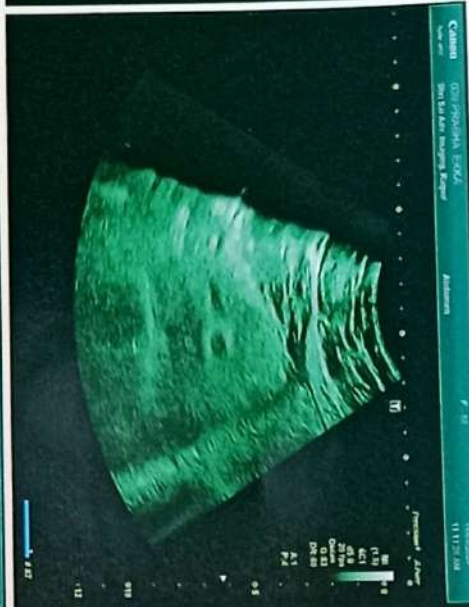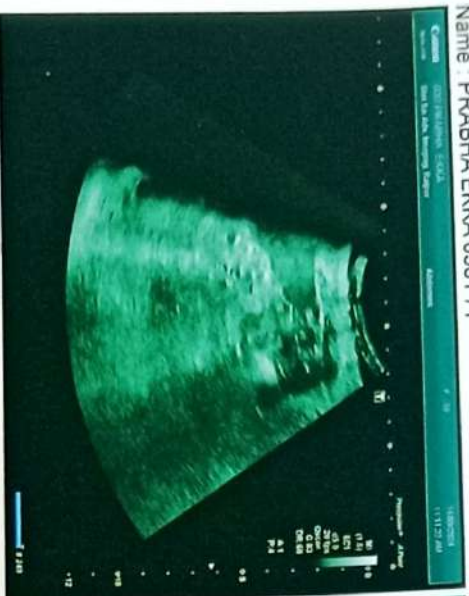DR. SAWAN AGRAWAL  
(MBBS, MD, DNB Cardiology)

Shri Sai's Imaging & Diagnostic Center  
Address - Near Advance Market, Krishna Nagar,  
Rajghar, Santoshi Nagar,  
Raipur (C.G.) - 492001

Investigations have their limitation, solitary radiological / pathological and other investigations never confirm the final diagnosis of disease. They only help in diagnosing the disease in correlation to symptom and other related test please interpret accordingly.

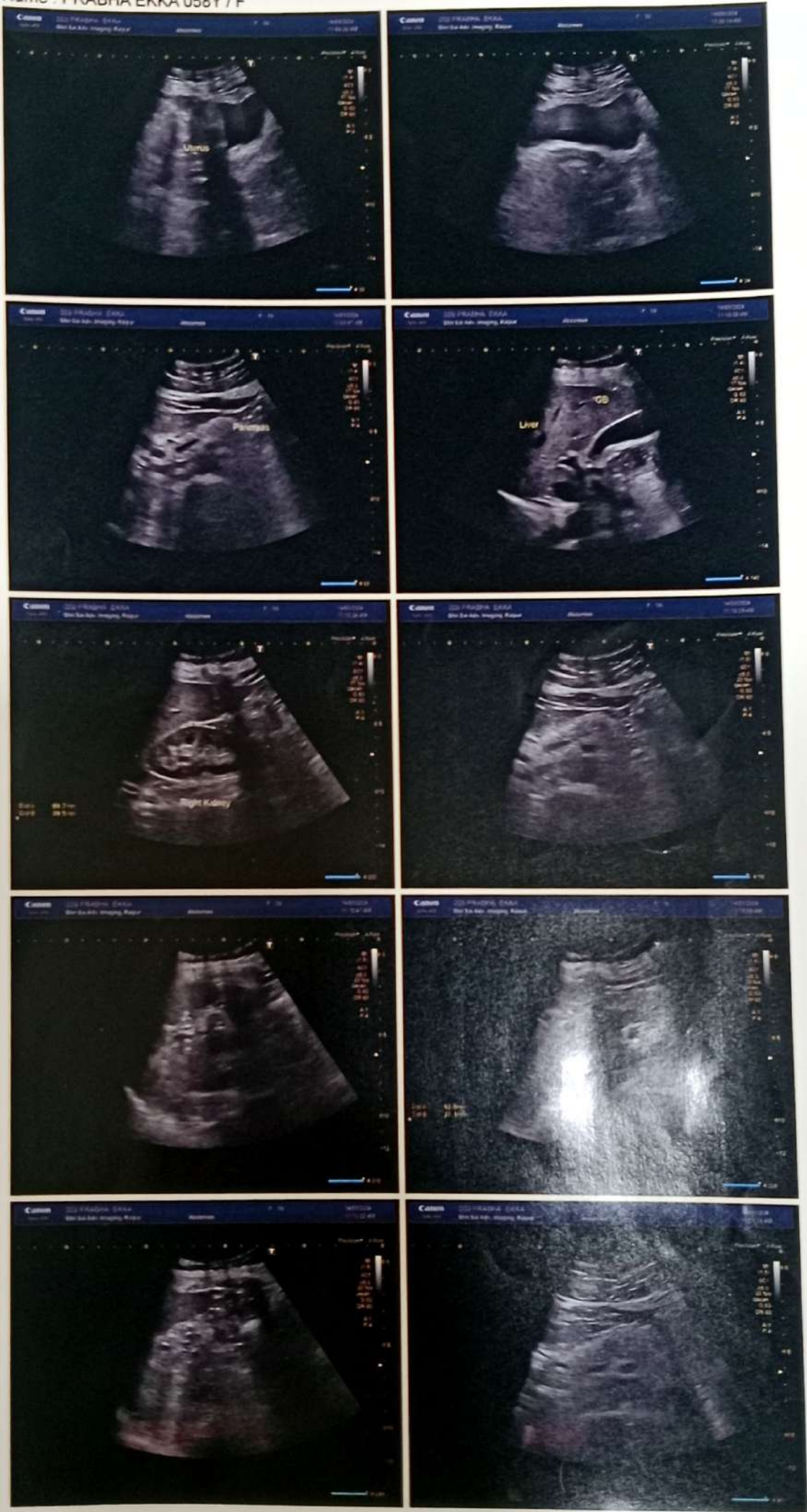# SHRI SAI ADVANCE IMAGING & DAIGNOSTIC CENTER, SANTOSHI NAGAR

14 Sep 2024 Study : Abdomen  
 Name : PRABHA EKA 058Y / F



# SHRI SAI ADVANCE IMAGING & DAIGNOSTIC CENTER, SANTOSHI NAGA R

14 Sep 2024 Study : Abdomen  
Name : PRABHA EKKA 058Y / F





A Unit of Diagnostic Care with Trust

# श्री साई एडवांस इमेजिंग एंड डायग्नोस्टिक सेंटर

PVT.LTD.

MRI | CT Scan | 4D Color USG | Digital X-Ray | Advance Pathology | 2D Echo / E.C.G. / TMT / E.E.G. / OPG / SPIRO

हर जीवन  अमूल्य है

पुराना धमतरी रोड, सब्जी बाजार के सामने,  
संतोषी नगर, रायपुर (छ.ग.) ☎ 0771-4023900

PATIENT NAME

AGE/SEX

REF. BY

.....

.....

.....

MRS. PRABHA EKKA

58 YRS / FEMALE

BANK OF BARODA

DATE- 14-Sep-24

## USG OF BOTH BREASTS

- Illdefined heterogenous lesion size ~ 3.4 x 2.3 cm noted at right breast retro-areolar aspect with size & moderate perilesional soft tissue inflammation
- Rest of the breasts parenchyma appears normal in echotexture.
- Ductal system otherwise appears normal.
- Skin and subcutaneous tissue appears normal.
- Right enlarged axillary lymph nodes noted, largest size ~ 19.5 x 9.4 mm.
- Left axillae is clear.

## IMPRESSION:

- ✂ Right enlarged axillary lymph nodes noted.
- ✂ Illdefined heterogenous lesion noted at right breast retro-areolar aspect with size & moderate perilesional soft tissue inflammation. -? CA breast. (BIRADS-IVb).

## Advice - Histopathological correlation

*Needs clinical correlation & other investigations.*



Dr. Hulesh Mandale, MD  
Consultant Radiologist

**DR. HULESH MANDE**  
CGMC-2012/04

*Investigations have their limitation, solitary radiological / pathological and other investigations never confirm the final diagnosis of disease. They only help in diagnosing the disease in correlation to symptom and other related test please interpret accordingly.*

### Kindly Note:-

- The report and films are not valid for medico - legal purpose.
- Please Intimate us if any typing mistakes and send the report for correction within 7 days.

सही जाँच ही सही इलाज का आधार है.

Email : shrisaiimaging@gmail.com, Website : www.shrisaidiagnostic.com

MRD No **DJE10820**

Patient : MRS.PRABHA EKKA / female / 58Yr(s)

Address: AVANTI VIHAR

Contact Number : 9406122518

Date : 14-09-2024 03:05 PM

Presenting Complaint: Left Eye-WATERING Since 6 Month(s)

Medical History: DIABETES 3 YRS.  
HYPERTENSION 3 YRS.  
BRAIN RELATED PROBLEM 10 YRS.

Eye	Distance vision			Near vision	
	UCDVA	BCDVA	PH	UCNVA	BCNVA
Right	6/9				
Left	6/9				

IOP:
DateTime: 14-09-2024 02:58 PM
NCT
15
17

Prescription  
Spectacle Correction:

	Right Eye				Left Eye			
	SPH	CYL	AXIS	V/A	SPH	CYL	AXIS	V/A
D.V		-0.50	80	6/6		-0.50	50	6/6
N.V	2.5	-0.50	80	N6	2.5	-0.50	50	N6
Add	2.5				2.5			

Examination:

Eye Parts	Right Eye	Left Eye
CORNEA	CLEAR	CLEAR
LENS	SIMC	SIMC
FUNDUS	CD - 0.7	CD - 0.7

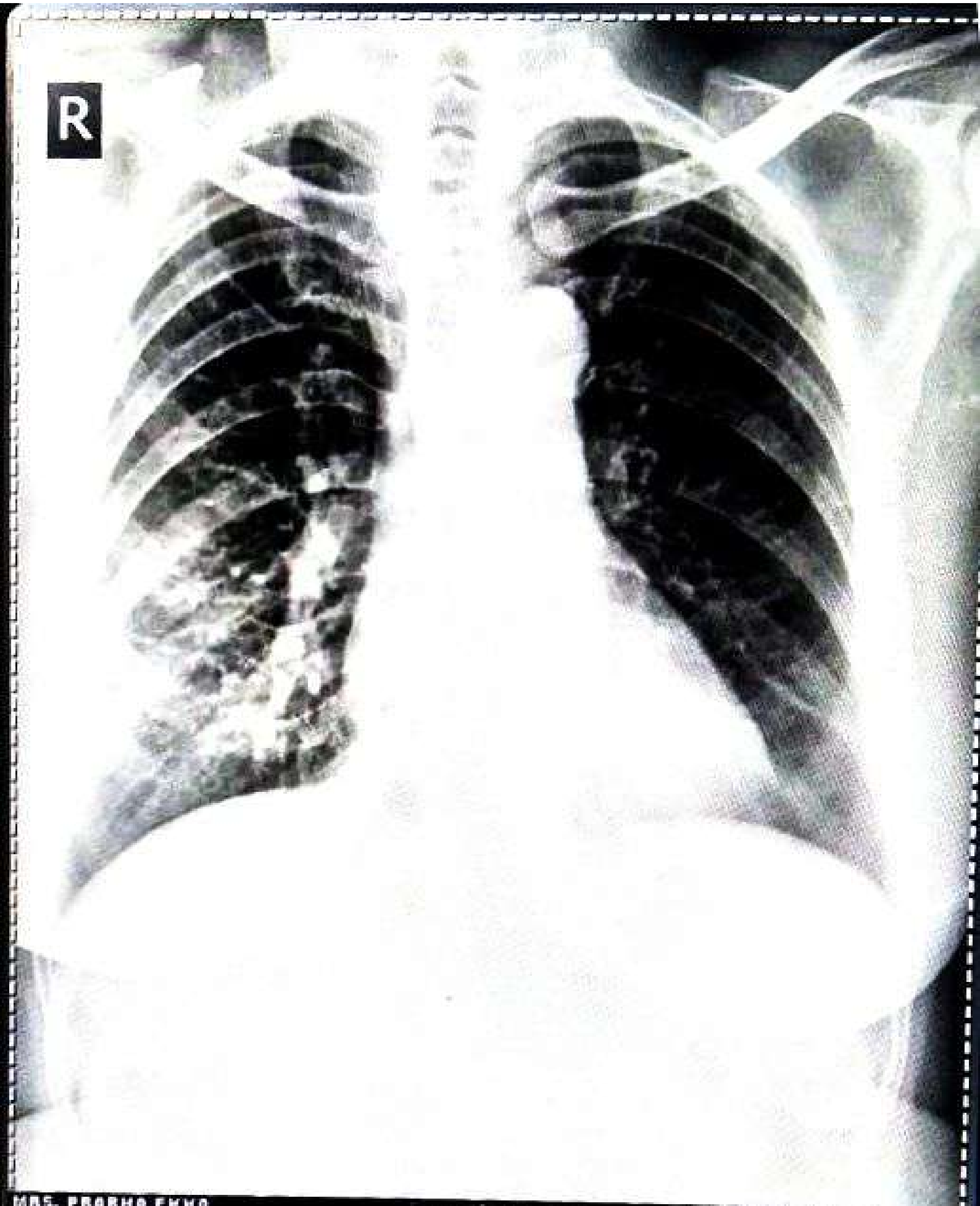
Diagnosis:

**Both Eyes-REFRACTIVE ERROR**

*adh*  
*Dr Dinesh*  
*24/9/24*

*Ds*  
DR DINESH (CGMC/862/2007)

R



MRS. PRABHA EKKA  
MEDIMHEEL  
SHRI SAI ADVANCE IMAGING & DIAGNOSTIC CENTER

EMPAK 50 WARDHARI

14/09/2024 10:16:24