

MER- MEDICAL EXAMINATION REPORT

Date of Examination	23/12/23		
NAME	JAYENDRA SINGH		
AGE	51	Gender	M
HEIGHT(cm)	163	WEIGHT (kg)	72 BMI- 27.1
B.P.	130/82		
ECG	normal		
X Ray	normal		
Vision Checkup	-		
Present Ailments	None		
Details of Past ailments (If Any)	No		
Comments / Advice : She /He is Physically Fit	MEDICALLY FIT		



Signature with Stamp of Medical Examiner  
 Dr. Simra Rastogi  
 MBBS, DCP  
 Reg. No. 37370






**भारत सरकार**  
**Unique Identification Authority of India**  
 भारत सरकार का आधिकारिक अंग

सामाजिक इकाई / Enrollment No 1093/43007/00472

To:  
 जेन्द्रा सिंह  
 Jendra Singh  
 S/O Thakur Prasad Singh  
 18/23  
 police awas nigam office ke piche vibhuti khurd  
 Gomtinagar  
 Lucknow  
 Uttar Pradesh 226010  
 9450140381

Ref: 185 / 18C / 143564 / 143878 / P



UE187286372IN



आपका आधार क्रमांक / Your Aadhaar No. :

**2228 2087 5116**

**आधार - आम आदमी का अधिकार**



**भारत सरकार**  
 भारत सरकार का आधिकारिक अंग



जिन्द्रा सिंह  
 Jendra Singh  
 जन्म वर्ष / Year of Birth : 1972  
 लिंग / Male



**2228 2087 5116**

**आधार - आम आदमी का अधिकार**

*Handwritten signature*



Dear sir

You have been informed that ent opthal ,diet consultation facility is not available at our centre.

If you are ready then your test can be start.

2D echo test facility is not available at our centre instead we do TMT test .





# MODERN PATHOLOGY & DIAGNOSTIC CENTRE

Dr. R. P. Rastogi  
M.B.B.S., M.D. (Path & Bact)



**CLINIC :**  
1/4A, Vineet Khand, (Opp Jaipuria Management)  
Gomti Nagar, Lucknow - 226 010  
Ph : 0522-4008184, 4308184 • 8112323230  
Mob : 7618884441, 9450389932, 8177063877

Date	: 23-Dec-2023		
Name	: <b>Mr. JITENDRA SINGH</b>	Age	: 51 Yrs.
Ref.By	: APOLLO HEALTH	Sex	: Male

Haemoglobin	15.0	gm%	14 - 17
-------------	------	-----	---------

Total Leucocyte Count	5400	Cells/cumm.	4000-11000
-----------------------	------	-------------	------------

Differential Leucocyte Count			
Polymorphs	70	%	45 - 70
Lymphocytes	22	%	20 - 45
Eosinophils	04	%	0 - 6
Monocytes	04	%	0 - 8
Basophils	00	%	0 - 1

Erythrocyte Sedimentation Rate (Wintrobe)			
ESR	06	mm in 1st Hr.	0 - 9
PCV	45.8	cc%	40 - 52
Corrected ESR	00	mm in 1st Hr.	0 - 9

Platelet Count	1.10	lakh/cumm.	1.5 - 4.0
----------------	------	------------	-----------

Red Cells Count	5.04	million/cmm	3.90 to 5.80
-----------------	------	-------------	--------------

Absolute values			
MCV	90.9	fL	77 - 97
MCH	29.7	pg	27 - 31
MCHC	32.7	gm /dl	31 - 34

Dr. Sanjay Rastogi  
Page 11 End Of Report  
M.B.B.S., DCP, CRIAT (BARC)

  
Dr. Smita Rastogi  
M.B.B.S., DCP

Results, adhering to W.H.O. and International Federation of Clinical Chemists Quality Control Standards.

SAMPLE COLLECTION FACILITY AVAILABLE

Report needs clinicopathological correlation ♦ Not for Medico Legal Purpose

e-mail : mpdcgn@gmail.com ♦ For online reports - www.modernpath.in

♦ Please ask for your computerized bill ♦ Pay only the printed collection charges



# MODERN PATHOLOGY & DIAGNOSTIC CENTRE

Dr. R. P. Rastogi  
M.B.B.S., M.D. (Path & Bact)



CLINIC :  
1/4A, Vineet Khand, (Opp Jaipuria Management)  
Gomti Nagar, Lucknow - 226 010  
Ph.: 0522-4008184, 4308184 • 8112323230  
Mob.: 7618884441, 9450389932, 8177063877

Date	: 23-Dec-2023	Age	: 51 Yrs.
Name	: Mr. JITENDRA SINGH	Sex	: Male
Ref.By	: APOLLO HEALTH		

## General Blood Picture

RBCs	RBCs are Normocytic & Normochromic. No Normoblasts are seen.
WBCs	TLC is within normal range. DLC shows normal counts. No immature cells of WBC seen.
PLATELETS	Platelets are reduced in number and morphology.
OTHERS	No haemoparasites are seen.
IMPRESSION	THROMBOCYTOPENIA

Dr. Sanjay Rastogi  
M.B.B.S., DCP, CRAT (BARC)

Dr. Smita Rastogi  
M.B.B.S., DCP

Results, adhering to W.H.O. and International Federation of Clinical Chemists Quality Control Standards.

SAMPLE COLLECTION FACILITY AVAILABLE

Report needs clinicopathological correlation ♦ Not for Medico Legal Purpose

e-mail : mpdcgn@gmail.com ♦ For online reports - www.modernpath.in

♦ Please ask for your computerized bill ♦ Pay only the printed collection charges



# MODERN PATHOLOGY & DIAGNOSTIC CENTRE

Dr. R. P. Rastogi  
M.B.B.S., M.D. (Path & Bact)



**CLINIC :**  
1/4A, Vineet Khand, (Opp Jaipuria Management)  
Gomti Nagar, Lucknow - 226 010  
Ph : 0522-4008184, 4308184 • 8112323230  
Mob : 7618884441, 9450389932, 8177063877

Date	: 23-Dec-2023		
Name	: <b>Mr. JITENDRA SINGH</b>	Age	: 51 Yrs.
Ref.By	: APOLLO HEALTH	Sex	: Male
SGOT	41	IU/L	UPTO 50
Blood Group & Rh	46		
Serum Urea	18.2	mg %	15 - 50
Serum Creatinine	1.14	mg%	0.5 - 1.5
Plasma Glucose - F GOD-POD Method	98	mg/dl	70 - 110
Plasma Glucose - PP GOD POD Method	142	mg/dl	110 - 170
Serum Uric Acid	5.3	mg%	2.0 - 7.0
SGPT	45	IU/L	Upto 50
Serum Bilirubin	0.49	mg%	0.2 - 1.0

**Dr. Sanjay Rastogi**  
M.B.B.S., DCP, CRIAT (BARC)

**Dr. Smita Rastogi**  
Contd... M.B.B.S., DCP

Results, adhering to W.H.O. and International Federation of Clinical Chemists Quality Control Standards.

SAMPLE COLLECTION FACILITY AVAILABLE

Report needs clinicopathological correlation ♦ Not for Medico Legal Purpose

e-mail : [mpdcgn@gmail.com](mailto:mpdcgn@gmail.com) ♦ For online reports - [www.modernpath.in](http://www.modernpath.in)

♦ Please ask for your computerized bill ♦ Pay only the printed collection charges

**CLINIC :**

1/4A, Vineet Khand, (Opp Jaipuria Management)  
Gomti Nagar, Lucknow - 226 010  
Ph.: 0522-4008184, 4308184 • 8112323230  
Mob.: 7618884441, 9450389932, 8177063877

Date : 23-Dec-2023  
Name : **Mr. JITENDRA SINGH**  
Ref.By : APOLLO HEALTH  
Age : 51 Yrs.  
Sex : Male

**LIPID PROFILE**

Triglycerids	96	mg%	70 - 190
S. Cholestrol S.	187	mg%	130 - 230
S. HDL Cholestrol	44.0	mg%	35 - 75
S. LDL Cholestrol	123.8	mg%	75 - 150
VLDL	19.2	mg%	0 - 34
Chol / HDL factor	4.25		
LDL / HDL Factor	2.81		

**COMMENTS**

\* Triglycerides (TG) are the main dietary lipids. Cholesterol constitutes a small part of the dietary lipids, it is mostly synthesised in the liver. Both TG and Chol. are transported through the plasma by lipoproteins (Chylomicrons, VLDL, LDL, IDL, HDL).  
\* LDL is the major cholesterol particle in plasma and high levels are strongly implicated in the formation of atheroma. An increase in the LDL leads to hypercholesterolemia, and therefore a risk factor for IHD. LDL increases with age particularly in females. Oestrogen lower LDL and raise HDL. Raised chol. in females is mostly due to disturbed thyroid function.  
\* Increase in VLDL leads to hyperglyceridaemia. Raised TGs are associated with increased risk of CHD. Very high TGs increase the risk of Pancreatitis. Cholesterol is often raised due to Diabetes, Renal disease, Diuretic or Betablocker therapy.

**TYPES OF HYPERLIPOPROTEINEMIAS**

TYPE 1: Normal cholesterol TG greatly raised	TYPE 3: Cholesterol increased TG increased
TYPE 2a: Cholesterol increased LDL increased TG normal	TYPE 4: Cholesterol normal /increased VLDL increased TG increased
TYPE 2b Chol. increased VLDL raised TG increased LDL increased	TYPE 5: Cholesterol increased LDL reduced VLDL increased TG greatly increased

Dr. Sanjay Rastogi  
M.B.B.S., DCP, CRIAT (BARC)

Dr. Smita Rastogi  
Contd... M.B.B.S., DCP

Results, adhering to W.H.O. and International Federation of Clinical Chemists Quality Control Standards.

SAMPLE COLLECTION FACILITY AVAILABLE

Report needs clinicopathological correlation ♦ Not for Medico Legal Purpose

e-mail : mpdcgn@gmail.com ♦ For online reports - www.modernpath.in

♦ Please ask for your computerized bill ♦ Pay only the printed collection charges



# MODERN PATHOLOGY & DIAGNOSTIC CENTRE

Dr. R. P. Rastogi  
M.B.B.S., M.D. (Path & Bact)



## CLINIC :

1/4A, Vineet Khand, (Opp Jaipuria Management)  
Gomti Nagar, Lucknow - 226 010  
Ph : 0522-4008184, 4308184 • 8112323230  
Mob : 7618884441, 9450389932, 8177063877

Date	: 23-Dec-2023	Age	: 51 Yrs.
Name	: Mr. JITENDRA SINGH	Sex	: Male
Ref.By	: APOLLO HEALTH		

## Urine Examination

<b>PHYSICAL</b>		
Colour	Straw	
Turbidity	Nil	
Deposit	Nil	
Reaction	Acidic	
*Specific Gravity	1.030	
<b>CHEMICAL</b>		
Protein	Nil	
Sugar	Nil	
*Bile Salts	Nil	
*Bile Pigments	Nil	
Phosphate	Nil	
<b>MICROSCOPIC</b>		
Pus Cells	Nil	/hpf
Epithelial Cells	Occasional	/hpf
Red Blood Cells	Nil	/hpf
Casts	Nil	
Crystals	Nil	
Others	Nil	

Dr. Sanjay Rastogi  
M.B.B.S., DCP, CRIAT (BARC)

Dr. Smita Rastogi  
M.B.B.S., DCP

Results, adhering to W.H.O. and International Federation of Clinical Chemists Quality Control Standards.

SAMPLE COLLECTION FACILITY AVAILABLE

Report needs clinicopathological correlation ♦ Not for Medico Legal Purpose

e-mail : mpdcgn@gmail.com ♦ For online reports - [www.modernpath.in](http://www.modernpath.in)

♦ Please ask for your computerized bill ♦ Pay only the printed collection charges





# MODERN PATHOLOGY & DIAGNOSTIC CENTRE

Dr. R. P. Rastogi  
M.B.B.S., M.D. (Path & Bact)



CLINIC :  
1/4A, Vineet Khand, (Opp Jaipuria Management)  
Gomti Nagar, Lucknow - 226 010  
Ph.: 0522-4008184, 4308184 • 8112323230  
Mob.: 7618884441, 9450389932, 8177063877



TEST REQUEST ID :012312230025	SAMPLE DATE	:23/Dec/2023 09:38AM
NAME :Mr. JITENDRA SINGH	SAMPLE REC. DATE	:23/Dec/2023 09:38AM
AGE/SEX :51 YRS/MALE	REPORTED DATE	:23/Dec/2023 12:18PM
REFERRED BY : Apollo Health and Lifestyle Limited.	BARCODE NO	:01230025

## USG WHOLE ABDOMEN-MALE

**Liver:** is normal in size (144 mm). **Parenchymal echogenicity is increased.** No focal echovariant lesion is seen. Intrahepatic biliary radicles are not dilated.

**Gall Bladder:** is not seen (operated).

**CBD:** is normal in diameter 6.4 mm. Portal vein is normal in diameter.

**Pancreas:** is normal in size, shape and echotexture. No focal echovariant lesion is seen. Pancreatic duct is not dilated.

**Spleen:** is normal in size (114 mm), shape and echotexture. No focal echovariant lesion is seen. Splenic vein is normal.

**Both Kidneys:** are normal in size (RK- 105 x 44 mm & LK -119 x 48 mm), shape, position and excursion. Parenchymal echogenicity and echotexture is normal with maintained corticomedullary differentiation. No mass, cyst or calculi is seen. Pelvicalyceal systems are not dilated. Ureters are not dilated.

**Urinary bladder:** is well distended. Lumen is anechoic. Wall is of normal thickness. No mass or calculus is seen.

**Prostate:** is enlarged in size (39 x 38 x 34 mms, wt = 27.4 gms), with normal shape and echotexture. No focal echovariant lesion is seen. Prostatic capsule appears to be intact. Median lobe is not projecting in UB lumen. Both seminal vesicles appear normal.

Both iliac fossae are clear. No obvious bowel pathology is noted.  
There is no free fluid in peritoneal cavity.

**OPINION:** - GRADE-I FATTY LIVER  
- GRADE-I BPH

\*\*\* End Of Report \*\*\*

Dr. Sanjay Rastogi  
M.B.B.S., DCP, CRIAT (BARC)

DR. PANKAJ UPADHYAYA

Dr. Smita Rastogi  
M.B.B.S., DCP

Results adhering to W.H.O. and International Federation of Clinical Chemists Quality Control Standards.

SAMPLE COLLECTION FACILITY AVAILABLE

Report needs clinicopathological correlation ♦ Not for Medico Legal Purpose

e-mail : mpdcgn@gmail.com ♦ For online reports - www.modernpath.in

♦ Please ask for your computerized bill ♦ Pay only the printed collection charges





# MODERN PATHOLOGY & DIAGNOSTIC CENTRE

Dr. R. P. Rastogi  
M.B.B.S., M.D. (Path & Bact)



CLINIC :  
1/4A, Vineet Khand, (Opp Jaipuria Management)  
Gomti Nagar, Lucknow - 226 010  
Ph.: 0522-4008184, 4308184 • 8112323230  
Mob.: 7618884441, 9450389932, 8177063877



TEST REQUEST ID :012312230025	SAMPLE DATE	:23/Dec/2023 09:38AM
NAME :Mr. JITENDRA SINGH	SAMPLE REC. DATE	:23/Dec/2023 09:38AM
AGE/SEX :51 YRS/MALE	REPORTED DATE	:23/Dec/2023 12:34PM
REFERRED BY : Apollo Health and Lifestyle Limited,	BARCODE NO	:01230025

## XRAY CHEST PA

- Trachea is central in position.
- Bilateral lung fields are normally aerated.
- Both hilar shadows are normal.
- Both C.P. angles are clear.
- Cardiac shadow is within normal limits.
- Bony cage appears normal.

## OPINION: NORMAL STUDY.

Please correlate clinically.

\*\*\* End Of Report \*\*\*

Dr. Sanjay Rastogi  
M.B.B.S., DCP, CRIAT (BARC)

DR. PANKAJ UPADHYAYA

Dr. Smita Rastogi  
M.B.B.S., DCP

Results, adhering to W.H.O. and International Federation of Clinical Chemists Quality Control Standards.

SAMPLES SENT TO OTHER LABORATORIES FOR SPECIALTY AVAILABLE

Report needs clinicopathological correlation ♦ Not for Medico Legal Purpose

Print Date/Time: 23/12/2023 5:26 PM email : mpdcgn@gmail.com ♦ For online reports - www.modernpath.in

♦ Please ask for your computerized bill ♦ Pay only the printed collection charges



# MODERN PATHOLOGY & DIAGNOSTIC CENTRE

Dr. R. P. Rastogi  
M.B.B.S., M.D. (Path & Bact)



**CLINIC :**

1/4A, Vineet Khand, (Opp Jaipuria Management)  
Gomti Nagar, Lucknow - 226 010  
Ph. : 0522-4008184, 4308184 • 8112323230  
Mob. : 7618884441, 9450389932, 8177063877

Patient name: Mr Jitendra Singh  
Ref By. Apollo Health

Age/Sex 51/M  
23/12/2023

## E.C.G. REPORT

1. Rhythm	:	Sinus, Regular
2. Atrial Rate	:	78/mt
3. Ventricular Rate	:	78/mt
4. P – Wave	:	Normal
5. P R Interval	:	Normal
6. Q R S	:	
Axis	:	Normal
R/S Ratio	:	Normal
Configuration	:	Normal
7. Q T c Interval	:	Normal
8. S-T Segment	:	Normal
9. T-Wave	:	Normal

## FINAL IMPRESSION

**E.C.G. is within normal limits.**

  
Signature of Doctor  
Reg No. 4559

**Dr. Sanjay Rastogi**  
M.B.B.S., DCP, CRIAT (BARC)

**Dr. Smita Rastogi**  
M.B.B.S., DCP

Results, adhering to W.H.O. and International Federation of Clinical Chemists Quality Control Standards.

SAMPLE COLLECTION FACILITY AVAILABLE

Report needs clinicopathological correlation ♦ Not for Medico Legal Purpose

e-mail : [mpdcgn@gmail.com](mailto:mpdcgn@gmail.com) ♦ For online reports - [www.modernpath.in](http://www.modernpath.in)

♦ Please ask for your computerized bill ♦ Pay only the printed collection charges

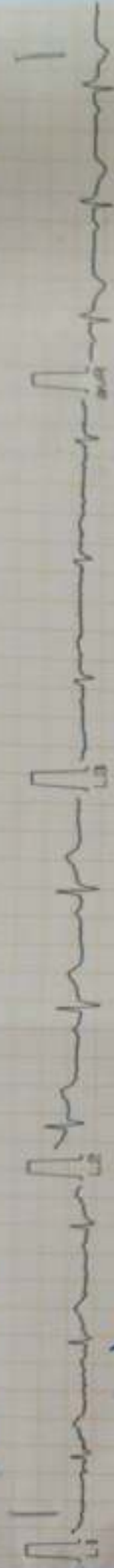Name Hendrix Sparks

Age \_\_\_\_\_ Yrs M/F

10mm/mV

25mm/s

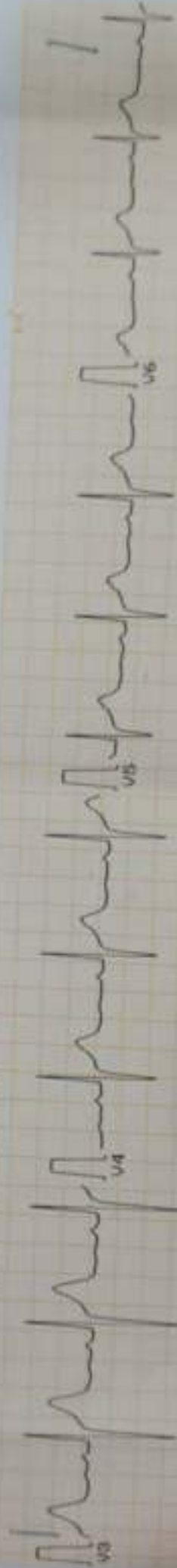
0.1-35 Hz BLC



*Handwritten signature*

Classified ECGS-101

Dr:



Dr. AMT *Signature*  
MD  
Reg. No. 44550

# MODERN PATHOLOGY AND DIAGNOSTIC CENTER

Gomti Nagar Lucknow

Report



JITENDRA SINGH / 51 Yrs / M / 163 Cms / 72 Kg

Date: 23 - 12 - 2023 Refd By : APOLLO HEALTH Examined By:

Stage	Time	Duration	Speed(Kmph)	Elevation	METs	Rate	% THR	BP	RPP	PVC	Comments
Supine	00:03	0:03	00.0	00.0	01.0	086	51 %	130/82	111	00	
Standing	00:07	0:04	00.0	00.0	01.0	086	51 %	130/82	111	00	
HV	00:11	0:04	00.0	00.0	01.0	086	51 %	130/82	111	00	
ExStart	00:30	0:19	00.0	00.0	01.0	086	51 %	130/82	111	00	
BRUCE Stage 1	03:30	3:00	02.7	10.0	04.7	118	70 %	130/82	153	00	
BRUCE Stage 2	06:30	3:00	04.0	12.0	07.1	134	79 %	136/90	182	00	
PeakEx	07:34	1:04	05.5	14.0	08.2	150	89 %	146/98	219	00	
Recovery	08:34	1:00	00.0	00.0	01.1	125	74 %	144/96	180	00	
Recovery	09:34	2:00	00.0	00.0	01.0	110	65 %	140/92	154	00	
Recovery	10:34	3:00	00.0	00.0	01.0	107	63 %	136/86	145	00	
Recovery	10:39	3:04	00.0	00.0	01.0	108	64 %	136/86	146	00	


## FINDINGS :

Exercise Time : 07:04  
 Max HR Attained : 150 bpm 89% of Target 169  
 Max BP Attained : 146/98 (mm/Hg)  
 Max WorkLoad Attained : 8.2 Fair response to induced stress  
 Test End Reasons : Test Complete

## REPORT :

### CONCLUSIONS:

1. STRESS TEST IS NEGATIVE FOR EXERCISE INDUCED ISCHAEMIC HEART DISEASE.

  
 DR. AMIT MOHAN  
 MID  
 Reg. No. 44553

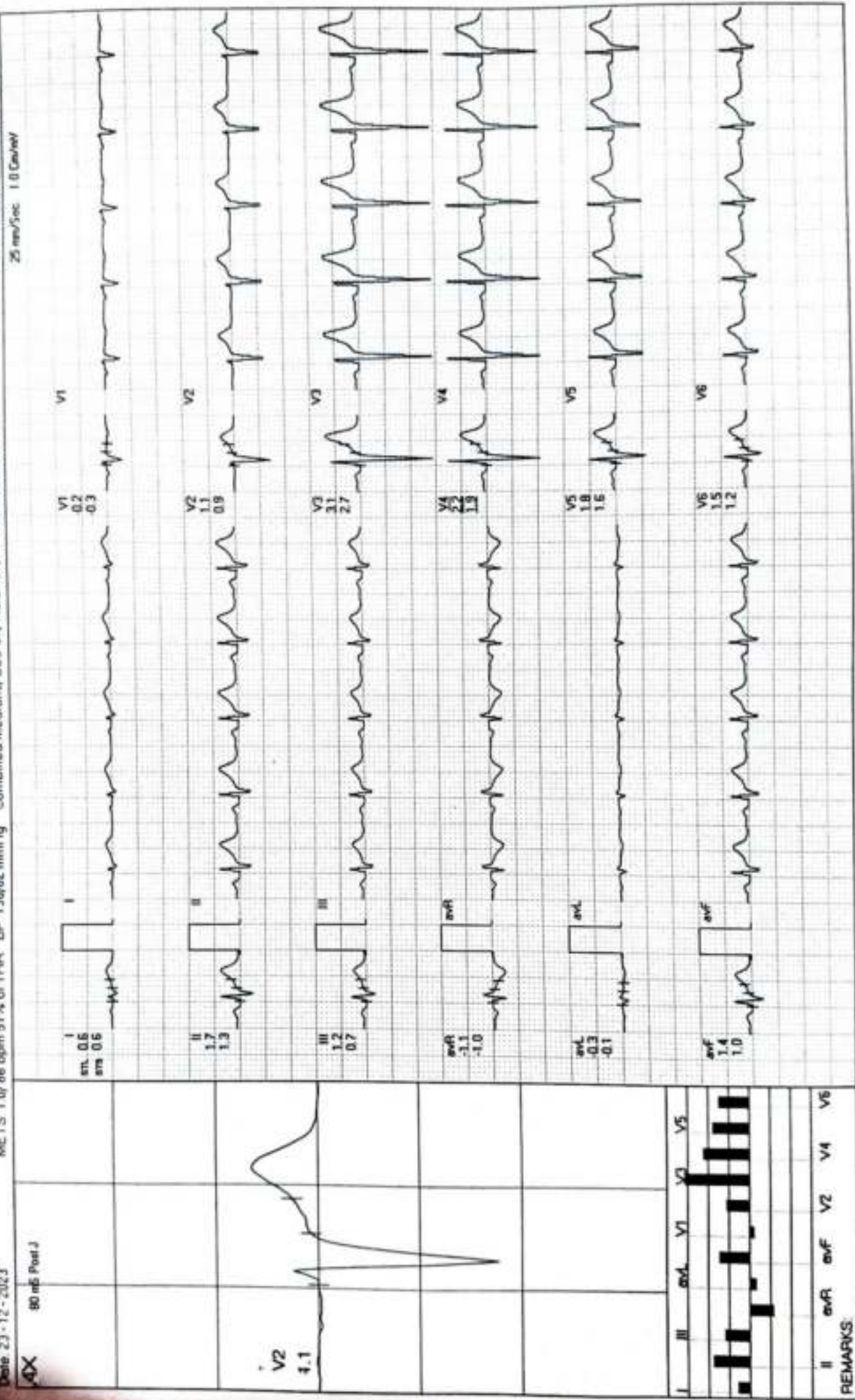
MODERN PATHOLOGY AND DIAGNOSTIC CENTER

BRUCE:Supine(0:06)



JITENDRA SINGH / 51 Yrs / M / 163 Cms / 72 Kg / HR : 86

Date: 23-12-2023 METS: 1.0/86 bpm 51% of THR BP: 130/82 mmHg Combined Medians/BLC On/Notch On/HF 0.05 Hz/LF 35 Hz



REMARKS:

**MODERN PATHOLOGY AND DIAGNOSTIC CENTER**

**BRUCE: Standing(0:05)**


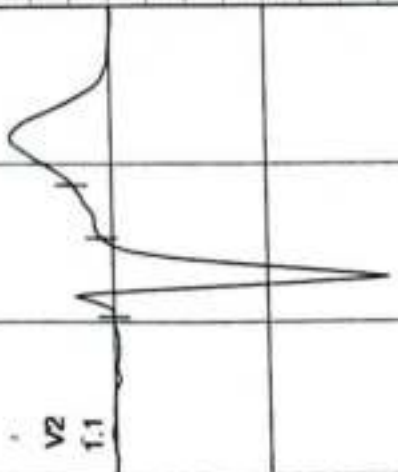
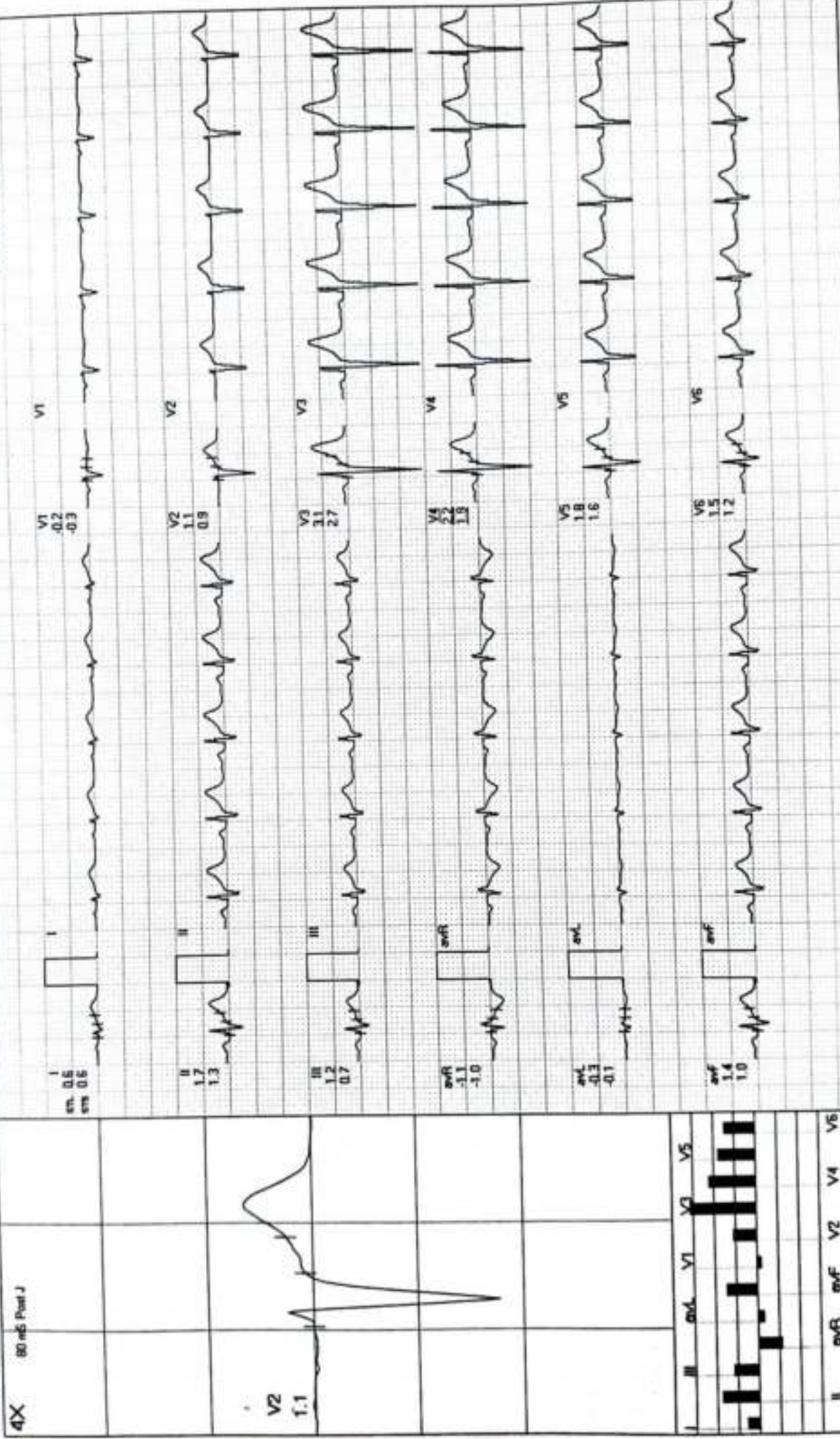


JITENDRA SINGH / 51 Yrs / M / 163 Cms / 72 Kg / HR : 86

ExTime: 00:00 0.0 Km/pt. 0.0%

METS: 1.0/ 86 bpm 51% of THR BP: 130/82 mmHg Combined Medians/BLC On/ HF 0.05 Hz/LF 35 Hz

25 mm/Sec. 1.0 Cm/mV



REMARKS:





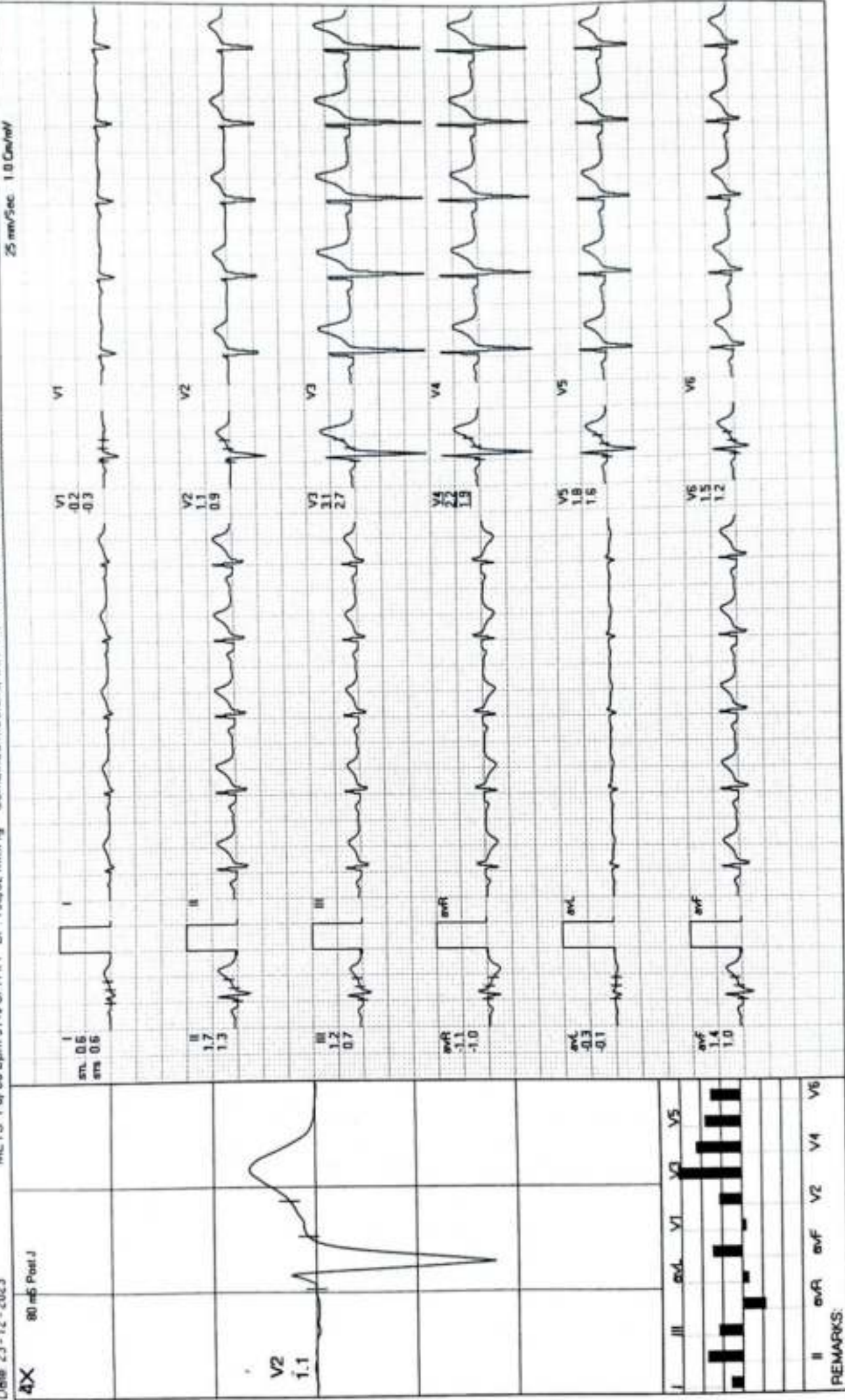
BRUCE:HV(0:07)

MODERN PATHOLOGY AND DIAGNOSTIC CENTER

JITENDRA SINGH / 51 Yrs / M / 163 Cms / 72 Kg / HR : 86

ExTime 00:00 0.0 Kmph. 0.0%

Date 23-12-2023 METS 1.0/86 bpm 51% of THR BP 130/82 mmHg Combined Medians/ BLC. On/ Notch On/ HF 0.05 Hz/ LF 35 Hz



4X 80 m5 Post J

V2 1.1

	I	II	III	aVR	aVL	aVF	V1	V2	V3	V4	V5	V6
ST-T												

REMARKS:

**MODERN PATHOLOGY AND DIAGNOSTIC CENTER**

JITENDRA SINGH / 51 Yrs / M / 163 Cms / 72 Kg / HR : 86

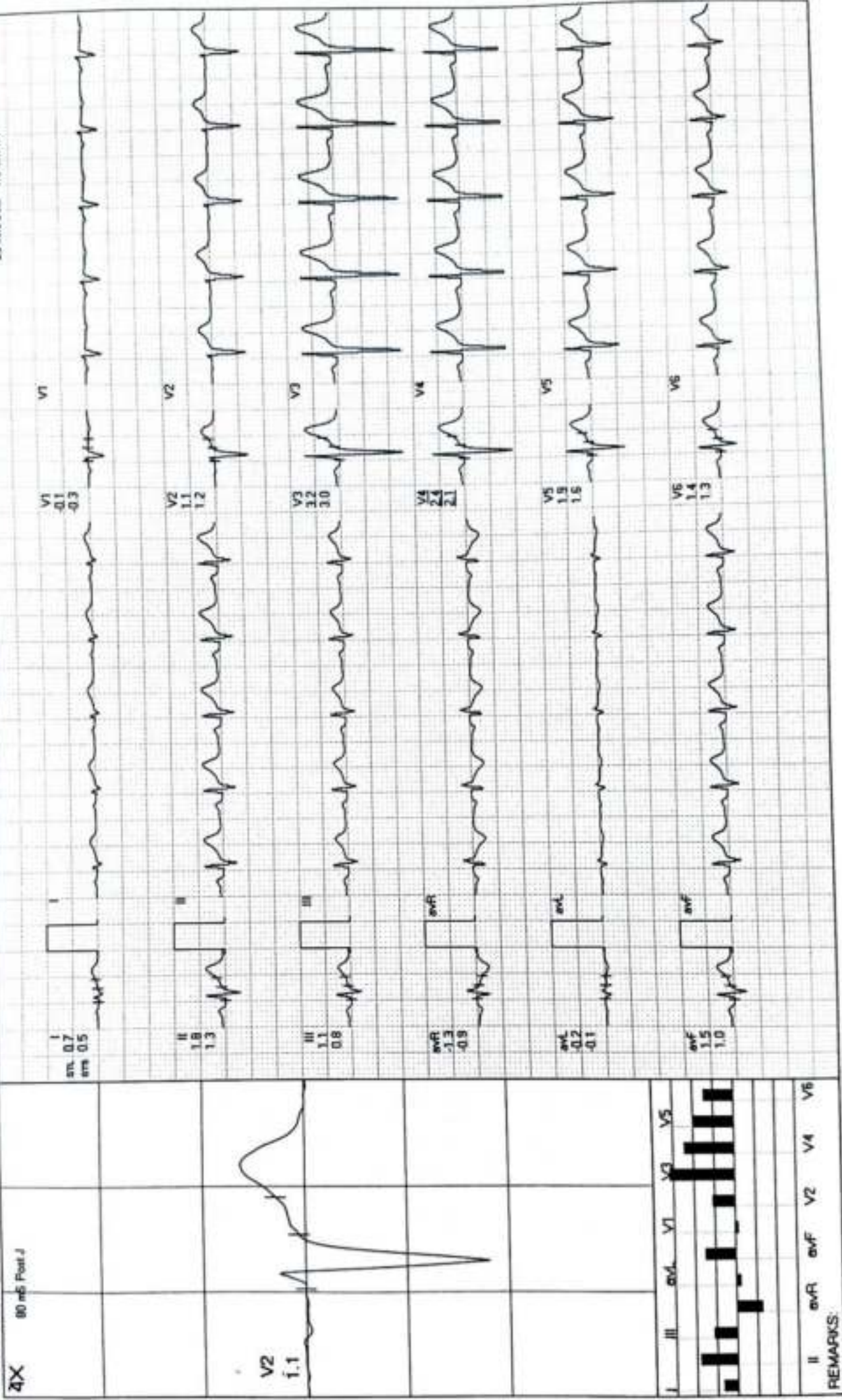
**ExStart**



ExTime 00:00 0.0 Km/h 0.0%

Date 23-12-2023 METS 1.0/86 bpm 51% of THR BP 130/82 mmHg Combined Medians/ BLC On/ Notch On/ HF 0.05 Hz/LF 35 Hz

25 mm/sec 1.0 Channel





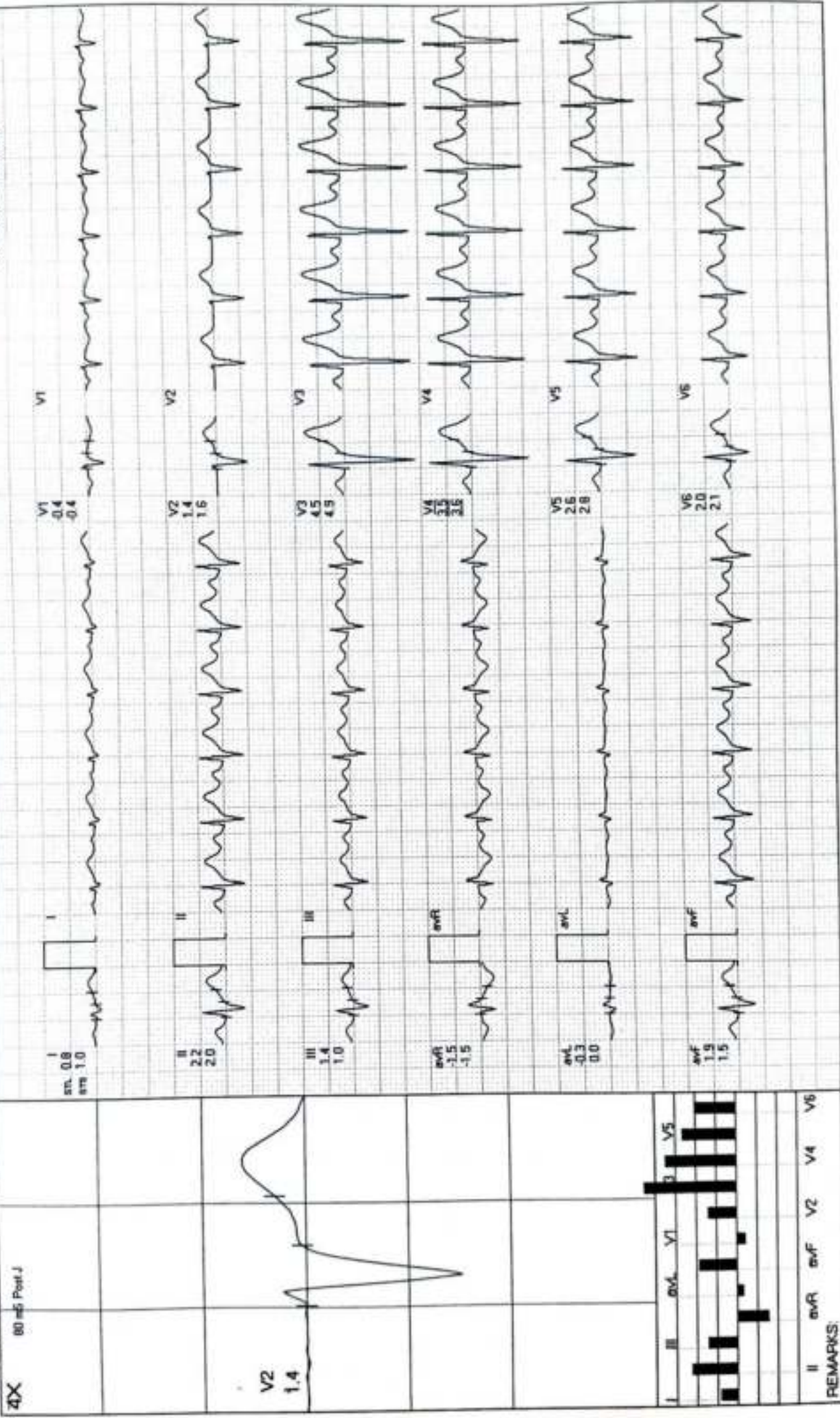
BRUCE: Stage 1 (3:00)

MODERN PATHOLOGY AND DIAGNOSTIC CENTER

JITENDRA SINGH / 51 Yrs / M / 163 Cms / 72 Kg / HR : 118

Date: 23-12-2023 METS 4.7/118 bpm 70% of THR BP: 130/82 mmHg Combined Medians/ BLC Ov/ Notch Ov/ Hf 0.05 Hz/LF 35 Hz

ExTime 03:00 2.7 Kmph 10.0%  
25 mm/Sec. 1.0 Cm/mV



REMARKS:



BRUCE: Stage 2(3:00)

MODERN PATHOLOGY AND DIAGNOSTIC CENTER

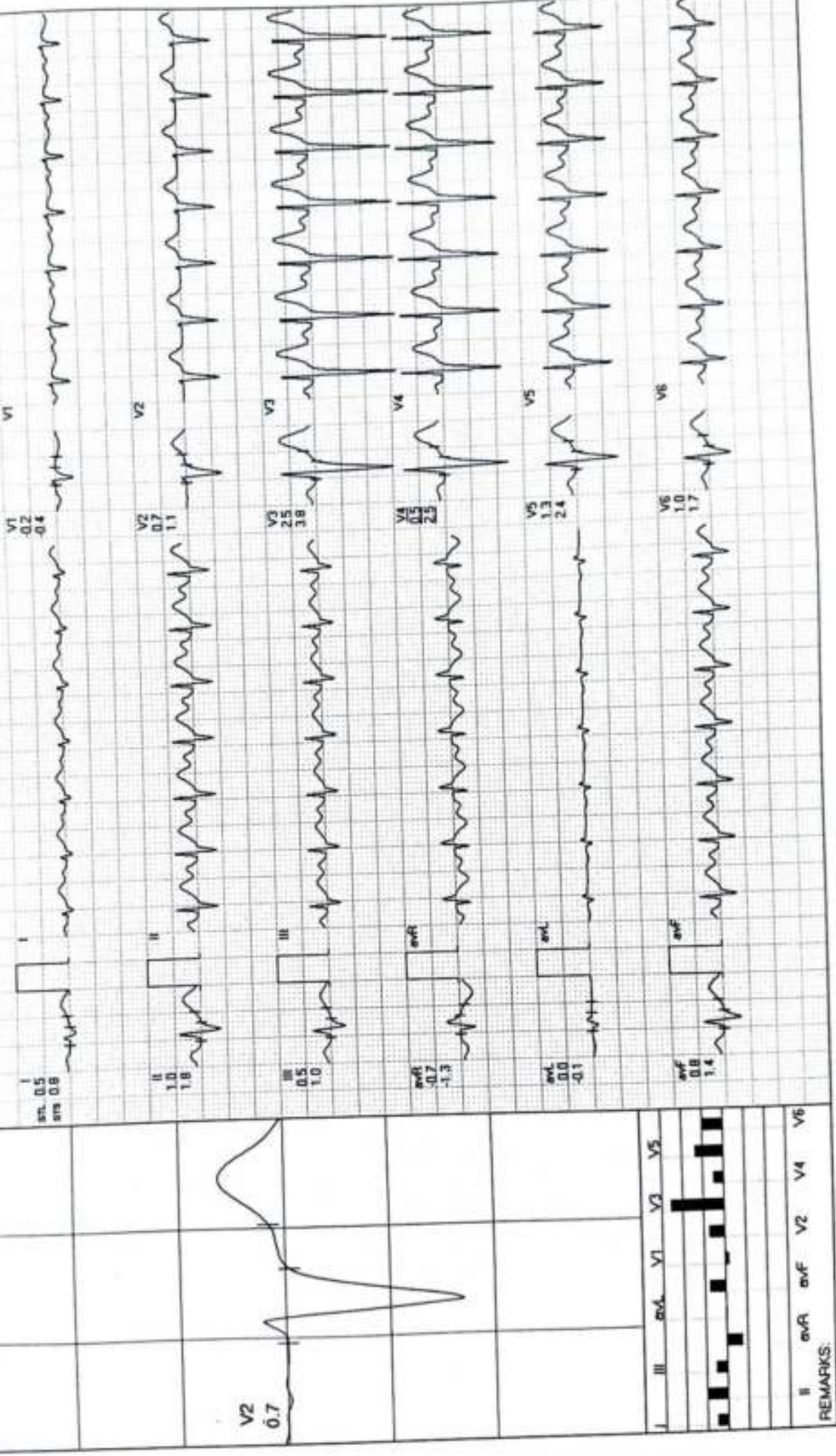JITENDRA SINGH / 51 Yrs / M / 163 Cms / 72 Kg / HR : 134

E\_rTime 06:00 4.0 Kmph. 12.0%  
25 mm/Sec 1.0 Cm/mV

METS 7.1/134 bpm 79% of Th-R BP 136/90 mmHg Combined Medians/ BLC Orv/Notch Orv/HF 0.05 Hz/LF 35 Hz

Date: 23-12-2023

4X 50 mS Post J



REMARKS:





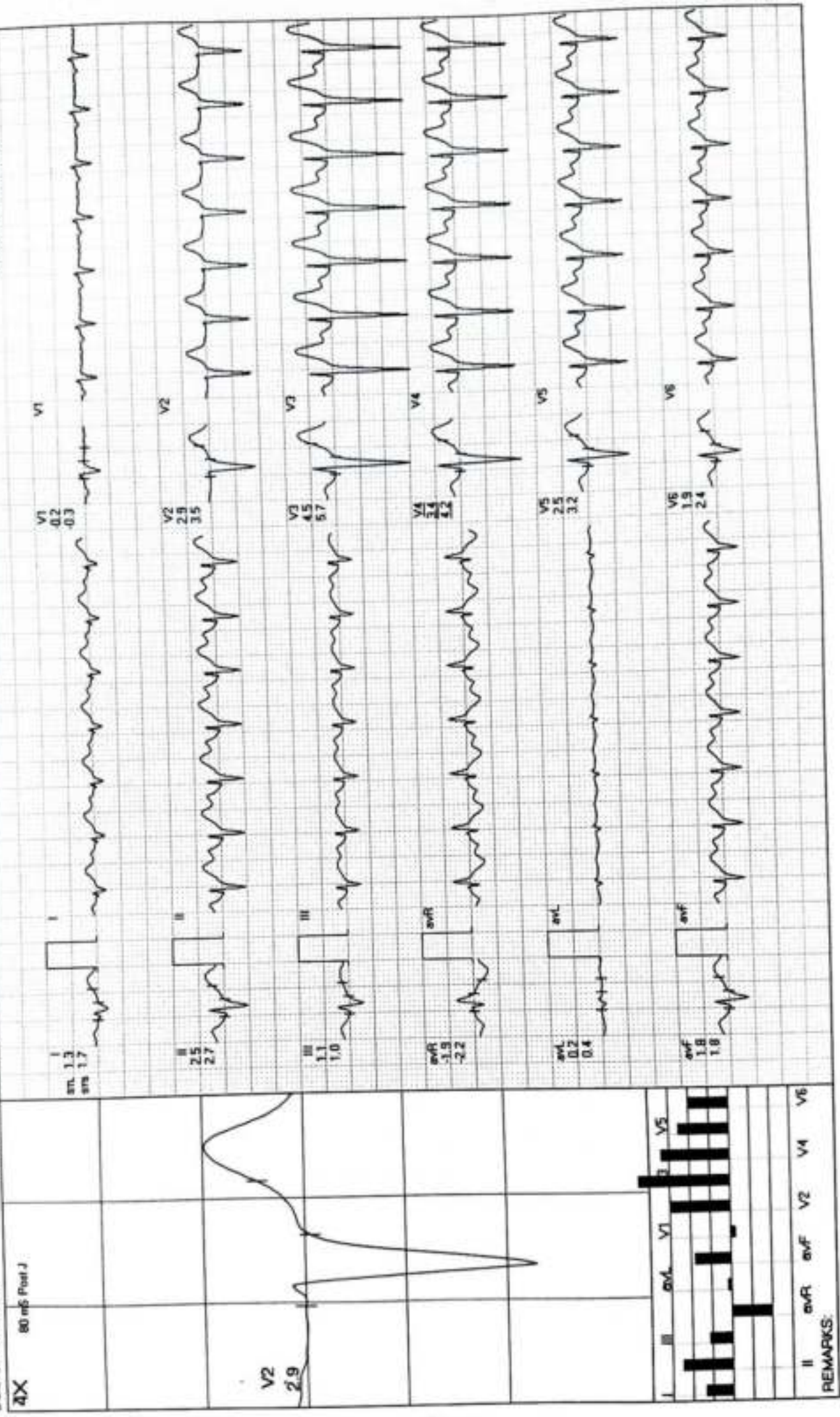
Recovery(1:00)

# MODERN PATHOLOGY AND DIAGNOSTIC CENTER

JITENDRA SINGH / 51 Yrs / M / 163 Cms / 72 Kg / HR : 125

ExTime 07:04 0.0 Km/h 0.0%

Date 23-12-2023 METS 1.1/125 bpm 74% of THR BP 144/96 mmHg Combined Medians/BLC On/Notch On/HF 0.05 Hz/LF 35 Hz



REMARKS:

**MODERN PATHOLOGY AND DIAGNOSTIC CENTER**

**JITENDRA SINGH / 51 Yrs / M / 163 Cms / 72 Kg / HR : 110**

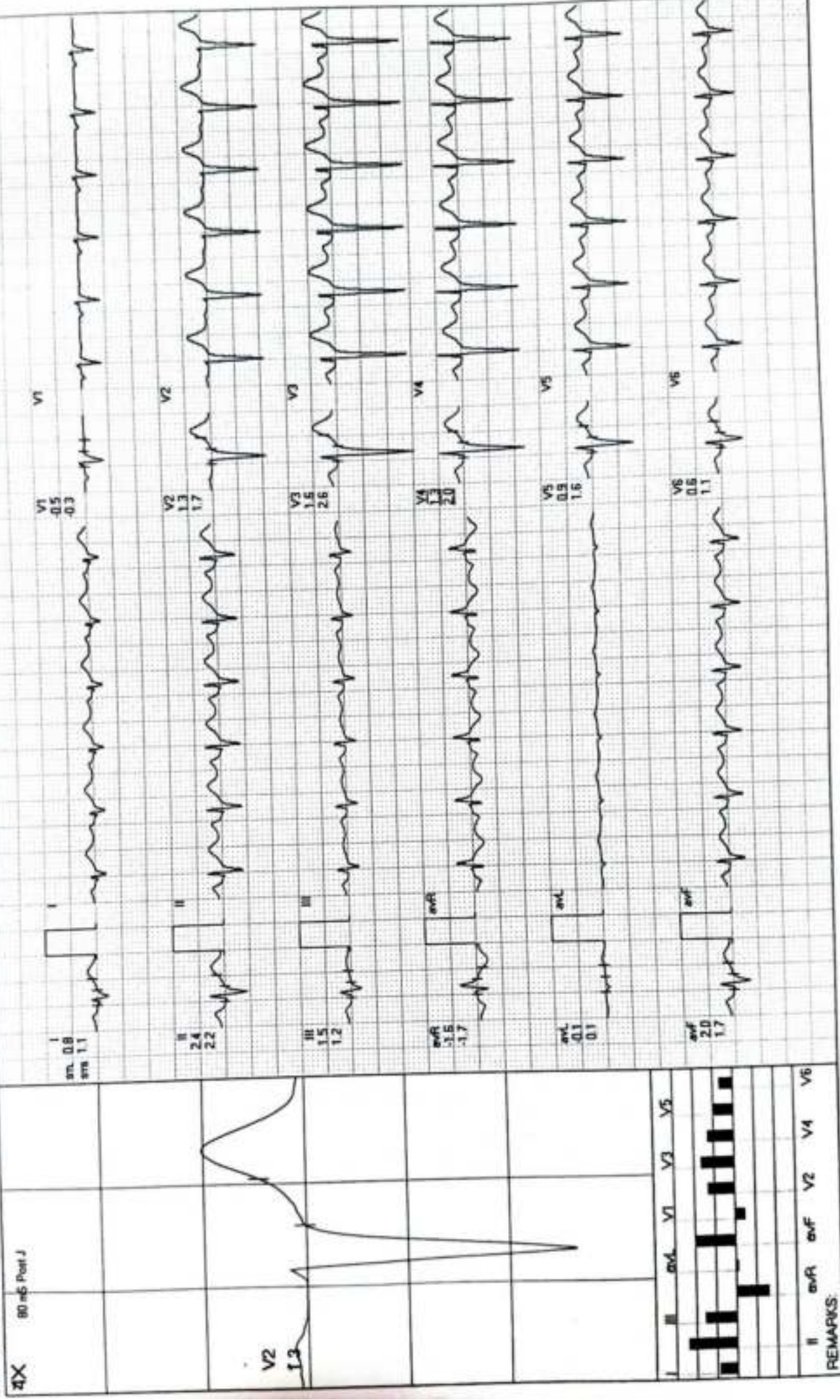
**Recovery(2:00)**



ErTime 07:04 0.0 kmph 0.0%

25 mm/Sec. 1.0 Cm/mV

Date 23-12-2023 METS 1.0/110 bpm 65% of Th-R BP 140/92 mmHg Combined Mediens/BLC On/ Natch On/ HF 0.05 Hz/LF 35 Hz



REMARKS:



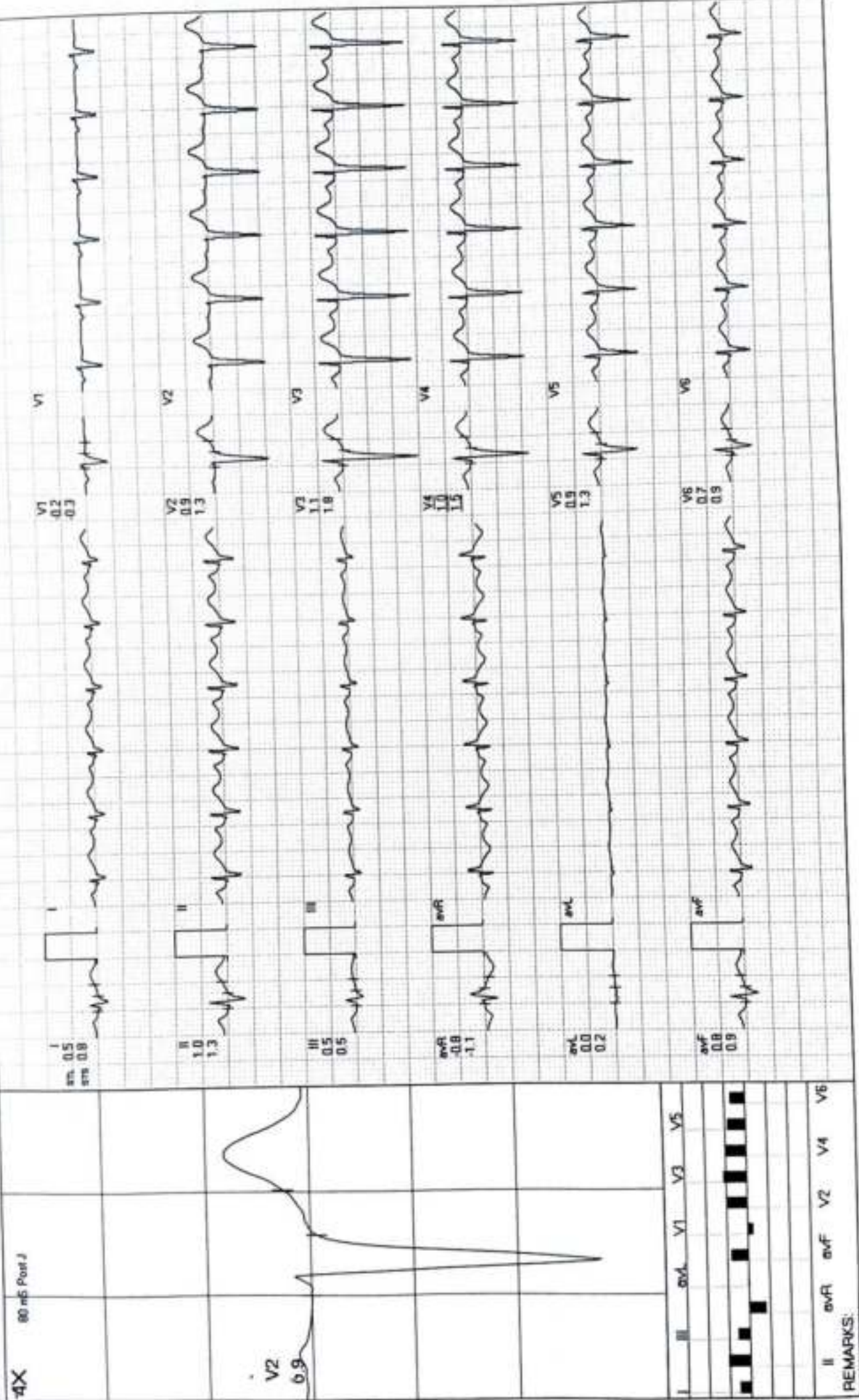
MODERN PATHOLOGY AND DIAGNOSTIC CENTER

JITENDRA SINGH / 51 Yrs / M / 163 Cms / 72 Kg / HR : 107

Ex Time: 07:04 0.0 Kmph 0.0%

METS 1.0/107 bpm 63% of THR BP: 136/86 mmHg Combined Medians/ BLC On/ Notch On/ HF 0.05 Hz/LF 35 Hz

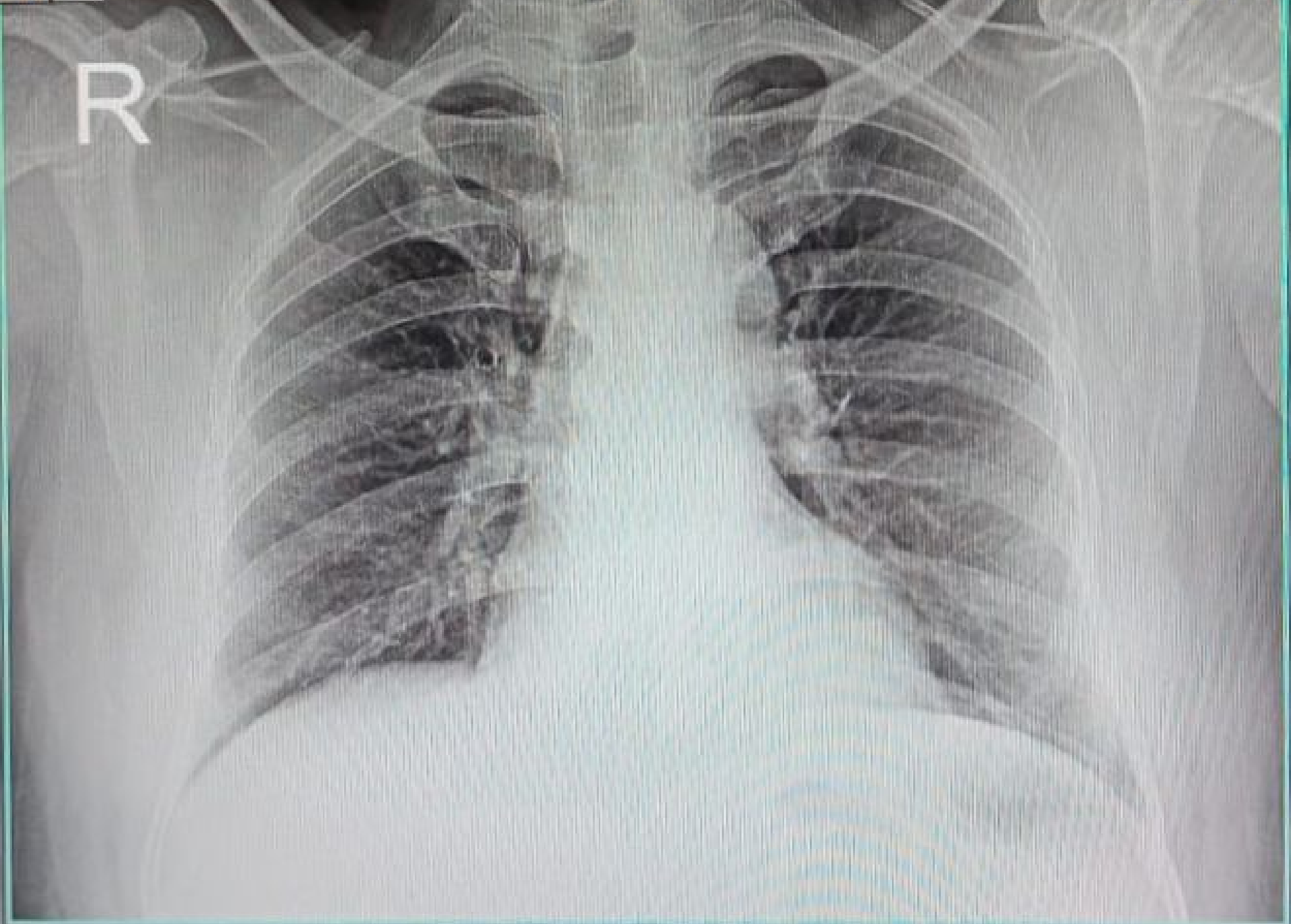
25 mm/Sec 1.0 Cm/mV







NEW!



23122302933 MR JITENDRA SINGH 00 YRS M DR SELF CHEST PA  
12/23/2023 MODERN PATHOLOGY & DIAGNOSTIC CENTRE GOMTI NAGAR LUCKNOW