

DAKSH HOSPITAL

396 - 397, Gandhi Nagar, Scheme No. 8, ALWAR -301001

Ref. No.

Date.....

MEDICAL EXAMINATION REPORT

Mediwheel (BOB)

Name: Mrs. Reema Meena Age: 30 yrs Sex: Female Date: 27/04/2024

General Physical Examination

Height	: 164cm	Weight	: 59.92 Kg
Pulse	: 78 /mt	BP	: 104/70 mm/hg
Respiration	: 18/mt	BMI	: 22.3 kg/m ²

Systemic Exam:-

NORMAL

Dental Check up :-

NORMAL

Eye check-up :-

NORMAL

Skin Check up:-

NORMAL

ENT Check up:-

NORMAL

Gynae Check up:-

MH - 2-4 d/mc ON-NIL Plu MAD
 S-6 ML-1/2y Paps near ltr
 LMP - 3mh

Impression:-

PCOD -
 TO CONSULT Gynaecologist

Recommendation:-


Dr. Mukesh Kumar Gupta

MD Gen. Medicine

Reg. No. MB, FC, D.S.

फिजिशियन एवं मधुमेह विशेषज्ञ

दक्ष हॉस्पिटल

397

राज.नं. - 5. 73/16262

Results

Run Date 27/04/2024 10:05:54 AM

Operator DAKSH

Last Name

Sample ID 6

First Name MRS REEMA

Department

Gender Female

Age

Physician DR. MUKESH GUPTA M.D

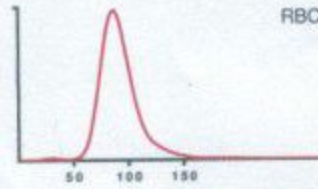
Patient ID AUTO_PID21186

Type Woman

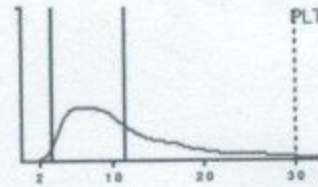
Date of birth

Sample comments

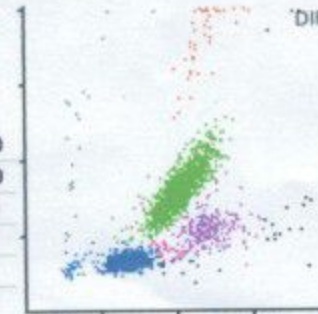
			Range
RBC	4.00	10 ⁶ /μL	3.80 - 5.50
HGB	12.0	g/dL	11.5 - 15.2
HCT	36.8	%	35.0 - 46.0
MCV	92.0	μm ³	77.0 - 97.0
MCH	30.1	pg	26.0 - 34.0
MCHC	32.7	g/dL	32.0 - 35.0
RDW-CV	15.9	%	11.0 - 17.0
RDW-SD	57.3	H μm ³	37.0 - 49.0



			Range
PLT	221	10 ³ /μL	150 - 450
PCT	0.24	%	0.15 - 0.40
MPV	10.8	μm ³	8.0 - 11.0
PDW	19.0	μm ³	11.0 - 22.0
P-LCC	82	10 ³ /μL	44 - 140
P-LCR	37.1	%	18.0 - 50.0



			Range
WBC	4.32	10 ³ /μL	3.50 - 10.00
	#	Range	%
NEU	2.55	1.60 - 7.00	59.5
LYM	1.49	1.00 - 3.00	34.8
MON	0.12	0.20 - 0.80	2.9
EOS	0.07	0.00 - 0.50	1.5
BAS	0.06	0.00 - 0.15	1.3
LIC	0.03	0.00 - 0.10	0.7



MK

Dr. R.S. Gupta
Dr. R.S. GUPTA
 MD (Pathology) (MAHE)
 RMC No. 7924/19778

Date :- 27/04/2024

Name :- MRS. REEMA

Age & Sex :- 30Yrs/ Female

Refd. :- Dr Mukesh Gupta M.D.

	TEST NAME	RESULT	REFERENCE RANGE	
	ESR	15	00 - 20 mm/hrs	
	Blood Group & Rh Factor	O * NEGATIVE		
	HbA1C	4.9	4 - 5.6%	
	Blood Sugar (R)	87.3	< 150 mg/dl	
	Blood Sugar (PP)	-	< 140 mg/dl	
	Urine Sugar (F)	-	-	
	Urine Sugar (PP)	-	-	
LIVER	S.Bilirubin Total	1.1	0.30 - 1.20 mg/dl	
	S.Bilirubin Direct	0.4	0.10 - 0.30 mg/dl	
	S.Bilirubin Indirect	0.7	0.30 - 0.90 mg/dl	
	S.G.O.T.	20	> 37 u/l	
	S.G.P.T.	29	> 40 u/l	
	S.Alk. Phosp.	181	80 - 306 u/l	
	G.G.T.	19	5 - 40 u/l	
	Total Protein	6.7	6.5 - 8.5 gm/dl	
	Albumin	3.6	3.8 - 5.4 gm/dl	
	Globulin	3.1	2.3 - 3.5 gm/dl	
	A/G Ratio	1.2	-	
	AST/ALT Ratio	0.6	-	
KIDNEY	Blood Urea	39.1	15 - 45 mg/dl	
	S.Creatinine	1.4	0.60 - 1.30 mg/dl	
	BUN	21	6 - 24 mg/dl	
	S.Uric Acid	5.2	M 3.1 - 7.0, F 2.5 - 5.6 mg/dl	
	BUN/Creatinine Ratio	15.0	-	
LIPID PROFILE	Total Cholesterol	165.1	Up to 200 mg/dl	
	S.HDL	43.1	30 - 70 mg/dl	
	S.LDL	96.1	Up to 170 mg/dl	
	S.VLDL	26.1	5.0 - 40 mg/dl	
	S. Triglycerides	130.1	Up to 170 mg/dl	
	LDL/HDL Ratio	2.2	-	
	Total Cholesterol/ HDL Ratio	3.8	-	
THYROID	T3	110.1	40 - 181 ng/dL	
	T4	7.2	4.6 - 10.5 µg/dL	
	TSH	4.1	0.30 - 5.0 mIU/L	
	URINE EXAMINATION		<u>Microscopic Examination:</u>	
General/Chemical Examination:	Colour	Pale Yellow	RBC	
	Reaction	Acidic	WBC	2 - 3
	Specific Gravity	QNS	Epithelial Cells	1 - 2
	Appearance	s.turbid	Cast	Absent
	Albumin	Nil	Crystal	Absent
	Sugar	Nil	Spermatozoa	Absent
	Patient in menses		Amorphous Sediments	Absent
		Other	Absent	
X-RAY CHEST	NORMAL STUDY			
	STOOL EXAMINATION		<u>Microscopic Examination:</u>	
General/Chemical Examination:			RBC	nil
	Colour	Pale Yellow	WBC	0 - 1
	Consistency	semi solid	Ova & Parasites	nil

Dr. R. S. GUPTA
 Doctor
 MD (Pathology) (MAHE)
 RMC No. 1924/1978

TECHNOLOGIST

Date :- 27/04/2024

Name :- Mrs. Reema Meena

Refd. :- Dr Mukesh Gupta MD

Age & Sex :- 30Yrs/ Female

CYTO-PATHOLOGY

PAP SMEAR

1. Specimen type	Received two conventional smears.
2. Specimen adequacy	Smears are satisfactory for evaluation.
3. Microscopic finding	Smears are moderately cellular comprises of predominantly intermediate with mature superficial squamous epithelial cells arranged in clusters & scattered singly.
4. Inflammation	Not seen
5. Bacilli	Not seen
6. Endocervical cells	Not seen
7. Koilocytic changes	Not seen
8. Trichomonas	Not seen
9. Dysplasia	Nil
10. Neoplasia	Nil
11. Endometrial cells	Nil

Impression:- Negative for intraepithelial lesion or malignancy


Dr. R.S. GUPTA
MD (Pathology) (MAHE)
RMC No. 7924/19778

Doctor


TECHNOLOGIST

All investigation have their own limitations regarding the sensitivity & specificity of individual assay procedures, isolated laboratory investigations never confirm the final diagnosis of the disease. They only help in arriving at a diagnosis in conjunction with clinical presentation and other related investigations. Report is not valid for medico-legal purpose subject to ALWAR jurisdiction only.



दक्ष हॉस्पिटल

396, गाँधी नगर स्कीम नं.8, अलवर (राज०) ☎ 0144-2703340

Sonography / 2D Echo Cardiography / Doppler Report

2D/ ECHO REPORT

Name: - Mrs REEMA MEENA

Age: - 30 Yrs

Date: - 27-Apr-24

Reg. No.: - Alw/2009/04
BOB health checkup

PROCEDURES:

M-MODE/2D/DOPPLER/COLOR/CONTRAST B.A.S. M²

MEASUREMENT:		DOPPLER:	
AOD	19	NORMAL	
LA	20	MV	0.6 (0.8- 1.3)
AVO	15	AV	1.4 (1.2- 1.8)
RVDd.	10	TV	0.6 (0.3- 0.8)
		PV	0.8 (0.7- 1.1)
LVDd	41	MITRAL VALVE-	
LVDs	24	AML	Normal
IVS d	9.7	PML	Normal
IVS s	10	AORTIC VALVE	
PWd	3	TV & PV	are normal.
LV FUNCTION			
M- E- S Separation	<0.9cm		
Minor	24.42%		
LV Ejection Fraction	72%		
	65 +/- 12%		

LV WALL MOTION: NO RWMA
ALL CARDIAC CHAMBERS ARE NORMAL
ALL VALVES ARE NORMAL
NO CLOT, VEGETATION, PERICARDIAL EFFUSION

FINAL DIAGNOSIS: NORMAL STUDY

Adv: - Follow up/ review at higher center for confirmation

Note:- Please Correlate clinically. Due to technical limitations as well as inaccuracies inherent in the laboratory and statistical analysis of biological process. Diagnostic accuracy of ECHO is up to 95% only.
Report is not valid for medico-legal purpose.


DR. MUKESH GUPTA
Dr. Mukesh Gupta
Physician & Sonologist
RM 5423/16262



"भ्रूण लिंग परीक्षण की शिकायत
104 टोल फ्री सेवा पर भी की
जा सकती है"

भ्रूण लिंग परीक्षण की शिकायत 104 टोल फ्री सेवा पर भी की जा सकती है।



दक्ष हॉस्पिटल

396, गाँधी नगर स्कीम नं.8, अलवर (राज०) ☎ 0144-2703340

Sonography / 2D Echo Cardiography / Doppler Report

NAME :- MKS REEMA MEENA/F/30 YRS

27-Apr-24

BOB HEALTH CHECKUP

U.S.G. OF ABDOMEN & PELVIS

LIVER

Liver is normal in size shape with normal echo-texture. Intra hepatic biliary radicals Are not dilated. No evidence of focal or diffuse lesion.

GALL BLADDER

Gall bladder is normal.

PANCREAS

Pancreas is normal in size, shape & echo-texture. No evidence of focal or diffuse lesion. MPD not dilated.

SPLEEN

Spleen normal in size with normal shape & echo- texture. Spleen vein is normal. No evidence of focal or diffuse lesion

KIDNEY

Both kidneys are normal size shape and echo- texture.

URINARY BLADDER

UB is normally distended, visualized lumen appear clear.

UTERUS:

Uterus is normal in size (7.4x3.1x4.5cm) with homogenous echo-texture. Endometrial 9 mm in thickness & echo genicity

OVARIES:

Both ovaries enlarged, Left ovary measure 50x22 mm & has multiple follicles with echogenic stoma, right ovary measure 47x26 mm & has multiple follicles with echogenic stoma. S/o polycystic ovary,,

No free fluid in POD.

Advice- follow up/ hormonal study review at higher center for confirmation

Please correlate clinically. USG accuracy is 95 % due to technical limitations as well as inaccuracies inherent in the laboratory and statistical analysis biological process.
This report is not valid for medico-legal cases

DR. MUKESH GUPTA
SONOLOGIST

Dr. Mukesh Kumar Gupta

Physician & Sonologist

RM 5423/16262



"भ्रूण लिंग परीक्षण की शिकायत
104 टोल फ्री सेवा पर भी की
जा सकती है"

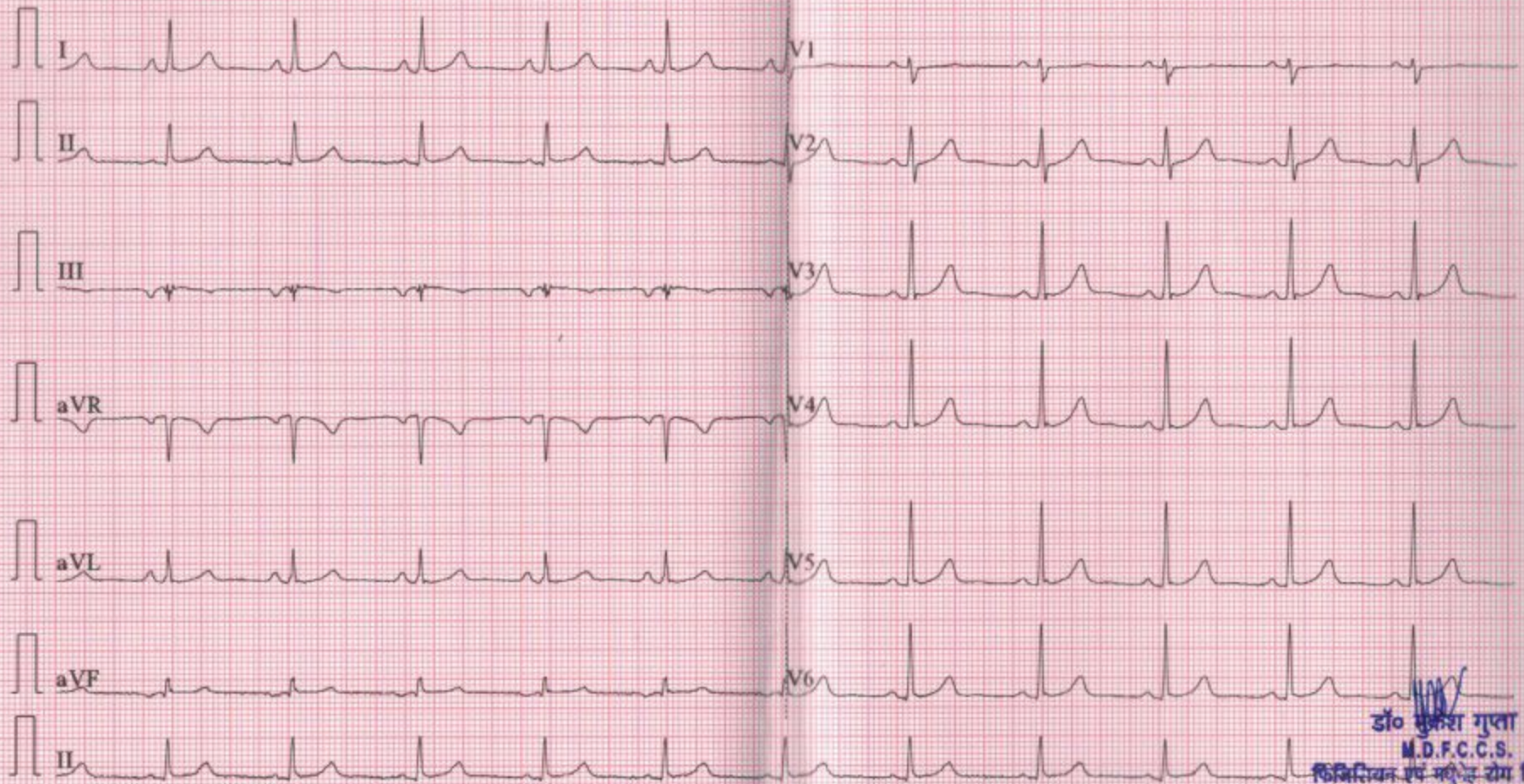
भ्रूण लिंग परीक्षण की शिकायत 104 टोल फ्री सेवा पर भी की जा सकती है।

ID:
 Male Years

HR : 70 bpm
P : 100 ms
PR : 139 ms
QRS : 84 ms
QT/QTc : 387/418 ms
P/QRS/T : -14/23/18 °
RV5/SV1 : 1.435/0.292 mV

Diagnosis Information:
Sinus Rhythm
Normal ECG

Report Confirmed by:



डॉ० सुरेश गुप्ता
M.D.F.C.C.S.
कैथिडिन एंड मल्टी स्पेशलिटी
दक्ष हॉस्पिटल, अलवर
फ़ोन नं०-5423/16262

R

