



Patient Name	: Mr.NAGARAJU M C	Collected	: 09/Nov/2024 08:13AM
Age/Gender	: 54 Y 9 M 14 D/M	Received	: 09/Nov/2024 10:10AM
UHID/MR No	: CMYS.0000058479	Reported	: 09/Nov/2024 01:12PM
Visit ID	: CMYSOPV131285	Status	: Final Report
Ref Doctor	: Self	Sponsor Name	: ARCOFEMI HEALTHCARE LIMITED
Emp/Auth/TPA ID	: 22E38056		

**DEPARTMENT OF HAEMATOLOGY**

**ARCOFEMI - MEDIWHEEL - FULL BODY ANNUAL PLUS ABOVE 50Y MALE - 2D ECHO - PAN INDIA - FY2324**

**IMPRESSION: NORMOCYTIC NORMOCHROMIC BLOOD PICTURE.**



**Dr. PAVAN KUMAR M**  
M.B.B.S,M.D(Pathology)  
Consultant Pathologist

SIN No:MYS241100332



Patient Name : Mr.NAGARAJU M C	Collected : 09/Nov/2024 08:13AM
Age/Gender : 54 Y 9 M 14 D/M	Received : 09/Nov/2024 10:10AM
UHID/MR No : CMYS.0000058479	Reported : 09/Nov/2024 01:12PM
Visit ID : CMYSOPV131285	Status : Final Report
Ref Doctor : Self	Sponsor Name : ARCOFEMI HEALTHCARE LIMITED
Emp/Auth/TPA ID : 22E38056	

**DEPARTMENT OF HAEMATOLOGY**

**ARCOFEMI - MEDIWHEEL - FULL BODY ANNUAL PLUS ABOVE 50Y MALE - 2D ECHO - PAN INDIA - FY2324**

Test Name	Result	Unit	Bio. Ref. Interval	Method
<b>BLOOD GROUP ABO AND RH FACTOR , WHOLE BLOOD EDTA</b>				
BLOOD GROUP TYPE	O			Forward & Reverse Grouping with Slide/Tube Aggluti
Rh TYPE	POSITIVE			Forward & Reverse Grouping with Slide/Tube Agglutination



**Dr. PAVAN KUMAR M**  
M.B.B.S,M.D(Pathology)  
Consultant Pathologist

SIN No:MYS241100332



Patient Name : Mr.NAGARAJU M C	Collected : 09/Nov/2024 08:13AM
Age/Gender : 54 Y 9 M 14 D/M	Received : 09/Nov/2024 10:10AM
UHID/MR No : CMYS.0000058479	Reported : 09/Nov/2024 11:08AM
Visit ID : CMYSOPV131285	Status : Final Report
Ref Doctor : Self	Sponsor Name : ARCOFEMI HEALTHCARE LIMITED
Emp/Auth/TPA ID : 22E38056	

DEPARTMENT OF BIOCHEMISTRY

ARCOFEMI - MEDIWHEEL - FULL BODY ANNUAL PLUS ABOVE 50Y MALE - 2D ECHO - PAN INDIA - FY2324

Test Name	Result	Unit	Bio. Ref. Interval	Method
GLUCOSE, FASTING , NAF PLASMA	98	mg/dl	74-106	GOD, POD

**Comment:**

As per American Diabetes Guidelines, 2023

Fasting Glucose Values in mg/dL	Interpretation
70-100 mg/dL	Normal
100-125 mg/dL	Prediabetes
≥126 mg/dL	Diabetes
<70 mg/dL	Hypoglycemia

**Note:**

- 1.The diagnosis of Diabetes requires a fasting plasma glucose of > or = 126 mg/dL and/or a random / 2 hr post glucose value of > or = 200 mg/dL on at least 2 occasions.
2. Very high glucose levels (>450 mg/dL in adults) may result in Diabetic Ketoacidosis & is considered critical.



Dr. PAVAN KUMAR M  
M.B.B.S,M.D(Pathology)  
Consultant Pathologist

SIN No:MYS241100331



Patient Name : Mr.NAGARAJU M C	Collected : 09/Nov/2024 10:45AM
Age/Gender : 54 Y 9 M 14 D/M	Received : 09/Nov/2024 12:17PM
UHID/MR No : CMYS.0000058479	Reported : 09/Nov/2024 01:17PM
Visit ID : CMYSOPV131285	Status : Final Report
Ref Doctor : Self	Sponsor Name : ARCOFEMI HEALTHCARE LIMITED
Emp/Auth/TPA ID : 22E38056	

**DEPARTMENT OF BIOCHEMISTRY**

**ARCOFEMI - MEDIWHEEL - FULL BODY ANNUAL PLUS ABOVE 50Y MALE - 2D ECHO - PAN INDIA - FY2324**

Test Name	Result	Unit	Bio. Ref. Interval	Method
<b>GLUCOSE, POST PRANDIAL (PP), 2 HOURS , SODIUM FLUORIDE PLASMA (2 HR)</b>	135	mg/dl	70-140	GOD, POD

**Comment:**

It is recommended that FBS and PPBS should be interpreted with respect to their Biological reference ranges and not with each other.  
 Conditions which may lead to lower postprandial glucose levels as compared to fasting glucose levels may be due to reactive hypoglycemia, dietary meal content, duration or timing of sampling after food digestion and absorption, medications such as insulin preparations, sulfonylureas, amylin analogues, or conditions such as overproduction of insulin.



**Dr. PAVAN KUMAR M**  
M.B.B.S,M.D(Pathology)  
Consultant Pathologist

SIN No:MYS241100466







Patient Name : Mr.NAGARAJU M C	Collected : 09/Nov/2024 08:13AM
Age/Gender : 54 Y 9 M 14 D/M	Received : 09/Nov/2024 10:10AM
UHID/MR No : CMYS.0000058479	Reported : 09/Nov/2024 11:17AM
Visit ID : CMYSOPV131285	Status : Final Report
Ref Doctor : Self	Sponsor Name : ARCOFEMI HEALTHCARE LIMITED
Emp/Auth/TPA ID : 22E38056	

**DEPARTMENT OF BIOCHEMISTRY**

**ARCOFEMI - MEDIWHEEL - FULL BODY ANNUAL PLUS ABOVE 50Y MALE - 2D ECHO - PAN INDIA - FY2324**

Test Name	Result	Unit	Bio. Ref. Interval	Method
<b>LIVER FUNCTION TEST (LFT) , SERUM</b>				
BILIRUBIN, TOTAL	0.87	mg/dl	0-1.2	NBD
BILIRUBIN CONJUGATED (DIRECT)	<b>0.24</b>	mg/dl	0-0.2	Diazotized sulfanilic acid
BILIRUBIN (INDIRECT)	0.63	mg/dL	0.0-1.1	Dual Wavelength
ALANINE AMINOTRANSFERASE (ALT/SGPT)	18	U/l	0-45	IFCC
ASPARTATE AMINOTRANSFERASE (AST/SGOT)	17.0	U/l	0-35	IFCC
AST (SGOT) / ALT (SGPT) RATIO (DE RITIS)	0.9		<1.15	Calculated
ALKALINE PHOSPHATASE	79.00	U/l	53-128	IFCC (AMP buffer)
PROTEIN, TOTAL	7.40	g/dl	6.4-8.3	Biuret
ALBUMIN	4.20	g/dl	3.5-5.2	Bromcresol Green
GLOBULIN	3.20	g/dL	2.0-3.5	Calculated
A/G RATIO	1.31		0.9-2.0	Calculated

**Comment:**

LFT results reflect different aspects of the health of the liver, i.e., hepatocyte integrity (AST & ALT), synthesis and secretion of bile (Bilirubin, ALP), cholestasis (ALP, GGT), protein synthesis (Albumin) Common patterns seen:

1. Hepatocellular Injury:

\*AST – Elevated levels can be seen. However, it is not specific to liver and can be raised in cardiac and skeletal injuries.\*ALT – Elevated levels indicate hepatocellular damage. It is considered to be most specific lab test for hepatocellular injury. Values also correlate well with increasing BMI. Disproportionate increase in AST, ALT compared with ALP. AST: ALT (ratio) – In case of hepatocellular injury AST: ALT > 1 In Alcoholic Liver Disease AST: ALT usually >2. This ratio is also seen to be increased in NAFLD, Wilson’s diseases, Cirrhosis, but the increase is usually not >2.

2. Cholestatic Patten:\*ALP – Disproportionate increase in ALP compared with AST, ALT. ALP elevation also seen in pregnancy, impacted by age and sex.\*Bilirubin elevated- predominantly direct , To establish the hepatic origin correlation with elevated GGT helps.

3. Synthetic function impairment:\*Albumin- Liver disease reduces albumin levels, Correlation with PT (Prothrombin Time) helps.

4. Associated tests for assessment of liver fibrosis - Fibrosis-4 and APRI Index.

  
Dr. PAVAN KUMAR M  
M.B.B.S,M.D(Pathology)  
Consultant Pathologist

SIN No:MYS241100328





Patient Name : Mr.NAGARAJU M C	Collected : 09/Nov/2024 08:13AM
Age/Gender : 54 Y 9 M 14 D/M	Received : 09/Nov/2024 10:10AM
UHID/MR No : CMYS.0000058479	Reported : 09/Nov/2024 11:39AM
Visit ID : CMYSOPV131285	Status : Final Report
Ref Doctor : Self	Sponsor Name : ARCOFEMI HEALTHCARE LIMITED
Emp/Auth/TPA ID : 22E38056	

**DEPARTMENT OF BIOCHEMISTRY**

**ARCOFEMI - MEDIWHEEL - FULL BODY ANNUAL PLUS ABOVE 50Y MALE - 2D ECHO - PAN INDIA - FY2324**

Test Name	Result	Unit	Bio. Ref. Interval	Method
<b>RENAL PROFILE/KIDNEY FUNCTION TEST (RFT/KFT) , SERUM</b>				
CREATININE	0.74	mg/dL	0.67-1.17	Enzymatic colorimetric
UREA	17.44	mg/dl	13-43	Urease, UV
BLOOD UREA NITROGEN	8.2	mg/dL	8.0 - 23.0	Calculated
URIC ACID	5.60	mg/dL	3.5-7.2	Uricase
CALCIUM	9.40	mg/dl	8.6-10.3	Arsenazo III
PHOSPHORUS, INORGANIC	3.52	mg/dl	2.7-4.5	Molybdate
SODIUM	138	mmol/L	135-145	Direct ISE
POTASSIUM	4.4	mmol/L	3.5-5.1	Direct ISE
CHLORIDE	102	mmol/L	98 - 107	Direct ISE
PROTEIN, TOTAL	7.40	g/dl	6.4-8.3	Biuret
ALBUMIN	4.20	g/dl	3.5-5.2	Bromcresol Green
GLOBULIN	3.20	g/dL	2.0-3.5	Calculated
A/G RATIO	1.31		0.9-2.0	Calculated



**Dr. PAVAN KUMAR M**  
M.B.B.S,M.D(Pathology)  
Consultant Pathologist

SIN No:MYS241100328



Patient Name : Mr.NAGARAJU M C	Collected : 09/Nov/2024 08:13AM
Age/Gender : 54 Y 9 M 14 D/M	Received : 09/Nov/2024 10:10AM
UHID/MR No : CMYS.0000058479	Reported : 09/Nov/2024 11:17AM
Visit ID : CMYSOPV131285	Status : Final Report
Ref Doctor : Self	Sponsor Name : ARCOFEMI HEALTHCARE LIMITED
Emp/Auth/TPA ID : 22E38056	

**DEPARTMENT OF BIOCHEMISTRY**

**ARCOFEMI - MEDIWHEEL - FULL BODY ANNUAL PLUS ABOVE 50Y MALE - 2D ECHO - PAN INDIA - FY2324**

Test Name	Result	Unit	Bio. Ref. Interval	Method
<b>GAMMA GLUTAMYL TRANSPEPTIDASE (GGT) , SERUM</b>	28.00	U/l	0-55	IFCC



**Dr. PAVAN KUMAR M**  
M.B.B.S,M.D(Pathology)  
Consultant Pathologist

SIN No:MYS241100328



Patient Name : Mr.NAGARAJU M C	Collected : 09/Nov/2024 08:13AM
Age/Gender : 54 Y 9 M 14 D/M	Received : 09/Nov/2024 10:10AM
UHID/MR No : CMYS.0000058479	Reported : 09/Nov/2024 12:53PM
Visit ID : CMYSOPV131285	Status : Final Report
Ref Doctor : Self	Sponsor Name : ARCOFEMI HEALTHCARE LIMITED
Emp/Auth/TPA ID : 22E38056	

**DEPARTMENT OF IMMUNOLOGY**

**ARCOFEMI - MEDIWHEEL - FULL BODY ANNUAL PLUS ABOVE 50Y MALE - 2D ECHO - PAN INDIA - FY2324**

Test Name	Result	Unit	Bio. Ref. Interval	Method
<b>THYROID PROFILE TOTAL (T3, T4, TSH) , SERUM</b>				
TRI-iodothyronine (T3, TOTAL)	1.17	ng/mL	0.87-1.78	CLIA
THYROXINE (T4, TOTAL)	<b>13.3</b>	µg/dL	6.09-12.23	CLIA
THYROID STIMULATING HORMONE (TSH)	1.200	µIU/mL	0.38-5.33	CLIA

**Comment:**

<b>For pregnant females</b>	<b>Bio Ref Range for TSH in uIU/ml (As per American Thyroid Association)</b>
First trimester	0.1 - 2.5
Second trimester	0.2 – 3.0
Third trimester	0.3 – 3.0

1. TSH is a glycoprotein hormone secreted by the anterior pituitary. TSH activates production of T3 (Triiodothyronine) and its prohormone T4 (Thyroxine). Increased blood level of T3 and T4 inhibit production of TSH.
2. TSH is elevated in primary hypothyroidism and will be low in primary hyperthyroidism. Elevated or low TSH in the context of normal free thyroxine is often referred to as sub-clinical hypo- or hyperthyroidism respectively.
3. Both T4 & T3 provides limited clinical information as both are highly bound to proteins in circulation and reflects mostly inactive hormone. Only a very small fraction of circulating hormone is free and biologically active.
4. Significant variations in TSH can occur with circadian rhythm, hormonal status, stress, sleep deprivation, medication & circulating antibodies.

TSH	T3	T4	FT4	Conditions
High	Low	Low	Low	Primary Hypothyroidism, Post Thyroidectomy, Chronic Autoimmune Thyroiditis
High	N	N	N	Subclinical Hypothyroidism, Autoimmune Thyroiditis, Insufficient Hormone Replacement Therapy.
N/Low	Low	Low	Low	Secondary and Tertiary Hypothyroidism
Low	High	High	High	Primary Hyperthyroidism, Goitre, Thyroiditis, Drug effects, Early Pregnancy
Low	N	N	N	Subclinical Hyperthyroidism
Low	Low	Low	Low	Central Hypothyroidism, Treatment with Hyperthyroidism
Low	N	High	High	Thyroiditis, Interfering Antibodies
N/Low	High	N	N	T3 Thyrotoxicosis, Non thyroidal causes

**Dr. PAVAN KUMAR M**  
 M.B.B.S, M.D(Pathology)  
 Consultant Pathologist

SIN No: MYS241100334



Patient Name	: Mr.NAGARAJU M C	Collected	: 09/Nov/2024 08:13AM
Age/Gender	: 54 Y 9 M 14 D/M	Received	: 09/Nov/2024 10:10AM
UHID/MR No	: CMYS.0000058479	Reported	: 09/Nov/2024 12:53PM
Visit ID	: CMYSOPV131285	Status	: Final Report
Ref Doctor	: Self	Sponsor Name	: ARCOFEMI HEALTHCARE LIMITED
Emp/Auth/TPA ID	: 22E38056		

**DEPARTMENT OF IMMUNOLOGY**

**ARCOFEMI - MEDIWHEEL - FULL BODY ANNUAL PLUS ABOVE 50Y MALE - 2D ECHO - PAN INDIA - FY2324**

High	High	High	High	Pituitary Adenoma; TSHoma/Thyrotropinoma
------	------	------	------	------------------------------------------




Dr. PAVAN KUMAR M  
M.B.B.S,M.D(Pathology)  
Consultant Pathologist

SIN No:MYS241100334



Patient Name : Mr.NAGARAJU M C	Collected : 09/Nov/2024 08:13AM
Age/Gender : 54 Y 9 M 14 D/M	Received : 09/Nov/2024 10:10AM
UHID/MR No : CMYS.0000058479	Reported : 09/Nov/2024 12:53PM
Visit ID : CMYSOPV131285	Status : Final Report
Ref Doctor : Self	Sponsor Name : ARCOFEMI HEALTHCARE LIMITED
Emp/Auth/TPA ID : 22E38056	

**DEPARTMENT OF IMMUNOLOGY**

**ARCOFEMI - MEDIWHEEL - FULL BODY ANNUAL PLUS ABOVE 50Y MALE - 2D ECHO - PAN INDIA - FY2324**

Test Name	Result	Unit	Bio. Ref. Interval	Method
<b>TOTAL PROSTATIC SPECIFIC ANTIGEN (tPSA) , SERUM</b>	1.930	ng/mL	0-4	CLIA



**Dr. PAVAN KUMAR M**  
M.B.B.S,M.D(Pathology)  
Consultant Pathologist

SIN No:MYS241100334



Patient Name : Mr.NAGARAJU M C	Collected : 09/Nov/2024 08:13AM
Age/Gender : 54 Y 9 M 14 D/M	Received : 09/Nov/2024 11:12AM
UHID/MR No : CMYS.0000058479	Reported : 09/Nov/2024 12:29PM
Visit ID : CMYSOPV131285	Status : Final Report
Ref Doctor : Self	Sponsor Name : ARCOFEMI HEALTHCARE LIMITED
Emp/Auth/TPA ID : 22E38056	

**DEPARTMENT OF CLINICAL PATHOLOGY**

**ARCOFEMI - MEDIWHEEL - FULL BODY ANNUAL PLUS ABOVE 50Y MALE - 2D ECHO - PAN INDIA - FY2324**

Test Name	Result	Unit	Bio. Ref. Interval	Method
<b>COMPLETE URINE EXAMINATION (CUE) , URINE</b>				
<b>PHYSICAL EXAMINATION</b>				
COLOUR	PALE YELLOW		PALE YELLOW	Visual
TRANSPARENCY	CLEAR		CLEAR	Physical Measurement
pH	6.5		5-7.5	Double Indicator
SP. GRAVITY	1.010		1.002-1.030	Bromothymol Blue
<b>BIOCHEMICAL EXAMINATION</b>				
URINE PROTEIN	NEGATIVE		NEGATIVE	Protein Error Of Indicator
GLUCOSE	NEGATIVE		NEGATIVE	Glucose Oxidase
URINE BILIRUBIN	NEGATIVE		NEGATIVE	Azo Coupling Reaction
URINE KETONES (RANDOM)	NEGATIVE		NEGATIVE	Sodium Nitro Prusside
UROBILINOGEN	NORMAL		NORMAL	Modified Ehrlich Reaction
NITRITE	NEGATIVE		NEGATIVE	Diazotization
LEUCOCYTE ESTERASE	NEGATIVE		NEGATIVE	Leucocyte Esterase
<b>CENTRIFUGED SEDIMENT WET MOUNT AND MICROSCOPY</b>				
PUS CELLS	4 - 6	/hpf	0-5	Microscopy
EPITHELIAL CELLS	2 - 3	/hpf	<10	Microscopy
RBC	NIL	/hpf	0-2	Microscopy
CASTS	NIL		0-2 Hyaline Cast	Microscopy
CRYSTALS	ABSENT		ABSENT	Microscopy

**Comment:**

All urine samples are checked for adequacy and suitability before examination. All abnormal chemical examination are rechecked and verified by manual methods. Microscopy findings are reported as an average of 10 high power fields.



Dr. PAVAN KUMAR M  
M.B.B.S.,M.D(Pathology)  
Consultant Pathologist

SIN No:MYS241100330



Patient Name : Mr.NAGARAJU M C	Collected : 09/Nov/2024 08:13AM
Age/Gender : 54 Y 9 M 14 D/M	Received : 09/Nov/2024 11:12AM
UHID/MR No : CMYS.0000058479	Reported : 09/Nov/2024 11:53AM
Visit ID : CMYSOPV131285	Status : Final Report
Ref Doctor : Self	Sponsor Name : ARCOFEMI HEALTHCARE LIMITED
Emp/Auth/TPA ID : 22E38056	

DEPARTMENT OF CLINICAL PATHOLOGY

ARCOFEMI - MEDIWHEEL - FULL BODY ANNUAL PLUS ABOVE 50Y MALE - 2D ECHO - PAN INDIA - FY2324

Test Name	Result	Unit	Bio. Ref. Interval	Method
URINE GLUCOSE(POST PRANDIAL)	NEGATIVE		NEGATIVE	GOD-POD

Test Name	Result	Unit	Bio. Ref. Interval	Method
URINE GLUCOSE(FASTING)	NEGATIVE		NEGATIVE	GOD-POD

\*\*\* End Of Report \*\*\*



Dr. PAVAN KUMAR M  
M.B.B.S,M.D(Pathology)  
Consultant Pathologist


SIN No:MYS241100333



Patient Name	: Mr.NAGARAJU M C	Collected	: 09/Nov/2024 08:13AM
Age/Gender	: 54 Y 9 M 14 D/M	Received	: 09/Nov/2024 11:12AM
UHID/MR No	: CMYS.0000058479	Reported	: 09/Nov/2024 11:53AM
Visit ID	: CMYSOPV131285	Status	: Final Report
Ref Doctor	: Self	Sponsor Name	: ARCOFEMI HEALTHCARE LIMITED
Emp/Auth/TPA ID	: 22E38056		

**TERMS AND CONDITIONS GOVERNING THIS REPORT**

1. Reported results are for information and interpretation of the referring doctor or such other medical professionals, who understand reporting units, reference ranges and limitation of technologies. Laboratories not be responsible for any interpretation whatsoever.
2. It is presumed that the tests performed are, on the specimen / sample being to the patient named or identified and the verifications of particulars have been confirmed by the patient or his / her representative at the point of generation of said specimen.
3. The reported results are restricted to the given specimen only. Results may vary from lab to lab and from time to time for the same parameter for the same patient (within subject biological variation).
4. The patient details along with their results in certain cases like notifiable diseases and as per local regulatory requirements will be communicated to the assigned regulatory bodies.
5. The patient samples can be used as part of internal quality control, test verification, data analysis purposes within the testing scope of the laboratory.
6. This report is not valid for medico legal purposes. It is performed to facilitate medical diagnosis only.



Dr. PAVAN KUMAR M  
M.B.B.S, M.D(Pathology)  
Consultant Pathologist



SIN No: MYS241100333



---

Patient Name	: Mr. NAGARAJU M C	Age	: 54Yrs 9Mths 16Days
UHID	: CMYS.0000058479	OP Visit No.	: CMYSOPV131285
Printed On	: 10-11-2024 04:45 AM	Advised/Pres Doctor	: --
Department	: Radiology	Qualification	: --
Referred By	: Self	Registration No.	: --
Employer Id	: 22E38056		

---

### DEPARTMENT OF RADIOLOGY

---

**LIVER:** It is normal in size, outline and is increased in echotexture. No focal lesions seen. IHBR are not dilated. CBD and Portal vein are normal.

**GALL BLADDER:** It is distended with evidence of a echogenic small calculus measuring ~5.5mm noted within the lumen

**SPLEEN:** It is normal in size, outline and echopattern. No e/o focal lesions.

**PANCREAS:** It is normal in size, outline and echopattern.

**RIGHT KIDNEY:** It measures 9.6 cm with parenchymal thickness of 1.4 cm. It is normal in size, outline and echotexture. No e/o calculus or hydronephrosis seen. **A simple large exophytic cystic lesion measuring ~ 5.5 x 3.9 cm is noted in lower pole cortex of right kidney**

**LEFT KIDNEY:** It measures 9.5cm with parenchymal thickness of 1.5 cm. It is normal in size, outline and echotexture. No e/o calculus or hydronephrosis seen.

**URINARY BLADDER:** It is well distended. The UB wall is normal. No e/o calculi.

**PROSTATE:** It is mildly enlarged (measures~26cc) with normal echotexture.

---

No e/o free fluid in the abdomen.

**IMPRESSION:**

**Grade I fatty liver**  
**Cholelithiasis .No features of cholecystitis**  
**Large exophytic simple right renal cyst**  
**Grade I prostatomegaly**

---End Of The Report---



**Dr.CHETAN HOLEPPAGOL**  
**MBBS, DNB(RADIO DIAGNOSIS)**  
90037  
Radiology



---

Patient	Mr. NAGARAJU M C	Doctor	SUJATHA T R	Appt ID	CMYSAPT1392
Age/Gender	54Y   Male	Qualification	MBBS, PGDMCH	Consult Date	10 Nov 2024
UHID	CMYS.0000058479	Reg. No.	69649	Order Bill ID	CMYS-OCR-24648
				Visit Display ID	CMYSOPV131285

---

## VITALS

---

Weight : 86.1Kgs	Height : 169Cms
Pulse : 72 BPM	Spo2 : 98%
BP : 120 / 90 MmHg	Respiratory Rate : 20 BPM
Temperature : 98 °F	

SUJATHA T R  
**Doctor's Signature**

**Apollo Health and Lifestyle Limited**

(CIN-U85110TG2000PLC115819)

Corporate Office: 7-1-617/A, 7\* Floor, Imperial Towers, Ameerpet, Hyderabad-500016, Telangana

Ph No: 040-4904 7777 | www.apollohl.com | Email ID:enquiry@apollohl.com

---

Patient Name	: Mr. NAGARAJU M C	Age	: 54Yrs 9Mths 20Days
UHID	: CMYS.0000058479	OP Visit No.	: CMYSOPV131285
Printed On	: 14-11-2024 07:40 AM	Advised/Pres Doctor	: --
Department	: Cardiology	Qualification	: --
Referred By	: Self	Registration No.	: --
Employer Id	: 22E38056		

---

## DEPARTMENT OF CARDIOLOGY

---

### 2D ECHOCARDIOGRAPHY STUDY

#### Impression:

Normal chambers and valves  
Mild MR/ PR  
No regional wall motion abnormality  
Normal left ventricular systolic function. EF 60 %  
Grade I LVDD  
No clots. No pericardial effusion

#### Findings

Left Ventricle: No RWMA  
Right Ventricle Normal  
Left Atrium Normal  
Right Atrium Normal  
Aorta Normal  
Pulmonary Artery Normal  
IAS Intact  
IVS Intact  
Valves Normal  
Pericardium Normal  
Doppler Grade I LVDD. Mild MR/ PR

---

**Patient's Name : Mr. Nagaraju Age & Sex; 54Yrs / Male**

**Date : 09.11.2024**

**UHID No:**

Measurements

AO:2.8cm

LA :2.6cm

RV :2.5 cm

---

LVIDd 4.70 cm

LVIDs :3.17 cm

IVSd :0.76 cm

IVSs :1.21 cm

PWd :1.05 cm

PWs :1.37 cm

EF : 60.0 %

FS : 32.0 %

Doppler

MV TV AV PV

E :0.52m/sE --- m/sV max1.01m/sV max1.01m/s

A: 0.81 m/sA --- m/s

---

---End Of The Report---



Dr. GURU PRASAD B V  
MBBS, PGDCC  
69949  
Cardiology

---

Patient Name	: Mr. NAGARAJU M C	Age	: 54Yrs 9Mths 16Days
UHID	: CMYS.0000058479	OP Visit No.	: CMYSOPV131285
Printed On	: 10-11-2024 03:58 AM	Advised/Pres Doctor	: --
Department	: Cardiology	Qualification	: --
Referred By	: Self	Registration No.	: --
Employer Id	: 22E38056		

## DEPARTMENT OF CARDIOLOGY

Observation :-

1. Sinus Rhythm.
2. Heart rate is 81 beats per minutes.

**Impression:**

NORMAL RESTING ECG.

---End Of The Report---



Dr. GURU PRASAD B V  
MBBS, PGDCC  
69949  
Cardiology



Name : Mr. NAGARAJU M C

Address : Mysore Mysore Karnataka INDIA 570001

Plan : ARCOFEMI MEDIWHEEL MALE AHC CREDIT  
PAN INDIA OP AGREEMENT

Age: 54Y 9M 14D  
sex: Male  
Ht → 169  
Wt → 86.1  
Bp → 120/90

UHID : CMYS.000058479



CMYS.000058479

OP No: CMYSOPV131285

Bill No: CMYS-OCR-24648

Date: Nov 9th, 2024, 8:10 AM

Sno.	Service Type/Service Name	Department	
1	ARCOFEMI - MEDIWHEEL - FULL BODY ANNUAL PLUS ABOVE 50Y MALE - 2D ECHO - PAN INDIA - FY2324		
1	DENTAL CONSULTATION	Consultation	<input type="checkbox"/>
2	PROSTATIC SPECIFIC ANTIGEN (PSA TOTAL)	Biochemistry	<input type="checkbox"/>
3	THYROID PROFILE (TOTAL T3, TOTAL T4, TSH)	Biochemistry	<input type="checkbox"/>
4	HbA1c, GLYCATED HEMOGLOBIN	Biochemistry	<input type="checkbox"/>
5	ULTRASOUND - WHOLE ABDOMEN	Ultrasound Radiology	<input type="checkbox"/>
6	OPTICAL BY GENERAL PHYSICIAN	Consultation	<input type="checkbox"/>
7	ENT CONSULTATION → P	Consultation	<input type="checkbox"/>
8	DIET CONSULTATION → P	Consultation	<input type="checkbox"/>
9	FITNESS BY GENERAL PHYSICIAN → P	Consultation	<input type="checkbox"/>
10	2 D ECHO → P	Cardiology	<input type="checkbox"/>
11	X-RAY CHEST PA	X Ray Radiology	<input type="checkbox"/>
12	EKG	Cardiology	<input type="checkbox"/>
13	BODY MASS INDEX (BMI)	General	<input type="checkbox"/>
14	BLOOD GROUP ABO AND RH FACTOR	Blood Bank	<input type="checkbox"/>
15	COMPLETE URINE EXAMINATION	Clinical Pathology	<input type="checkbox"/>
16	HEMOGRAM + PERIPHERAL SMEAR	Haematology	<input type="checkbox"/>
17	RENAL PROFILE/RENAL FUNCTION TEST (RFT/KFT)	Biochemistry	<input type="checkbox"/>
18	GAMMA GLUTAMYL TRANSFERASE (GGT)	Biochemistry	<input type="checkbox"/>
19	LIVER FUNCTION TEST (LFT)	Biochemistry	<input type="checkbox"/>
20	LIPID PROFILE	Biochemistry	<input type="checkbox"/>
21	URINE GLUCOSE(POST PRANDIAL)	Clinical Pathology	<input type="checkbox"/>
22	URINE GLUCOSE(FASTING)	Clinical Pathology	<input type="checkbox"/>
23	GLUCOSE, POST PRANDIAL (PP), 2 HOURS (POST MEAL)	Biochemistry	<input type="checkbox"/>
24	GLUCOSE, FASTING	Biochemistry	<input type="checkbox"/>


## CERTIFICATE OF MEDICAL FITNESS

This is to certify that I have conducted the clinical examination

of Mr Nagaraju - MC on 09/12/25

After reviewing the medical history and on clinical examination it has been found that he/she is

	Tick
<ul style="list-style-type: none"> <li>• Medically Fit</li> </ul>	✓
<ul style="list-style-type: none"> <li>• Fit with restrictions/recommendations</li> </ul> <p>Though following restrictions have been revealed, in my opinion, these are not impediments to the job.</p> <p>1.....</p> <p>2.....</p> <p>3.....</p> <p>However the employee should follow the advice/medication that has been communicated to him/her.</p> <p>Review after _____</p>	
<ul style="list-style-type: none"> <li>• Currently Unfit. Review after _____ recommended</li> <li>• Unfit</li> </ul>	

Dr.   
Medical Officer

**Apollo Clinic**  
# 23, 1st Floor,  
Kannasa Road, Mysore - 02  
Ph : 0821-4006040/41

*This certificate is not meant for medical/legal purposes*

**Apollo Health and Lifestyle Limited**

(CIN - U85110TG2000PLC115819)

Regd. Office: 1-10-60/62, Ashoka Raghupathi Chambers, 5th Floor, Begumpet, Hyderabad, Telangana - 500 016.


Ph No: 040-4904 7777, Fax No: 4904 7744 | Email ID: enquiry@apollohl.com | www.apollohl.com

**APOLLO CLINICS NETWORK KARNATAKA**

Bangalore (Basavanagudi | Bellandur | Electronic City | Fraser Town | HSR Layout | Indira Nagar | JP Nagar | Kundalahalli | Koramangala | Sarjapur Road) Mysore (VV Mohalla)

Online appointments: www.apolloclinic.com

TO BOOK AN APPOINTMENT

 **1860 500 7788**

[Phy]

Mr. Nagaraju M C  
54yrs / Male

Height : 169 cm	Weight : 86 kg	BMI :	Waist Circum :
Temp :	Pulse : 74	Resp : 20/min	B.P : 120/90

General Examination /  
Allergies History

Wx  
Rx  
Sx / Wx

Clinical Diagnosis & Management Plan

Adv

Regular Exercise / Dieting

→ Bontamine plus (15)  
210

Follow up date :

  
Doctor Signature

**Apollo Clinic**  
# 23, 1st Floor,  
Kaldasa Road, Mysore - 02  
Ph : 0821-4006040/41

(ENT)

Date : 11/9/2024 Department : ENT  
Patient Name : Mr. NAGARAJU M C Doctor : Dr. PRAVEEN KUMAR R  
UHID : CMYS.0000058479 Registration No. : 66012  
Age / Gender : 54Yrs 9Mths 14Days/ Male Qualification : MBBS, MS (ENT)  
Consulation Timing : 1:36 PM

Height :	Weight :	BMI :	Waist Circum :
Temp :	Pulse :	Resp :	B.P :

General Examination /  
Allergies History

Clinical Diagnosis & Management Plan

Came for regular checkup

Eor - Bilateral TM - (a)

Nose - nasal mucosa (a)

oral cavity & oropharynx - (a)

neck (a)

As  
examined

Follow up date :

Doctor Signature

**Apollo Clinic**  
# 23, 1st Floor,  
Kalidasa Road, Mysore - 02  
Ph : 0821-4006040/41

(Dental)

Date : 11/9/2024 Department : Dental  
 Patient Name : Mr. NAGARAJU M C Doctor : Dr. JYOTHISHREE P V  
 UHID : CMYS.0000058479 Registration No. : 33268A  
 Age / Gender : 54Yrs 9Mths 14Days/ Male Qualification : B.D.S[Bachelor of Dental Surgery]  
 Consultation Timing : 1:35 PM

Height :	Weight :	BMI :	Waist Circum :
Temp :	Pulse :	Resp :	B.P :

General Examination / Allergies History

Clinical Diagnosis & Management Plan

5/7 missing

ADULT Replacement

76 / 6

HLB RCT + crown

Isokhas

Follow up date :

Doctor Signature

**Apollo Clinic**  
 # 23, 1st Floor,  
 Kalidasa Road, Mysore - 02  
 Ph : 0821-4006040/41

Date : 11/9/2024 Department : General Practice  
 Patient Name : Mr. NAGARAJU M C Doctor : Dr.SUJATHA T R  
 UHID : CMYS.0000058479 Registration No. : 69649  
 Age / Gender : 54Yrs 9Mths 14Days/ Male Qualification : MBBS, PGDMCH  
 Consultation Timing : 1:36 PM

Height :	Weight :	BMI :	Waist Circum :
Temp :	Pulse :	Resp :	B.P :

General Examination /  
Allergies History

Clinical Diagnosis & Management Plan

Distance vision

Near vision

Colour vision

un  $\left\{ \begin{array}{l} 6/12 \\ 6/18 \end{array} \right.$   $\bar{e}$  glasses  $\left\{ \begin{array}{l} 6/6 \\ 6/6 \end{array} \right.$   
 $\bar{e}$  p H  $\left\{ \begin{array}{l} 6/6 \\ 6/6 \end{array} \right.$

N 10

(CV) = normal

Sub

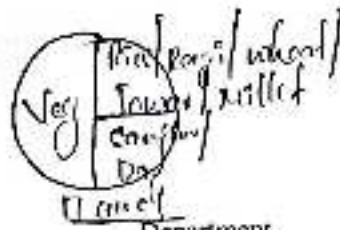
R = -1.50 Sp / -1.00 x 90°

L = -1.50 Sp / -1.00 x 120°

- Add +2.50 Sp (BE)

Doctor Signature

Follow up date : 09/11/24



Date : 11/9/2024 Department : Nutrition & Dietetics  
 Patient Name : Mr. NAGARAJU M C Doctor : Miss.MADHURA B P  
 UHID : CMYS.0000058479 Registration No. : A104102  
 Age / Gender : 54 Yrs 9Mths 14Days/ Male Qualification : M.Sc. Nutrition and Dietetics  
 Consultation Timing : 1:36 PM Ph.D<sup>M</sup>

T.B.W - 69 kg

Height : 169 cm	Weight : 86 kg	BMI : 30 kg/m <sup>2</sup>	Waist Circum :
Temp :	Pulse :	Resp :	B.P :

**General Examination / Allergies History**

**Clinical Diagnosis & Management Plan**

HbA1c - 6.2 %  
 Triglycerides - 259  
 Non HDL - 156  
 LDL - 105.24  
 VLDL - 50.36

- Δ<sup>cl</sup> - Grade I Fatty liver, cholelithiasis.
- Advised low fat diabetic diet with fiber rich foods.
- Take small frequent meals. Do not skip meals.
- Include all variety of seasonal fruits, vegetables & green leafy vegetables.
- \* Avoid fruits like Mango, Papaya, Jackfruit, custard apple & Big banana.
- \* Avoid root vegetables like potato, sweet potato, Yam & Arbi.
- Include nuts like Almonds & walnuts daily.
- Drink 12-14 big glasses of water.
- Regular physical exercise is compulsory.

Follow up date :

Doctor Signature

*[Signature]*  
 9/11/2024

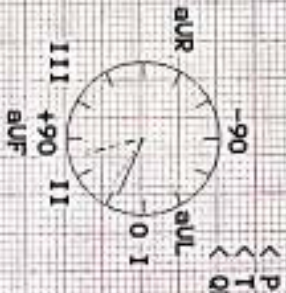
**Apollo Clinic**  
 # 23, 1st Floor,  
 Kalidasa Road, Mysore - 02  
 Ph : 0821-4006040/41

AGE: 54

NO:

Measurement Results:

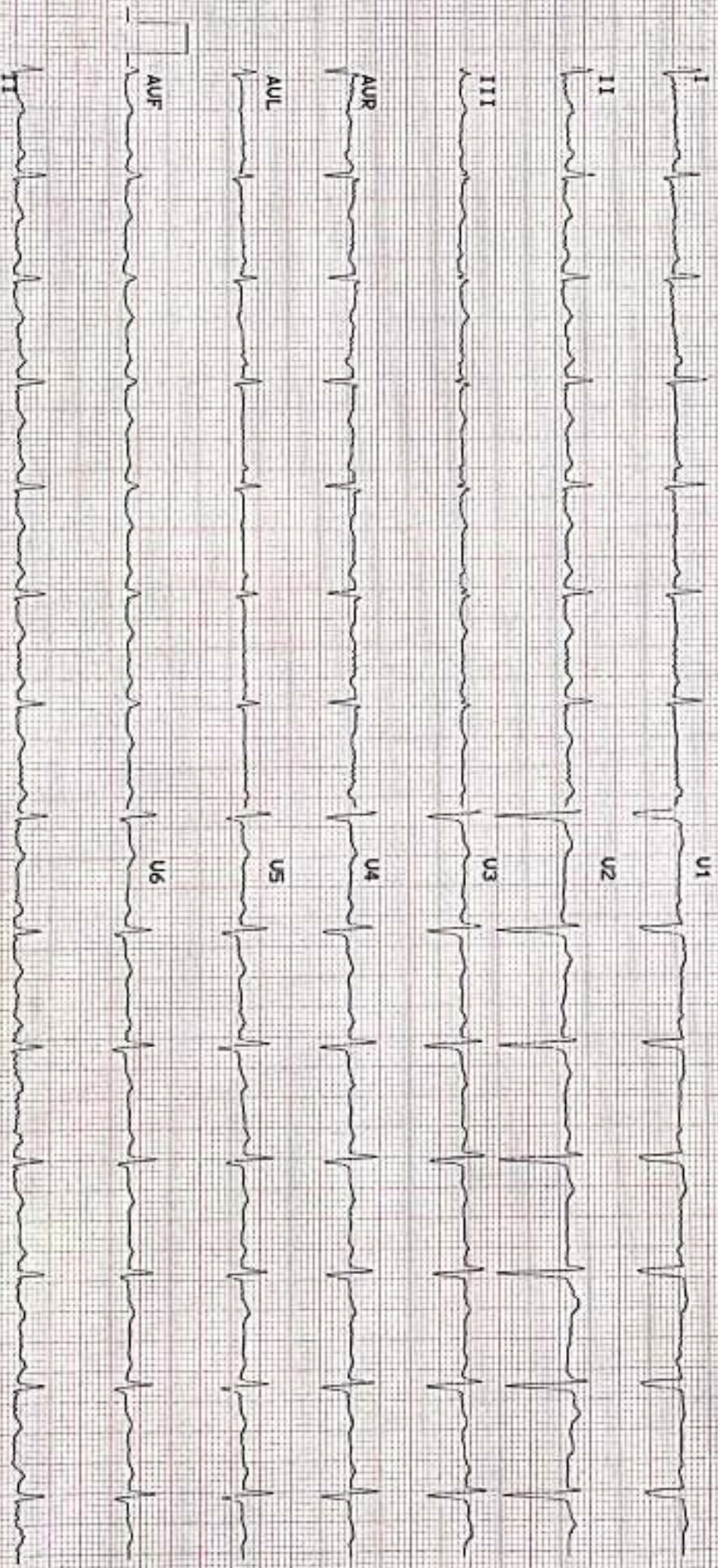
QRS	100 ms
QT/QTcB	376 / 438 ms
PR	168 ms
P	118 ms
RR/PP	736 / 750 ms
P/QRS/T	35 / 25 / 75 degrees
QTd/QTcBd	46 / 54 ms
Sokolow	1.1 mV
NK	11



Interpretation:

**Apollo Clinic**  
# 23, 1st Floor,  
Kajidasa Road, Mysore - 02  
Ph : 0821-4006040/41

Unconfirmed report.





Patient Name	: Mr. NAGARAJU M C	Age	: 54Yrs 9Mths 14Days
UHID	: CMYS.0000058479	OP Visit No.	: CMYSOPV131285
Printed On	: 09-11-2024 12:44 PM	Advised/Pres Doctor	: --
Department	: Radiology	Qualification	: --
Referred By	: Self	Registration No.	: --
Employer Id	: 22E38056		

**DEPARTMENT OF RADIOLOGY**

Lung fields are clear.

Cardio thoracic ratio is normal.

Apices, costo and cardio phrenic angles are free.

Cardio vascular shadow and hila show no abnormal feature.

Bony thorax shows no significant abnormality.

Domes of diaphragm are well delineated.

**IMPRESSION: NORMAL STUDY .**

---End Of The Report---



**Dr. CHETAN HOLEPPAGOL**  
**MBBS, DNB(RADIO DIAGNOSIS)**  
**90037**  
**Radiology**

Patient Name: Mr. NAGARAJU M C	Date: 09.11.2024	Referring Doctor: Self
Age / Sex : 54yrs /Male	UHID :58479	
<b>ULTRASONOGRAPHY – ABDOMEN &amp; PELVIS</b>		

**LIVER:** It is normal in size, outline and is increased in echotexture. No focal lesions seen. IHBR are not dilated. CBD and Portal vein are normal.

**GALL BLADDER:** It is distended with evidence of a echogenic small calculus measuring ~5.5mm noted within the lumen

**SPLEEN:** It is normal in size, outline and echopattern. No e/o focal lesions.

**PANCREAS:** It is normal in size, outline and echopattern.

**RIGHT KIDNEY:** It measures 9.6 cm with parenchymal thickness of 1.4 cm. It is normal in size, outline and echotexture. No e/o calculus or hydronephrosis seen. A simple large exophytic cystic lesion measuring ~ 5.5 x 3.9 cm is noted in lower pole cortex of right kidney

**LEFT KIDNEY:** It measures 9.5cm with parenchymal thickness of 1.5 cm. It is normal in size, outline and echotexture. No e/o calculus or hydronephrosis seen.


**URINARY BLADDER:** It is well distended. The UB wall is normal. No e/o calculi.

**PROSTATE:** It is mildly enlarged (measures~26cc) with normal echotexture.

No e/o free fluid in the abdomen.

**IMPRESSION:**

Grade I fatty liver  
Cholelithiasis .No features of cholecystitis  
Large exophytic simple right renal cyst  
Grade I prostatomegaly



Dr. Karthik H V MDRD , DNB  
Consultant Radiologist.

**Apollo Health and Lifestyle Limited**

ICIN: URS110TG2000PLC1158191

Regd. Office: 1-10/60-62, Ashoka Raghupathi Chambers, 5th Floor, Begumpet, Hyderabad, Telangana - 500 016


Ph. No: (040) 4904 7777, Fax No: 4904 7744 | Email ID: enquiry@apollohi.com | www.apollohi.com

**APOLLO CLINICS NETWORK KARNATAKA**

Bangalore | Saravanagudi | Bellandur | Electronic City | Fraser Town | HSR Layout | Indira Nagar | JP Nagar | Kundalahalli | Koramangala | Sarjapur Road | Mysore (VV Mohalla)

Online appointments: www.apolloclinic.com

TO BOOK AN APPOINTMENT

 **1860 500 7788**

Patient's Name : Mr. Nagaraju	Age & Sex; 54Yrs /Male
Date : 09.11.2024	UHID No:

## 2D ECHOCARDIOGRAPHY STUDY

### Impression:

- Normal chambers and valves
- Mild MR/ PR
- No regional wall motion abnormality
- Normal left ventricular systolic function. EF 60 %
- Grade I LVDD
- No clots. No pericardial effusion

### Findings

Left Ventricle:	No RWMA
Right Ventricle	Normal
Left Atrium	Normal
Right Atrium	Normal
Aorta	Normal
Pulmonary Artery	Normal
IAS	Intact
IVS	Intact
Valves	Normal
Pericardium	Normal
Doppler	Grade I LVDD. Mild MR/ PR

#### Apollo Health and Lifestyle Limited

City: UAS110752/00PLC1158197

Regd Office: 1-10-60-62, Ashoka Rajghatpath Chambers, 5th Floor, Begumpet, Hyderabad, Telangana - 500 016

Ph No: 040-4904 7777 Fax No: 4904 7744 | Email ID: enquiry@apolloh.com | www.apolloh.com

#### APOLLO CLINICS NETWORK KARNATAKA

Bangalore | Bannerghatta | Bellandur | Electronic City | Frazer Town | HSR Layout | Indira Nagar | JP Nagar | Kundalahalli |

Koramangala | Sarjapur Road | Mysore (VV Mahallal)

Online appointments: www.apolloh.com

TO BOOK AN APPOINTMENT

**1860 500 7788**


Patient's Name : Mr. Nagaraju	Age & Sex; 54Yrs /Male
Date : 09.11.2024	UHID No:

Measurements

AO : 2.8 cm  
LA : 2.6 cm

RV : 2.5 cm  
LVIDd : 4.70 cm  
LVIDs : 3.17 cm  
IVSd : 0.76 cm  
IVSs : 1.21 cm  
PWd : 1.05 cm  
PWs : 1.37 cm  
EF : 60.0 %  
FS : 32.0 %

Doppler  
MV TV AV PV  
E 0.52 m/s E --- m/s V max 1.01 m/s V max 1.01 m/s  
:  
A: 0.81 m/s A --- m/s



**Dr. GURU PRASAD. B. V, MBBS, PGDCC**  
**CONSULTANT - NON-INVASIVE CARDIOLOGY**

Apollo Health and Lifestyle Limited

CIN: U65110TG2000PLC1158191

Keya Office: 1-10-60-62, Ashoka Raghupathi Chambers, 5th Floor, Begumpet, Hyderabad, Telangana - 500 016

Ph No: (91) 4104 7777 Fax No: 4104 7744 | Email ID: enquiry@apolohl.com | www.apolohl.com

APOLLO CLINICS NETWORK KARNATAKA

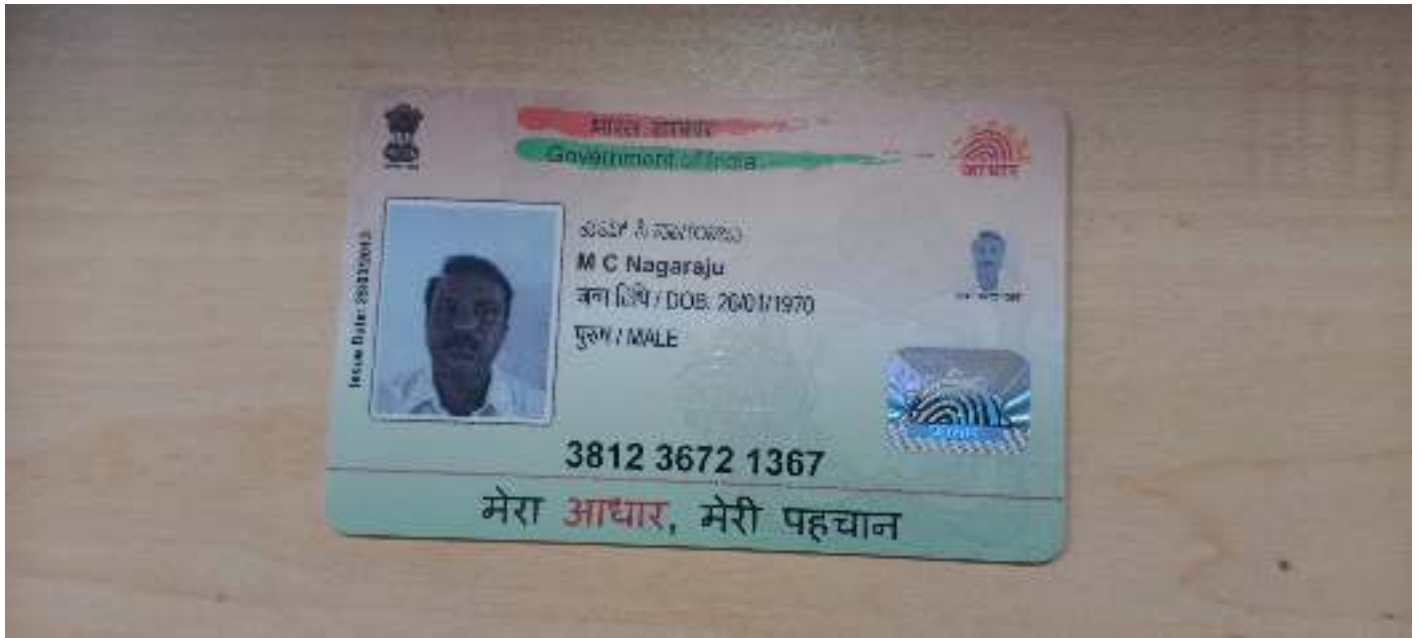Bangalore (Basavanagudi) | Bellandur | Electronic City | Fraser Town | MSR Layout | Indira Nagar | JP Nagar | Kundalahalli |

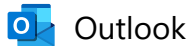
Yarimanjala | Sarjapur Road | Mysore (Vy Mohalla)

Online appointments: www.apolloclinic.com

TO BOOK AN APPOINTMENT

**1860 500 7788**





## Your appointment is confirmed

**From** noreply@apolloclinics.info <noreply@apolloclinics.info>

**Date** Fri 08-11-2024 13:32

**To** m.nagaraju@bankofbaroda.com <m.nagaraju@bankofbaroda.com>

**Cc** Mysore Apolloclinic <mysore@apolloclinic.com>; Yogeesh KV <mkt.mysore@apolloclinic.com>; Syamsunder M <syamsunder.m@apollohl.com>



**Dear MR. M C NAGARAJU,**

Greetings from Apollo Clinics,

Your corporate health check appointment is confirmed at **KALIDASA RAOD clinic** on **2024-11-09** at **08:15-08:30**.

Payment Mode	
Corporate Name	<b>ARCOFEMI HEALTHCARE LIMITED</b>
Agreement Name	<b>[ARCOFEMI MEDIWHEEL MALE AHC CREDIT PAN INDIA OP AGREEMENT]</b>
Package Name	<b>[ARCOFEMI - MEDIWHEEL - FULL BODY ANNUAL PLUS ABOVE 50Y MALE - 2D ECHO - PAN INDIA - FY2324]</b>

**"Kindly carry with you relevant documents such as HR issued authorization letter and or appointment confirmation mail and or valid government ID proof and or company ID card and or voucher as per our agreement with your company or sponsor."**

**Note: Video recording or taking photos inside the clinic premises or during camps is not allowed and would attract legal consequences.**

**Note: Also once appointment is booked, based on availability of doctors at clinics tests will happen, any pending test will happen based on doctor availability and clinics will be updating the same to customers.**

**Instructions to be followed for a health check:**

1. Please ensure you are on complete fasting for 10-To-12-Hours prior to check.
2. During fasting time do not take any kind of alcohol, cigarettes, tobacco or any other liquids (except Water) in the morning. If any medications taken, pls inform our staff before health check.

3. Please bring all your medical prescriptions and previous health medical records with you.
4. Kindly inform our staff, if you have a history of diabetes and cardiac problems.

**For Women:**

1. Pregnant women or those suspecting are advised not to undergo any X-Ray test.
2. It is advisable not to undergo any health check during menstrual cycle.

**For further assistance, please call us on our Help Line #: 1860 500 7788.**

**Clinic Address: 23, KALIDASA ROAD, VV MOHLLA, MYSORE.**

**Contact No: (0821) 400 6040 - 41.**

P.S: Health Check-Up may take 4 - 5hrs for completion on week days & 5 - 6hrs on Saturdays, kindly plan accordingly, Doctor Consultation will be completed after all the Reports are ready.

Warm Regards,  
Apollo Clinic