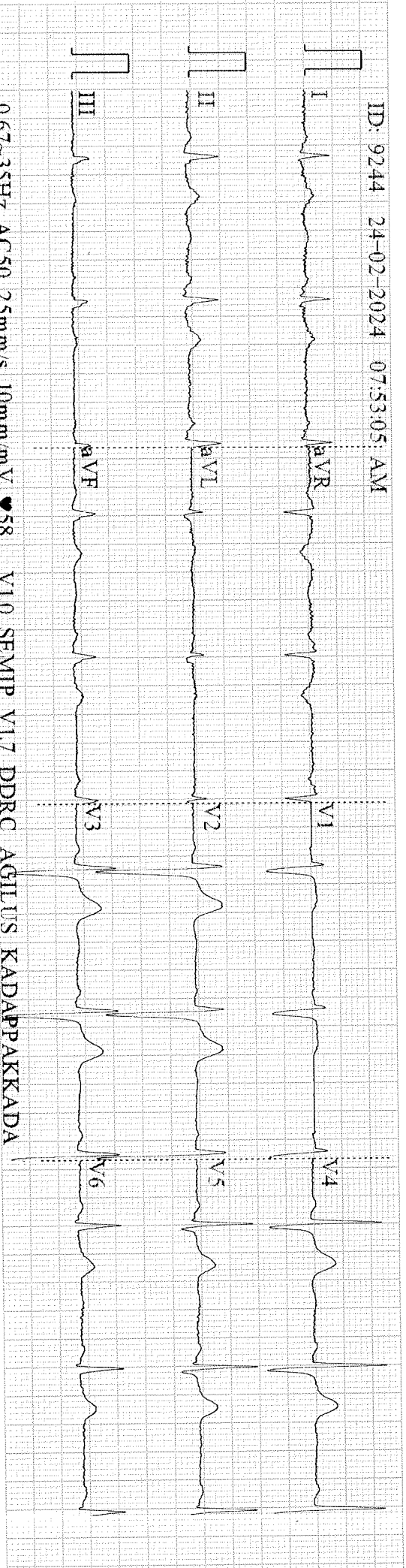


ID: 9244 24-02-2024 07:53:05 AM



0.67~35Hz AC50 25mm/s 10mm/mV 58 V1.0 SEMIP V1.7 DDRC AGILUS KADAPPAKADA

Armed CE

If the examinee is suffering from an acute life threatening situation, you may be obliged to disclose the result of the medical examination to the examinee.

1. Name of the examinee	: Mr./Mrs./Ms. BINU MURALI
2. Mark of Identification	: (Mole/Scar/any other (specify location)):
3. Age/Date of Birth	: 35, 28-06-1989 Gender: F/M - Male
4. Photo ID Checked	: (Passport/Election Card/PAN Card/Driving Licence/Company ID) LICCOSE

PHYSICAL DETAILS:

a. Height 185 (cms)	b. Weight 81 (Kgs)	c. Girth of Abdomen 98 (cms)
d. Pulse Rate 71 (/Min)	e. Blood Pressure:	Systolic 120 Diastolic 80
		1 st Reading
		2 nd Reading

FAMILY HISTORY:

Relation	Age if Living	Health Status	If deceased, age at the time and cause
Father	63	Healthy	
Mother	60	Healthy	
Brother(s)	37	Healthy	
Sister(s)			

HABITS & ADDICTIONS: Does the examinee consume any of the following?

Tobacco in any form	Sedative	Alcohol

PERSONAL HISTORY

- a. Are you presently in good health and entirely free from any mental or Physical impairment or deformity. If No, please attach details. **Y/N**
- b. Have you undergone/been advised any surgical procedure? **Y/N**
- c. During the last 5 years have you been medically examined, received any advice or treatment or admitted to any hospital? **Y/N**
- d. Have you lost or gained weight in past 12 months? **Y/N**

Have you ever suffered from any of the following?

- Psychological Disorders or any kind of disorders of the Nervous System? **Y/N**
- Any disorders of Respiratory system? **Y/N**
- Any Cardiac or Circulatory Disorders? **Y/N**
- Enlarged glands or any form of Cancer/Tumour? **Y/N**
- Any Musculoskeletal disorder? **Y/N**
- Any disorder of Gastrointestinal System? **Y/N**
- Unexplained recurrent or persistent fever, and/or weight loss **Y/N**
- Have you been tested for HIV/HBsAg / HCV before? If yes attach reports **Y/N**
- Are you presently taking medication of any kind? **Y/N**

To whomsoever concerned,

Mr Binu Murali, 34 yr old male was examined at our hospital on 24/2/24.

On examination his vision was $6/6$, N_6 in both eyes, colour vision $20/21$ in right eye & $18/21$ in left eye. Ocular examination found to be normal, IOP - 12 mm of Hg in both eyes and undilated fundus examination also found to be normal.

Thanking You.

Yours faithfully

Dr Haripriya



24/2/24

Dr. HARIPRIYA.H
MBBS, MS - OPHTHALMOLOGY
TCMC Reg. No: 44880

Chaithanya Eye Hospital & Research Institute
Prathibha Junction, Kadappakkada, Kollam - 691008

From

Binu Murali (E/o Athira A. Choudhary)

To,

MediWheel

I am giving a consent to avoid
testing of Motion & TMT.



Binu Murali

NAME	AGE/ SEX	DATE
BINU MURALI	34/M	24.02.2024

X-RAY- CHEST WITH REPORT

CHEST X RAY : NORMAL

Impression : **Within radiological limits**

R. Intal prominence

Dr. Akhila Sekhar MBBS.MD
Consultant Pathologist
Reg.No. 55174



DR AKHILA SEKHAR

MBBS, MD

CONSULTANT PATHOLOGIST

* Any disorders of Urinary System?

Y/N ✓

* Any disorder of the Eyes, Ears, Nose, Throat or Mouth & Skin

Y/N

FOR FEMALE CANDIDATES ONLY

a. Is there any history of diseases of breast/genital organs?

Y/N

d. Do you have any history of miscarriage/ abortion or MTP

Y/N

b. Is there any history of abnormal PAP Smear/Mamimogram/USG of Pelvis or any other tests? (If yes attach reports)

Y/N

e. For Parous Women, were there any complication during pregnancy such as gestational diabetes, hypertension etc

Y/N

c. Do you suspect any disease of Uterus, Cervix or Ovaries?

Y/N

f. Are you now pregnant? If yes, how many months?

Y/N

CONFIDENTIAL COMMENTS FROM MEDICAL EXAMINER

➤ Was the examinee co-operative?

Y/N

➤ Is there anything about the examinee's health, lifestyle that might affect him/her in the near future with regard to his/her job?

Y/N

➤ Are there any points on which you suggest further information be obtained?

Y/N

➤ Based on your clinical impression, please provide your suggestions and recommendations below;

.....
.....
.....

➤ Do you think he/she is **MEDICALLY FIT** or **UNFIT** for employment.

fit

MEDICAL EXAMINER'S DECLARATION

I hereby confirm that I have examined the above individual after verification of his/her identity and the findings stated above are true and correct to the best of my knowledge.


Name & Signature of the Medical Examiner :

DR AKHILA SEKSHAR Akhila

Seal of Medical Examiner :

Dr. Akhila Sekhar MBBS.MD
Consultant Pathologist
Reg.No. 55174

Name & Seal of DDRC SRL Branch :



Date & Time :

24/2/2024 12:48 pm

DDRC agilus Pathlabs Limited.

Corp. Office : Express House, Second Floor, Opp. Pothys Silks, Banerjee Road, Kaloor -682017

Contact :- 93334 93334, Web :- www.ddrcagilus.com Email :- info.ddrc@agilus.in

NAME : BINU MURALI	AGE/ SEX : 34 /M	24.02.2024
--------------------	------------------	------------

ELECTRO CARDIOGRAM REPORT

ELECTRO CARDIOGRAM


: NSR - ⁶²...../minute. No evidence of ischaemia or chamber hypertrophy.

Impression

: ECG with in normal limits.

ECG inferior P axis & V1-V3

Dr Akhila Sekhar MBBS.MD
Consultant Pathologist
Reg.No. 55174


DR AKHILA SEKHAR
MBBS, MD

CONSULTANT PATHOLOGIST

RADIOLOGY DIVISION

Name : Mr. Binu Murali	Age : 34 yrs	Sex: M	
Ref. from. Mediwheel Arcofemi			Date : 24.02.2024

USG OF ABDOMEN

(Technical consideration : Poor sonological window)

LIVER: Is normal in size (14.7 cms). *Echotexture is increased uniformly through out of liver, suggestive of fatty changes.* No focal lesions are seen. No dilatation of intra-hepatic biliary radicles present. Portal vein is normal. Common bile duct is normal.

GALL BLADDER: Is distended. Normal in wall thickness. No calculus or mass.

PANCREAS: Visualized head and body appears normal. Rest obscured by bowel gas

SPLEEN: Is normal in size (8.7 cms) and echotexture.

RIGHT KIDNEY: Measures 10.7 x 3.4 cms. Normal in size and echotexture. Cortico medullary differentiation is well maintained. No calculus, hydronephrosis or mass.

LEFT KIDNEY: Measures 10.6 x 4.9 cms. Normal in size and echotexture. Cortico medullary differentiation is well maintained. No calculus, hydronephrosis or mass.

URINARY BLADDER: Is distended. Normal in wall thickness. No evidence of calculus or mass. No vesical diverticulum present.

PROSTATE: Is normal in size (volume - 15.6 cc). Parenchymal echoes normal.

No ascites present. No retroperitoneal lymphadenopathy present.

Both iliac fossae appear normal and there is no obvious evidence of bowel mass or bowel wall thickening present.

IMPRESSION:

❖ *Grade I fatty infiltration of liver.*

- Suggested follow up & clinical correlation.
- Images overleaf.

DR. AISALUTH THULASEEDHARAN
MBBS, DMRD

(Note: Diagnosis should not be made solely on one investigation. Advised further / repeat investigation and clinical correlation in suspected cases and in case of unexpected results, ultrasound is not 100% accurate and this report is not valid for medico legal purpose)

MSK Report

Patient ID : 24_02_2024_11_12_17

Sex : M

Age :

Patient Name : BINU

Study Date : 24/02/2024

Referring MD :

Performing MD :

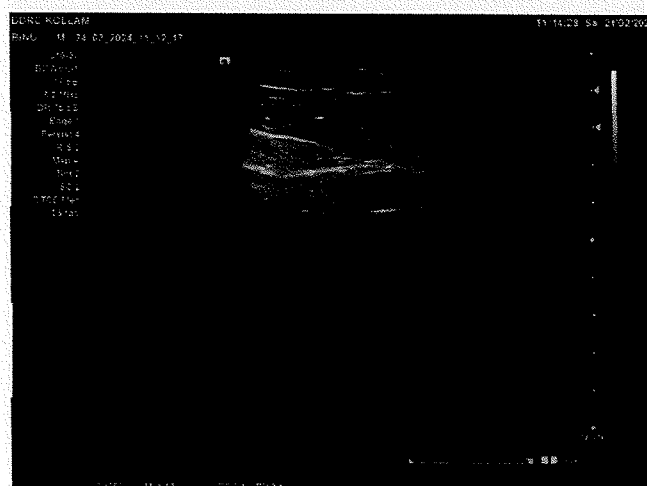
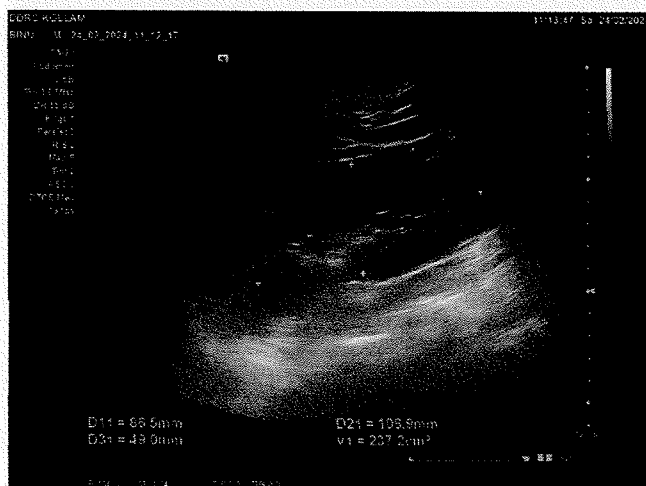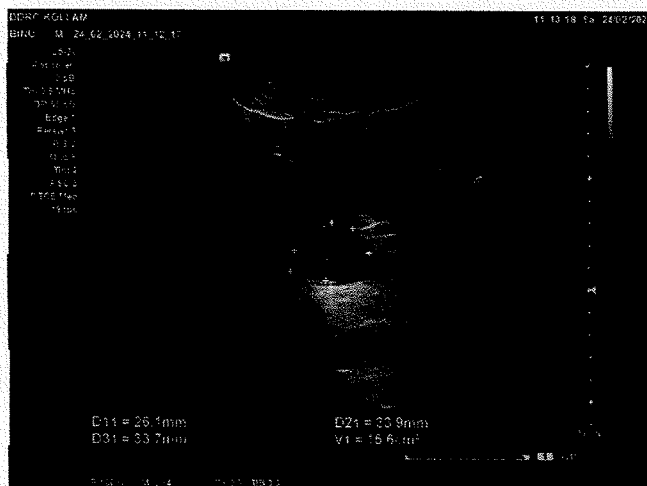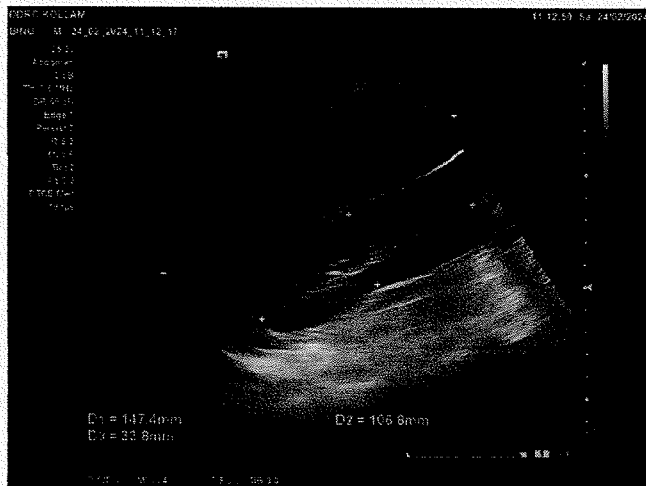Sonographer :

Indication :

Exam Type : MSK

Height :

Weight :



Signature _____

ID: 9244

Diagnosis Information:

Male

mmHg

34 Years

cm

kg

Binu Musali 34y/m

24 / 02 / 24

HR

62

bpm

P

116

ms

PR

149

ms

QRS

107

ms

QT/QTc

421/429 ms

P/QRS/T

47/67/43

RV5/SV1

1.033/0.773 mV

Musali

Report Confirmed by:

Amr W. CE

PATIENT NAME : BINU MURALI

REF. DOCTOR : SELF

CODE/NAME & ADDRESS : CA00010147 -

MEDIWHEEL ARCOFEMI HEALTHCARE LIMITED
 F701A, LADO SARAI, NEW DELHI,SOUTH DELHI,
 DELHI,
 SOUTH DELHI 110030
 8800465156

ACCESSION NO : 4071XB005731

PATIENT ID : BINUM2806894071

CLIENT PATIENT ID: 144764

ABHA NO :

AGE/SEX : 34 Years Male

DRAWN :

RECEIVED : 24/02/2024 07:29:21

REPORTED : 24/02/2024 15:16:49

Test Report Status	Final	Results	Biological Reference Interval	Units
--------------------	-------	---------	-------------------------------	-------

MEDIWHEEL HEALTH CHEKUP BELOW 40(M)TMT

OPHTHAL

OPHTHAL TEST COMPLETED

PHYSICAL EXAMINATION

PHYSICAL EXAMINATION TEST COMPLETED

**JIBI J
 LAB TECHNOLOGIST**



View Details



View Report

PERFORMED AT :

DDRC AGILUS PATHLABS LIMITED
 Phoenix Tower, Near Central Park Hotel,
 Prathibha Junction, Kadappakada,
 KOLLAM, 691008
 KERALA, INDIA
 Tel : 93334 93334
 Email : customercare.ddrc@agilus.in



Patient Ref. No. 66600007974415

PATIENT NAME : BINU MURALI

REF. DOCTOR : SELF

CODE/NAME & ADDRESS : CA00010147 -

MEDIWHEEL ARCOFEMI HEALTHCARE LIMITED
F701A, LADO SARAI, NEW DELHI,SOUTH DELHI,
DELHI,
SOUTH DELHI 110030
8800465156ACCESSION NO : **4071XB005731**

PATIENT ID : BINUM2806894071

CLIENT PATIENT ID: 144764

ABHA NO :

AGE/SEX : 34 Years Male

DRAWN :

RECEIVED : 24/02/2024 07:29:21

REPORTED : 24/02/2024 15:16:49

Test Report Status **Final**

Results

Units

MEDIWHEEL HEALTH CHEKUP BELOW 40(M)TMT**ECG WITH REPORT****REPORT**

REPORTED

USG ABDOMEN AND PELVIS**REPORT**

Reported

CHEST X-RAY WITH REPORT**REPORT**

REPORTED

HAEMATOLOGY**MEDIWHEEL HEALTH CHEKUP BELOW 40(M)TMT****GLYCOSYLATED HEMOGLOBIN(HBA1C), EDTA WHOLE BLOOD**

HBA1C	5.4	Normal	: 4.0 -	%
		5.6%.		
		Non-diabetic level	: < 5.7%.	
		Diabetic	: >6.5%	

Glycemic control goal
More stringent goal : < 6.5 %.
General goal : < 7%.
Less stringent goal : < 8%.

Glycemic targets in CKD :-
If eGFR > 60 : < 7%.
If eGFR < 60 : 7 - 8.5%.

MEAN PLASMA GLUCOSE	108.3	< 116.0	mg/dL
---------------------	-------	---------	-------

JIBI J
LAB TECHNOLOGISTDR.KARTHIKA RAMANATHAN, M.D
Pathology
(Reg No - TCMC 53950)
CONSULTANT PATHOLOGISTSHILPA B L
LAB TECHNOLOGIST

View Details



View Report

Page 2 Of 8

PERFORMED AT :DDRC AGILUS PATHLABS LIMITED
Phoenix Tower, Near Central Park Hotel,
Prathibha Junction, Kadappakada,
KOLLAM, 691008
KERALA, INDIA
Tel : 93334 93334
Email : customercare.ddrc@agilus.in

Patient Ref. No. 66600007974415

PATIENT NAME : BINU MURALI

REF. DOCTOR : SELF

CODE/NAME & ADDRESS : CA00010147 -

MEDIWHEEL ARCOFEMI HEALTHCARE LIMITED
F701A, LADO SARAI, NEW DELHI, SOUTH DELHI,
DELHI,
SOUTH DELHI 110030
8800465156

ACCESSION NO : 4071XB005731

PATIENT ID : BINUM2806894071

CLIENT PATIENT ID: 144764

ABHA NO :

AGE/SEX : 34 Years Male

DRAWN :

RECEIVED : 24/02/2024 07:29:21

REPORTED : 24/02/2024 15:16:49

Test Report Status **Final**

Results

Units

BLOOD COUNTS, EDTA WHOLE BLOOD

HEMOGLOBIN	15.9	13.0 - 17.0	g/dL
RED BLOOD CELL COUNT	5.55 High	4.5 - 5.5	mil/ μ L
WHITE BLOOD CELL COUNT	5.60	4.0 - 10.0	thou/ μ L
PLATELET COUNT	231	150 - 410	thou/ μ L

RBC AND PLATELET INDICES

HEMATOCRIT	49.5	40 - 50	%
MEAN CORPUSCULAR VOL	89.2	83 - 101	fL
MEAN CORPUSCULAR HGB.	28.7	27.0 - 32.0	pg
MEAN CORPUSCULAR HEMOGLOBIN CONCENTRATION	32.2	31.5 - 34.5	g/dL
RED CELL DISTRIBUTION WIDTH	13.1	11.6 - 14.0	%
MENTZER INDEX	16.1		
MEAN PLATELET VOLUME	9.0	6.8 - 10.9	fL

WBC DIFFERENTIAL COUNT


SEGMENTED NEUTROPHILS	62	40 - 80	%
LYMPHOCYTES	29	20 - 40	%
MONOCYTES	06	2 - 10	%
EOSINOPHILS	03	1 - 6	%
BASOPHILS	00	< 1 - 2	%
ABSOLUTE NEUTROPHIL COUNT	3.47	2.0 - 7.0	thou/ μ L
ABSOLUTE LYMPHOCYTE COUNT	1.62	1.0 - 3.0	thou/ μ L
ABSOLUTE MONOCYTE COUNT	0.34	0.2 - 1.0	thou/ μ L
ABSOLUTE EOSINOPHIL COUNT	0.17	0.02 - 0.50	thou/ μ L
ABSOLUTE BASOPHIL COUNT	00		thou/ μ L
NEUTROPHIL LYMPHOCYTE RATIO (NLR)	2.1		



DR. KARTHIKA RAMANATHAN, M.D
Pathology
(Reg No - TCMC 53950)
CONSULTANT PATHOLOGIST



SHILPA B L
LAB TECHNOLOGIST



DR. AKHILA SEKHAR, M.D
Pathology
(Reg No - TCMC 55174)
CONSULTANT PATHOLOGIST



View Details



View Report

Page 3 Of 8

PERFORMED AT :

DDRC AGILUS PATHLABS LIMITED
Phoenix Tower, Near Central Park Hotel,
Prathibha Junction, Kadappakada,
KOLLAM, 691008
KERALA, INDIA
Tel : 93334 93334
Email : customercare.ddrc@agilus.in



Patient Ref. No. 66600007974415

PATIENT NAME : BINU MURALI

REF. DOCTOR : SELF

CODE/NAME & ADDRESS : CA00010147 -

MEDIWHEEL ARCOFEMI HEALTHCARE LIMITED
F701A, LADO SARAI, NEW DELHI,SOUTH DELHI,
DELHI,
SOUTH DELHI 110030
8800465156

ACCESSION NO : 4071XB005731

PATIENT ID : BINUM2806894071

CLIENT PATIENT ID: 144764

ABHA NO :

AGE/SEX : 34 Years Male

DRAWN :

RECEIVED : 24/02/2024 07:29:21

REPORTED : 24/02/2024 15:16:49

Test Report Status **Final**

Results

Units

ERYTHROCYTE SEDIMENTATION RATE (ESR),EDTA BLOOD

SEDIMENTATION RATE (ESR)	01	0 - 14	mm at 1 hr
--------------------------	----	--------	------------

SUGAR URINE - POST PRANDIAL

SUGAR URINE - POST PRANDIAL	NOT DETECTED	NOT DETECTED
-----------------------------	--------------	--------------

SUGAR URINE - FASTING

SUGAR URINE - FASTING	NOT DETECTED	NOT DETECTED
-----------------------	--------------	--------------

IMMUNOHAEMATOLOGY**MEDIWHEEL HEALTH CHEKUP BELOW 40(M)TMT****ABO GROUP & RH TYPE, EDTA WHOLE BLOOD**

ABO GROUP	TYPE A
RH TYPE	POSITIVE

Interpretation(s)


ABO GROUP & RH TYPE, EDTA WHOLE BLOOD-Blood group is identified by antigens and antibodies present in the blood. Antigens are protein molecules found on the surface of red blood cells. Antibodies are found in plasma. To determine blood group, red cells are mixed with different antibody solutions to give A,B,O or AB.

Disclaimer: "Please note, as the results of previous ABO and Rh group (Blood Group) for pregnant women are not available, please check with the patient records for availability of the same."

The test is performed by both forward as well as reverse grouping methods.

BIO CHEMISTRY


DR.KARTHIKA RAMANATHAN, M.D
Pathology
(Reg No - TCMC 53950)
CONSULTANT PATHOLOGIST



DEVAYANI SATHEESAN
LAB TECHNOLOGIST



SHILPA B L
LAB TECHNOLOGIST

Page 4 Of 8



View Details



View Report

PERFORMED AT :

DDRC AGILUS PATHLABS LIMITED
Phoenix Tower, Near Central Park Hotel,
Prathibha Junction, Kadappakada,
KOLLAM, 691008
KERALA, INDIA
Tel : 93334 93334
Email : customercare.ddrc@agilus.in



Patient Ref. No. 66600007974415

PATIENT NAME : BINU MURALI
REF. DOCTOR : SELF
CODE/NAME & ADDRESS : CA00010147 -
MEDIWHEEL ARCOFEMI HEALTHCARE LIMITED
F701A, LADO SARAI, NEW DELHI,SOUTH DELHI,
DELHI,
SOUTH DELHI 110030
8800465156

ACCESSION NO : **4071XB005731**
PATIENT ID : BINUM2806894071
CLIENT PATIENT ID: 144764
ABHA NO :
AGE/SEX : 34 Years Male
DRAWN :
RECEIVED : 24/02/2024 07:29:21
REPORTED : 24/02/2024 15:16:49

Test Report Status	Final	Results	Units
--------------------	-------	---------	-------

MEDIWHEEL HEALTH CHEKUP BELOW 40(M)TMT
BUN/CREAT RATIO

BUN/CREAT RATIO	9.78		
-----------------	------	--	--

CREATININE, SERUM

CREATININE	0.92	18 - 60 yrs : 0.9 - 1.3	mg/dL
------------	------	-------------------------	-------

GLUCOSE, POST-PRANDIAL, PLASMA

GLUCOSE, POST-PRANDIAL, PLASMA	121	Diabetes Mellitus : > or = 200. Impaired Glucose tolerance/ Prediabetes : 140 - 199. Hypoglycemia : < 55.	mg/dL
--------------------------------	-----	--	-------


GLUCOSE FASTING,FLUORIDE PLASMA

FBS (FASTING BLOOD SUGAR)	96	Diabetes Mellitus : > or = 126. Impaired fasting Glucose/ Prediabetes : 101 - 125. Hypoglycemia : < 55.	mg/dL
---------------------------	----	--	-------

LIVER FUNCTION TEST WITH GGT

BILIRUBIN, TOTAL	0.40	General Range : < 1.1	mg/dL
BILIRUBIN, DIRECT	0.11	General Range : < 0.3	mg/dL
BILIRUBIN, INDIRECT	0.29	0.00 - 0.60	mg/dL
TOTAL PROTEIN	7.1	Ambulatory : 6.4 - 8.3 Recumbant : 6 - 7.8	g/dL
ALBUMIN	4.5	20-60yrs : 3.5 - 5.2	g/dL
GLOBULIN	2.6	General Range : 2 - 3.5 Premature Neonates : 0.29 - 1.04	g/dL


SHILPA B L
LAB TECHNOLOGIST


DR.AKHILA SEKHAR, M.D
Pathology
(Reg No - TCMC 55174)
CONSULTANT PATHOLOGIST

Page 5 Of 8



View Details



View Report

PERFORMED AT :

DDRC AGILUS PATHLABS LIMITED
Phoenix Tower, Near Central Park Hotel,
Prathibha Junction, Kadappakada,
KOLLAM, 691008
KERALA, INDIA
Tel : 93334 93334
Email : customercare.ddrc@agilus.in

Patient Ref. No. 66600007974415

PATIENT NAME : BINU MURALI

REF. DOCTOR : SELF

CODE/NAME & ADDRESS : CA00010147 -
 MEDIWHEEL ARCOFEMI HEALTHCARE LIMITED
 F701A, LADO SARAI, NEW DELHI,SOUTH DELHI,
 DELHI,
 SOUTH DELHI 110030
 8800465156

ACCESSION NO : **4071XB005731**
PATIENT ID : BINUM2806894071
CLIENT PATIENT ID: 144764
ABHA NO :

AGE/SEX : 34 Years Male
DRAWN :
RECEIVED : 24/02/2024 07:29:21
REPORTED : 24/02/2024 15:16:49

Test Report Status	Final	Results	Units
--------------------	-------	---------	-------

ALBUMIN/GLOBULIN RATIO	1.7	1.0 - 2.0	RATIO
ASPARTATE AMINOTRANSFERASE (AST/SGOT)	20	Adults : < 40	U/L
ALANINE AMINOTRANSFERASE (ALT/SGPT)	23	Adults : < 45	U/L
ALKALINE PHOSPHATASE	52	Adult(<60yrs) : 40 -130	U/L
GAMMA GLUTAMYL TRANSFERASE (GGT)	22	Adult (Male) : < 60	U/L

TOTAL PROTEIN, SERUM

TOTAL PROTEIN	7.1	Ambulatory : 6.4 - 8.3 Recumbant : 6 - 7.8	g/dL
---------------	-----	---	------

URIC ACID, SERUM

URIC ACID	5.7	Adults : 3.4-7	mg/dL
-----------	-----	----------------	-------

BLOOD UREA NITROGEN (BUN), SERUM

BLOOD UREA NITROGEN	9	Adult(<60 yrs) : 6 to 20	mg/dL
---------------------	---	--------------------------	-------

BIOCHEMISTRY - LIPID

MEDIWHEEL HEALTH CHEKUP BELOW 40(M)TMT

LIPID PROFILE, SERUM

CHOLESTEROL	230	Desirable : < 200 Borderline : 200-239 High : >or= 240	mg/dL
TRIGLYCERIDES	89	Normal : < 150 High : 150-199 Hypertriglyceridemia : 200-499 Very High : > 499	mg/dL

SHILPA B L
LAB TECHNOLOGIST

DR.AKHILA SEKHAR, M.D
Pathology
(Reg No - TCMC 55174)
CONSULTANT PATHOLOGIST



View Details



View Report

PERFORMED AT :

DDRC AGILUS PATHLABS LIMITED
 Phoenix Tower, Near Central Park Hotel,
 Prathibha Junction, Kadappakada,
 KOLLAM, 691008
 KERALA, INDIA
 Tel : 93334 93334
 Email : customercare.ddrc@agilus.in



Patient Ref. No. 66600007974415

PATIENT NAME : BINU MURALI

REF. DOCTOR : SELF

CODE/NAME & ADDRESS : CA00010147 -
 MEDIWHEEL ARCOFEMI HEALTHCARE LIMITED
 F701A, LADO SARAI, NEW DELHI,SOUTH DELHI,
 DELHI,
 SOUTH DELHI 110030
 8800465156

ACCESSION NO : 4071XB005731
PATIENT ID : BINUM2806894071
CLIENT PATIENT ID: 144764
ABHA NO :

AGE/SEX : 34 Years Male
DRAWN :
RECEIVED : 24/02/2024 07:29:21
REPORTED : 24/02/2024 15:16:49

Test Report Status	Final	Results	Units
HDL CHOLESTEROL		36 Low	mg/dL
LDL CHOLESTEROL, DIRECT		174 High	mg/dL
General range : 40-60 Optimum : < 100 Above Optimum : 100-129 Borderline High : 130-159 High : 160-189 Very High : >or= 190			
NON HDL CHOLESTEROL		194 High	mg/dL
Desirable: Less than 130 Above Desirable: 130 - 159 Borderline High: 160 - 189 High: 190 - 219 Very high: > or = 220			
VERY LOW DENSITY LIPOPROTEIN		17.8	mg/dL
Desirable value : 10 - 35			
CHOL/HDL RATIO		6.4 High	
3.3-4.4 Low Risk 4.5-7.0 Average Risk 7.1-11.0 Moderate Risk > 11.0 High Risk			
LDL/HDL RATIO		4.8 High	
0.5 - 3.0 Desirable/Low Risk 3.1 - 6.0 Borderline/Moderate Risk >6.0 High Risk			

SPECIALISED CHEMISTRY - HORMONE

MEDIWHEEL HEALTH CHEKUP BELOW 40(M)TMT

THYROID PANEL, SERUM

T3	111.50	Adult : 80-200	ng/dL
T4	7.31	Adults : 4.5-12.1	µg/dl
TSH 3RD GENERATION	1.750	21-50 yrs : 0.4 - 4.2	µIU/mL

ATHIRA S
LAB TECHNOLOGIST

DR. AMJAD A, M.D Pathology
 (Reg No - TCMC 38949)
CONSULTANT PATHOLOGIST

JIBI J
LAB TECHNOLOGIST



View Details



View Report

PERFORMED AT :

DDRC AGILUS PATHLABS LIMITED
 Phoenix Tower, Near Central Park Hotel,
 Prathibha Junction, Kadappakada,
 KOLLAM, 691008
 KERALA, INDIA
 Tel : 93334 93334
 Email : customercare.ddrc@agilus.in



Patient Ref. No. 66600007974415

PATIENT NAME : BINU MURALI

REF. DOCTOR : SELF

CODE/NAME & ADDRESS : CA00010147 -
 MEDIWHEEL ARCOFEMI HEALTHCARE LIMITED
 F701A, LADO SARAI, NEW DELHI,SOUTH DELHI,
 DELHI,
 SOUTH DELHI 110030
 8800465156

ACCESSION NO : **4071XB005731**
PATIENT ID : BINUM2806894071
CLIENT PATIENT ID: 144764
ABHA NO :

AGE/SEX : 34 Years Male
DRAWN :
RECEIVED : 24/02/2024 07:29:21
REPORTED : 24/02/2024 15:16:49

Test Report Status	Final	Results	Units
--------------------	-------	---------	-------

CLINICAL PATH - URINALYSIS

MEDIWHEEL HEALTH CHEKUP BELOW 40(M)TMT

PHYSICAL EXAMINATION, URINE

COLOR	PALE YELLOW
APPEARANCE	CLEAR

CHEMICAL EXAMINATION, URINE

PH	6.0	4.7 - 7.5
SPECIFIC GRAVITY	1.025	1.003 - 1.035
PROTEIN	NOT DETECTED	NOT DETECTED
GLUCOSE	NOT DETECTED	NOT DETECTED
KETONES	NOT DETECTED	NOT DETECTED
BLOOD	NOT DETECTED	NOT DETECTED
BILIRUBIN	NOT DETECTED	NOT DETECTED
UROBILINOGEN	NORMAL	NORMAL
NITRITE	NOT DETECTED	NOT DETECTED

MICROSCOPIC EXAMINATION, URINE

RED BLOOD CELLS	NOT DETECTED	NOT DETECTED	/HPF
WBC	1-2	0-5	/HPF
EPITHELIAL CELLS	0-1	0-5	/HPF
CASTS	NIL		
CRYSTALS	NIL		
BACTERIA	NOT DETECTED	NOT DETECTED	
YEAST	NOT DETECTED	NOT DETECTED	

ATHIRA S
LAB TECHNOLOGIST

DR.KARTHIKA RAMANATHAN, M.D
Pathology
(Reg No - TCMC 53950)
CONSULTANT PATHOLOGIST



View Details



View Report

PERFORMED AT :

DDRC AGILUS PATHLABS LIMITED
 Phoenix Tower, Near Central Park Hotel,
 Prathibha Junction, Kadappakada,
 KOLLAM, 691008
 KERALA, INDIA
 Tel : 93334 93334
 Email : customercare.ddrc@agilus.in



Patient Ref. No. 66600007974415