

Id no: 24/8/3



NATHAN SUPER SPECIALITY HOSPITAL, SALEM - 16.



Dr. P. GNANAVEL, MD.,DM.,
Cardiologist

Cell : 98409 57954

12/9/24

Name	Mr. Thammai Selvan	52yrs/M
------	--------------------	---------

ECHOCARDIOGRAM REPORT

M-MODE

AORTIC ROOT	NORMAL	mm	IVS D/S	NORMAL	11/18	mm
AORTIC ANNULUS	NORMAL	mm	LVPW D/S	NORMAL	11/18	mm
RV	NORMAL	mm	VVID D/S	NORMAL	43/20	mm
LA	NORMAL	mm	LVEF D/S	NORMAL	74%	%

2-D ECHO

Mitral Value	NORMAL	LA	NORMAL
Aortic Value	NORMAL	LV	NORMAL
Pulmonary Value	NORMAL	RA	NORMAL
Tricuspid Value	NORMAL	RA	NORMAL
IAS / IVS	NORMAL	Periardial effusion	NIL

COLOUR DOPPLER

MR - NIL	TR - NIL	IAS - NORMAL	
AR - NIL	PR - NIL	IVS - NORMAL	

PULSE WAVE DOPPLER

MITRAL E/A	E/A	CM / SEC
TRICUSPID E/A	NORMAL	

CONTINUAS WAVE DOPPLER

Aortic Flow Velocity	NORMAL
Pulmonary Flow Velocity	NORMAL
Tricuspid Flow Velocity	NORMAL

IMPRESSION

NORMAL LV SYSTOLIC FUNCTION.
~~NORMAL~~ LV DIASTOLIC FUNCTION. LVH IDO
 NO PHT. SR. NO. RWMW.

CLINICALLY CARDIAC STATUS IS STABLE.
 RESTING ECG SR. NORMAL.
 FIT FOR ORTHO SURGERY

Dr. GNANAVEL, M.D.D.M., Cardia
 Reg No : 54032

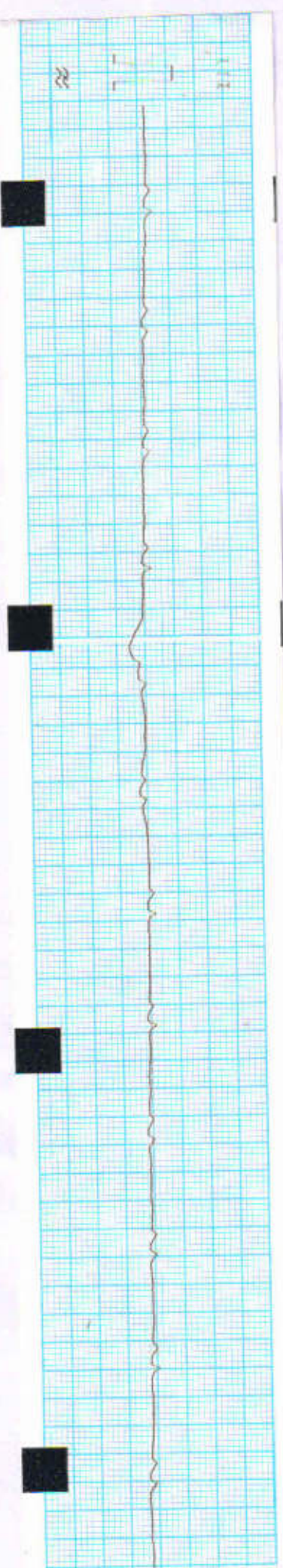
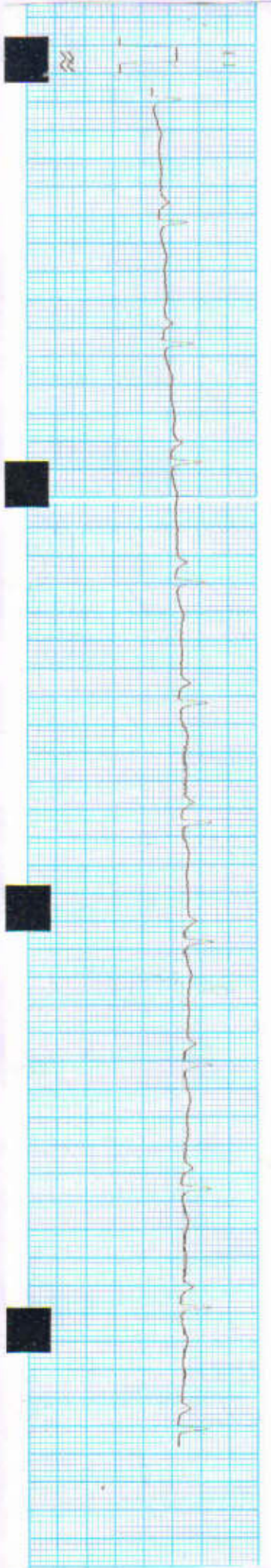
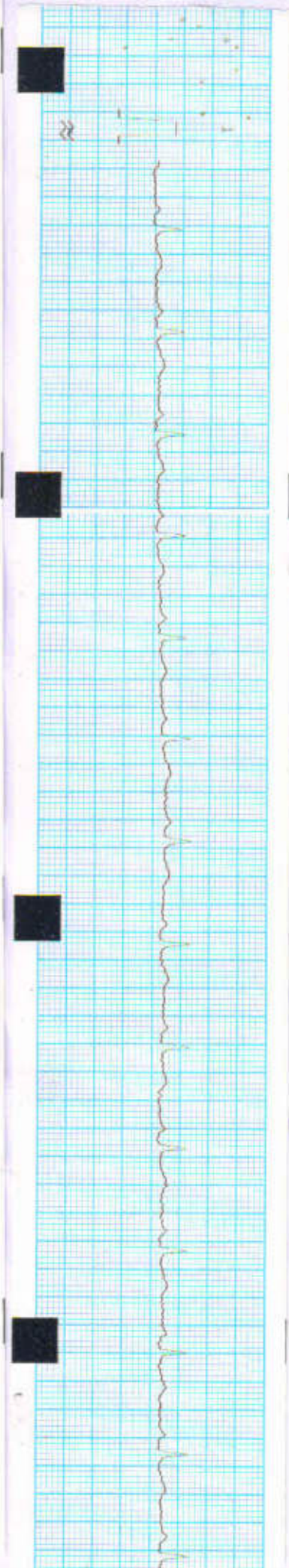
Dr. P. GNANAVEL, MD.,DM.,

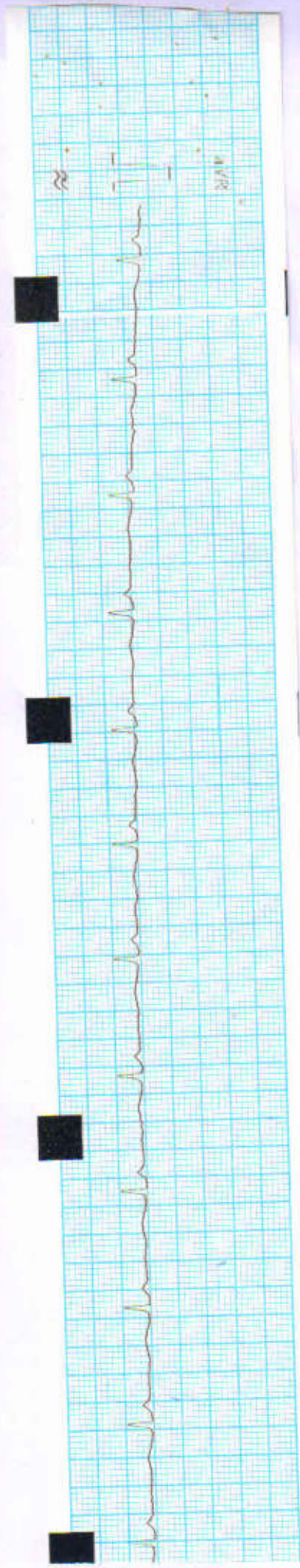
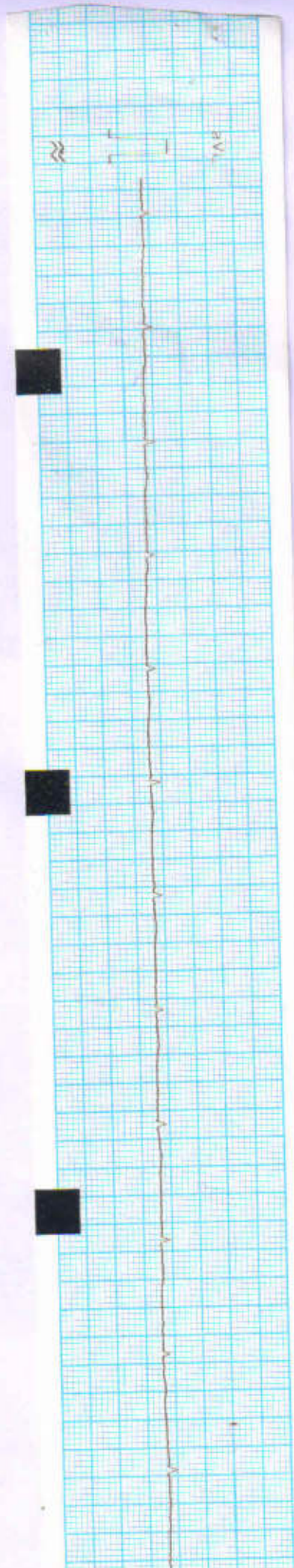
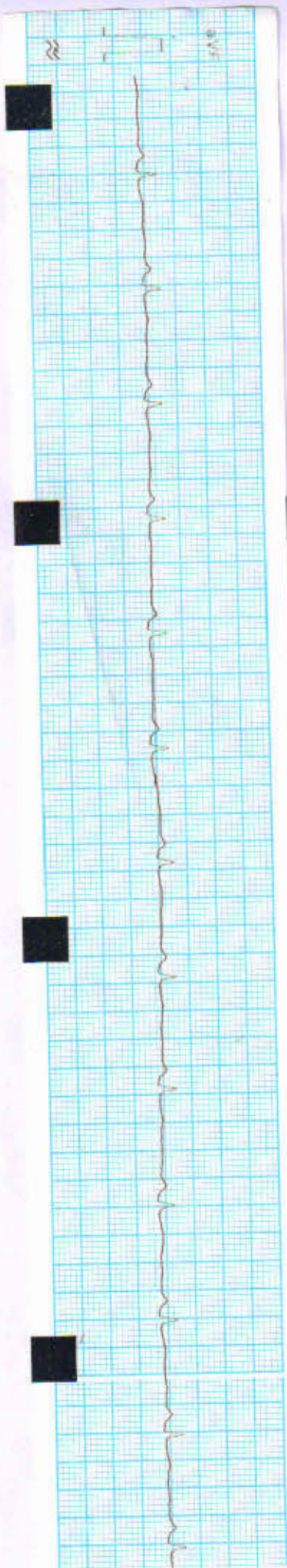
Mr. Mamegai Seivan

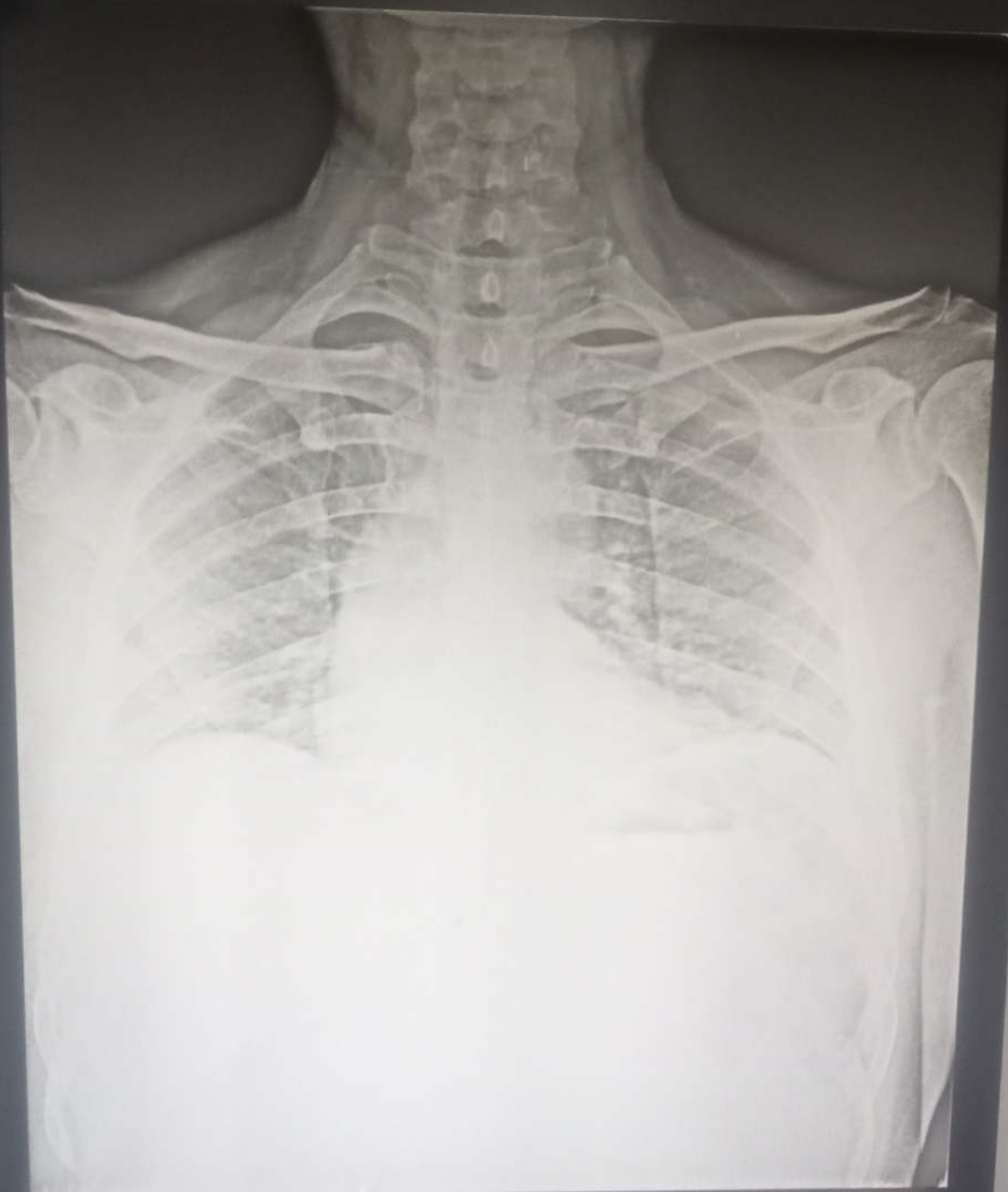59 yrs/m

14/09/24

Idno: 24/813







Mr. THAMARAI SELVAM 52/M 1148 M CHEST AP 14/09/2024 12:33 PM
NATHAN HOSPITAL, SALEM

NATHAN SUPER SPECIALITY HOSPITAL

ISO 9001-2000 CERTIFIED HOSPITAL

NABH ACCREDITED HOSPITAL

State Government Recognized Hospital

Advaitha Ashram Road, Opp. New Bus Stand,
Opp. Holy Flower School, Salem - 636 016. Tamilnadu, INDIA



0091-(0) 427-4264101, 2442303 (H)

0091-(0) 427-2330095 (R)

Mobile : (0) 98942 76633

Fax : 0091-(0)427-4264202

e-mail : nathanorthocare@gmail.com

Web : www.nathanortho.com

Date :

NAME : MR. THAMARAISELVAN

DATE :14.9.2024

AGE/ SEX : 52 YRS /MALE

UHID : 24/ 813

REFERRED BY :DR.G.CHIDAMBARANATHAN .,

SAMPLE : BLOOD SAMPLE

TEST NAME	RESULTS/RANGES	NORMAL RANGES
-----------	----------------	---------------

CBC/HAEMOGRAM COMPLETE:

Haemoglobin : 15.5 mg/dl (M:13.5-18.0) (F:11.5-16.4)

Total WBC Count : 8900cells/cumm (4,000-10,000)

Differential Count:

Polymorphs : 54% (40-75)

Lymphocytes : 32% (20-45)

Eosinophils : 03% (1-6)

Monocytes : 3 % (2-10)

Basophils : 0.1% (0-1)

Platelet count : 2,95,000CELLS/CUMM (1,50,000-4,00,000)

PCV : 44% (36.0-47.0)

RBC Count : 5.0 mills/cumm (3.9-5.6)

MCV : 85.1fl (76.0-96.0)

MCH : 30.0 pg (27.0-32.0)

MCHC : 33.1% (32.0-36.0)

1

Dr. KARTHIKESH

Reg. No: 50797

MD. Pathologist

NATHAN SUPER SPECIALITY HOSPITAL

ISO 9001-2000 CERTIFIED HOSPITAL

NABH ACCREDITED HOSPITAL

State Government Recognized Hospital

Advaitha Ashram Road, Opp. New Bus Stand,
Opp. Holy Flower School, Salem - 636 016. Tamilnadu, INDIA



0091-(0) 427-4264101, 2442303 (H)
0091-(0) 427-2330095 (R)
Mobile : (0) 98942 76633
Fax : 0091-(0)427-4264202
e-mail : nathanorthocare@gmail.com
Web : www.nathanortho.com

Date :

NAME : MR.THAMARAISELVAN

DATE: 14.9..2024

AGE /SEX : 52 YRS /MALE

UHID: 24/813

REFERRED BY : DR.G.CHIDAMBARANATHAN.,

SPECIMEN SOURCE: URINE

TEST NAME	RESULTS	UNIT	BIOLOGICAL REFERENCE INTERVAL
-----------	---------	------	-------------------------------

BIOCHEMISTRY :

Blood group &Rh Typhing	: "O" Positive		
Bleeding Time	: 04.00 mints		(2 to 7 mints)
Clotting Time	: 8.00mints		(2 to 8 mints)
ESR	: 11mm/hour		(0 to 15 - Men, 0 to 20 Female)
Fasting Blood Sugar (FSB)	: 220 mg/dl		(70 to 100)
Postprandial Blood Sugar (PP)	: 253 mg/dL		(less than 140)
Glycosylated Hemoglobin (HBA1c)	: 3.4%		(below 5.7% normal)
Uric Acid	: 4.1 mg/l		(3.5 to 7.2)
BUN	: 12 mg/dl		(5 to 20mg/dL)
Creatinine	: 0. 89 mgs/dl		(0.74- 1.35)
Bun /Creatinine RATIO	: 13:1		(10:1 to 20:1)
Total protein	: 7.9 g/dL		(6.0 to 8.3 g/dL)

SEROLOGY :

Albumin	: 4.2 g/dL		(3.4 to 5.4)
Globulin	: 24gm/l		(20 to 35 gm/l)

Alkaline Phosphate (ALP)	: 75 U/L	(40 to 125 (or) 0.5-1.3)
Bilirubin Total	: 7.2 mg/dl	(5.1 - 17)
Bilirubin (DIRECT)	: 0.2mg/dL	(less than 0.3 mg/dL)
Bilirubin (INDIRECT)	: 0.3 mg/dL	(0.2 to 0.8 mg/dL)
Gamma Glutamyl Transpeptidase (GGT)	: 14 U/L	(5 to 40)
Serum protein	: 7.4 g/dL	(6.0 TO 8.3)
AST / ALT RATION	: 1.15	(1.15)
A: G RATION	: 1.4	(1.1 & 2.5)
PSA	: 2.0 ng/ml	(below 4.0ng/ml)

LIPID PROFILE TEST :

Total cholestrol	: 149 mg/dl	(0.0 - 200.0)
HDL-Cholestrol	: 40 mgs %	(M:35 - 80)(F:42-88)
LDL - Cholestrol	: 80 mgs %	(0 -170)
Cholestrol,HDL Ratio	: 3.3	(3.2 - 5.0)
Triglycerides	: 130 mgs %	(0 - 170)
VLDL	: 18 mgs%	(0 - 35)
LDL/HDL Ratio	: 2.3	(2.2-3.3)

THYROID TEST :

TSH	: 0.9 mIU/l	(0.5 to 5.0 mIU/L)
T4	: 6.0 ng/dL	(5.0 to 12.0ng/dL)
T3	: 65 ng/dL	(20 to 220ng/dL)

NATHAN SUPER SPECIALITY HOSPITAL

ISO 9001-2000 CERTIFIED HOSPITAL

NABH ACCREDITED HOSPITAL

State Government Recognized Hospital

Advaitha Ashram Road, Opp. New Bus Stand,
Opp. Holy Flower School, Salem - 636 016. Tamilnadu, INDIA



0091-(0) 427-4264101, 2442303 (H)

0091-(0) 427-2330095 (R)

Mobile : (0) 98942 76633

Fax : 0091-(0)427-4264202

e-mail : nathanorthocare@gmail.com

Web : www.nathanortho.com

Date :

NAME :MR.THAMARASELVAN

DATE: 14.9.2024

AGE /SEX : 52 YRS/MALE

UHID :24/810

REFERRED BY : DR.G.CHIDAMBARANATHAN,,

SPECIMEN SOURCE: URINE

TEST NAME	RESULTS	UNIT	BIOLOGICAL REFERENCE INTERVAL
-----------	---------	------	-------------------------------

URINE ANALYSIS: (URINE ANALYSIS /MACROSCOPIC EXAM)

COLOUR	PALE YELLOW		
APPERAREANCE	CLEAR		CLEAR
SPECIFIC GRAVITY	1.021		1.010-1.025
REACTION	ACID		ACID
PH	7.0		
ALBUMIN	NIL		NIL TO TRACE
GLUCOSE	NIL		NIL
SUGAR	NEGATIVE		NEGATIVE
BILE PIGMENT	NEGATIVE		NEGATIVE
BILE SALT	NEGATIVE		NEGATIVE
KETONE	NORMAL		NORMAL
UROBILINOGEN	NEGATIVE		NEGATIVE
MICROSCOPIC EXAMINATION/HPE:			
PUS CELLS	1-2		0-4
RED BLOOD CELLS	NIL		RARE
	1		

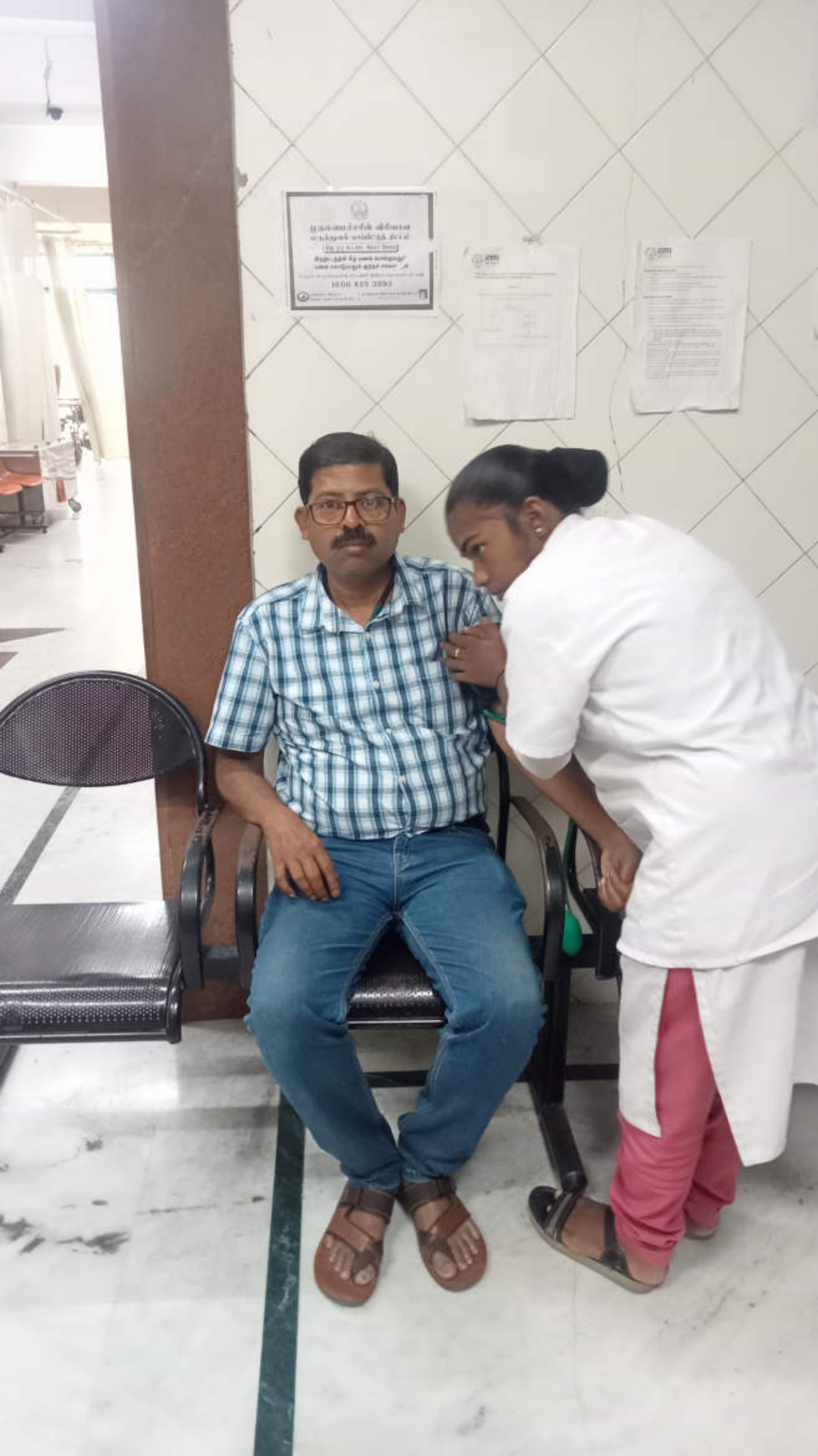EPITHELIAL CELLS	1-2	
CAST	NIL	NIL
CRYSTALS	NIL	NIL
OTHERS	NIL	NIL

✓
Dr. KARTHIKESH
Reg. No: 50797
MD. Pathologist

മുഖ്യമന്ത്രിയുടെ ഉദ്യോഗസ്ഥർക്ക്
ആരോഗ്യ പരിരക്ഷ നൽകുന്നതിനായി
ആരോഗ്യ സേവന കേന്ദ്രം
ആരോഗ്യ സേവന കേന്ദ്രം
1800 323 3000

am

am



NATHAN SUPER SPECIALITY HOSPITAL

ISO 9001-2000 CERTIFIED HOSPITAL

NABH ACCREDITED HOSPITAL

State Government Recognized Hospital

Advaitha Ashram Road, Opp. New Bus Stand,
Opp. Holy Flower School, Salem - 636 016. Tamilnadu, INDIA.



0091-(0) 427-4264101, 2442303 (H)
0091-(0) 427-2330095 (R)
Mobile : (0) 98942 76633
Fax : 0091-(0)427-4264202
e-mail : nathanorthocare@gmail.com
Web : www.nathanortho.com

Date: 14/9/24

PATIENT NAME : MR.THAMARASELVAN

AGE : 52 YRS /MALE

DATE : 14.9.2024

UHID : 24 / 813

REFERRED BY : DR.G.CHIDAMBARANATHAN.,

- BP : 120/90mmHg
- SPO2 : 98%
- PR : 80 pts
- HEIGHT : 171 CM
- WEIGHT : 79 KG
- EYE : NORAML

REMARKS :

nil


DR.G.CHIDAMBARANATHAN.,MS.,ORTHO

Dr. G. CHIDAMBARANATHAN,
M.B.B.S.,M.S.Ortho.,
MCh.Ortho(U.K)..DNB.Ortho.,
Reg. No: 46713

NATHAN SUPER SPECIALITY HOSPITAL

ISO 9001-2000 CERTIFIED HOSPITAL
NABH ACCREDITED HOSPITAL
State Government Recognized Hospital

Advaita Ashram Road, Opp. New Bus Stand,
Opp. Holy Flower School, Salem - 636 016. Tamilnadu, INDIA



0091-(0) 427-4264101, 2442303 (H)
0091-(0) 427-2330095 (R)
Mobile : (0) 98942 76633
Fax : 0091-(0)427-4264202
e-mail : nathanorthocare@gmail.com
Web : www.nathanortho.com

Date :

NAME : MR.THAMARAISELVAN

DATE :14.9.2024

AGE/SEX : 52YRS /MALE

UHID : 24/813

REFERED BY : DR.G.CHIDAMBARANATHAN.,


ULTRASOUND –WHOLE ABDOMEN REPORT

- No Pleural effusion seen.
- LIVER : Liver is large in size.Parenchymal echos are normal.Biliary cabaliculi are not dilated.
- GALL BLADDER : Is normal in wall thickness.Lumen is echofree.
- C.B.D : Normal in caliber.
- BOTH KIDNEYS: Size,shape position and outlining normal.
- PANCREAS : Is normal in size and shape.
- SPLEEN : Is normal in size .
- AORTA,IVC seen is normal in caliber.Ascitis is not seen.
- LYMPH GLAND para arotic lymph glands normal.
- URINARY BLADDER : Wall thickness normal.No calculus seen.No mass lesion seen.
- PROSTATE : Size and outlining normal.

IMPRESSION :

- WHOLE ABDOMEN : NORMAL.

1


Dr. G. CHIDAMBARANATHAN.
M.B.B.S.,M.S.Ortho.,
MCh.Ortho(U.K.),DNB.Ortho.,
Reg. No: 46713

NATHAN SUPER SPECIALITY HOSPITAL

ISO 9001-2000 CERTIFIED HOSPITAL

NABH ACCREDITED HOSPITAL

State Government Recognized Hospital

Advaita Ashram Road, Opp. New Bus Stand,
Opp. Holy Flower School, Salem - 636 016, Tamilnadu, INDIA



0091-(0) 427-4264101, 2442303 (H)
0091-(0) 427-2330095 (R)
Mobile : (0) 98942 76633
Fax : 0091-(0)427-4264202
e-mail : nathanorthocare@gmail.com
Web : www.nathanortho.com

Date : 14/9/24

CHEST X-RAY REPORT

PATIENT NAME :MR.THAMARAISELVAN ,52 YRS/M

- NORMAL AIR SHADOWS
- TRACHEA IN MID LINE
- HEART BORDER NORMAL
- PHRENIC ANGLE NORMAL
- GASTRIC AIR SHADOWS NORMAL
- NO CRADIC PULMONARY ABNORMALITIES.

G. Chidambaranathan
DR.G.CHIDAMBARANATHAN.,MD

Dr. G. CHIDAMBARANATHAN,
M.B.B.S.,M.S.Ortho.,
MCh.Ortho(U.K.),DNB.Ortho.,
Reg. No: 46713