

Name	Mr. Praveen Kumar	Date	17-10-24
Age/Gender	43yrs/M	UHID	400218802

Presenting Complaints: eye strain + Blurring of vsm while using computer x 6M

Past History: DM | HT | CAD

cholesterol + thyroid -
IOP: Right Eye: mmHg Left Eye: mmHg POG RE:

LE:

Spectacles	Sphere	Cylinder	Axis	Vision	Near add	Vision
Right Eye			RCR	6/6		NG
Left Eye				6/6		NG

Clinical Features:

Allegri symptoms
dry eye

Diagnosis:

left eye

for CAD

Advice:

Amput 120y
Refer kungiel sy
are dependent eye
x 4m

Dr Shibal Bhartiya

Dr Shibal Bhartiya
Clinical Director, Ophthalmology | Program Director, Community Outreach & Wellness
HN-15650

For Appointments: 8882638735 | For Clinical queries: +91 9818700269 | www.drshibalbhartiya.com

North East Health Care Pvt Ltd

Registered Address: Plot No 67/1, Opposite Pancharut Bunglows, Near Shukan Mall, OFF Science City Road,
Sala, Dakrui, Assam, India. 782002



H-2019-0615

18802
ars

preveen kumar
Male

17-Oct-24 9:22:07 AM

MARENGO ASIA HOSPITALS

EMERGENCY

- 51 . Sinus rhythm.....normal P axis, V-rate 50- 99
- 135 . Atrial premature complex.....SV complex w/ short R-R interval
- 89 . ST elev, probable normal early repol pattern.....ST elevation, age<55
- 395 . Baseline wander in lead(s) V5
- 364

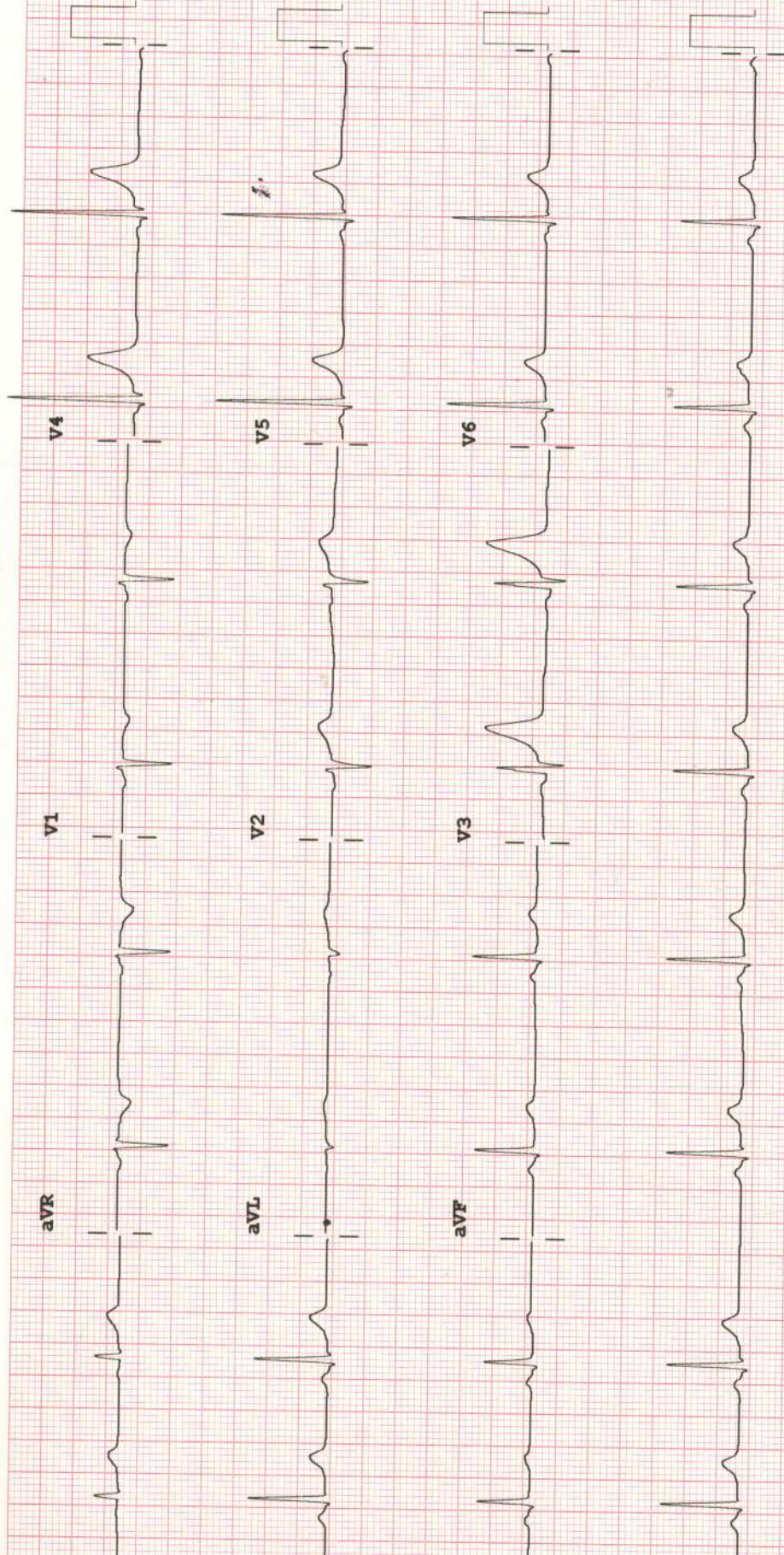
S--

77
68
40

Lead; Standard Placement

- OTHERWISE NORMAL ECG -

Unconfirmed Diagnosis



Speed: 25 mm/sec Limb: 10 mm/mV Chest: 10.0 mm/mV

F 50~ 0.50~ 40 Hz W

100B CL

P?

17/04/24

Dental

Mr. Paveen. Kumar

O/E

slain +

celebrity +

Altrikaw wrt. ^{low} anterior

+/-

Adv. full mouth oral
prophylaxis

✓

Exercise Stress Test Report (TMT)

Name	: MR PREVEEN KUMAR	UHID	: 400218802
Age/Sex	: 43 Years / Male		
Referring Physician	: SELF	Date	: 17.10.2024
Indication	: R/o CAD		

Baseline ECG	Normal sinus rhythm		
Prior Medications			
Protocol	Bruce	MPHR	177
Duration of exercise	10 min 24 sec	85% of MPHR	150
Reasons for termination	THR achieved	Peak HR Achieved	155
Blood Pressure (mmHg)	Baseline BP : 120/80	% MPHR	88%
	Peak BP : 160/90	METS	13.50

Results:


- Had good effort tolerance.
- Normal Heart Rate and BP response.
- ECG
- No Significant ST-T changes during the test.
- No symptoms of angina/ chest pain during the test.
- No significant arrhythmia during the test.
- No S3/S4 Gallop during the test.

Final Impression:

- The Exercise Stress test is Negative for provokable myocardial ischemia.
- Good effort tolerance.

Please Correlate Clinically

Dr. Anshul Goyal
 MD, Medicine
 Attending consultant- Cardiology


Dr. Yogendra Singh Rajput
 MBBS, MD, DM FSCAI
 Interventional Cardiologist
 Associate Clinical Director-Cardiology



PatientID:	400218802	PaientName:	PREVEEN KUMAR
Age:	43Years	Sex:	M
RefPhysician:		Modality/Study:	CR
StudyDate:	17-Oct-2024	ReportedDate:	«ReportedDate»
Study:	Chest		

Investigation: Radiograph of Chest (PA View)
Result:

Mild prominent bilateral bronchovascular markings are seen.
 Bilateral hilar shadow appear normal.
 Cardiomedastinal contour is maintained.
 Cardiophrenic & costophrenic angles are normal.
 Domes of diaphragm are normal.

Please correlate clinically.



Dr. Shallini Mittal
 Senior Consultant Radiologist
 Dept. of Radiology
 (MT-A)



H-2019-0615

North East Health Care Pvt Ltd

Registered Address: Plot No 67/1, Opposite Panchamrut Bunglows, Near Shukan Mall, OFF Science City Road,
 Sola, Daskroi, Ahmedabad- 380060, Gujarat, India

Correspondence Address: Marengo Asia Hospitals, Golf Course Ext. Road, Sushant Lok-2, Sector 56, Gurugram, Haryana - 122011

☎ 1800 309 9999 ■ helpdesk@marengoasia.com

CIN No. U85110GJ2010PTC146108, PAN No. AACDN4016H, GST No. 06AACDN4016H1Z5