

**MEDICOVER****HOSPITALS**

NAVI MUMBAI

Name : Mrs. VANITA ATHAWALE  
Bill No. : MCB54241101842Age /Sex : 88 YRS / FEMALE  
UMR No. : 542411000417**LABORATORY REPORT : BIOCHEMISTRY**

Parameters	Result	Reference Range	Units
<b>BUN(BLOOD UREA NITROGEN)</b>			
( Bill Date : 09-Nov-2024 08:29 AM Result ID : RMI241106218)			
BUN (Blood Urea Nitrogen.) Calculated	21	7 - 21.0	mg/dL
<b>LIPID PROFILE</b>			
( Bill Date : 09-Nov-2024 08:29 AM Result ID : RMI241106220)			
TOTAL CHOLESTEROL Enzymatic colorimetric	227 *	Desirable : < 200 mg/dL Borderline High : 200 - 239 mg/dL High risk : > 240 mg/dL	mg/dL
HDL CHOLESTEROL Homogeneous enzymatic colorimetric	35	Low : < 40 mg/dL High : > 60 mg/dL	mg/dL
LDL CHOLESTEROL Direct-Enzymatic colorimetric	137 *	Very High : - > 190 mg/dL Optimal : - < 100 mg/dL Near Optimal : 100 - 129 mg/dL High : 160 - 189 mg/dL Borderline High: 130-159 mg/dl	mg/dL
VLDL Calculation	48 *	2 - 30 mg/dL	mg/dL
SERUM TRYGLYCERIDES Enzymatic colorimetric	238 *	< 150 mg/dL Borderline High : 150 - 199 mg/dL High : 200 - 499 mg/dL	mg/dL
CHO/HDL RATIO Calculation	6.49 *	Normal : - < 3.5 High Risk : - > 5.0	
LDL/HDL RATIO	3.91		
<b>SERUM CREATININE</b>			
( Bill Date : 09-Nov-2024 08:29 AM Result ID : RMI241106221)			
CREATININE Jaffe	1.06	0.6 - 1.2	mg/dL
<b>BUN / CREATININE RATIO</b>			
( Bill Date : 09-Nov-2024 08:29 AM Result ID : RMI241106222)			
BUN / CREATININE RATIO CALCULATED	19.81	10-20	





# MEDICOVER

Name : Mrs. VANITA ATHAWALE  
Bill No. : MCB54241101842

Age /Sex : 68Y Y (S) FEMALE  
UMR No. : 542411000417

NAVI MUMBAI

## LFT(LIVER FUNCTION TEST)

( Bill Date : 09-Nov-2024 08:29 AM Result ID : RMI241106223)

TOTAL BILIRUBIN <i>DIAZO</i>	0.3	<1.2	mg/dL
DIRECT BILIRUBIN <i>DIAZO</i>	0.1	<=0.20	mg/dL
INDIRECT BILIRUBIN <i>Calculated</i>	0.2	<=1.0	mg/dL
SGPT (ALT) <i>UV without PSP</i>	15	<=33	U/L
SGOT (AST) <i>UV without PSP</i>	16	<= 32	U/L
ALKALINE PHOSPHATASE (ALP) <i>PNPP, AMP Buffer - IFCC Ref.</i>	126 *	35 - 105	U/L
TOTAL PROTEINS <i>Buret method</i>	7.3	6.0 - 8.0 g/dL	g/dL
SERUM ALBUMIN <i>Biochromol Green (BCG)</i>	4.2	3.5 - 5.2 g/dL	g/dL
GLOBULINS <i>Calculated</i>	3.1	2.5 - 3.5 g/dL	g/dL
A/G RATIO <i>Calculation</i>	1.35	1.2 - 2.5	
GAMMA GLUTAMYL TRANSFERASE(GGT) <i>S-glutamyl-carboxy-nitroamide-IFCC</i>	22	6-42	U/L

## SERUM URIC ACID

( Bill Date : 09-Nov-2024 08:29 AM Result ID : RMI241106224)

SERUM URIC ACID <i>UV/ASA</i>	8.0 *	2.4-5.7	mg/dL
----------------------------------	-------	---------	-------

## T3,T4 AND TSH

( Bill Date : 09-Nov-2024 08:29 AM Result ID : RMI241106229)

T3 <i>ECLIA</i>	102..0 *	70 - 204	ng/dL
--------------------	----------	----------	-------





# MEDICOVER

<b>Name</b>	: Mrs. VANITA ATHAWALE	<b>Age /Sex</b>	: 58Y / F / BEM
<b>Bill No.</b>	: MCB54241101842	<b>UMR No.</b>	: 542411000417

HOSPITALS

NAVI MUMBAI

T4 ECLIA	6.90	5.1 - 14.1	ug/dL
TSH(THYROID STIMULATING HORMONE) ECLIA	5.69 *	0.270 - 4.20	uIU/mL

  
DR. MEHROTRA VISHAL  
MD PATHOLOGY





# MEDICOVER

## HOSPITALS

### NAVI MUMBAI

Name	: Mrs. VANITA ATHAWALE	Age /Sex	: 58Y (s) FEMALE
Bill No.	: MCB54241101842	UMR No.	: 542411000417

### LABORATORY REPORT : BIOCHEMISTRY

Parameters	Result	Reference Range	Units
<b>HBA1C (GLYCOSYLATED HAEMOGLOBIN)</b>			
( Bill Date : 09-Nov-2024 08:29 AM Result ID : RMI241106219)			
HBA1C <small>HPLC</small>	8.7 *	* Normal : < 5.7% Pre diabetic : 5.7 % - 6.5 % Diabetic : > 6.5 %	
<b>FBS (FASTING BLOOD GLUCOSE WITH URINE GLUCOSE)</b>			
( Bill Date : 09-Nov-2024 08:29 AM Result ID : RMI241106230)			
FASTING BLOOD GLUCOSE <small>Hexokinase</small>	209 *	Normal Range : 70 - 99 Impaired Glucose tolerance : 100 -125 Diabetes Mellitus : >=126	mg/dL
FASTING URINE GLUCOSE	+		
<b>PLBS (POST LUNCH BLOOD SUGAR WITH URINE SUGAR)</b>			
( Bill Date : 09-Nov-2024 08:29 AM Result ID : RMI241106789)			
PLBS (POST LUNCH BLOOD GLUCOSE)	293		
URINE SUGAR	+		

  
DR. MEHROTRA VISHAL  
MD Pathology





# MEDICOVER

<b>Name</b> : Mrs. VANITA ATHAWALE	<b>Age /Sex</b> : 53 Yrs / FEMALE
<b>Bill No.</b> : MCB54241101842	<b>UMR No.</b> : 542411000417

## HOSPITALS

### NAVI MUMBAI

### LABORATORY REPORT : BLOOD BANK

Parameters	Result	Reference Range	Units
<b>BLOOD GROUPING AND RH</b>			
( Bill Date : 09-Nov-2024 08:29 AM      Result ID : RMI241106228)			
<b>BLOOD GROUP</b> <i>Automated microcolumn gel method</i>	AB		
<b>RH TYPE</b>	POSITIVE		

#### INTERPRETATION

1. If Rh is Du positive it is best considered as Rh negative as recipient and Rh positive as donor. Proper Cross matching is recommended before transfusion.
2. In case of forward and reverse grouping discrepancy, clinical correlation and repeat sample analysis is recommended.
3. For Infants below 6 months only forward grouping is performed.
4. A sub-grouping is recommended after the age of 6 months.

  
**DR. MEHROTRA VISHAL**  
MD PATHOLOGY



**MEDICOVER**

NAVI MUMBAI

Name : Mrs. VANITA ATHAWALE  
 Bill No. : MCB54241101842

Age /Sex : 58Y 7510 FEMALE  
 UMR No. : 542411000417

HOSPITALS

**LABORATORY REPORT : CLINICAL PATHOLOGY**

Parameters	Result	Reference Range	Units
<b>CUE(COMPLETE URINE EXAMINATION)</b>			
( Bill Date : 09-Nov-2024 08:29 AM Result ID : RMI241106225)			
<b>PHYSICAL EXAMINATION</b>			
VOLUME	30 ML		ml
COLOUR	Pale yellow	PALE YELLOW	
APPEARANCE	S.HAZY	CLEAR	
<b>CHEMICAL EXAMINATION</b>			
DEPOSIT	ABSENT	ANSENT	
SPECIFIC GRAVITY <i>Bromthymol blue</i>	1.020	1.000 - 1.030	
PH <i>Bromthymol blue</i>	5.0	5.0 - 8.0	
PROTEIN <i>Tetra-bromophenol blue/Hesl's coagulation test</i>	NIL	NIL (<15 mg/dL)	
GLUCOSE <i>Glucose oxidase/Panastase/Benedict's test</i>	+	NIL (<25 mg/dL)	
UROBILINOGEN <i>Diazonium salt</i>	NIL	NIL	
KETONE <i>Sodium nitroprusside/Rothmann's test</i>	NIL	NIL (<5 mg/dL)	
BILIRUBIN <i>Dipstick/Fouchet's test</i>	NIL	NEGATIVE	
BILE SALT <i>Heys sulphur powder</i>	NIL	NEGATIVE	
BILE PIGMENT <i>Fouchet test</i>	NIL	NEGATIVE	
NITRITE <i>Sulfanilic acid</i>	NIL	NEGATIVE	





# MEDICOVER

# HOSPITALS

## NAVI MUMBAI

<b>Name</b>	: Mrs. VANITA ATHAWALE	<b>Age /Sex</b>	: 39 Yrs FEMALE
<b>Bill No.</b>	: MCB54241101842	<b>UMR No.</b>	: 542411000417

LEUCOCYTE ESTERASE	NIL	NEGATIVE	
<b>MICROSCOPIC EXAMINATION</b>			
PUS CELLS	2-3	0 - 5 /hpf	
EPITHELIAL CELLS	1-2	0 - 5	hpf
RBC	2-3	0 - 5 /hpf	
CAST	NIL	NIL	
<i>Microscopy examination</i>			
CRYSTALS	NIL	NIL	
BACTERIA	NIL		
<i>Microscopic examination</i>			
YEAST	NIL		
<i>Microscopic examination</i>			
AMORPHOUS DEPOSITS	NIL		
<i>Microscopic examination</i>			
MUCUS THREAD	NIL		
<i>Microscopic examination</i>			

### NOTE

Microscopic examination of urine is carried out on centrifuged urinary sediment.

Dr Neeta Shrivastava  
MBBS, MD, DNB ( Microbiology)



**MEDICOVER****HOSPITALS**

NAVI MUMBAI

Name : Mrs. VANITA ATHAWALE  
Bill No. : MCB54241101842Age /Sex : 53Y (S) FEMALE  
UMR No. : 542411000417**LABORATORY REPORT : HAEMATOLOGY**

Parameters	Result	Reference Range	Units
<b>ESR</b>			
( Bill Date : 09-Nov-2024 08:29 AM Result ID : RMI241105226)			
ESR MODIFIED WESTERGREW'S METHOD	70 *	0 - 20	mm/1st hour

**CBP(COMPLETE BLOOD PICTURE)**

Parameters	Result	Reference Range	Units
( Bill Date : 09-Nov-2024 08:29 AM Result ID : RMI241105227)			
R B C COUNT Electrical impedance	4.40	3.8-4.8	10 <sup>12</sup> /L
HEMOGLOBIN Photometric	11.5 *	12.0 - 15.0	gms/dL
PCV/HCT Calculated	38.7	36 - 46	%
MCV Calculated	88.0	83 - 101	fl
MCH Calculated	26.2 *	27 - 32	pg
MCHC Calculated	29.8 *	31.5 - 34.5	g/dL
RDW(cv)	15.3 *	11.6 - 14.0 %	%
TLC (TOTAL LEUCOCYTE COUNT)	6.95	4.0 - 10.0	10 <sup>3</sup> /µl

Impedance

**DIFFERENTIAL COUNT**

NEUTROPHILS DHSS/Microscopy	66	40 - 80 %
LYMPHOCYTES DHSS/Microscopy	26	20 - 40 %
MONOCYTES DHSS/Microscopy	05	02 - 10 %
EOSINOPHILS DHSS/Microscopy	03	00 - 06 %







# MEDICOVER

## HOSPITALS

### NAVI MUMBAI

**Name** : Mrs. VANITA ATHAWALE  
**Bill No.** : MCB54241101842

**Age /Sex** : 36 Yrs (s) FEMALE  
**UMR No.** : 542411000417

<b>BASOPHILS</b> <i>DHSS/Microscopy</i>	00	00 - 01 %	
<b>PLATELET COUNT</b> <i>Electrical Impedance</i>	322	150 - 400 $10^3/\mu\text{L}$	$10^3/\mu\text{L}$

  
**DR. MEHROTRA VISHAL**  
MD Pathology



<b>Patient ID:</b>	542411000417	<b>Patient Name:</b>	VANITA ATHAWALE
<b>Age:</b>	58YRS	<b>Sex:</b>	F
<b>Accession Number:</b>		<b>Modality:</b>	US
<b>Referring Physician:</b>	DMO	<b>Study:</b>	USG ABDOMEN PELVIS
<b>Study Date:</b>	09-Nov-2024		

### ULTRASOUND EXAMINATION OF ABDOMEN & PELVIS

The Liver is normal in size (15.3 cm) and shows increase in parenchymal reflectivity. No focal lesion is seen. The Hepatic veins appear normal. There is no evidence of any dilated IHBR. The portal vein appears normal.

The gall bladder is distended with normal wall thickness. There is no evidence of gallstones. C.B.D. is of normal caliber.

The Pancreas is normal in size and shows homogeneous reflectivity. There is no evidence of any calcification or ductal dilatation.

The spleen is normal in size and shows a homogeneous echotexture. It measures 9.8 cm in long axis. There is no evidence of any focal lesion.

Both kidneys are normal in position and size. They show borderline raised cortical reflectivity with maintained cortico-medullary distinction.

The Right Kidney measures 9.1 x 4.8 cm.

The Left Kidney measures 9.2 x 5.0 cm. *An echogenic focus (3.2 mm) is seen in mid to lower pole cortex of left kidney – likely calcification.*

There is no evidence of renal calculi, hydronephrosis noted.

There is no evidence of ascites.

The Urinary bladder is adequately distended and shows normal wall thickness. No evidence of any intraluminal mass or calculi.

The uterus is post menopausal status. It measures 6.0 x 3.8 x 2.8 cm.

The uterine myometrial echotexture is homogeneous. No focal lesion is seen.

The Endometrial thickness is 3.1 mm.

Bilateral adnexa appear unremarkable.

No evidence of any fluid collection in the pelvis.

<b>Patient ID:</b>	542411000417	<b>Patient Name:</b>	VANITA ATHAWALE
<b>Age:</b>	58YRS	<b>Sex:</b>	F
<b>Accession Number:</b>		<b>Modality:</b>	US
<b>Referring Physician:</b>	DMO	<b>Study:</b>	USG ABDOMEN PELVIS
<b>Study Date:</b>	09-Nov-2024		

**IMPRESSION:**

- Grade I fatty liver.
- Borderline raised renal cortical echogenicity. *Suggest KFT correlation.*

Suggest clinical correlation and further evaluation sos.



Dr. Garima Shalendra Sharma  
MBBS, M.D. (Radio Diagnosis)  
DNB, FRCR  
Consultant Radiologist

Date: 09-Nov-2024 11:55:10

Patient ID:	11000417	Patient Name:	VANITA ATHAWALE 58YRS/F
Age:		Sex:	O
Accession Number:		Modality:	CR
Referring Physician:		Study:	BREAST
Study Date:	09-Nov-2024		

### X-RAY MAMMOGRAPHY

**INDICATION:** Routine screening.

#### MAMMOGRAPHY

Bilateral mammograms were obtained in the oblique mediolateral and craniocaudad projections. The film markers are placed on the axillary / lateral part of the breast. Both breasts display almost entirely fatty parenchyma (ACR category a). There is no focal spiculated mass lesion seen. A punctate microcalcification is seen in lateral, central part of left breast. There are no clusters of microcalcification, distortion of the lobular architecture or nipple retraction. Skin and subcutaneous tissues are normal. Multiple axillary lymph nodes are seen bilaterally- likely reactive.

#### IMPRESSION :-

**Punctate microcalcification in lateral, central part of left breast.**

**BIRADS Category II (Benign)**

**Suggest a routine screening mammography after one year.**

*(BIRADS CATEGORY : BIRADS 0 - Requires additional evaluation, I - Negative, II - Benign findings, III - Probably benign findings, IV - Suspicious abnormality, V - Highly suggestive of malignancy, VI - Known biopsy proven malignancy.)*



**Dr. Garima Shalendra Sharma**  
MBBS, M.D. (Radio Diagnosis),  
DNB, FRCR  
Consultant Radiologist.

Date: 09-Nov-2024 13:03:26

<b>Patient ID:</b>	5424110000417	<b>Patient Name:</b>	VANITA ATHAWALE
<b>Age:</b>	58 Years	<b>Sex:</b>	F
<b>Accession Number:</b>		<b>Modality:</b>	DX
<b>Referring Physician:</b>		<b>Study:</b>	CHEST
<b>Study Date:</b>	09-Nov-2024		

**X RAY CHEST PA VIEW**

Patient in rotation

Both lungs are clear.

Cardiac size cannot be commented upon.

The pleural spaces are clear.

Both hilar shadows are normal in position and density.

No diaphragmatic abnormality is seen.

The soft tissues and bony thorax are normal.



**Dr. Garima Shalendra Sharma**  
MBBS, MD (Radio Diagnosis)  
DMS, FRCR  
Consultant Radiologist

Date: 09-Nov-2024 10:15:03

HC 417  
58 Years

VANITA ATHAWALE  
Female

11/9/2024 1:02:56 PM

Rate 66 . Sinus rhythm.....normal P axis, V-rate 50-99

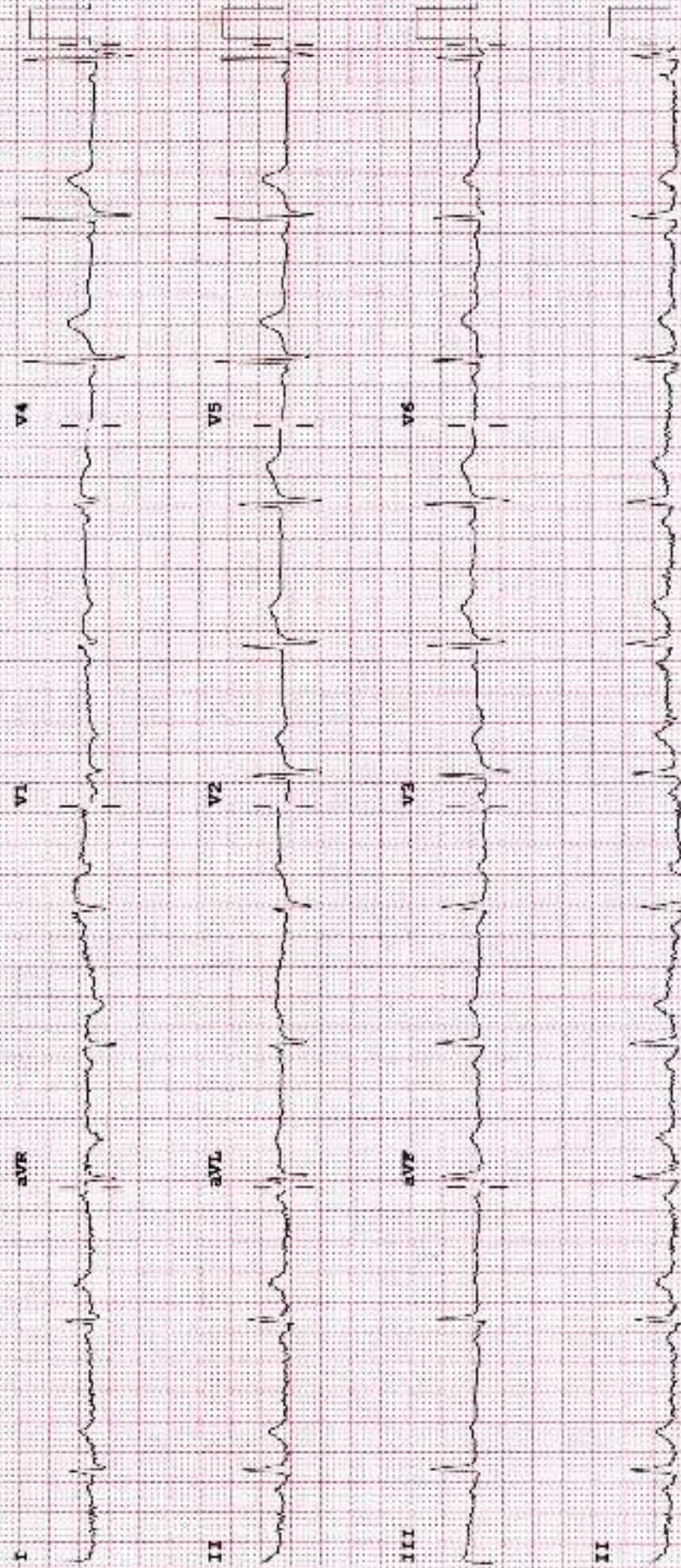
PR 146  
QRSD 92  
QT 376  
QTc 394

--AXIS--  
P 53  
QRS 76  
T 42

12 Lead; Standard Placement

- NORMAL ECG -

Unconfirmed Diagnosis



Device:

Speed: 25 mm/sec Limb: 10 mm/mV Chest: 10.0 mm/mV

P 50- 0.50- 40 Hz W

100B CL

P?





**MEDICOVER**  
HOSPITALS

NAVI MUMBAI

## 2D ECHO CARDIOGRAPHY WITH COLOR DOPPLER

<i>Name</i>	: Mrs. Vanita Athawale	Date:- 09/11/2024
<i>Age / Sex</i>	: 58 Yrs / Female	UMR No. 00417
<i>Referred By</i>	: Health Checkup	

### FINDINGS:

- No left ventricle regional wall motion abnormality.
- Normal left ventricle systolic function. LVEF = 60%.
- Grade I left ventricle diastolic dysfunction.
- Trivial mitral regurgitation.
- Trivial aortic regurgitation. No aortic stenosis.
- No tricuspid regurgitation. No pulmonary hypertension.
- No left ventricle clot / vegetation / pericardial effusion.
- Intact IAS and IVS.
- Normal left atrium and left ventricle dimensions.
- Normal right atrium and right ventricle dimensions.
- Normal right ventricle systolic function. No hepatic congestion.

### IMP:

- No RWMA.
- Grade I left ventricle diastolic dysfunction.
- Trivial MR and AR.
- Normal LV and RV systolic function.

**DR. KESHAV KALE**

DNB (Cardiology), MD (Medicine), MBBS  
PhD (Cardiology), MNAMS, LLB (Law)  
FSCAI (USA), AFACC (USA), FESC (EU)  
Consultant & Interventional Cardiologist





**MEDICOVER**  
HOSPITALS

NAVI MUMBAI

**M-MODE MEASUREMENTS:**

LA	34	mm
AO root	29	mm
AO CUSP SEP	18	mm
LVID( s)	32	mm
LVID(d)	41	mm
IVS(d)	11	mm
LVPW(d)	10	mm
RVID(d)	29	mm
RA	31	mm
LVEF	60	%

	PEAK	MEAN	Vmax	Gradient of Regurgitation
MITRAL	N			Trivial
AORTIC	7			Trivial
TRICUSPID	N			Nil
PULMONERY	4.1			Nil







**MEDICOVER  
HOSPITALS**

# MEDICOVER HOSPITALS

## MEDICAL HEALTH CHECK- UP ASSESMENT FORM

NAME : Mr / (Mrs) Vanita . Athawale.

DATE: 09/11/24

AGE : 58y 8m 1f

SEX: Male / (Female)

NMU: NMU000 542411000417

DOCTOR'S NAME:

TEMP :	<u>97.8</u>	<sup>o</sup> f	BP :	<u>147/97</u>	mmHg
PULSE :	<u>72</u>	b/m	HEIGHT :	<u>149</u>	cm
RR :	<u>20</u>	b/m	WEIGHT :	<u>82.6</u>	kg
SPO2 :	<u>98</u>	%	HGT:	<u>—</u>	

REMARK:



**DEPARTMENT OF OPHTHALMOLOGY**

NAVI MUMBAI

DATE: 9/11/24

PATIENT NAME: Mrs. Vanita Athawale

AGE / SEX 58/F

UMR NO: SA2411000417

	RE	LE
VA (DISTANCE)	6/12p.	6/36.
VA (NEAR)	N18	N12
COLOUR VISION	(N)	(N)

		SPHERE	CYLINDER	AXIS	VA	Accn
MRx	O D (R)	-0.25	-1.00	180	6/C	+2.50 WC
	O S (L)	-2.50	-0.50	10	6/C	+2.50 WC

**HISTORY :**

h/o HT ⊕ on Rp ∴ 12 yrs

h/o DM ⊕ on Rp ∴ 7 years

h/o Thyroid ⊕ on Rp ∴ 10 yrs.

**OCULAR FINDINGS :**

(BE) - Cataract L > R  
N I - II

Disc ← 0.3  
0.2

**ADVICE:**

Fundoscopy i/v/o HT / DM / Thyroid  
Refresh Tears eld qit 1777 X (months)

Mon - Fri 11am to 2pm

AP  
CRA. ANUSHREE VANUWAKR



Vanita Athawale, F, 58 yrs

c/o routine check up.

O/E - S + +, Ca + +  
- root piece int  $\frac{\quad}{5}$

Adm:

- Scaling + polishing  
- X<sup>n</sup> int  $\frac{\quad}{5}$

Dr. Binota Singh