

DAKSH HOSPITAL

396 - 397, Gandhi Nagar, Scheme No. 8, ALWAR -301001

Ref. No.

Date.....

MEDICAL EXAMINATION REPORT

Mediwheel (BOB)

Name: Mrs ^{RAJ} Rajeshwari Sharma Age: 28 yrs Sex: Female

Date: 26/10/2024

General Physical Examination

Height	:	162 cm.	Weight	:	53.4 kg
Pulse	:	76 bpm	BP	:	110/70 mm/hg.
Temp.	:	97.2 F	Respiration SpO2	:	92 %
BMI	:	20.1			

Systemic Exam:- NORMALDental Check up :- NORMALEye check-up :- NORMALSkin Check up:- NORMALENT Check up:- NORMALGynae Check up:-on-NIL, Mn-3/30/24
fluent LMP 6/11/24

Paps smear taken

Impression:-

NORMAL LAB TESTS MER

Recommendation:-- NO
Cap update O3 weekly (S)

Dr. Mukesh Kumar Gupta
MD Gen. Medicine
Reg. No 5423/16262

डॉ० मुकेश गुप्ता
M.D.F.C.C.S.

किजिशियन एवं मधुमेह रोग विशेषज्ञ
दक्ष हॉस्पिटल, अलवर
रजि० नं०-5423/16262

Results

Run Date 26/10/2024 09:28:15 AM

Operator DAKSH

Last Name

Sample ID 4

First Name MRS. RAJ RAJESHWARI

Department

Gender Female Age

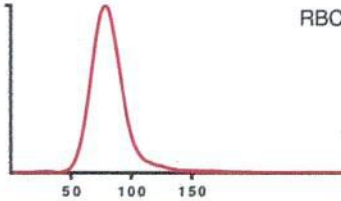
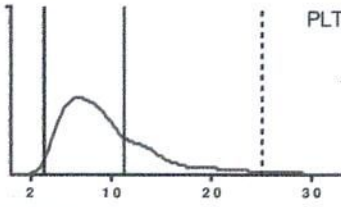
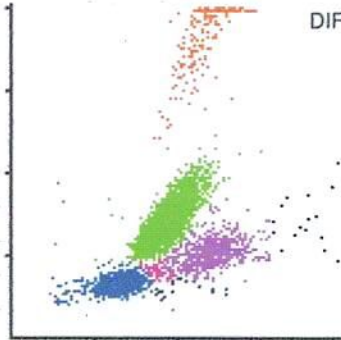
Physician DR. MUKESH GUPTA M.D

Patient ID AUTO_PID26057

Type Woman

Date of birth

Sample comments

			Range		
RBC	4.16	10 ⁶ /μL	3.80 - 5.50	 <p>RBC</p>	
HGB	11.2	g/dL	11.5 - 15.2		
HCT	33.6	%	35.0 - 46.0		
MCV	80.7	μm ³	77.0 - 97.0		
MCH	26.9	pg	26.0 - 34.0		
MCHC	33.3	g/dL	32.0 - 35.0		
RDW-CV	15.1	%	11.0 - 17.0		
RDW-SD	49.0	μm ³	37.0 - 49.0		
			Range		
PLT	226	10 ³ /μL	150 - 450	 <p>PLT</p>	
PCT	0.21	%	0.15 - 0.40		
MPV	9.2	μm ³	8.0 - 11.0		
PDW	14.2	μm ³	11.0 - 22.0		
P-LCC	56	10 ³ /μL	44 - 140		
P-LCR	24.9	%	18.0 - 50.0		
			Range		
WBC	8.24	10 ³ /μL	3.50 - 10.00	 <p>DIF</p>	
	#	Range	%		Range
NEU	4.58	1.60 - 7.00	55.8		40.0 - 75.0
LYM	2.84	1.00 - 3.00	34.6		20.0 - 45.0
MON	0.33	0.20 - 0.80	4.0		2.0 - 10.0
EOS	0.36	0.00 - 0.50	4.4		1.0 - 6.0
BAS	0.10	0.00 - 0.15	1.2 h		0.0 - 1.0
LIC	0.03	0.00 - 0.10	0.3		0.0 - 1.0

Signature

Dr. R.S. GUPTA
MD (Pathology) (MAHE)
RMC No. 7924/19778

Date :-26/10/2024

Name :- MRS. RAJ RAJESHWARI SHARMA

Age & Sex :- 28 Yrs Female

Refd. :- Dr Mukesh Gupta M.D.

	TEST NAME	RESULT	REFERENCE RANGE	
	ESR	10	00 -20 mm/hrs	
	Blood Group & Rh Factor	O" POSITIVE		
	HbA1C	4.5	4 - 5.6%	
	Blood Sugar (F)	85.3	< 70 - 100 mg/dl	
	Blood Sugar (PP)	-	< 140 mg/dl	
	Urine Sugar (F)	NIL	-	
	Urine Sugar (PP)	-	-	
LIVER	S.Bilirubin Total	1.0	0.30 - 1.20 mg/dl	
	S.Bilirubin Direct	0.3	0.10 - 0.30 mg/dl	
	S.Bilirubin Indirect	0.7	0.30 - 0.90 mg/dl	
	S.G.O.T.	20	> 37 u/l	
	S.G.P.T.	25	> 40 u/l	
	S.Alk. Phosp.	165	80 - 306 u/l	
	G.G.T.	28.0	5 -40 u/l	
	Total Protein	6.7	6.5 - 8.5 gm/dl	
	Albumin	3.7	3.8 - 5.4 gm/dl	
	Globulin	3.0	2.3 - 3.5 gm/dl	
	A/G Ratio	1.2	-	
	AST/ALT Ratio	0.8	-	
KIDNEY	Blood Urea	22.6	15 -45 mg/dl	
	S.Creatinine	0.85	0.60 - 1.30 mg/dl	
	BUN	19.1	6 -24 mg/dl	
	S.Uric Acid	5.3	M 3.1 - 7.0, F 2.5 - 5.6 mg/dl	
	BUN/Creatinine Ratio	23.1	-	
LIPID PROFILE	Total Cholesterol	140.0	Up to 200 mg/dl	
	S.HDL	44	30 - 70 mg/dl	
	S.LDL	72.0	Up to 170 mg/dl	
	S.VLDL	24.1	5.0 - 40 mg/dl	
	S. Triglycerides	120.1	Up to 170 mg/dl	
	LDL/HDL Ratio	1.6	-	
	Total Cholesterol/ HDL Ratio	3.1	-	
THYROID	T3	115.2	40 - 181 ng/dl	
	T4	8.5	4.6 - 10.5 µg/dl	
	TSH	3.68	0.30 - 5.0 mlu/l	
	URINE EXAMINATION		Microscopic Examination:	
General/Chemical Examination:			RBC	Absent
	Colour	Pale Yellow	WBC	1 -2
	Reaction	Acidic	Epithelial Cells	0 -1
	Specific Gravity	QNS	Cast	Absent
	Appearance	Clear	Crystal	Absent
	Albumin	NIL	Spermatozoa	Absent
	Sugar	Nil	Amorphous Sediments	Absent
			Other	Absent
X-RAY CHEST	NORMAL STUDY			

Signature

Dr. R.S. GUPTA
MD (Pathology) (MAHE)
Doctor RMC No. 7924/19778

TECHNOLOGIST

All investigation have their own limitations regarding the sensitivity & specificity of individual assay procedures, Isolated laboratory investigations never confirm the final diagnosis of the disease. They only help in arriving at a diagnosis in conjunction with clinical presentation and other related investigations. Report is not valid for medico-legal purpose subject to ALWAR jurisdiction only.



दक्ष हॉस्पिटल

396, गाँधी नगर स्कीम नं.8, अलवर (राज०) ☎ 0144-2703340

Sonography / 2D Echo Cardiography / Doppler Report

2D/ ECHO REPORT

Name: - Mrs Rajeshwari Sharma

Age: - 28 Yrs

Date: - 26-Oct-24

Reg. No.:- Alw/2009/04
BOB health checkup

PROCEDURES:

M-MODE/2D/DOPPLER/COLOR/CONTRAST B.A.S. M²


MEASUREMENT:			DOPPLER:				
AOD	19	(20- 37mm)	MV	0.7	(0.8- 1.3)	MR	No
LA	21	(19- 40mm)	AV	1.3	(1.2- 1.8)	AR	No
AVO	15	(12- 25mm)	TV	0.6	(0.3- 0.8)	TR	No
RVDd.	11.6	(03- 09mm)	PV	0.8	(0.7- 1.1)	PR	No
LV Dd	44	(37- 56mm)	MITRAL VALVE-				
LV Ds	27.8	(22- 40mm)			AML	Normal	
IVS d	12	(06- 12mm)			PML	Normal	
IVS s	13.6		AORTIC VALVE				
PWd	5.8	(05- 10mm)				Normal	
LV FUNCTION			TV & PV are normal.				
M- E- S Separation		<0.9cm					
Minor		24.42%					
LV Ejection Fraction	70%	65 +/- 12%					

LV WALL MOTION: NO RWMA
ALL CARDIAC CHAMBERS ARE NORMAL
ALL VALVES ARE NORMAL
NO CLOT, VEGETATION, PERICARDIAL EFFUSION

FINAL DIAGNOSIS: NORMAL STUDY

Adv: - Follow up/ review at higher center for confirmation

Note:- Please Correlate clinically. Due to technical limitations as well as inaccuracies inherent in the laboratory and statistical analysis of biological process. Diagnostic accuracy of ECHO is up to 95% only.
Report is not valid for medico-legal purpose.


DR. MUKESH GUPTA
Physician & Sonologist
RM 5423/16262



"भ्रूण लिंग परीक्षण की शिकायत
104 टोल फ्री सेवा पर भी की
जा सकती है।"

भ्रूण लिंग परीक्षण की शिकायत 104 टोल फ्री सेवा पर भी की जा सकती है।



दक्ष हॉस्पिटल

396, गाँधी नगर स्कीम नं.8, अलवर (राज०) ☎ 0144-2703340

Sonography / 2D Echo Cardiography / Doppler Report

NAME :- MRS RAJESHWARI SHARMA/F/28 YRS

26-Oct-24

BOB HEALTH CHECKUP

U.S.G. OF ABDOMEN & PELVIS

LIVER

Liver is normal in size shape with normal echo-texture. Intra hepatic billiary radicals Are not dilated. No evidence of focal or diffuse lesion.

GALL BLADDER

Gall bladder is normal.

PANCREAS

Pancreas is normal in size, shape & echo-texture. No evidence of focal or diffuse lesion. MPD not dilated.

SPLEEN

Spleen normal in size with normal shape & echo- texture. Spleen vein is normal. No evidence of focal or diffuse lesion

KIDNEY

Both kidneys are normal size shape and echo- texture.

URINARY BLADDER

UB is normal.

UTERUS:

Uterus is normal in size (7.6x3.5x4.8cm) with homogenous echo-texture. Endometrial 8 mm in thickness & echo genicity

OVARIES:

Both ovaries are normal size, shape & echo-texture.

Advice- follow up/ hormonal study review at higher center for confirmation

Please correlate clinically. USG accuracy is 95 % due to technical limitations as well as inaccuracies inherent in the laboratory and statistical analysis biological process. This report is not valid for medico-legal cases


DR. MUKESH GUPTA
Sonologist
Dr. Mukesh Gupta
Physician & Sonologist
RM 5423/16262



"भ्रूण लिंग परीक्षण की शिकायत
104 टोल फ्री सेवा पर भी की
जा सकती है।
भ्रूण लिंग परीक्षण की शिकायत 104 टोल फ्री सेवा पर भी की जा सकती है।

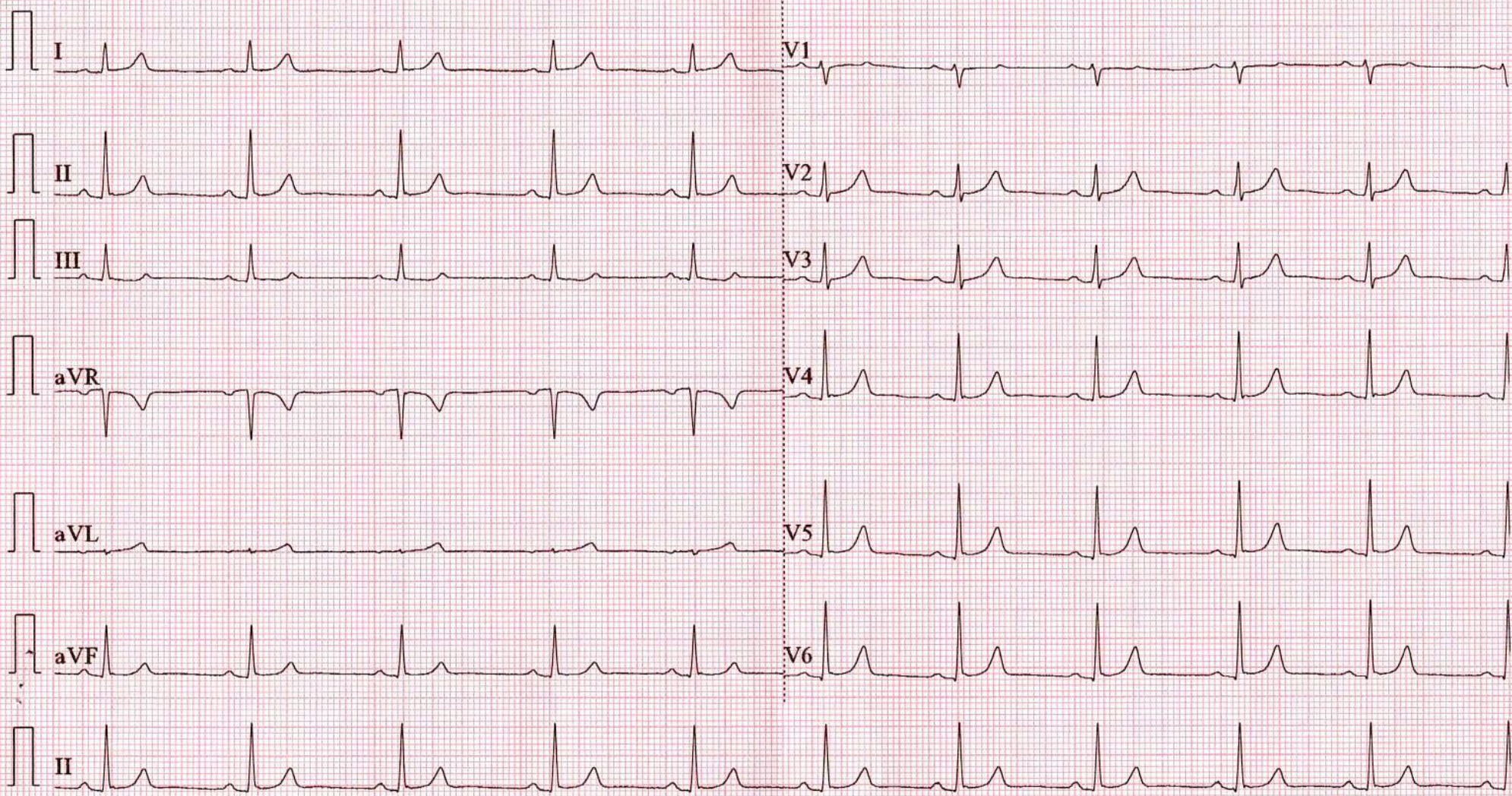
ID: 4
MRS. RAJ RAJESHWARI SHARMA
Female 28Years

HR : 62 bpm
P : 99 ms
PR : 158 ms
QRS : 72 ms
QT/QTc : 374/381 ms
P/QRS/T : 68/61/39 °
RV5/SV1 : 1.249/0.290 mV

Diagnosis Information:
Sinus Rhythm
Normal ECG


डॉ० मुकेश गुप्ता
M.D.F.C.C.S.
कैजिशियन एवं मधुमेह रोग विशेषज्ञ
दक्ष हॉस्पिटल, अलवर
रजि० नं०-5423/16262

Report Confirmed by:



T01129102 MRS RAJESHWARI REFD BY DR. MUKESH GUPTA MD CHEST 26.10.2024

R

