

Date - 21/12/23

Mrs. Sarita Singh

Age - 39 y

for hnc.

LMP = 20/11/23

0/1 y
12/2 y → 12 y ♀ Alu.
8 y ♀ m

B/C - Breast Examination - NAD

pls.
Cr - erosion (+) (+)
Not bleed on touch
Pap smen.



Abn.

- BSC - monthly
- FAS - 3 kit - (1)
- Cap - CLYNAGN FORTE vaginally x 2 nights x 7 days.

- Cap - FEMBZO @ BD x 2 weeks.

- R/w Pap smen.
← Pap smen. in Anupa m.

Counselling Dept
Dr. Jay GARDAS LL
HPV - VACCINE

Apollo Sage Hospital - Bhopal

Regd No. NH/7272/Sept. 2022
(A unit of S. R. Associates)

KH.No. 98/3-99-100, E-8 Arera Colony, Bhopal - 462026 (MP) India

+91 -755- 4308101 Emergency +91 -755- 3505050

info@apollosage.in www.apollosage.in

Dr. Anupa Walia Lokwani

Sr. Consultant Obst. & Gynaecology

MD (OBG), Dip. in Laparoscopic & Endoscopic Gynae Surgery

Apollo Sage Hospital Bhopal

Reg. No. MP-13453



Scan here to know us better

Dep. of ophthalmology

Mrs. Sarita Singh

89/F

1/12/23

V₀₅ 6/12
(CPC) 6/6

Sub (R) - 6.0 / -0.5 x 180° 6/12 ^(F2) ~~12~~ ¹²

(L) - 3.5 / -0.75 x 180° 6/6

N_v — N_e (39)

AR $\left\{ \begin{array}{l} -6.75 / -1.25 \times 180 \\ -3.75 / -1.25 \times 180 \end{array} \right.$

PG $\left\{ \begin{array}{l} -6.0 / -0.5 \times 180 \\ -3.5 / -0.75 \times 180 \end{array} \right.$

Dr. Siddharth Malviya
MS Ophthalm, FVPEI (Cornea), FRCO
(Consultant Ophthalmology & Cornea Specialist)
Reg No.: MP-13858

Dr. Siddharth Malviya
MS Ophthalm, FVPEI (Cornea), FRCO
(Consultant Ophthalmology & Cornea Specialist)
Reg No.: MP-13858



Vital Signs™
226 166 C5

01.12.20 8:49:33

66 bpm
-- / -- mmHg

CE 0537

D7 D 736

39 Years
Female

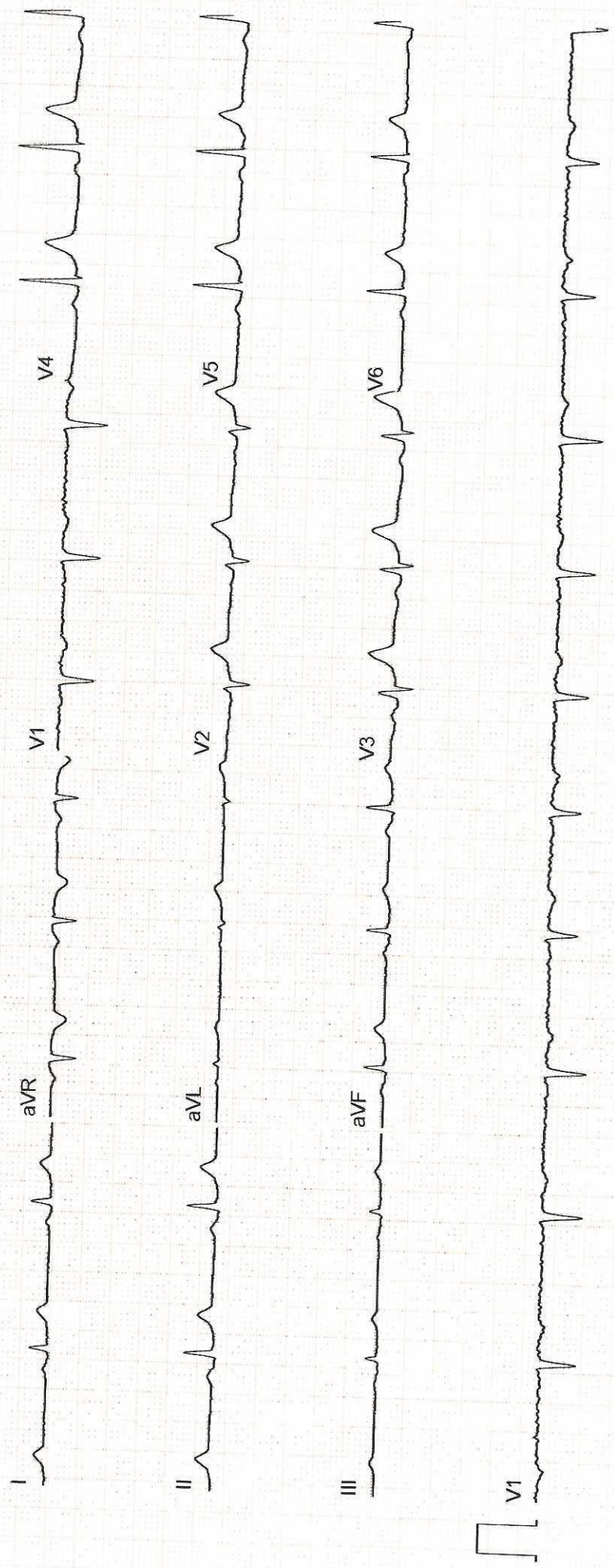
QRS : 74 ms
QT / QTcBaz : 380 / 398 ms
PR : 158 ms
P : 106 ms
RR / PP : 904 / 909 ms
P / QRS / T : 56 / 58 / 44 degrees

Normal sinus rhythm with sinus arrhythmia
Normal ECG

Technician:
Ordering Ph:
Referring Ph:
Attending Ph:

Location:
Order Nurse:
Indication:
Medication 1:
Medication 2:
Medication 3:

Handwritten signature



Apollo Sage Hospital
 --
 Bhopal

Station
 Telephone:

EXERCISE STRESS TEST REPORT

Patient Name: SINGH, SARITA
 Patient ID: HC-23706
 Height: 164 cm
 Weight: 91.4 kg

DOB: 24.08.1984
 Age: 39 yrs
 Gender: Female
 Race: Indian

Study Date: 01.12.2023
 Test Type: Treadmill Stress Test
 Protocol: BRUCE

Referring Physician: --
 Attending Physician: Dr. Anurag Jain
 Technician: Radha Prajapati

Medications:
 --

Medical History:
 NONE

Reason for Exercise Test:
 Screening for CAD

Exercise Test Summary

Phase Name	Stage Name	Time in Stage	Speed [km/h]	Grade [%]	HR [bpm]	BP [mmHg]	Comment
PRETEST	SUPINE	00:25	0.00	0.00	93	120/80	
	STANDING	00:23	0.00	0.00	98	120/80	
	HYPERV.	00:25	0.00	0.00	97	120/80	
EXERCISE	WARM-UP	00:17	1.60	0.00	100	120/80	
	STAGE 1	03:00	2.70	10.00	141	120/80	
	STAGE 2	03:00	4.00	12.00	157	120/80	
	STAGE 3	00:34	5.40	14.00	164	140/80	
RECOVERY		03:14	0.00	0.00	107	120/80	


The patient exercised according to the BRUCE for 6:34 min:s, achieving a work level of Max. METS: 8.60. The resting heart rate of 100 bpm rose to a maximal heart rate of 164 bpm. This value represents 90 % of the maximal, age-predicted heart rate. The resting blood pressure of 120/80 mmHg, rose to a maximum blood pressure of 140/80 mmHg. The exercise test was stopped due to Target heart rate achieved.

Interpretation

Summary: Resting ECG: normal.
 Functional Capacity: normal.
 HR Response to Exercise: appropriate.
 BP Response to Exercise: normal resting BP - appropriate response.
 Chest Pain: none.
 A rhythmias: none.
 ST Changes: Depression horizontal.
 Overall impression: Moldly Positive stress test suggestive of ischemia.

Conclusions

-ST-T Changes Noted During Exercise & Recovery
 -Mildly Positive Stress Test

Physician _____ Technician _____


PRINTED IN USA

3

ULTRA SONOGRAPHY ABDOMEN

NAME	Mrs. Sarita Singh	UHID NUMBER:-	ASHB.0000023706
REF. BY	Dr. Akhil Kumar Tiwari	DATE	01.Dec.2023
		AGE/SEX:-	39y/F

Liver:- is normal in size and **shows mild increase in echotexture.** Portal and hepatic venous system appears normal. Intra and extra hepatic biliary radicals are not dilated.

Gall Bladder:- is partially contracted (Non fasting status).

Pancreas is normal in size outline and echopattern.

Spleen is normal in size and echopattern.

Both kidneys are normal in size, shape and echogenicity. Central pelvicalyceal sinus and corticomedullary ratio are normal.

Right kidney measures:- 8.6x4.3cm

Left kidney measures:- 9.4x5.0cm

No evidence of ascites is seen.

Urinary bladder is normal in shape and contour. Its wall is normal.

Uterus and ovaries:- Uterus is anteverted, bulky and shows inhomogeneous echopattern. There is evidence of a relatively defined heterogeneously hypoechoic lesion measuring about 3.6x3.7x3.6cm noted arising from the anterior myometrium and projecting outside the left lateral wall of uterus. The lesion shows peripheral vascularity with no obvious internal vascularity. Cervix shows normal echopattern. No adnexal mass. No free fluid in POD. Uterus measures:- 9.5x4.5x5.4cm. Endometrial thickness is 13mm. Right ovary measures 2.1x0.7cm.

Left ovary measures 2.6x2.2cm. Left ovary shows a dominant follicle measuring about 18mm.

IMPRESSION:- Sonography Study Reveals:-

- **Grade- I fatty liver**
- **Bulky uterus with small uterine fibroid (FIGO classification type - 6).**

ADV:- TVS Correlation.

For

Dr. Mahesh Kumar Verma, MD
Sr. Consultant Radiologist



Patient Name:	SARITA SINGH	Patient ID:	ASHB.0000023706
Age:	39 Years	Sex:	F
Accession Number:	17101.123012800	Modality:	DX
Referring Physician:	Akhil Kumar Tiwari	Study:	CHEST
Study Date:	01-Dec-2023		

X-RAY CHEST (PA VIEW)

Both lung fields are clear. No active pleural or parenchymal lesion is seen.

The hila, mediastinum, bony thoracic cage and the diaphragmatic domes are normal.

The costophrenic and cardiophrenic angles are clear.

The cardiac silhouette is unremarkable.

IMP:- RADIOGRAPHIC IMAGE REVEALS:-

Normal findings are seen. ✓

Thanks for Ref


Dr. Kirti Khandelwal
Consultant Radiologist

Apollo Sage Hospital - Bhopal

Regd No. NH/7272/Sept. 2022

(A unit of S. R. Associates)

KH.No. 98/3-99-100, E-8 Arera Colony, Bhopal - 462026 (MP) India

+91 -755- 4308101

Emergency +91 -755- 3505050


info@apollosage.in


www.apollosage.in



Scan here to
know us better

 ApolloSageHospitals

 apollosagehospital

 apollo-sage-hospital



Out Patient Assessment Form

Apollo Hospital, Bhopal

Place Patient Label Here

Ms. Savita Singh
 If label not available, write Pt. Name UHID No. IP
 No Age, Sex, Date, Name of Treating Physician

Date : 11/12/23

Time : 8:42 AM

Consultant Name : HC

Pain Assessment

Nursing Assessment

--	--	--	--	--	--

Height: 164 cm

Weight: 91.4 kg

Pulse: 85/m

BP: 124/82

Allergies (if any)

NO

Falls risk : Yes No

Oral hygiene :

Poor

Fair

Good

Investigation Ordered

SpO2 - 99.1

BMI (34)

Chief complains past medical / surgical history. Diagnosis, Treatment Plan, Current Medications & Follow - up advice :

Loxon L (LA)
 - (antacid)

Patient Education (Patient Is Briefed on Following) Cost May Vary In Course Of Disease

Proposed Care Plan Yes No

Expected Outcome : Yes No

Expected Cost : Yes No

Admission Advice : Yes No

Consultant Signature

Date :

Time