



Name	: MR. RANJIT R. SONI	UHID No.	: AFB000308843
FATHER	: RAJAPPAN	Date	: 23-03-2024 10:02:36
Age / Gender	: 39 Yrs 5 Mth / MALE	Doctor / Unit	: DR. PRABHSARAN AHUJA /
CPG	: CORPORATE CASH/ArcoFemi HealthCare Ltd	Department	: Health Check Up
Inst. Name	: ArcoFemi Healthcare Ltd		
Address	: FLAT NO. G1102, BRTP RESORTS, SEC-75, FARIDABAD, HARYANA, INDIA		

DR. PRABHSARAN AHUJA, MBBS, Director - PHC-Health Check Up,
PHC (1st Floor), OPD Timmings Mon to Sat 9:00 a.m to 3:00p.m.

Note :
Nature of illness, prognosis, potential side effects of medication used, risk of allergic reaction, need for follow-up & monitoring has been explained to the Patient/attendants in their own language.
WHEN TO OBTAIN URGENT CARE : In case high grade fever, recurrent vomiting, profuse diarrhea, severe oral ulcers, skin rash, breathlessness, dizziness, loss of consciousness, bleeding from any site or new relevant/ alarming symptom

Asian Institute of Medical Sciences (A unit of Blue Sapphire Healthcares Private Limited) CIN: U74999DL2007PTC159674
Reg. Off.: Level 10, Plot No. 18-20, Hindustan Times House, Kasturba Gandhi Marg, New Delhi - 110001, Corp. Off.: Badkal Flyover Road, Sector - 21A, Faridabad - 121001 (Haryana)
T +91 129 425 3000 · E-mail: bshealthcares@aimsindia.com · Web: www.aimsindia.com

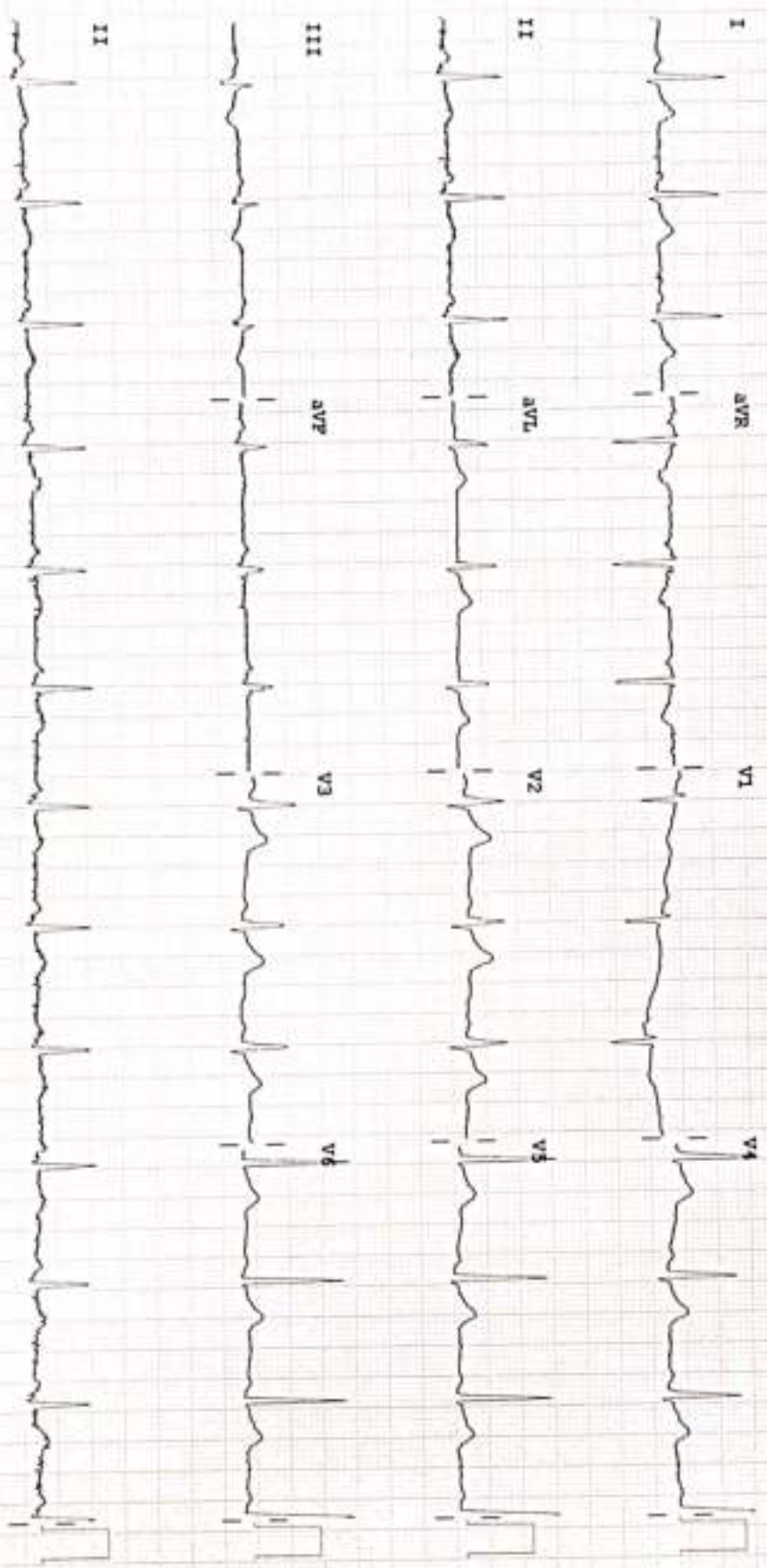
Asian Institute of Medical Sciences (A unit of Blue Sapphire Healthcares Private Limited) CIN: U74999DL2007PTC159674
Reg. Off.: Level 10, Plot No. 18-20, Hindustan Times House, Kasturba Gandhi Marg, New Delhi - 110001, Corp. Off.: Badkal Flyover Road, Sector - 21A, Faridabad - 121001 (Haryana)
T +91 129 425 3000 · E-mail: bshealthcares@aimsindia.com · Web: www.aimsindia.com

Rate 75

PR 135
QRSD 100
QT 375
QTc 419

--AXIS--
P 60
QRS 29
T 7

12 Lead: Standard Placement



Device: Speed: 25 mm/sec Limb: 10 mm/mV Chest: 10.0 mm/mV

F 60-0.15-100 Hz

100B

P?



NON INVASIVE CARDIOLOGY

Patient Name	: MR. RANJIT R. SONI	IPD No.	:
Age	: 39 Yrs 5 Mth	UHID	: AFB000308843
Gender	: MALE	Bill No.	: AFBHC240003221
Ref. Doctor	: SELF	Bill Date	: 23-03-2024 10:06:04
Ward	:	Room No.	:
		Procedure Date	: 23-03-2024 11:06:38

ECHOCARDIOGRAPHY & COLOR DOPPLER REPORT

MEASUREMENTS	ABSOLUTE VALUE		NORMAL VALUE
Aortic Root Diameter	2.6		2.0-3.7cm < 2.2cm/M2
Aortic Valve Opening	N		1.5-2.6cm
Left Atrial Dimension	3.3		1.9-4.0cm < 2.2cm/M2
RV Dimensions	N		0.7-2.6cm
RV thickness	N		0.3-0.9cm
LV ED Dimension	4.2		3.7-5.6 cm < 3.2cm /M2
LV ES Dimension	2.4		2.2-4.0 cm
IVS thickness	ED - 1.0	ES-1.3	0.6-1.2cm
LVPW Thickness	ED - 1.0	ES-1.5	0.5-1.1cm
IVS/ LVPW Ratio	N		
Mitral Valve	DE-N	EF -N	

INDICES OF LV FUNCTION		
EPSS		<9mm
FS%		24-42%
LV Ejection Fraction	60%	60+/-6%

NON INVASIVE CARDIOLOGY

Patient Name	: MR. RANJIT R. SONI	IPD No.	:
Age	: 39 Yrs 5 Mth	UHID	: AF18572358843
Gender	: MALE	Bill No.	: AF181024522/15221
Ref. Doctor	: SELF	Bill Date	: 23-03-2024 19:56:04
Ward	:	Room No.	:
		Procedure Date	: 23-03-2024 11:56:38

MORPHOLOGICAL DATA

Mitral Valve : AML PML	Normal	Interatrial Septum	Intact
Aortic Valve	Normal	Interventricular Septum	Intact
Tricuspid Valve	Normal	Pulmonary Artery	Normal
Pulmonary Valve	Normal	Aorta	Normal
Right Ventricle	Normal	Right Atrium	Normal
Left Ventricle	Normal	Left Atrium	Normal

DOPPLER STUDY

	Cm/s	Cm/s	
MITRAL VELOCITY	E-83	A-58	MR 1/4
TRICUSPID VELOCITY	cm/s		TR 1/4
AORTIC VELOCITY	134 cm/s		AR 0/4
PULMONARY VELOCITY	130 cm/s		PR 0/4
PA Pressure	30 mmHg		

NON INVASIVE CARDIOLOGY

Patient Name	: MR. RANJIT R. SONI	IPD No.	:
Age	: 39 Yrs 5 Mth	UHID	: AFB000308843
Gender	: MALE	Bill No.	: AFBHC240003221
Ref. Doctor	: SELF	Bill Date	: 23-03-2024 10:06:04
Ward	:	Room No.	:
		Procedure Date	: 23-03-2024 11:06:38


COLOUR FLOW MAPPING

Trace MR, Trace TR.

FINAL IMPRESSION

1. No RWMA, LVEF-60%.
2. Normal RV systolic function.
3. Normal cardiac chamber dimension.
4. Trace MR, Trace TR (PASP=30mmHg).
5. Normal mitral inflow pattern.
6. No clot/mass/vegetation/PE.

DR. SUBRAT AKHOURY
MD,DM(Cardiology)FSCAI(USA)
Director & Sr. Consultant
Interventional Cardiologist


DR. KUMAR HRISHIKESH
MBBS, PGDCC
Fellowship in Non Invasive
Cardiology
Consultant Cardiology

DR. PRATEEK CHAUDHARY
MBBS,MD,DM(Cardio)
Consultant Cardiology
Interventional Cardiologist.

DR. DIWAKAR KUMAR
MBBS,MD,DNB(Cardiology)
Consultant Cardiology

For The perusal of a medical professional only
The content of this report is only an opinion based on images and is therefore subject to inherent technical limitations.

It is not the diagnosis & must be correlated clinically.
NOT FOR MEDICOLEGAL PURPOSES
.....End of Report.....

Prepare By:
KUMAR.HRISHIK
ES

FINAL REPORT

Bill No.	: AFBHC240003221	Bill Date	: 23-03-2024 10:08
Patient Name	: MR. RANJIT R. SONI	UHID	: AFB000308843
Age / Gender	: 39 Yrs 5 Mth / MALE	Patient Type	: OPD IF PHC :
Ref. Consultant	: SELF	Ward / Bed	: /
Sample ID	: AFB24098422	Current Ward / Bed	: /
		Receiving Date & Time	: 23-03-2024 10:27
		Reporting Date & Time	: 23-03-2024 12:37

BLOOD BANK REPORTING

Test (Methodology)	Flag	Result	UOM	Biological Reference Interval
Sample Type: EDTA Whole Blood				
MEDIWHEEL FULL BODY ANNUAL PLUS(WITH 2D)				
BLOOD GROUP (ABO & RH)				
ABO GROUP		AB		
RH TYPE		POSITIVE		

**** End of Report ****

IMPORTANT INSTRUCTIONS

CL - Critical Low, CH - Critical High, H - High, L - Low

DR. RAMESH CHANDNA
MD, MICROBIOLOGY, PGDHMM
Chairman (Quality, Safety, LAB Services & Blood Bank)

Uma Rani
DR. UMA RANI
MD, PATHOLOGY
DIRECTOR

DR. SHILPA GUPTA
MD, PATHOLOGY
Associate Director

DR. SHARMILA RAI
MD, PATHOLOGY
Consultant

FINAL REPORT

All No.	AFBHC240003221	Bill Date	23-03-2024 10:06
Patient Name	MR. RANJIT R. SONI	UHID	AFB000308843
Age / Gender	39 Yrs 5 Mth / MALE	Patient Type	OPD IF PHC : <input type="checkbox"/>
Ref. Consultant	SELF	Ward / Bed	/
Sample ID	AFB24098424	Current Ward / Bed	/
		Receiving Date & Time	23-03-2024 10:27
		Reporting Date & Time	23-03-2024 12:03

SEROLOGY REPORTING

Test (Methodology)	Flag	Result	UOM	Biological Reference Interval
--------------------	------	--------	-----	-------------------------------

Sample Type: Serum

MEDIWHEEL FULL BODY ANNUAL PLUS(WITH 2D)

THYROID PROFILE (FT3+FT4+TSH)

Test Name	Result	UOM	Reference Interval
FREE-TRI IODO THYRONINE (FT3) (CLIA)	3.03	pg/mL	2.0-4.4
FREE -THYROXINE (FT4) (CLIA)	1.35	ng/dL	0.9-1.7
THYROID STIMULATING HORMONE (TSH) (CLIA)	3.76	mIU/L	0.27-4.20

**** End of Report ****

IMPORTANT INSTRUCTIONS

CL - Critical Low, CH - Critical High, H - High, L - Low

Results are Verified By



DR. C.P. SHARMA
Ph.D.(Biochemistry)
BIOCHEMIST

DR. RAMESH CHANDNA
MD, MICROBIOLOGY, PGDHM
Chairman (Quality, Safety, LAB
Services & Blood Bank)

DR. UMA RANI
MD, PATHOLOGY
DIRECTOR


DR. SHILPA GUPTA
MD, PATHOLOGY
Associate Director

DR. SHARMILA RAI
MD, PATHOLOGY
Consultant

FINAL REPORT

Jill No.	: AFBHC240003221	Bill Date	: 23-03-2024 10:06
Patient Name	: MR. RANJIT R. SONI	UHID	: AFB000308843
Age / Gender	: 39 Yrs 5 Mth / MALE	Patient Type	: OPD <input type="checkbox"/> If PHC <input type="checkbox"/>
Ref. Consultant	: SELF	Ward / Bed	: /
Sample ID	: AFB24098424	Current Ward / Bed	: /
		Receiving Date & Time	: 23-03-2024 10:27
		Reporting Date & Time	: 23-03-2024 12:03

SEROLOGY REPORTING

Test (Methodology)	Flag	Result	UOM	Biological Reference Interval
--------------------	------	--------	-----	-------------------------------

Sample Type: Serum


MEDIWHEEL FULL BODY ANNUAL PLUS(WITH 2D)
THYROID PROFILE (FT3+FT4+TSH)

FREE-TRI IODO THYRONINE (FT3) (ECLIA)		3.03	pg/mL	2.0-4.4
FREE -THYROXINE (FT4) (ECLIA)		1.35	ng/dL	0.9-1.7
THYROID STIMULATING HORMONE (TSH) (ECLIA)		3.76	mIU/L	0.27-4.20

**** End of Report ****
IMPORTANT INSTRUCTIONS

CL - Critical Low, CH - Critical High, H - High, L - Low

Results are Verified By


DR. C.P. SHARMA
 Ph.D.(Biochemistry)
 BIOCHEMIST

DR. RAMESH CHANDNA
 MD, MICROBIOLOGY, PGDIHM
 Chairman (Quality, Safety, LAB
 Services & Blood Bank)

DR. UMA RANI
 MD, PATHOLOGY
 DIRECTOR


DR. SHILPA GUPTA
 MD, PATHOLOGY
 Associate Director

DR. SHARMILA RAI
 MD, PATHOLOGY
 Consultant

FINAL REPORT

Bill No.	: AFBHC240003221	Bill Date	: 23-03-2024 10:06
Patient Name	: MR. RANJIT R. SONI	UHID	: AFB000308843
Age / Gender	: 39 Yrs 5 Mth / MALE	Patient Type	: OPD <input type="checkbox"/> IF PHC <input type="checkbox"/>
Ref. Consultant	: SELF	Ward / Bed	: /
Sample ID	: AFB24098625	Current Ward / Bed	: /
		Receiving Date & Time	: 23-03-2024 12:34
		Reporting Date & Time	: 23-03-2024 14:56

CLINICAL PATH REPORTING

Test (Methodology)	Flag	Result	UOM	Biological Reference Interval
<i>Sample Type: Urine</i>				
MEDIWHEEL FULL BODY ANNUAL PLUS(WITH 2D)				
URINE-SUGAR (GOD POD Method)		Negative		Negative

**** End of Report ****

IMPORTANT INSTRUCTIONS

CL - Critical Low, CH - Critical High, H - High, L - Low

DR. RAMESH CHANDNA
 MD, MICROBIOLOGY, PGDHIM
 Chairman (Quality, Safety, LAB
 Services & Blood Bank)



DR. UMA RANI
 MD, PATHOLOGY
 DIRECTOR

DR. SHILPA GUPTA
 MD, PATHOLOGY
 Associate Director

DR. SHARMILA RAI
 MD, PATHOLOGY
 Consultant



Bill No.	: AFBHC240003221	Bill Date	: 23-03-2024 10:06
Patient Name	: MR. RANJIT R. SONI	UHID	: AFB000308843
Age / Gender	: 39 Yrs 5 Mth / MALE	Patient Type	: OPD
Ref. Consultant	: SELF	Ward / Bed	: /
Sample ID	: AFB24098421	Current Ward / Bed	: /
		Receiving Date & Time	: 23-03-2024 10:27
		Reporting Date & Time	: 23-03-2024 13:55

HAEMATOLOGY REPORTING

Test (Methodology)	Flag	Result	UOM	Biological Reference Interval
Sample Type: EDTA Whole Blood				
MEDIWHEEL FULL BODY ANNUAL PLUS(WITH 2D)				
ESR (Westergren)		9	mm 1st hr	0 - 10
CBC -1 (COMPLETE BLOOD COUNT)				
TOTAL LEUCOCYTE COUNT (Flow Cytometry)		9.0	thousand/cumm	4 - 11
RED BLOOD CELL COUNT (Hydro Dynamic Focussing)		4.8	million/cumm	4.5 - 5.5
HAEMOGLOBIN (SLS Hb Detection)		14.0	g/dL	13 - 17
PACK CELL VOLUME (Cumulative Pulse Height Detection)		42.2	%	40 - 50
MEAN CORPUSCULAR VOLUME		87.9	fL	83 - 101
MEAN CORPUSCULAR HAEMOGLOBIN		29.2	Pg	27 - 32
MEAN CORPUSCULAR HAEMOGLOBIN CONCENTRATION		33.2	g/dL	31.5 - 34.5
PLATELET COUNT (Hydro Dynamic Focussing)		179	thousand/cumm	150 - 400
RED CELL DISTRIBUTION WIDTH (S.D - RDW) (Particle Size Distribution)	L	38.6	fL	39 - 46
RED CELL DISTRIBUTION WIDTH (C.V.)		12.0	%	11.6 - 14
DIFFERENTIAL LEUCOCYTE COUNT				
NEUTROPHILS		66	%	40 - 80
LYMPHOCYTES		26	%	20 - 40
MONOCYTES		7	%	2 - 10
EOSINOPHILS		1	%	1 - 5
BASOPHILS		0	%	0 - 1
GLYCATED HAEMOGLOBIN (HBA1C)				
HBA1C (HPLC)	H	11.1	%	4.27 - 6.07

INTERPRETATION:

HbA1c %	Degree of Glucose Control
>8%	Action suggested due to high risk of developing long term complications like Retinopathy, Nephropathy, Cardiopathy and Neuropathy
7.1 - 8.0	Fair Control
<7.0	Good Control

Note:

1. A three monthly monitoring is recommended in diabetics.
2. Since HbA1c concentration represents the integrated values for blood glucose over the recent food intake, it is a more useful tool for monitoring diabetics.

End of Report

IMPORTANT INSTRUCTIONS

CL - Critical Low, CH - Critical High, H - High, L - Low

FINAL REPORT

Bill No. :	AFBHC240003221	Bill Date :	23-03-2024 10:06
Patient Name :	MR. RANJIT R. SONI	UHID :	AFB000308843
Age / Gender :	39 Yrs 5 Mth / MALE	Patient Type :	OPD
Ref. Consultant :	SELF	Ward / Bed :	/
Sample ID :	AFB24098421	Current Ward / Bed :	/
		Receiving Date & Time :	23-03-2024 10:27
		Reporting Date & Time :	23-03-2024 13:55

HAEMATOLOGY REPORTING

Test (Methodology)	Flag	Result	UOM	Biological Reference Interval
--------------------	------	--------	-----	-------------------------------

Sample Type: EDTA Whole Blood

MEDIWHEEL FULL BODY ANNUAL PLUS(WITH 2D)

ESR (Westergren)		9	mm 1st hr	0 - 10
------------------	--	---	-----------	--------

CBC -1 (COMPLETE BLOOD COUNT)

TOTAL LEUCOCYTE COUNT (Flow Cytometry)		9.0	thousand/cumm	4 - 11
RED BLOOD CELL COUNT (Hydro Dynamic Focusing)		4.8	million/cumm	4.5 - 5.5
HAEMOGLOBIN (I.S.S HB Detection)		14.0	g/dL	13 - 17
PACK CELL VOLUME (Cumulative Pulse Height Detection)		42.2	%	40 - 50
MEAN CORPUSCULAR VOLUME		87.9	fL	83 - 101
MEAN CORPUSCULAR HAEMOGLOBIN		29.2	pg	27 - 32
MEAN CORPUSCULAR HAEMOGLOBIN CONCENTRATION		33.2	g/dL	31.5 - 34.5
PLATELET COUNT (Hydro Dynamic Focusing)		179	thousand/cumm	150 - 400
RED CELL DISTRIBUTION WIDTH (S.D - RDW) (Particle Size Distribution)	L	38.6	fL	39 - 46
RED CELL DISTRIBUTION WIDTH (C.V.)		12.0	%	11.6 - 14

DIFFERENTIAL LEUCOCYTE COUNT

NEUTROPHILS		66	%	40 - 80
LYMPHOCYTES		26	%	20 - 40
MONOCYTES		7	%	2 - 10
EOSINOPHILS		1	%	1 - 5
BASOPHILS		0	%	0 - 1

GLYCATED HAEMOGLOBIN (HBA1C)

HBA1C (HPLC)	H	11.1	%	4.27 - 6.07
--------------	---	------	---	-------------

INTERPRETATION:

HbA1c %	Degree of Glucose Control
>8%	Action suggested due to high risk of developing long term complications like Retinopathy, Nephropathy, Cardiopathy and Neuropathy
7.1 - 8.0	Fair Control
<7.0	Good Control

Note: 1.A three monthly monitoring is recommended in diabetics.
 2.Since HbA1c concentration represents the integrated values for blood glucose over the recent food intake, it is a more useful tool for monitoring diabetics.

End of Report

IMPORTANT INSTRUCTIONS

CL - Critical Low, CH - Critical High, H - High, L - Low

FINAL REPORT

Bill No.	: AFBHC240003221	Bill Date	: 23-03-2024 10.06
Patient Name	: MR. RANJIT R. SONI	UHID	: AFB000308843
Age / Gender	: 39 Yrs 5 Mth / MALE	Patient Type	: OPD If PHC :
Ref. Consultant	: SELF	Ward / Bed	: /
Sample ID	: AFB24098421	Current Ward / Bed	: /
		Receiving Date & Time	: 23-03-2024 10.27
		Reporting Date & Time	: 23-03-2024 13.55

DR. RAMESH CHANDNA
MD, MICROBIOLOGY, PGDHHM
Chairman (Quality, Safety, LAB
Services & Blood Bank)

DR. UMA RANI
MD, PATHOLOGY
DIRECTOR

Shilpa
DR. SHILPA GUPTA
MD, PATHOLOGY
Associate Director

DR. SHARMILA RAI
MD, PATHOLOGY
Consultant

FINAL REPORT

Bill No. : AFBHC240003221	Bill Date : 23-03-2024 10:06
Patient Name : MR. RANJIT R. SONI	UHID : AFB000308843
Age / Gender : 39 Yrs 5 Mth / MALE	Patient Type : OPD If PHC :
Ref. Consultant : SELF	Ward / Bed : /
Sample ID : AFB24098754	Current Ward / Bed : /
	Receiving Date & Time : 23-03-2024 13:59
	Reporting Date & Time : 23-03-2024 14:45

BIOCHEMISTRY REPORTING

Test (Methodology)	Flag	Result	UOM	Biological Reference Interval
--------------------	------	--------	-----	-------------------------------

Sample Type: Plasma, Serum

MEDIWHEEL FULL BODY ANNUAL PLUS(WITH 2D)

GLUCOSE-PLASMA (FASTING) (UV Hexokinase)	H	199.0	mg/dL	70 - 100
--	---	-------	-------	----------

 Note: A diagnosis of diabetes mellitus is made if fasting blood glucose exceeds 126 mg/dL.
 (As per American Diabetes Association recommendation)

GLUCOSE-PLASMA (POST PRANDIAL) (UV Hexokinase)	H	306.0	mg/dL	70 - 140
--	---	-------	-------	----------

 Note: A diagnosis of diabetes mellitus is made if 2 hour post load glucose exceeds 200 mg/dL.
 (As per American Diabetes Association recommendation)

KFT/RFT- KIDNEY/RENAL PANEL 1

BLOOD UREA (Urea-GDH/Kinetic)		23	mg/dL	15 - 45
CREATININE-SERUM (Modified Jaffe's Kinetic)	L	0.6	mg/dL	0.9 - 1.3
SODIUM-SERUM (Indirect Ion-Selective Electrode)		137	m.mol/L	135 - 145
POTASSIUM-SERUM (Indirect Ion-Selective Electrode)		4.2	m.mol/L	3.5 - 5.1
CHLORIDE-SERUM (Indirect Ion-Selective Electrode)		104	m.mol/L	98 - 107


LIVER FUNCTION TESTS (LFT)

BILIRUBIN-TOTAL (DPO)	H	1.01	mg/dL	0.2 - 1.0
BILIRUBIN-DIRECT (DPO)		0.19	mg/dL	0 - 0.2
BILIRUBIN-INDIRECT	H	0.82	mg/dL	0.2 - 0.8
S.PROTEIN-TOTAL (Buret)		6.6	g/dL	6.6 - 8.3
ALBUMIN-SERUM (Dye Binding-Bromocresol Green)		4.0	g/dL	3.5 - 5.2
S.GLOBULIN	L	2.6	g/dL	2.8-3.8
A/G RATIO		1.54		1.5 - 2.5
ALKALINE PHOSPHATASE (IHC AMP BUFFER)		81.7	IU/L	53 - 128
ASPARTATE AMINO TRANSFERASE (SGOT) (IFCC)		29.2	IU/L	0 - 50
ALANINE AMINO TRANSFERASE(SGPT) (IFCC)		44.4	IU/L	0 - 50
GAMMA-GLUTAMYLTRANSPEPTIDASE (IFCC)		54.0	IU/L	0 - 55
LACTATE DEHYDROGENASE (IFCC, L-P)		133.5	IU/L	0 - 248

**** End of Report ****
IMPORTANT INSTRUCTIONS

CL - Critical Low, CH - Critical High, H - High, L - Low

Results are Verified By


DR. C.P. SHARMA
 Ph.D.(Biochemistry)
 BIOCHEMIST

FINAL REPORT

Bill No.	: AFBHC240003221	Bill Date	: 23-03-2024 10:06
Patient Name	: MR. RANJIT R. SONI	UHID	: AFB000308843
Age / Gender	: 39 Yrs 5 Mth / MALE	Patient Type	: OPD <input type="checkbox"/> If PHC <input type="checkbox"/>
Ref. Consultant	: SELF	Ward / Bed	: /
Sample ID	: AFB24098754	Current Ward / Bed	: /
		Receiving Date & Time	: 23-03-2024 13:59
		Reporting Date & Time	: 23-03-2024 14:45

Shilpa

DR. RAMESH CHANDNA
MD, MICROBIOLOGY, PGDHMM
Chairman (Quality, Safety, LAB
Services & Blood Bank)

DR. UMA RANI
MD, PATHOLOGY
DIRECTOR

DR. SHILPA GUPTA
MD, PATHOLOGY
Associate Director

DR. SHARMILA RAI
MD, PATHOLOGY
Consultant

FINAL REPORT

Bill No.	: AFBHC240003221	Bill Date	: 23-03-2024 10:06
Patient Name	: MR. RANJIT R. SONI	UHID	: AFB000308843
Age / Gender	: 39 Yrs 5 Mth / MALE	Patient Type	: OPD IF PHC :
Ref. Consultant	: SELF	Ward / Bed	: /
Sample ID	: AFB24098625	Current Ward / Bed	: /
		Receiving Date & Time	: 23-03-2024 12:34
		Reporting Date & Time	: 23-03-2024 14:56

CLINICAL PATH REPORTING

Test (Methodology)	Flag	Result	UOM	Biological Reference Interval
--------------------	------	--------	-----	-------------------------------

Sample Type: Urine

MEDIWHEEL FULL BODY ANNUAL PLUS(WITH 2D)
PHYSICAL EXAMINATION

QUANTITY	60 mL		
COLOUR	Yellow		Pale Yellow
TURBIDITY	Clear		

CHEMICAL EXAMINATION

PH (Double pH Indicator method)	5.0		5.0 - 8.5
PROTEINS (Protein-error of indicators)	1+		Negative
SUGAR (GOD POD Method)	Negative		Negative
SPECIFIC GRAVITY, URINE (Apparent gfa change)	1.030		1.005 - 1.030
UROBILINOGEN (Modified Erlich Reaction)	Normal		NORMAL
BILIRUBIN (Azo Coupling)	Negative		NEGATIVE
KETONES (Acetoacetic acid reaction with sodium nitroprusside)	Negative		
NITRITE (Diazotization-reduction)	Negative		NEGATIVE

MICROSCOPIC EXAMINATION

LEUCOCYTES	1-2	/HPF	0 - 5
RBCS	Nil		
EPITHELIAL CELLS (URINE)	1-2		
CASTS	Nil		
CRYSTALS	Nil		

**** End of Report ****
IMPORTANT INSTRUCTIONS

CL - Critical Low, CH - Critical High, H - High, L - Low


DR. RAMESH CHANDNA
 MD, MICROBIOLOGY, PGDHMM
 Chairman (Quality, Safety, LAB
 Services & Blood Bank)

DR. UMA RANI
 MD, PATHOLOGY
 DIRECTOR

DR. SHILPA GUPTA
 MD, PATHOLOGY
 Associate Director

DR. SHARMILA RAI
 MD, PATHOLOGY
 Consultant



DEPARTMENT OF RADIO-DIAGNOSIS & IMAGING

Report : ULTRASOUND

Patient Name	: MR. RANJIT R. SONI	IPD No.	:	
Age	: 39 Yrs 5 Mth	UHID	:	AFB000308843
Gender	: MALE	Bill No.	:	AFBHC240003221
Ref. Doctor	: SELF	Bill Date	:	23-03-2024 10:06:04
Ward	:	Room No.	:	
		Print Date	:	24-03-2024 15:57:26

USG Abdomen:

Sonographic evaluation of the abdomen & pelvis was performed with a curvilinear transducer, in transverse and longitudinal planes, with gray scale and color Doppler evaluations.

Liver: Measures ~19cms in size- **Enlarged in size and increased in texture.** No evidence of any focal lesions / IHBRD noted. Normal Portal vein caliber noted.

GB: Well-distended; Normal wall-thickness noted. The lumen appears echofree at present scan. CBD is normal in calibre.

Spleen: Normal in size and normal in texture.

Pancreas: Visualized parts are normal in size and texture. No evidence of any focal lesions / calcifications noted.

Kidneys: Normal in size, shape and echotexture; CMD maintained bilaterally. No evidence of any hydronephrosis noted bilaterally.

Urinary Bladder: Well distended; Normal wall thickness noted. No evidence of any calculi noted.

Prostate: Normal in size and normal in echotexture. No evidence of any calcifications / focal lesions noted.

Visualized bowel shows normal wall thickness and peristaltic movements. No evidence of any sonographically significant free fluid noted.


IMPRESSION: Sonographic features are suggestive of:

- **Hepatomegaly with grade II hepatosteatosis- (Suggested LFT and fibroscan correlation).**

Suggested: Clinical correlation.

.....End of Report.....

Prepare By.
IMAGING


DR. RAVI GARG, MD (Radiodiagnosis),
Fellowship in Sonography, Specialist in
Fetal Medicine,
Consultant

Note : The information in this report is based on interpretation of images. This report is not the diagnosis and should be correlated with clinical details and other investigation.

DEPARTMENT OF RADIO-DIAGNOSIS & IMAGING

Report : XRAY

Patient Name	: MR. RANJIT R. SONI	IPD No.	:	
Age	: 39 Yrs 5 Mth	UHID	:	AFB000308843
Gender	: MALE	Bill No.	:	AFBHC240003221
Ref. Doctor	: SELF	Bill Date	:	23-03-2024 10 05 04
Ward	:	Room No.	:	
		Print Date	:	23-03-2024 17 25 03

CHEST PA VIEW:

Cardiac shadow appears normal.

Both lung fields appear clear.

Both domes of diaphragm and both CP angles are clear.


Both hila appear normal.

Soft tissues and bony cage appear normal.

Please correlate clinically.

.....End of Report.....

Prepare By.
IMAGING


DR. GUR PRASAD VASHIST, MBBS, MD
Radio-diagnosis

Note : The information in this report is based on interpretation of images. This report is not the diagnosis and should be correlated with clinical details and other investigation.