


<b>Name</b> : Mr. SHANKAR D K  <b>Address</b> : 12 SHESH PARAGI SHANKAR DK PUTTANA ROAD BASAVANAGUDI  <b>Plan</b> : ARCOFEMI MEDIWHEEL MALE AHC CREDIT PAN INDIA OP AGREEMENT	<b>Age:</b> 33 Y  <b>Sex:</b> M	<b>UHID:</b> CBAS.0000037632  <small>*CBAS.0000037632*</small> <b>OP Number:</b> CBASOPV99993 <b>Bill No :</b> CBAS-OCR-60771 <b>Date</b> : 10.02.2024 09:56
---	---------------------------------------	---

Sno	Service Type/ServiceName	Department
1	ARCOFEMI - MEDIWHEEL - FULL BODY ANNUAL PLUS MALE - 2D ECHO - PAN INDIA - FY2324	
1	GAMMA GLUTAMYL TRANSFERASE (GGT)	
<del>2</del>	<del>2</del> D-ECHO <i>- Penchis</i>	
<del>3</del>	<del>3</del> LIVER FUNCTION TEST (LFT)	
<del>4</del>	<del>4</del> GLUCOSE, FASTING	
<del>5</del>	<del>5</del> HEMOGRAM + PERIPHERAL SMEAR	
6	DIET CONSULTATION <i>- Pen</i>	
7	COMPLETE URINE EXAMINATION	
<del>8</del>	<del>8</del> URINE GLUCOSE (POST PRANDIAL)	
<del>9</del>	<del>9</del> PERIPHERAL SMEAR	
<del>10</del>	<del>10</del> ECG	
11	RENAL PROFILE/RENAL FUNCTION TEST (RFT/KFT)	
12	DENTAL CONSULTATION	
13	GLUCOSE, POST PRANDIAL (PP), 2 HOURS (POST MEAL)	
14	URINE GLUCOSE (FASTING)	
15	HbA1c, GLYCATED HEMOGLOBIN	
16	X-RAY CHEST PA	
17	ENT CONSULTATION <i>- Pen</i>	
18	FITNESS BY GENERAL PHYSICIAN	
19	BLOOD GROUP ABO AND RH FACTOR	
<del>20</del>	<del>20</del> LIPID PROFILE	
<del>21</del>	<del>21</del> BODY MASS INDEX (BMI)	
<del>22</del>	<del>22</del> OPHTHAL BY GENERAL PHYSICIAN	
<del>23</del>	<del>23</del> ULTRASOUND - WHOLE ABDOMEN	
24	THYROID PROFILE (TOTAL T3, TOTAL T4, TSH)	

Physio -> (6)

Dental -> (10)

HA -> 168cm  
 WT -> 71.3kg  
 Hip -> 85cm  
 wid -> 92cm  
 B.P -> 118/75  
 PP -> 95

Date: IST: 2024-02-10 13:35:59

Personal Details  
UHID: 01P3FGAT6SN11RK  
PatientID: 555555  
Name: MR SHANKAR  
Age: 33  
Gender: Male  
Mobile: 576867676798

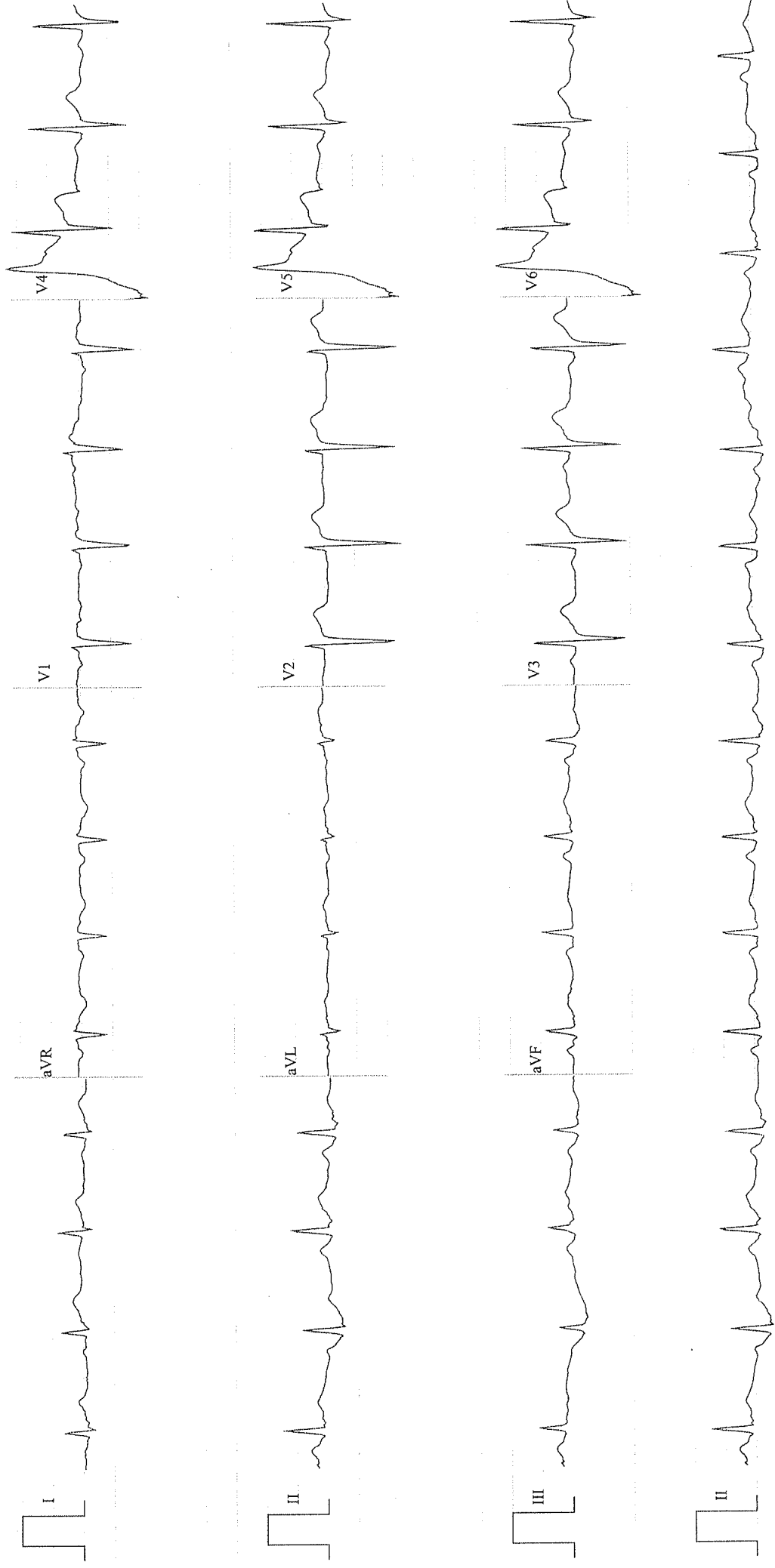
Vitals

Measurements  
HR: 92 BPM  
PR: 160 ms  
PD: 122 ms  
QRSD: 85 ms  
QRS Axis: 60 deg  
QT/QTc: 320/320 ms

Interpretation

Sinus Rhythm Regular  
Normal Axis

This trace is generated by KardioScreen: Cloud-Connected, Portable, Digital, 6-12 Lead Scalable ECG Platform from IMEDRIX



Speed: 25 mm/sec F: 0.05 - 40 Hz Limb: 10 mm/mV Chest: 10 mm/mV  
Disclaimer: This report is based on ECG alone and should be used in conjunction with clinical history, symptoms and results of other non-invasive tests and must be interpreted by a qualified physician.  
Normal ECG does not rule out heart disease. Abnormal ECG does not always mean severe heart disease. Comments & report is based on available data. Clinical correlation is important.

Mr. Shankar DK 33/M 37632

10/2/24

EYE CHECK UP REPORT

Vision Acuity { 6/6  
unaided  
6/6

Digital IOP { (2)  
(2)

Near Vision { N26  
unaided  
N26

Colour Vision { Normal  
Normal

• Fundus: Normal @ study

• Ant. Segment :- normal

• Media: normal

• Pupil: normal

AKS



**Fwd: Health Check up Booking Request(bobS8594), Beneficiary Code-135299**

shankar dk <dkshankar01@gmail.com>

Fri 09-02-2024 16:33

To: Vanivilas Road , Bengaluru South Region <VJVANI@bankofbaroda.com>

You don't often get email from dkshankar01@gmail.com. [Learn why this is important](#)

**\*\*सावधान:** यह मेल बैंक डोमेन के बाहर से आया है. अगर आप प्रेषक को नहीं जानते तो मेल में दी गयी  
**\*\*CAUTION:** THIS MAIL IS ORIGINATED FROM OUTSIDE OF THE BANK'S DOMAIN. DO NOT

----- Forwarded message -----

From: **Mediwheel** <[wellness@mediwheel.in](mailto:wellness@mediwheel.in)>

Date: Thu, 8 Feb 2024, 12:15

Subject: Health Check up Booking Request(bobS8594), Beneficiary Code-135299

To: <[dkshankar01@gmail.com](mailto:dkshankar01@gmail.com)>

Cc: <[customercare@mediwheel.in](mailto:customercare@mediwheel.in)>

**011-41195959**

Dear MR. D K SHANKARA,

We have received your booking request for the following health checkup, please upload HRM Letter as soon as possible.

[Upload HRM Letter](#)

**Booking Date** : 08-02-2024

**User Package Name** : Mediwheel Full Body Health Checkup Female Below 40

**Hospital Package Name** : Mediwheel Full Body Health Annual Plus Check

**Health Check Code** : PKG10000377

**Name of Diagnostic/Hospital** : Apollo Clinic - Basavanagudi

**Address of Diagnostic/Hospital-** Apollo Clinic, # 99, Bull Temple Road , Next to Ramakrishna mutt, Basavanagudi - 560019

**Appointment Date** : 10-02-2024

**Preferred Time** : 8:00am

Member Information		
Booked Member Name	Age	Gender
Ashwini C P	25 year	Female

**Patient Name** : Mr. SHANKAR D K

**Age/Gender** : 33 Y/M

**UHID/MR No.** : CBAS.0000037632

**OP Visit No** : CBASOPV99993

**Sample Collected on** :

**Reported on** : 10-02-2024 18:08

**LRN#** : RAD2232331

**Specimen** :

**Ref Doctor** : SELF

**Emp/Auth/TPA ID** : 351459

## DEPARTMENT OF RADIOLOGY

### ULTRASOUND - WHOLE ABDOMEN

**Liver:** appears normal in size (13.0 cm) and increased in echotexture. No focal lesion is seen. Portal vein and Common Bile Duct appear normal. No dilatation of the intrahepatic biliary radicals.

**Gall bladder** is well distended. No evidence of calculus. Wall thickness appears normal. No evidence of periGB collection. No evidence of focal lesion is seen.

**Spleen** appears normal. No focal lesion seen. Splenic vein appears normal.

**Pancreas** appears normal in echo-pattern. No focal/mass lesion/calcification. No evidence of peripancreatic free fluid or collection. Pancreatic duct appears normal.

**Right kidney** appear normal in size 9.4x1.2 cm, shape and echopattern. Cortical thickness and Cortico-medullary differentiation are maintained.

**Left kidney** appear normal in size 9.9x1.1 cm, shape and echopattern. Cortical thickness and Cortico-medullary differentiation are maintained.

**Urinary Bladder** is well distended and appears normal. No evidence of any wall thickening or abnormality. No evidence of any intrinsic or extrinsic bladder abnormality detected.

**Prostate** is normal in size (volume 15 cc) and echo texture.

- No thickened or tender bowel loops. No mass lesion. No ascites / pleural effusion.


-

### **IMPRESSION:-**

**GRADE I FATTY LIVER.**

### **Suggested clinical correlation.**

(The sonography findings should always be considered in correlation with the clinical and other investigation finding where applicable.) It is only a professional opinion, Not valid for medico legal purpose.



**Dr. V K PRNAV VENKATESH**  
**MBBS,MD**  
Radiology