

Metro Hospital & Heart Institute, Haridwar

Health Check-up Certificate

COMPANY... Mediwheel

EMPLOYEE NO. 076474 DEPTT. BOB Cchowk DATE 27-01-24

NAME Mrs. Ruchi Tiwari AGE/SEX 35y/F DOB 15-6-1988

DESIGNATION Business Associate MOBILE NO 8077784201

CHEST (INSP) ✓ cm. CHEST (EXP) ✓ cm. CHEST EXPANSION ✓ cm

HEIGHT 144 cm. WEIGHT 68 Kg. BMI.....

P/R 80b/m per mt. BP 100/50 mmHg SIGN OF EMP Dr

EXAMINATION/INVESTIGATIONS

No	Investigations	Room No	Result
✓ 1	LAB INVESTIGATIONS	Path Lab	Hb <u>14.5 g/dl</u> TLC <u>5370</u> /DLC <u>(N)</u>
✓ 2	BLOOD SUGAR F/PP/RANDOM	Path Lab	F /PP /RBS <u>135mg/dl</u>
✓ 3	BLOOD GROUP	Path Lab	<u>B⊕</u>
✓ 4	URINE	Path Lab	<u>(N)</u>
✓ 5	STOOL	Path Lab	<u>SNR</u>
✓ 6	X RAY CHEST PA	Radiology	<u>(N)</u>
✓ 7	ULTRASONOGRAPHY (Whole Abd)	Radiology	<u>(N)</u>
✓ 8	ECC	Health check up	<u>(N)</u>
✓ 9	ECHO	Radiology	<u>(N)</u>
10	TMT	Radiology	
11	PFT	Health check up	
12	AUDIOMETRY	25	
13	ENT EXAM	25	
14	DENTAL EXAMINATION	24	
✓ 15	ACUITY OF VISION/COLOUR VISION	13	<u>Normal B/E</u>
✓ 16	EXAMINATION BY PHYSICIAN	23	<u>fit for Job</u>
17	Pap Smear		

Observations -

DR. NITIN KUMAR

MBBS MD

Consultant General Medicine

Reg. No. U/G-5845

Metro Hospital & Heart Institute

SIDCUL, Haridwar-249403 (U.K.)

Subject: Health Check up Booking Confirmed Request(bobE6651),Package Code-PKG10000475, Beneficiary Code-282633

Mediwheel <wellness@mediwheel.in>

Sent: Thu, 25 Jan 2024 17:57:32 GMT+0530

To: You

Cc: customercare@mediwheel.in

MedSave

011-41195959

Hi **Metro Hospital & Heart Institute**,

We have received the confirmation for the following booking. Please provide your confirmation by clicking on the yes and no button.

Hospital Package Name : Mediwheel Full Body Health Checkup Female Below 40

Patient Package Name : Mediwheel Full Body Health Checkup Female Below 40

Package Code : PKG10000475

Contact Details : 8077784201

Email : Ruchi.Tiwari@bankofbaroda.co.in

Booking Date : 25-01-2024

Appointment Date : 27-01-2024

Confirmation Status: Booking Confirmed

Preferred Time : 9:00am

Member Information

Booked Member Name	Age	Gender
MRS. TIWARI RUCHI	35 year	Female

We request you to facilitate the employee on priority.

Thanks,
Mediwheel Team

You have received this mail because your e-mail ID is registered with This is a system-generated e-mail **Arcofemi Healthcare Limited**, please don't reply to this message.

Please visit to our Terms & Conditions for more informaion. This email is recieved because you are register with us Click here to unsubscribe.

@ 2024 - 25, Arcofemi Healthcare Pvt Limited.(Mediwheel)



LETTER OF APPROVAL / RECOMMENDATION

To,

The Coordinator,
Mediwheel (Arcofemi Healthcare Limited)
Helpline number: 011- 41195959

Dear Sir / Madam,

Sub: Annual Health Checkup for the employees of Bank of Baroda

This is to inform you that the following employee wishes to avail the facility of Cashless Annual Health Checkup provided by you in terms of our agreement.

PARTICULARS	EMPLOYEE DETAILS
NAME	MRS. TIWARI RUCHI
EC NO.	76474
DESIGNATION	SINGLE WINDOW OPERATOR A
PLACE OF WORK	HARIDWAR,NB DHARAMSHALA
BIRTHDATE	15-06-1988
PROPOSED DATE OF HEALTH CHECKUP	10-02-2024
BOOKING REFERENCE NO.	23M76474100084276E

This letter of approval / recommendation is valid if submitted along with copy of the Bank of Baroda employee id card. This approval is valid from **16-01-2024** till **31-03-2024** The list of medical tests to be conducted is provided in the annexure to this letter. Please note that the said health checkup is a **cashless facility** as per our tie up arrangement. We request you to attend to the health checkup requirement of our employee and accord your top priority and best resources in this regard. The EC Number and the booking reference number as given in the above table shall be mentioned in the invoice, invariably.

We solicit your co-operation in this regard.

Yours faithfully,

Sd/-

Chief General Manager
HRM Department
Bank of Baroda

(Note: This is a computer generated letter. No Signature required. For any clarification, please contact Mediwheel (Arcofemi Healthcare Limited))



भारतीय विशिष्ट पहचान प्राधिकरण

भारत सरकार
Unique Identification Authority of India
Government of India

नमोद्वयन क्रम / Enrollment No. : 0000/00528/44180

To
Ruchi Shukla
रुचि शुक्ला
W/O Atul Kumar
Quarter No 71
Type 3
Sector 5b
Bhel, Ranipur
Ranipur Range
Bhel, Haridwar,
Uttarakhand - 249403
8192000531
72014540
10/01/2015
KA720145405FH



आपका आधार क्रमांक / Your Aadhaar No. :

4592 1135 6486

मेरा आधार, मेरी पहचान



भारत सरकार
Government of India



रुचि शुक्ला
Ruchi Shukla
जन्म तिथि / DOB: 15/06/1988
लिंग / Gender

(Handwritten signature)



4592 1135 6486

मेरा आधार, मेरी पहचान



सूचना

- आधार पहचान का प्रमाण है, नागरिकता का नहीं।
- पहचान का प्रमाण ऑनलाइन प्रमाणीकरण द्वारा प्राप्त करें।

INFORMATION

- Aadhaar is proof of identity, not of citizenship .
- To establish identity, authenticate online .

- आधार देश भर में मान्य है।
- आधार भविष्य में सरकारी और गैर-सरकारी सेवाओं का लाभ उठाने में उपयोगी होगा।
- Aadhaar is valid throughout the country .
- Aadhaar will be helpful in availing Government and Non-Government services in future .



भारतीय विशिष्ट पहचान प्राधिकरण
Unique Identification Authority of India

पता: अतुल कुमार, बर्दौर नं. 71, टाईप 3, सेक्टर 5 बी, भेल,
छोपूर, रामपुर रेंज, भेल, हरिद्वार, उत्तराखण्ड, 249403



Address: W/O Atul Kumar, Quarter No 71, Type
3, Sector 5b, Bhel, Ranipur, Ranipur Range,
Bhel, Haridwar, Uttarakhand, 249403

4592 1135 6486



1947



help@uidai.gov.in



www.uidai.gov.in



METRO
HOSPITAL & HEART INSTITUTE
(A unit of Sunhill Hospitals Private Limited)
(NABH & ISO 9001: 2008 Certified)



we treat...HE CURES

**Metro Hospital
& Heart Institute**

(A unit of Sunhill Hospital Private Limited)

OPD CONSULTATION

Patient Name Mrs. Ruchi Tiwari Age/Sex 25/F Reg. No. _____

Doctor's Name Dr. Sushil Kumar

Date 27/07/24 Time _____

OPHTHALMIC EXAMINATION

VISION

DISTANCE VISION-

Rt 6/6
Lt 6/6

NEAR VISION-

Rt N6
Lt N6

COLOUR VISION

Normal ISE

EYE EXAMINATION

- Cornea
- Ant Chamber
- Pupil
- Fundus Examination

ADVICE-

Dr. Sushil Kumar, MBBS, MD (Ophtho)
Consultant Ophthalmologist
Metro Hospital & Heart Institute
Signature _____
Siccul, Haridwar, Reg. No.-2572 (UK)

Plot No. F-1, Sector-6A, SIDCUL, Haridwar - 249 403

Emergency : +91 8191902600, Phone : 01334 - 239040 / 42 / 43, Fax : 01334 - 239043

E-mail : metroharidwar@metrohospitals.com, Website: www.metrohospitals.com

Regd. Office : 21, Community Center, Preet Vihar, New Delhi-110092

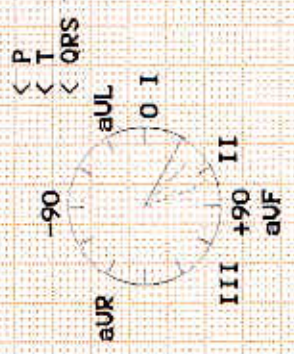
CIN No.: U33201DL2006PTC156918

MHHI/CL/0115/Rev. No. 01

Mrs. Ruchi Arora
354/F
27-01-24

Measurement Results:

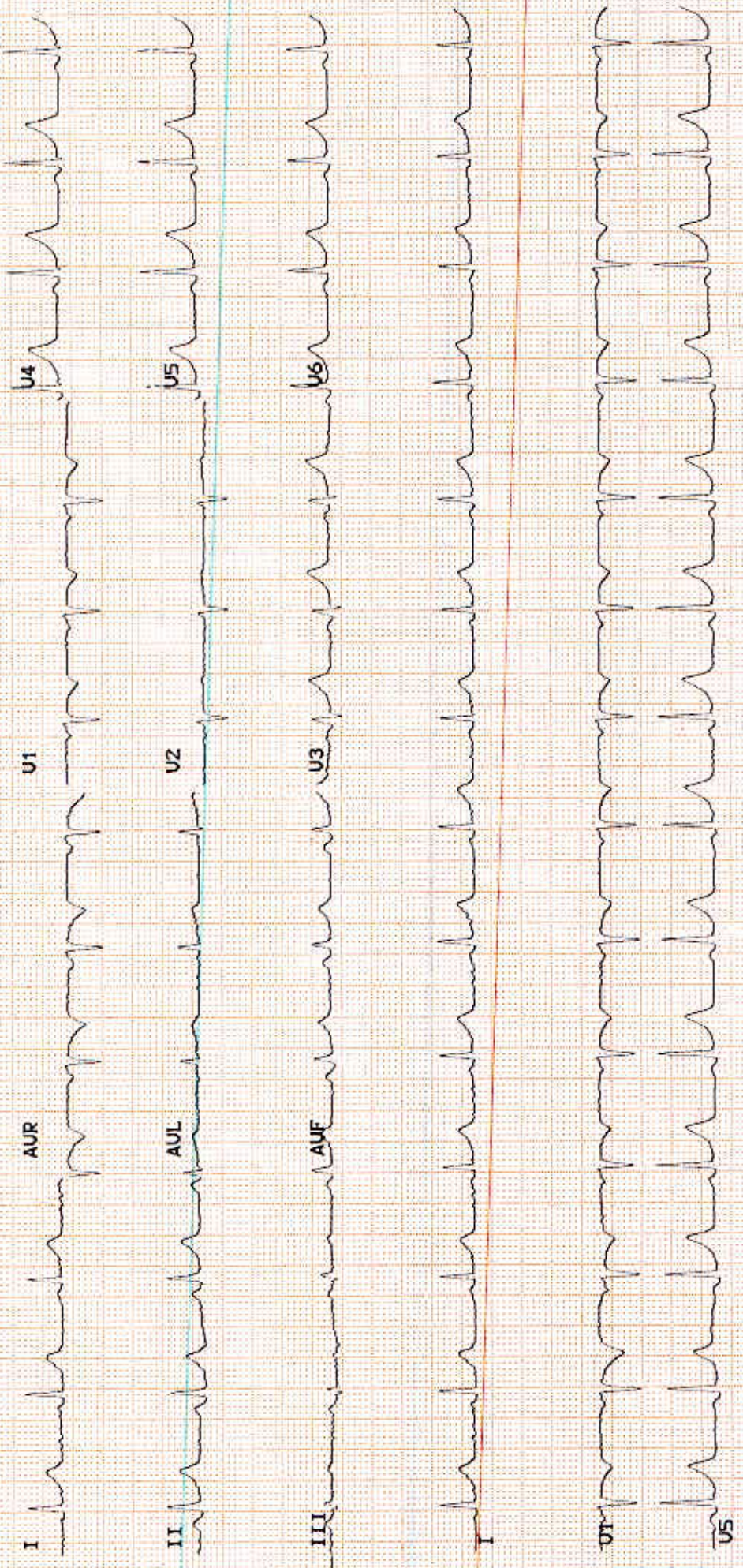
QRS	:	82 ms
QT/QTcB	:	366 / 430 ms
PR	:	114 ms
P	:	94 ms
RR/pp	:	726 / 720 ms
P/QRS/T	:	70/ 30/ 45 degrees
QT/QTcBD	:	64 / 75 ms
Sokolow	:	1.5 mV
NK	:	12

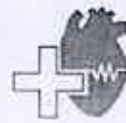

Interpretation:
short PR interval
low QRS amplitudes
probably abnormal ECG



unconfirmed report.





METRO

HOSPITAL & HEART INSTITUTE

(A unit of Sunhill Hospitals Private Limited)

(NABH & ISO 9001: 2008 Certified)

Radiology Investigation Report (Provisional)

Name : Mrs. RUCHI TIWARI
Ref. By : Dr. NITIN KUMAR
IP/OP : OP/202314561
Date : 27/01/2024

Age/Sex : 35 Y/F
UHID NO : 2024000875
Request No : 70247075

USG WHOLE ABDOMEN

The diaphragm is normal in contour & respiratory excursion. There is no ascitis or lymph node mass.

Liver is normal in shape, outline & echotexture. No focal lesion of abnormal ecogenecity is seen. Intrahepat biliary radicles are not dilated. Portal vein & portal venous radicles are normal.

Gall bladder is well distended, its outlines are smooth & its wall are not thick. No calculus /mass lesion is see in its lumen. Common bile duct is normal in course & caliber. No calculus is seen in its lumen.

Spleen & pancreas appears normal in shape, size, outline & echotexture.

Both the kidneys are normal in shape, size, outline & echotexture. Renal parenchymal thickness is norma Corticomedullary junction is defined & is normal. There is no hydronephrosis. No echogenic renal calculus seen.

Urinary bladder is normal in contour & capacity. Bladder wall is not thick. No pathological filling defect / vesic calculus is seen in bladder. Ureterovesical junctions appear normal.

Uterus is normal in size shape, outline & echotexture. Myometrial & endometrial echoes are normal. No uterin mass is seen. Both the ovaries appear normal. There is no free fluid seen in cul de sac.

IMPRESSION : NORMAL STUDY


DR. PRAKASH CHANDRA PANDEY
MBBS, DMRD
CONSULTANT RADIOLOGIST

Note:

- (1) Not Valid for medical-legal purposes.
- (2) This is a professional opinion based on imaging finding and not the diagnosis.
- (3) In case of any discrepancy due to machine error or typing error, please get it rectified immediately.

Plot No. F-1, Sector-6A, SIDCUL, Haridwar - 249 403

Emergency : +91 8191902600, Phone : 01334 - 239040 / 42 / 43, Fax : 01334 - 239043

E-mail : metroharidwar@metrohospitals.com, Website: www.metrohospitals.com

Regd. Office : 21, Community Center, Preet Vihar, New Delhi-110092

CIN No.: U33201DL2006PTC156918

MHHI/CL/0115/Rev. No. 01



Pathology Report

Name : Mrs. RUCHI TIWARI
Ref. By : Dr. NITIN KUMAR
IP/OP : OP/202314561
Sample Date : 27/01/2024
Reporting Date: 27/01/2024

Age/Sex : 35 Y/F
UHID : 2024000875
Request No. : 10389131
Sample Time : 10:51
Reporting Time : 20:59

Test	Result	Unit	Bio. Ref.	Inter. Test Method
Hematology				
CBC (COMPLETE BLOOD COUNT/HAEMOGRAM)				
HB	14.5	gm/dl	F - 11.5-15	
TLC	5370	/cumm	4000-11000	
DLC (WBC DIFFERENTIAL)				
NEUTROPHILS	50	%	45-75	
LYMPHOCYTES	40	%	25-45	
EOSINOPHILS	04	%	1-6	
MONOCYTES	06	%	2-8	
BASOPHILS	00	%	--<2	
RBC	5.13	million	3.5-5.5	
PCV	47.8	%	36-52	
MCV	93.2	fL	80-100	
MCH	28.3	PG	27-32	
PLATELET COUNT	30.3	gm/dl	31-37	
RDW	1.53	lakh/cumm	1.5-4.5	
BLOOD GROUP	13.7	%	11.5-15	
ABO	B	-	-	
Rh	POSITIVE	-	-	
ESR	14.0	mm/hr	20	
Serology & Immunology				
THYROID PROFILE				
T3	2.42	nmol/L	1.70-3.10	
T4	10.2	µg/dl	5.95-15.4	
TSH	1.59	µIU/L	0.46-4.68	

*** End of Reports ***

Dr. Vishal Arora
MBBS, DCP
(Consultant Pathologist)



Checked By

Note:

1. These reports are mere estimation of values at that particular time and are liable to vary/change in different conditions in different laboratories.
2. The values are to be collaborated with clinical findings by qualified doctor and any alarming and unexpected results should be reported to Lab urgently for recheck and manual typing errors.
3. These reports are not valid for medicolegal purposes and all doctor unsigned reports should be considered provisional only.
4. All card based tests are screening test therefore need confirmation by other alternative test like (PCR, ELISA).



Pathology Report

Name : Mrs. RUCHI TIWARI
 Ref. By : Dr. NITIN KUMAR
 IP/OP : OP/202314561
 Sample Date : 27/01/2024
 Reporting Date: 27/01/2024

Age/Sex : 35 Y/F
 UHID : 2024000875
 Request No. : 10389131
 Sample Time : 10:51
 Reporting Time : 20:59

Test	Result	Unit	Bio. Ref. Inter.	Test Method
Biochemistry				
HBIAC	5.0	%	4.5-6.3	
BLOOD SUGAR -FASTING	84.0	mg/dl	70.0-110.0	
BLOOD SUGAR -PP	92.0	mg/dl	70.0-140.0	
LIPID PROFILE				
TOTAL CHOLESTEROL	159.0	mg/dl	00-250.0	
HDL-CHOLESTEROL	50.0	mg/dl	00-50.0	
LDL	89.4	mg/dl	00-150.0	
TRIGLYCERIDES	98.0	md/dl	30-150	
VLDL	19.6	mg/dl	0-50	
CHOL/HDL Ratio	3.1		<4.5	
LFT (LIVER FUNCTION TEST)				
BILIRUBIN INDIRECT	0.30	mg/dl	0.2-0.8	
SGOT	27.0	U/L	10-42	
SGPT	24.0	U/L	10-42	
BILIRUBIN TOTAL	0.67	mg/dl	0.2-1.0	
ALKALINE PHOSPHATASE	100.0	IU/L	28-111	
BILIRUBIN DIRECT	0.37	mg/dl	0.1-0.4	
TOTAL PROTEIN	6.7	gm/dl	6.4-8.2	
ALBUMIN	3.4	g/dl	3.5-5.0	
GLOBULIN	3.3	gm/dl	2.0-4.0	
AG RATIO	1.0		-	
KFT (KIDNEY FUNCTION TEST)				
UREA	18.2	mg/dl	15-45	
SODIUM	134.0	mmol/L	135-155	
CREATININE	0.72	mg/dl	0.6-1.3	
URIC ACID	4.7	mg/dl	3.0-7.6	
BUN	8.6	mg/dl	05-20	
POTTASSIUM	5.4	mmol/L	3.5-5.5	
CALCIUM	8.0	mg/dl	8.5-10.5	

*** End of Reports ***

Dr. Vishal Arora
 MBBS, DCP
 (Consultant Pathologist)



Checked By

Note:

1. These reports are mere estimation of values at that particular time and are liable to vary/change in different conditions in different laboratories.
2. The values are to be collaborated with clinical findings by qualified doctor and any alarming and unexpected results should be reported to Lab urgently for recheck and manual typing errors.
3. These reports are not valid for medicolegal purposes and all doctor unsigned reports should be considered provisional only.
4. All card based tests are screening test therefore need confirmation by other alternative test like (PCR, ELISA).

Plot No. F-1, Sector-6A, SIDCUL, Haridwar - 249 403

Emergency : +91 8191902600, Phone : 01334 - 239040/42/43, Fax : 01334 - 239043

E-mail : metroharidwar@metrohospitals.com, Website: www.metrohospitals.com

Regd. Office : 21, Community Center, Preet Vihar, New Delhi-110092

CIN No.: U33201DL2006PTC156918

MHHI/CL/0115/Rev. No. C


Pathology Report

Name : Mrs. RUCHI TIWARI
 Ref. By : Dr. NITIN KUMAR
 IP/OP : OP/202314561
 Sample Date : 27/01/2024
 Reporting Date: 27/01/2024

Age/Sex : 35 Y/F
 UHID : 2024000875
 Request No. : 10389131
 Sample Time : 10:51
 Reporting Time : 20:59

Test	Result	Unit	Bio. Ref. Inter.	Test Method
Urine Examination				
URINE SUGAR	NIL			
URINE ROUTINE ANALYSIS				
PHYSICAL EXAMINATION				
COLOUR	STRAW			
TRANSPARENCY	CLEAR			
S. GRAVITY	1.030			
CHEMICAL EXAMINATION				
ALBUMIN	NIL			
SUGAR	NIL			
pH	6.0			
BLOOD	NIL			
KETONE	NIL			
MICROSCOPIC EXAMINATION				
PUS CELLS	2-3			
EPITHELIAL CELLS	1-2			
RBC	NIL			
CRYSTALS	NIL			
CAST	NIL			
BACTERIA	NIL			
AMORPHOUS PHOSPHATE	NIL			
AMORPHOUS URATES	NIL			

*** End of Reports ***

Dr. Vishal Arora
 MBBS, DCP
 (Consultant Pathologist)



Checked By

Note:

1. These reports are mere estimation of values at that particular time and are liable to vary/change in different conditions in different laboratories.
2. The values are to be collaborated with clinical findings by qualified doctor and any alarming and unexpected results should be reported to Lab urgently for recheck and manual typing errors.
3. These reports are not valid for medicolegal purposes and all doctor unsigned reports should be considered provisional only.
4. All card based tests are screening test therefore need confirmation by other alternative test like (PCR, ELISA).

Plot No. F-1, Sector-6A, SIDCUL, Haridwar - 249 403

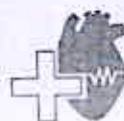Emergency : +91 8191902600, Phone : 01334 - 239040 / 42 / 43, Fax : 01334 - 239043

E-mail : metroharidwar@metrohospitals.com, Website: www.metrohospitals.com

Regd. Office : 21, Community Center, Preet Vihar, New Delhi-110092

CIN No.: U33201DL2006PTC156918

MHHI/CL/0115/Rev. No. 01



METRO

HOSPITAL & HEART INSTITUTE

(A unit of Sunhill Hospitals Private Limited)

(NABH & ISO 9001: 2008 Certified)


Radiology Investigation Report

Name	: Mrs. RUCHI TIWARI	Age/Sex	: 35 Y/F
Ref. By	: Dr. NITIN KUMAR	UHID NO	: 2024000875
IP/OP	: OP/202314561	Request No	: 70247075
Date	: 27/01/2024		

X-RAY CHEST PA View

Cardiac contour & size are normal.
Trachea is central.
Lung fields are clear.
Hilar shadows are normal.
Costophrenic angles are clear.
Bony rib cage is normal.

IMPRESSION: NORMAL CHEST.


DR. PRAKASH CHANDRA PANDEY
MBBS, DMRD
CONSULTANT RADIOLOGIST



Note:

- (1) Not Valid for medical-legal purposes.
- (2) This is a professional opinion based on imaging finding and not the diagnosis.
- (3) In case of any discrepancy due to machine error or typing error, please get it rectified immediately.

2D ECHOCARDIOGRAPHY

Name:	Mrs. Ruchi Tiwari	UHID No:	2024000875
Age/Sex:	35Y/F	Ward:	OPD
Referred by:	Dr. Nitin Kumar	Date:	27.01.2024

ACOUSTIC WINDOW: Normal

MEASUREMENTS AND CALCULATIONS

Measurements	Observed Value	Reference Value
IVS (ED)	0.9	(0.6 – 1.1 cm)
LVPW (ED)	1.0	(0.6 – 1.1 cm)
LVID (ED)	3.7	Male (3.7 – 5.5 cm) Female (3.7 – 5.2 cm)
Aortic root diameter	2.0	(2.0 – 3.7 cm)
LA dimension	2.5	Male (1.9 – 4.0 cm) Female (1.7 – 3.8 cm)
LV EF	55%	(55 – 75%)

MORPHOLOGICAL DATA

Mitral valve	Normal	Right Atrium	Normal
Aortic valve	Normal	Right Ventricle	Normal
Tricuspid valve	Normal	PA	Normal
Pulmonary valve	Normal	IVS	Intact
		IAS	Intact

DOPPLER STUDY

Valve	Regurges	Velocities (cm/s)	Gradients (mmHg)
Mitral	Mild	E – 104, A – 72, E/A>1	
Aortic	Nil	Vel – 155	
Tricuspid	Mild	Vel – 279	PASP – 35
Pulmonary	Nil	Vel – 117	

FINAL IMPRESSION

- Normal Acoustic Window
- Normal chambers dimensions
- No RWMA
- LVEF~55%
- No LVDD
- Mild MR, Mild TR, PASP 35 mmHg
- No pericardial effusion
- No Intracardiac clot



Ajit Kumar

Dr. Krishna CK

MD, DNB (Medicine), DNB (Cardiology)
Consultant Interventional Cardiology
UKMC Reg. No: 12883

Dr. Ajit Kumar

MBBS, PGDCC
Associate Consultant, Cardiology
UKMC Reg. No: 7569

(Note: This document is not for medico-legal purpose)