



MER- MEDICAL EXAMINATION REPORT

Date of Examination	09 / 08 / 2024		
NAME	Rupesh More		
AGE	32	Gender: Male	
HEIGHT(cm)	164	WEIGHT(kg):	BMI: 26.4
B.P.	120 / 80 mm hg		
ECG	Report Attached		
X Ray	Report Attached		
Vision Checkup:	Left Eye		Right Eye
	Distance Vision:	6/6	6/6
	Near Vision:	6/6	6/6
	Color Vision:	Normal	
ENT / Audiometry Checkup	-		
Present Ailments	No		
Details of Past ailments (If Any)	No		
Comments / Advice : She /He is Physically Fit	He is physically fit		
No Medical History			

Dr. Jai B. Raisinghani

M.D., Card.
Clinical Cardiologist
Reg. No. 20981 (MCI)

Signature with Stamp of Medical Examiner

भारत सरकार
Government of India

रुपेश एक्नाथ मोरे
Rupesh Eknath More
जन्म तारीख / DOB: 06/03/1982
पुरुष / Male

Issue Date: 20/09/2011

7491 7807 5278

माझे आधार, माझी ओळख

Dr. Jai B. Raisinghani
M.D., D. Card.
Clinical Cardiologist
Reg. No. 20061 (MCI)



Penon

Patient Name : Rupesh More	Patient ID : AHCN-34006082401006
Age/Sex : 32 Years /Male	Register Date : 09 Aug, 2024
Ref. By : Apollo Health - Arcofemi - Mediwheel	Reported Date : 09 Aug, 2024

CBC with ESR

Investigation	Observed Value		Biological Reference Interval	Unit
Hemoglobin (Hb)	12.1	Low	13 - 17	g/dL
Hemoglobin %	71.18		0 - 100	
Total RBC Count	6.84	High	4.5 - 5.5	mill/cumm
Packed Cell Volume (PCV)	39.1	Low	40.7 - 50.3	%
Mean Corpuscular Volume(MCV)	57.16		78.2 - 97.90	fL
Mean Corpuscular Hemoglobin (MCH)	17.69		27 - 33	pg/cell
Mean Corpuscular Hemoglobin Concentration (MCHC)	30.95		33 - 36	g/dL
Hematocrit Value (Hct)	39.1	Low	40 - 50	%
Red cell Distribution Width (RDW)	16.8	High	11.5 - 14	%
Total WBC Count	6053		4000 - 11000	cumm
Neutrophils	65		40 - 70	%
Lymphocytes	30		20 - 40	%
Eosinophils	02		1 - 4	%
Monocytes	03		1 - 6	%
Basophils	00		0 - 1	%
Platelet Count	276000		150000 - 450000	/cumm
Erythrocyte Sedimentation Rate (ESR)	11		0 - 22	mm/hr



Dr. S N Tripathi
M.D. (Path)
Reg No. 2000/04/1994

The above result relate only to the specimens received and tested in laboratory and should be always correlate with clinical findings and other laboratory markers.

Kalyan Group of Institutions
Opp Chetna School, Malang Gad Road, Kalyan East,
Maharashtra - 421 306.

Contact: 96197 91666 / 98209 81915
Email : info@knahealthcare.com

Sune: Block No. 9, First Floor, Above Laxmi Sweet
Mart, 335, Rasta Peth, Pune - 411011

Contact: 020 2997 2669 / 99708 24521
Email: rppune@knahealthcare.com
W : www.knahealthcare.com

Patient Name : Rupesh More	Patient ID : AHCN-34006082401006
Age/Sex : 32 Years /Male	Register Date : 09 Aug, 2024
Ref. By : Apollo Health - Arcofemi - Mediwheel	Reported Date : 09 Aug, 2024

Investigation	Observed Value	Biological Reference Interval	Unit
---------------	----------------	-------------------------------	------

Indirect, Direct & Total Bilirubin

Indirect, Direct & Total Bilirubin

Indirect Bilirubin	0.33	0.2 - 0.8	mg/dL
Direct Bilirubin	0.16	0 - 0.3	mg/dL
Total Bilirubin	0.49	0 - 2.0	mg/dL

Fasting Glucose And Post Prandial Glucose

Fasting Blood Glucose	91.42	70 - 110	mg/dL
Fasting Urine Glucose	Absent		
Fasting Urine ketone	Absent		
Post Prandial Blood Glucose	98.63	70 - 140	mg/dL
Post Prandial Urine Glucose	SNR		
Post Prandial Urine ketone	SNR		

SGPT (ALT)

SGPT (ALT)	44.6	High 00 - 40	U/L
------------	------	--------------	-----

Interpretation

SGPT exists predominantly in the liver and leaks into the bloodstream when produced in excess. The SGPT normal range is about 0 - 28 units per liter of blood serum. Thus, very high level of SGPT in the blood can be an indication of damage or problems related to the liver.

Serum Creatinine

Serum Creatinine	0.84	0.60 - 1.40	mg/dL
------------------	------	-------------	-------

BUN / Creatinine Ratio

BUN / Creatinine Ratio	13.6		
------------------------	------	--	--

*****END OF REPORT*****



Dr. S N Tripathi
M.D. (Path)
Reg No. 2000/04/1994

The above result relate only to the specimens received and tested in laboratory and should be always correlate with clinical findings and other laboratory markers.

Kalyan - Opp Chetna School, Malang Gad Road, Kalyan East, Maharashtra - 421 306.

Contact: 96197 91666 / 98209 81915
Email : info@knahealthcare.com

Pune: Block No. 9, First Floor, Above Laxmi Sweet Mart, 335, Rasta Peth, Pune - 411011

Contact: 020 2997 2669 / 99708 24521
Email: rppune@knahealthcare.com
W : www.knahealthcare.com

Patient Name : Rupesh More	Patient ID : AHCN-34006082401006
Age/Sex : 32 Years /Male	Register Date : 09 Aug, 2024
Ref. By : Apollo Health - Arcofemi - Mediwheel	Reported Date : 09 Aug, 2024

BLOOD GROUP, ABO & RH TYPING

Blood Group, ABO & RH Typing

Investigation	Observed Value	Biological Reference Interval	Unit
ABO Group	A		
RH Factor	Positive		

The test to determine your blood group is called ABO typing. Your blood sample is mixed with antibodies against type A and B blood. Then, the sample is checked to see whether or not the blood cells stick together. If blood cells stick together, it means the blood reacted with one of the antibodies.

Rhesus (Rh) factor is an inherited protein found on the surface of red blood cells. **If your blood has the protein, you're Rh positive. If your blood lacks the protein, you're Rh negative.**



Dr. S N Tripathi
M.D. (Path)
Reg No. 2000/04/1994

The above result relate only to the specimens received and tested in laboratory and should be always correlate with clinical findings and other laboratory markers.

Kalyan Branch: Opp Chetna School, Malang Gad Road, Kalyan East, Maharashtra - 421 306.

Contact: 96197 91666 / 98209 81915
Email : info@knahealthcare.com

Pune: Block No. 9, First Floor, Above Laxmi Sweet Mart, 335, Rasta Peth, Pune - 411011
Contact: 020 2997 2669 / 99708 24521
Email: rppune@knahealthcare.com
W : www.knahealthcare.com

Patient Name : Rupesh More	Patient ID : AHCN-34006082401006
Age/Sex : 32 Years /Male	Register Date : 09 Aug, 2024
Ref. By : Apollo Health - Arcofemi - Mediwheel	Reported Date : 09 Aug, 2024

Urine Examination Routine

Urine Examination Routine

Investigation	Observed Value	Biological Reference Interval	Unit
Quantity	20ml		ml
Appearance clear	Clear		
Colour	Pale yellow		
PH	6.5	5.0 - 8.0	
Specific Gravity	1.015	1.005 - 1.030	
Proteins	Absent		
Glucose	Absent		
Ketones	Absent		
Bilirubin	Absent		
Urobilinogen	Absent		
Leucocyte Esterase	Absent		
Nitrite	Absent		
Occult Blood	Absent		
R.B.C.	Absent		
Pus Cells	2-4	0 - 5	WBC / hpf
Epithelial Cells	1-1	0 - 2	/hpf
Casts	Absent	0 - 0	/lpf
Crystals	Absent		
Amorphous Material	Absent		
Bacteria	Absent		



Dr. S N Tripathi
M.D. (Path)
Reg No. 2000/04/1994



Carliv Medical Pvt. Ltd.

45-Rupesh More
32 Yrs / M / Non-Smoker
Ht/Wt: 164 Cms / 71 Kgs

KNA HEALTH CARE

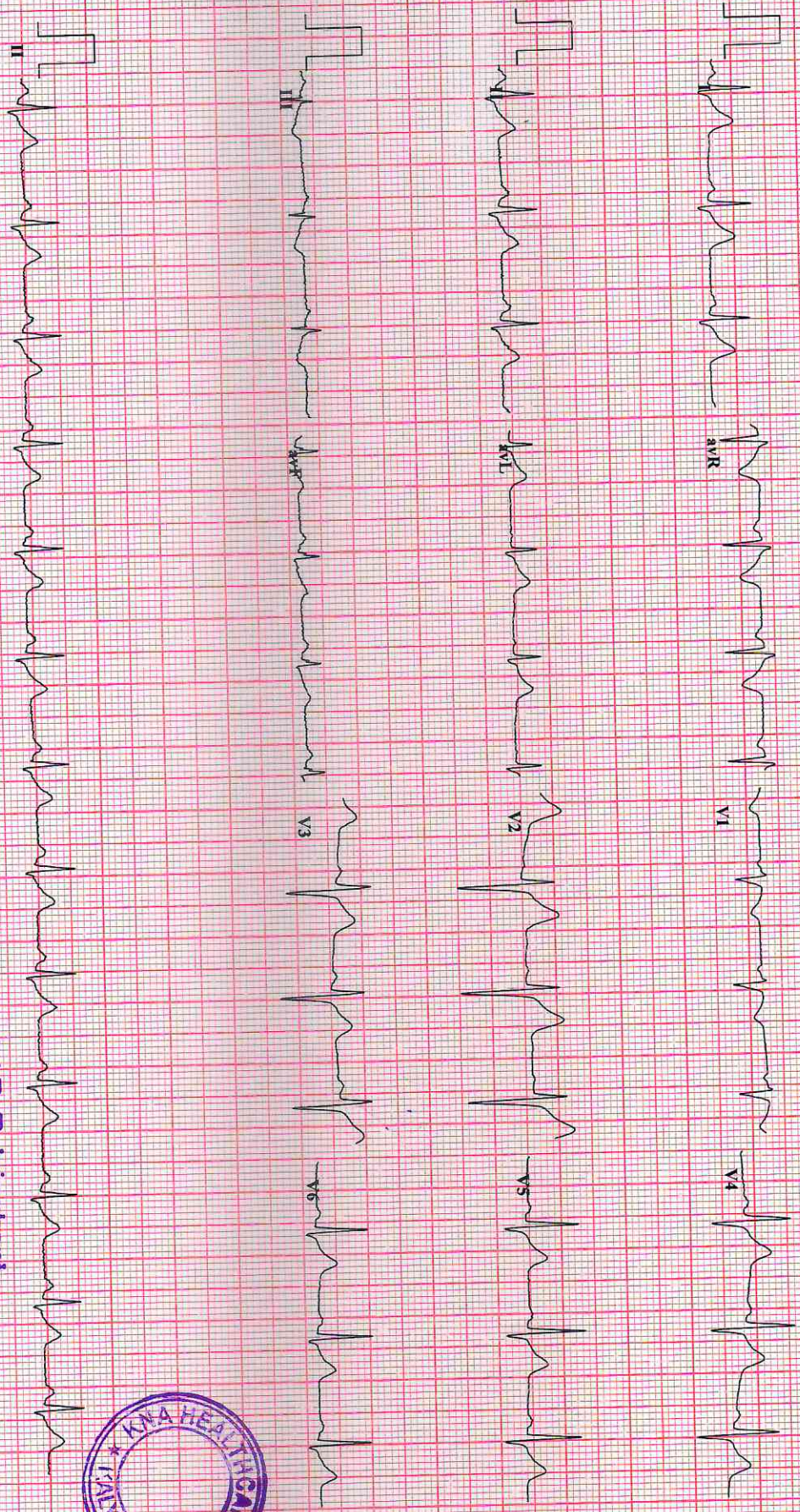
Kna Healthcare Karyan East (Mumbai)

Date-Time : 09-08-24 - 12:41
Ref. By :
BP(mmHg) : / /

Sweep : 25 mm/Sec
Gain : 10 mm/mV
Filter/Notch : 0.1-35Hz/Off

HeartRate : 77
P Interval : 100 msec
PR Interval : 142 msec
QRS Interval : 87 msec
QT Interval : 355 msec
QTc Interval : 402 msec
P axis : +55°
QRS axis : +38°
T axis : +14°

[Signature]



Normal ECG

Within Normal limits

Dr. Jai B. Raisinghani

M.D./D. Card.
Clinical Cardiologist
Reg. No. 28981 (MCI)

Dr. Jai Raisinghani
MD Cardiologist





SHREE GANESH DIAGNOSTIC CENTER

Let's do good...

SONOGRAPHY | COLOR DOPPLER | DIGITAL X-RAY | PATHOLOGY

Dr. Abhishek Singh

MBBS, DMRE, FMF (Mumbai)

Consultant Radiologist & Sonologist

Previous post in

- 1) Krishna Scan (Chennai)
- 2) Premier Scan (Kerala)
- 3) Bhabha Atomic Research Centre (Chembur, Mumbai)
- 4) Lokmanya Tilak Hospital (Sion, Mumbai)
- 5) Maharishi Valmiki Hospital (Delhi)

Name of Patient :- RUPESH MORE	Age/Sex: 32Years/MALE
	Date: 09/08/2024

RADIOGRAPH OF CHEST PA VIEW

Both the lung fields are clear.

The broncho vascular markings are appears normal.

The hilar shadows are appears normal.

Both Cardio phrenic and Cost phrenic angles are clear.

The Cardiac silhouette is within normal limits.

Aortic shadow is normal.

Both domes of diaphragms are normal.

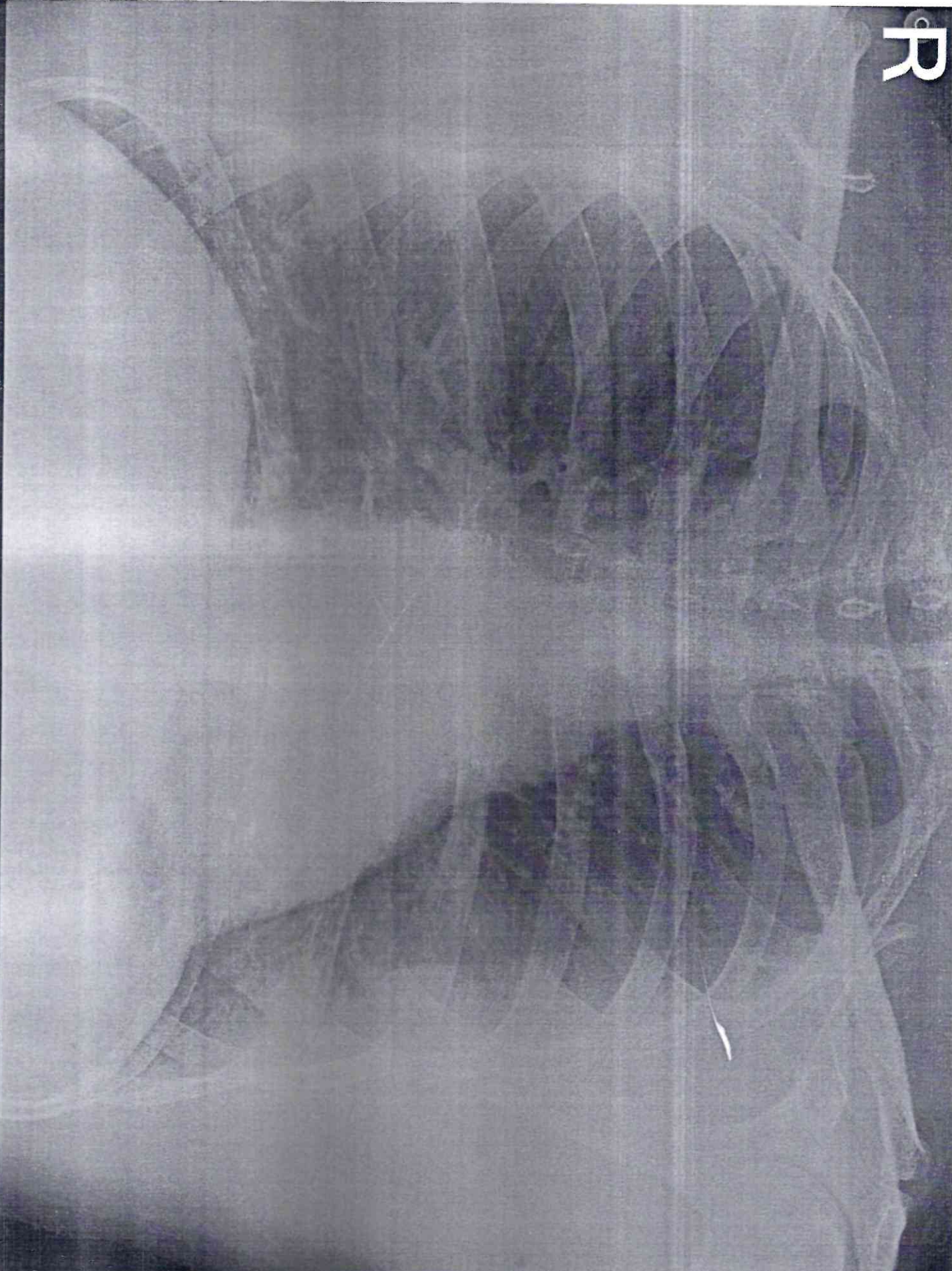
The visualised bony thorax is normal.

CONCLUSION : No Active Pulmonary Parenchymal Lesion is seen.

Abhishek

DR ABHISHEK SINGH,
MBBS DMRE FMF
CONSULTANT RADIOLOGIST

R



RUPESH MORE 32 Y M 9 8 24 02 CHEST,FRN P->A 09-Aug-24
SHREE GANESH DIAGNOSTIC CLINIC