

# PACE HOSPITALS

Hitech City: Beside Avasa Hotel, Pillar No. 18, Hyderabad - 81. T: 040 4848 6868  
 Miyapur: Beside South India Shopping, Madinaguda, Hyderabad - 50, T:040 48486767

## DEPARTMENT OF BIOCHEMISTRY

Patient Name	: Mr. MANGALA DILLI GANESH	Age / Sex	: 30 Y(s)/Male
Ref By	: Dr. GENERAL PHYSICIAN	UMR No	: UMR105814
Bill Date	: 10-Aug-24 08:53 am	Bill No	: BIL185890
Lab No	: BIO/24/8/755	Result No	: RES545058
Samp.Coll	: 10-Aug-24 09:08 am	Auth. Tim	: 10-Aug-2024 11:26 am
Reported On	: 10-Aug-24 11:26 am		

<u>Parameter</u>	<u>Result</u>	<u>Biological Reference Interval</u>	<u>Method</u>
<b>THYROID PROFILE</b>			Specimen Serum
T3-Free (Tri#odothyronine#Free)	: 3.4	2.0 - 4.2 pg/mL	C L I A
T4-Free (Thyroxine #Free)	: 15.8	8.9 - 17.2 pg/ml	C L I A
TSH(Thyroid Stimulating Hormone).	: 1.6	0.3 - 4.5 µIU/ml	C L I A
<b>LIPID PROFILE: SERUM</b>			Specimen Serum
Triglycerides	: 135	BorderLine : 150 - 199 mg/dl High : 200 - 500 mg/dl Normal : < 150 mg/dl	GPO-Trinder End Point
Total Cholesterol	: 238	< 200 mg/dl	CHOD-PAP End Point
HDL Cholesterol	: 45	Undesirable : < 40 Optimal : 40 - 59 Desirable : > 60	
VLDL Cholesterol	: 27	2 - 30 mg/dl	
LDL Cholesterol	: 166	0 - 100 mg/dl	
Cholestrol / HDL Ratio	: 5.29	1.0 - 3.5	
Serum Uric Acid	: 6.3	3.5 - 7.2 mg/dl	Uricase-Peroxidase
Blood Urea Nitrogen(BUN)	: 11.7	6 - 21 mg/dl	GLDH - Urease
Serum Creatinine	: 0.8	0.4 - 1.2 mg/dl	Jaffe Kinetic
<b>LFT- LIVER FUNCTION TESTS</b>			Specimen Serum
Total Bilirubin	: 1.1	0.2 - 1.2 mg/dl	Diazo
Direct Bilirubin	: 0.4	0.0 - 0.3 mg/dl	Diazo
Indirect Bilirubin	: 0.7	0.2 - 0.7 mg/dL	

# PACE HOSPITALS

Hitech City: Beside Avasa Hotel, Pillar No. 18, Hyderabad - 81. T: 040 4848 6868  
Miyapur: Beside South India Shoping, Madinaguda, Hyderabad - 50, T:040 48486767

## DEPARTMENT OF BIOCHEMISTRY

Patient Name	: Mr. MANGALA DILLI GANESH	Age / Sex	: 30 Y(s)/Male
Ref By	: Dr. GENERAL PHYSICIAN	UMR No	: UMR105814
Bill Date	: 10-Aug-24 08:53 am	Bill No	: BIL185890
Lab No	: BIO/24/8/755	Result No	: RES545059
Samp.Coll	: 10-Aug-24 09:08 am	Auth. Tim	: 10-Aug-2024 11:26 am
Reported On	: 10-Aug-24 11:26 am		

<u>Parameter</u>	<u>Result</u>	<u>Biological Reference Interval</u>	<u>Method</u>
SGPT	: 24	< 41 IU/L	IFCC - Kinetic
SGOT	: 17	< 40 IU/L	IFCC - Kinetic
AST / ALT -Ratio	: 0.71		
Alkaline Phosphatase	: 99	< 115 U/L	AMP Kinetic
Total Protein	: 7.1	6.4 - 8.3 gm/dl	Biuret Method
Serum Albumin	: 4.3	3.5 - 5.2 gm/dl	BCG Dye
Serum Globulin	: 2.8	2.0 - 3.5 g/dL	
Albumin / Globulin Ratio	: 1.54	1.2 - 2.2	
Glycated Haemoglobin - HbA1c	: 5.4	Non Diabetic : < 5.7 Pre Diabetic : 5.7 - 6.4 Diabetic : >= 6.5	Immunoturbidimetry

--- End Of Report ---

PHH8506

Dr.B PRATHYUSHA  
MD BIOCHEMIST  
CONSULTANT BIOCHEMIST

Dr.Y NIHARIKA REDDY  
M.D PATHOLOGY  
CONSULTANT PATHOLOGIST

Dr.SAMATHA  
MD Microbiology  
CONSULTANT MICROBIOLOGIST

# PACE HOSPITALS

Hitech City: Beside Avasa Hotel, Pillar No. 18, Hyderabad - 81. T: 040 4848 6868  
Miyapur: Beside South India Shoping, Madinaguda, Hyderabad - 50, T:040 48486767

## DEPARTMENT OF HAEMATOLOGY

Patient Name	: Mr. MANGALA DILLI GANESH	Age / Sex	: 30 Y(s)/Male
Ref By	: Dr. GENERAL PHYSICIAN	UMR No	: UMR105814
Bill Date	: 10-Aug-24 08:53 am	Bill No	: BIL185890
Lab No	: 185890	Result No	: RES545023
Samp.Coll	: 10-Aug-24 09:08 am	Auth. Tim	: 10-Aug-2024 10:26 am
Reported On	: 10-Aug-24 10:26 am		

<u>Parameter</u>	<u>Result</u>	<u>Method</u>
<b>BLOOD GROUPING &amp; RH TYPING</b>		
BLOOD GROUP	: " B "	Specimen Blood Agglutination
RH TYPING	: POSITIVE	
<b>COMPLETE BLOOD PICTURE</b>		
Haemoglobin	: 15.0 gm%	13.0 - 17.0 gm%
RBC Count	: 5.2 Millions/cumm	4.5-6.5 Millions/cumm
PCV	: 44 Vol%	40 - 50 Vol%
Platelet count	: 3.14 Lakhs/Cumm	1.5 - 4.5 Lakhs/Cumm
WBC Count	: 7,670 cells/cumm	4000 - 11000 cells/cumm
<b><u>DIFFERENTIAL COUNT</u></b>		
NEUTROPHILS	: 52 %	40-75 %
LYMPHOCYTES	: 41 %	20 - 45 %
EOSINOPHILS	: 01 %	2-6 %
MONOCYTES	: 06 %	2-8 %
BASOPHILS	: 00 %	0 - 2 %
<b><u>SMEAR EXAMINATION</u></b>		
RBC	:	Normocytic / Normochromic
WBC	:	With In Normal Limits
Platelets	:	Adequate

--- End Of Report ---

PHH8624

# PACE HOSPITALS

Hitech City: Beside Avasa Hotel, Pillar No. 18, Hyderabad - 81. T: 040 4848 6868  
Miyapur: Beside South India Shopping, Madinaguda, Hyderabad - 50, T:040 48486767

## DEPARTMENT OF HAEMATOLOGY

Patient Name	: Mr. MANGALA DILLI GANESH	Age / Sex	: 30 Y(s)/Male
Ref By	: Dr. GENERAL PHYSICIAN	UMR No	: UMR105814
Bill Date	: 10-Aug-24 08:53 am	Bill No	: BIL185890
Lab No	: HEM/24/8/528	Result No	: RES545116
Samp.Coll	: 10-Aug-24 09:08 am	Auth. Tim	: 10-Aug-2024 12:38 pm
Reported On	: 10-Aug-24 12:38 pm		

<u>Parameter</u>	<u>Result</u>	<u>Biological Reference Interval</u>
------------------	---------------	--------------------------------------

---

Dr.B PRATHYUSHA  
MD BIOCHEMIST  
CONSULTANT BIOCHEMIST

Dr.Y NIHARIKA REDDY  
M.D PATHOLOGY  
CONSULTANT PATHOLOGIST

Dr.SAMATHA  
MD Microbiology  
CONSULTANT MICROBIOLOGIST

# PACE HOSPITALS

Hitech City: Beside Avasa Hotel, Pillar No. 18, Hyderabad - 81. T: 040 4848 6868  
Miyapur: Beside South India Shoping, Madinaguda, Hyderabad - 50, T:040 48486767

## DEPARTMENT OF CLINICAL PATHOLOGY

Patient Name	: Mr. MANGALA DILLI GANESH	Age / Sex	: 30 Y(s)/Male
Ref By	: Dr. GENERAL PHYSICIAN	UMR No	: UMR105814
Bill Date	: 10-Aug-24 08:53 am	Bill No	: BIL185890
Lab No	: 185290	Result No	: RES545039
Samp.Coll	: 10-Aug-24 09:08 am	Auth. Tim	: 10-Aug-2024 11:15 am
Reported On	: 10-Aug-24 11:15 am		

<u>Parameter</u>	<u>Result</u>	<u>Biological Reference Interval</u>	<u>Method</u>
<b>COMPLETE URINE EXAMINATION</b>			
			Specimen Urine
<u>PHYSICAL EXAMINATION:</u>			
Colour	: Pale Yellow		
Appearance	: Clear		
pH	: 5.5	5.5 - 7.0	pH indicator
Specific gravity	: 1.010	1.010 - 1.025	Bromthymol blue indicator
<u>CHEMICAL EXAMINATION:</u>			
Urine for Sugar	: Nil	0 - 2.8 mmol/L	GOD-POD
Protein	: Trace	0 - 0.15 g/L	protein error of indicator
Blood	: Nil	0 - 10 Cells/ $\mu$ L	
Bilirubin	: Nil	0 - 0 $\mu$ mol/L	Diazonium method
NITRITE	: Absent	13 - 22 $\mu$ mol/L	
Leukocytes	: Nil	05 - 15 leuco/ $\mu$ L	
Ketone bodies	: Negative	0 - 0 mmol/L	Nitroprusside reaction
<u>MICROSCOPIC EXAMINATION:</u>			
Pus Cells	: 1-2	0 - 5 /HPF	
Epithelial Cells	: 0-1	0 - 8 /HPF	
RBC COUNT	: Nil	0 - 2 /HPF	
Casts	: Nil		
Crystals	: Nil		
Others	:	Nil	
<b>ESR - ERYTHROCYTE SEDIMENT RATE</b>			
			Specimen Blood
ESR - ERYTHROCYTE SEDIMENTATION RATE	: 12	< 15 mm	

--- End Of Report ---

# PACE HOSPITALS

Hitech City: Beside Avasa Hotel, Pillar No. 18, Hyderabad - 81. T: 040 4848 6868  
Miyapur: Beside South India Shopping, Madinaguda, Hyderabad - 50, T:040 48486767

## DEPARTMENT OF CLINICAL PATHOLOGY

Patient Name	: Mr. MANGALA DILLI GANESH	Age / Sex	: 30 Y(s)/Male
Ref By	: Dr. GENERAL PHYSICIAN	UMR No	: UMR105814
Bill Date	: 10-Aug-24 08:53 am	Bill No	: BIL185890
Lab No	: 185890	Result No	: RES545061
Samp.Coll	: 10-Aug-24 09:08 am	Auth. Tim	: 10-Aug-2024 11:15 am
Reported On	: 10-Aug-24 11:15 am		

<u>Parameter</u>	<u>Result</u>	<u>Biological Reference Interval</u>
------------------	---------------	--------------------------------------



PHH8624  
Verified by

Dr. POTTURU BHARAT, DNB, D.I.P RC PATH  
CONSULTANT PATHOLOGIST

Dr.B PRATHYUSHA  
MD BIOCHEMIST  
CONSULTANT BIOCHEMIST

Dr.Y NIHARIKA REDDY  
M.D PATHOLOGY  
CONSULTANT PATHOLOGIST

Dr.SAMATHA  
MD Microbiology  
CONSULTANT MICROBIOLOGIST



EYE CHECKUP

NAME: Mangala Dilli Ganesh . AGE: 30 GENDER: MALE / FEMALE  
 UMR NO: 105814 . CONSULTANT NAME: SAIVENNELA.P

CHIEF COMPLAINTS:

General checkup.  
 15/20 x 15/20 15/20 x 15/20

MEDICAL HISTORY:

— Nil —

REFRACTION & VISION:

UNAIDED		AIDED $\pm$ 0.25		COLOR VISION	
OD	OS	OD	OS	OD	OS
DISTANCE: 3/60 3/60		6/6 6/6		2/25 2/25	
NEAR: N6 N6		N6 N6			

SUBJECTIVE REFRACTION:

	SPH	CYL	AXIS	ADD	BCVA	BNCVA
OD:						
OS:						

PLAN OF CARE:

SIGNATURE

## DEPARTMENT OF CARDIOLOGY

<b>Patient Name</b> : Mr. MANGALA DILLI GANESH	<b>Age /Sex</b> : 30 Y(s)/Male
<b>Ref By</b> : Dr. GENERAL PHYSICIAN	<b>UMR No</b> : UMR105814
<b>Bill Date</b> : 10-Aug-24 08:53 am	<b>Bill No</b> : BIL185890
<b>Lab No</b> : 0	<b>Result No</b> : RES545083
<b>Samp.Coll</b> : 10-Aug-24 08:53 am	<b>Auth. Tim</b> :
<b>Reported On</b> : 10-Aug-24 11:16 am	

### 2D ECHO / TMT

MITRAL VALVE	:	Normal	
TRICUSPID VALVE	:	Normal	
AORTIC VALVE	:	Trileaflets	
PULMONARY VALVE	:	Normal	
RIGHT ATRIUM	:	Normal	
RIGHT VENTRICLE	:	TAPSE=2.1cm	
LEFT ATRIUM	:	3.3cm	
LEFT VENTRICLE	:	EDD:4.5cm FS:39%	IVS:8mm
LVEF	:	ESD:2.7cm 70%	LVPW:8mm
IAS	:	Intact	
IVS	:	Intact	



## DEPARTMENT OF CARDIOLOGY

<b>Patient Name</b> : Mr. MANGALA DILLI GANESH	<b>Age /Sex</b> : 30 Y(s)/Male
<b>Ref By</b> : Dr. GENERAL PHYSICIAN	<b>UMR No</b> : UMR105814
<b>Bill Date</b> : 10-Aug-24 08:53 am	<b>Bill No</b> : BIL185890
<b>Lab No</b> : 0	<b>Result No</b> : RES545083
<b>Samp.Coll</b> : 10-Aug-24 08:53 am	<b>Auth. Tim</b> :
<b>Reported On</b> : 10-Aug-24 11:16 am	

AORTA	:	2.4cm
IVC	:	Collapse
PULMOANRY VEINS	:	Normal
PERICARDIUM	:	No effusion
INTRACARDIAC MASSES	:	Nil
SVC/IVC/CS	:	Normal
PJV	:	0.8m/sec
AJV	:	1.1m/sec
MVF-E	:	0.8m/sec
MVF-A	:	0.6m/sec
NO MR, NO AR, NO TR	:	NO MR/AS/AR/TR/PH

## DEPARTMENT OF CARDIOLOGY

<b>Patient Name</b> : Mr. MANGALA DILLI GANESH	<b>Age /Sex</b> : 30 Y(s)/Male
<b>Ref By</b> : Dr. GENERAL PHYSICIAN	<b>UMR No</b> : UMR105814
<b>Bill Date</b> : 10-Aug-24 08:53 am	<b>Bill No</b> : BIL185890
<b>Lab No</b> : 0	<b>Result No</b> : RES545083
<b>Samp.Coll</b> : 10-Aug-24 08:53 am	<b>Auth. Tim</b> :
<b>Reported On</b> : 10-Aug-24 11:16 am	

IMPRESSION :

NO LV RWMA  
GOOD LV/RV FUNCTION  
NORMAL LV DIASTOLIC FUNCTION  
NO MR/AS/AR/TR/PH  
LEFT AORTIC ARCH; NO CoA  
NO CLOT/PE/VEGETATION

**Dr. DEVUPALLI SRAVAN, DM  
CARDIOLOGY(SJICR)**

**CONSULTANT CARDIOLOGIST**

Page 3 of 3

**DEPARTMENT OF BIOCHEMISTRY**

<b>Patient Name</b> : Mr. MANGALA DILLI GANESH	<b>Age /Sex</b> : 30 Y(s)/Male
<b>Ref By</b> : Dr.GENERAL PHYSICIAN	<b>UMR No</b> : UMR105814
<b>Bill Date</b> : 10-Aug-24 08:53 am	<b>Bill No</b> : BIL185890
<b>Lab No</b> : BIO/24/8/755	<b>Result No</b> : RES545059
<b>Samp.Coll</b> : 10-Aug-24 09:08 am	<b>Auth. Tim</b> : 10-Aug-2024 4:59 pm
<b>Reported On</b> : 10-Aug-24 04:59 pm	


**BLOOD SUGAR FASTING AND POST PRANDIAL**

<u>Parameter</u>	<u>Result</u>	<u>Biological Reference Interval</u>	<u>Method</u>
Fasting Blood Sugar :	98 mg/dl	60 - 110 mg/dl	GOD-POD
Blood Sugar Post Prandial :	* 102 mg/dl	110 - 140 mg/dl	

--- End Of Report ---

PHH8506

Verified by



**Dr. B PRATHYUSHA, MD BIOCHEMIST**  
**CONSULTANT BIOCHEMIST**

**Dr.B PRATHYUSHA**  
MD BIOCHEMIST  
CONSULTANT BIOCHEMIST

**Dr.Y NIHARIKA REDDY**  
M.D PATHOLOGY  
CONSULTANT PATHOLOGIST

**Dr.SAMATHA**  
MD Microbiology  
CONSULTANT MICROBIOLOGIST

185890  
30 Years

mangala dilli ganesh  
Male

10/08/2024 11:06:16 AM

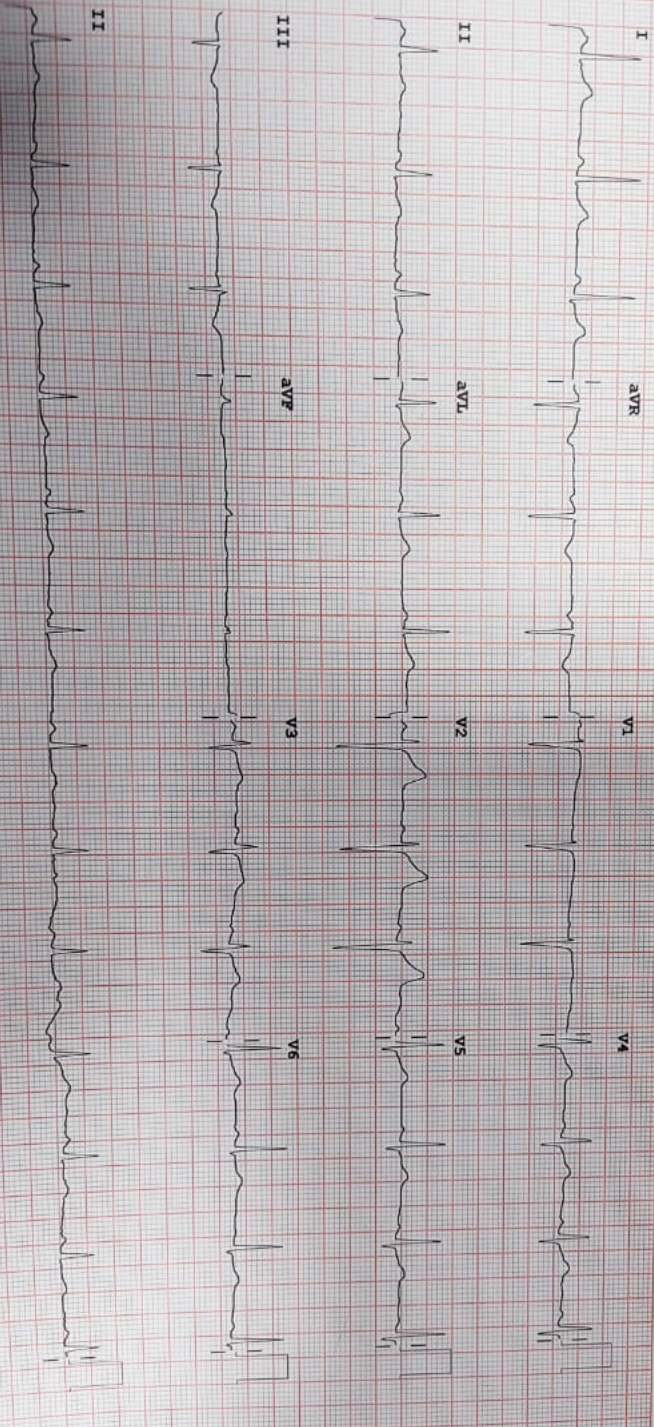
PACE HOSPITALS

Rate 74 Sinus rhythm  
PR 133 Borderline T abnormalities, inferior leads  
QRS 89 normal P axis, V-rate 50-99  
QT 376 T flat/neg, II III avf  
QTc 418

--AXIS--  
P 7  
QRS 12  
T -4  
12 Lead; Standard Placement

- BORDERLINE ECG -

Unconfirmed Diagnosis



Device:

Speed: 25 mm/sec

Limbs: 10 mm/mV

Chest: 10.0 mm/mV

PH100B CL P2

F 50-0.15-40 Hz

PH100B CL P2

POCO

SHOT BY MOHINUR

2024/8/10 12:29

## DEPARTMENT OF RADIOLOGY

<b>Patient Name</b> :Mr. MANGALA DILLI GANESH	<b>Age / Gender</b> : 30 Y(s) / Male
<b>Requested Date</b> :10-Aug-2024 8:53 AM	<b>UMR No</b> : UMR105814
<b>Reported Date</b> :10-Aug-2024 12:12 PM	<b>Result/ Bill No</b> : RES545104 / BIL185890
<b>Referred By</b> :Walk-In	<b>Lab No</b> : 0
<b>Advised By</b> :Dr.GENERAL PHYSICIAN	

### US ABDOMEN AND PELVIS

#### FINDINGS

LIVER: Normal in size (154 mm) and echotexture. No focal lesions noted. No intra hepatic biliary dilatation. CBD and Portal vein 8.5 mm appear normal in course and calibre.

GALL BLADDER: Well distended. No evidence of sludge / calculus. No evidence of wall thickening / pericholecystic collection.

PANCREAS: Normal in size and echotexture. Pancreatic duct appears normal. No peri pancreatic collection.

SPLEEN: Normal in size (88 mm) and echotexture.

BOTH KIDNEYS: Right= 97 x 50 mm . Left : 110 x 55 mm. Both kidneys are normal in size and echotexture. CMD is maintained. No evidence of calculi. Pelvicalyceal system appears normal on both sides.

Aorta and IVC: are normal.No evidence of para-aortic or paracaval lymphadenopathy.

URINARY BLADDER: Well distended. Wall thickness is normal.


PROSTATE: Normal in size and echotexture. Volume= 22 cc.

No evidence of ascites.

#### IMPRESSION

NO OBVIOUS ABNORMALITY.



  
Dr. AKHIL REDDY, MBBS, MD  
CONSULTANT RADIOLOGIST

---

Dr.LAKSHMI KUMAR CH  
MBBS,DNB,PDCC,EBIR  
INTERVENTIONAL RADIOLOGIST

## DEPARTMENT OF RADIOLOGY

<b>Patient Name</b> :Mr. MANGALA DILLI GANESH	<b>Age / Gender</b> : 30 Y(s) / Male
<b>Requested Date</b> :10-Aug-2024 8:53 AM	<b>UMR No</b> : UMR105814
<b>Reported Date</b> :10-Aug-2024 01:00 PM	<b>Result/ Bill No</b> : RES545153 / BIL185890
<b>Referred By</b> :Walk-In	<b>Lab No</b> : 0
<b>Advised By</b> :Dr.GENERAL PHYSICIAN	

### X-RAY CHEST PA VIEW

#### FINDINGS

Heart size is normal.


Both lung fields clear.

Both hila normal.

Both CP angles free.

Soft tissue chest wall and bony cage normal.



  
Dr. AKHIL REDDY, MBBS, MD  
CONSULTANT RADIOLOGIST

---

Dr.LAKSHMI KUMAR CH  
MBBS,DNB,PDCC,EBIR  
INTERVENTIONAL RADIOLOGIST