

MR. AWADHESH AHIRWAR
BOB

28 YEARS /MALE

01-4-2024

Height: 159 Cms

Weight: 56 Kg

BP: - 118/70 mmhg

Pulse: - 78/- Regular

BMI: - 22.2 kg/m²

EYE: - NORMAL

The Medical Examiner should record the findings under one of the following categories:-

FIT

UNFIT on account of



Dr. D. S. Chhabra

DR. D.S. CHHABRA

MBBS. MD.

MR. AWADHESH AHIRWAR

28 Years /M

BANK OF BARODA

01-04-2024

HEAMOGRAM

Test Name	Results	Normal Range
Haemoglobin (HB)	13.4	13 - 18 gm%
R.B.C. Count	4.75	4.5 - 5.5 milli./cu.mm
PCV	44.1	40 - 50 %
MCV	92.84	80 - 95 fl
MCH	28.21	27 - 32 pg
MCHC	30.39	31.5 - 34.5 %
TOTAL WBC COUNT	7,800	4,000 to 11,000 /cu.mm
DIFFERENTIAL WBC COUNT	.	
Neutrophils	65	40 - 75 %
Lymphocytes	31	20 - 40 %
Monocytes	02	02 - 08 %
Eosinophils	02	01 - 05 %
Basophils	00	00 - 01 %
PLATELET COUNT	2.13	1.5 - 4 Lacs/cu.mm.
E.S.R	10	M- 0-10 at the end of 1 hr. F- 0-20 at the end of 1 hr

Dr. POOJA PRAPANNA
MD

DR. POOJA PRAPANNA

M.D.

MR. AWADHESH AHIRWAR

28 Years /M

BANK OF BARODA

01-04-2024

HBA1C

Test Name	Results	Normal Range
HBA1C	5.10	Normal 4-6 % Good Control 6-7 % Fair Control 7-8 % Unsatisfactory Control 8-10 % Poor Control Above 10 %


DR. POOJA PRAPANNA
MB

DR. POOJA PRAPANNA

M.D.

MR. AWADHESH AHIRWAR

28 Years /M

BANK OF BARODA

01-04-2024

LIPID PROFILE

Test Name	Results	Normal Range
TOTAL LIPIDS	474	400 - 700 mg/dl
CHOLESTROL	156.0	<200 mg/dl- Desirable 200 - 239 mg/dl - Borderline High >240 Mg/dl High
HDL CHOLESTROL	38.0	35- 60 mg/dl
TRIGLYCERIDE	112.0	<150 mg/dl Normal 150 - 199 mg/dl Borderline High 200 - 499 mg/dl High
LDL CHOLESTROL	95.6	<100 mg/dl Optimal 100- 129 mg/dl Borderline high 160 - 189 mg/dl High
VLDL CHOLESTROL	22.4	<40 mg/dl
RISK RATIO	4.11	3 - 6

Dr. POOJA PRAPANNA
MD

DR. POOJA PRAPANNA

M.D.

MR. AWADHESH AHIRWAR

28 Years /M

BANK OF BARODA

01-04-2024

BIOCHEMISTRY

Test Name	Results	Normal Range
SERUM BILIRUBIN	:-	
TOTAL BILIRUBIN	0.78	0 - 1 mg/dl
DIRECT BILIRUBIN	0.11	<0.25 mg/dl
INDIRECT BILIRUBIN	0.67	< 1.0 mg/dl
S.G.O.T	30.0	0 - 45 IU/L
S.G.P.T	33.0	0 - 45 IU/L
ALKALINE PHOSPHATE	81.0	Adult - 42 - 128 IU/L Child - 150 - 630 IU/L
TOTAL PROTEIN	6.00	6.0 to 8.0 g/dl
ALBUMIN	4.51	3.2 to 5.0 g/dl
GLOBULIN	1.49	1.9 to 3.5
A:G RATIO	3.03	1.2 TO 2.3
GAMA GT	35.0	5 - 43 Iu/l

DR. POOJA PRAPANNA
M.D.

DR. POOJA PRAPANNA

M.D.

MR. AWADHESH AHIRWAR

28 Years /M

BANK OF BARODA

01-04-2024

Test Name	Results	Normal Range
-----------	---------	--------------

HAEMATOLOGY PROFILE

BLOOD GROUP	: -
"ABO " GROUP	"O"
Rh (D) Factor	Positive

(Cross matching & recheck of Blood Group is mandatory before any transfusion)

SEROLOGY PROFILE

HBsAg	Non Reactive
-------	--------------

* Test done by screening methods. Requires confirmation at refferal centre.

BIOCHEMISTRY

FASTING BLOOD SUGAR	71.0	70 - 110 mg/dl
P.P. BLOOD SUGAR	82.0	upto 140 mg/dl
BUN	13.0	5 - 21 Mg/dl
CREATININE	1.11	0.6 - 1.4 mg\dl
URIC ACID	5.86	3.5 - 7 mg\dl
CALCIUM	8.56	8.5 - 10.5 mg\dl

DR. POOJA PRAPANNA
MD
DR. POOJA PRAPANNA

Note :- All pathological tests have technical and biological limitations. Please correlate clinically as well as with other investigative findings. A review should be requested in case of any disparity. This report is not valid for medicolegal purpose.

M.D.

MR. AWADHESH AHIRWAR
BANK OF BARODA28 Years /M
01-04-2024**URINE EXAMINATION**

Test Name	Results	Normal Range
PHYSICAL EXAMINATION		
Quantity	30 ml	.
Colour	Pale Yellow	.
Appearance	Clear	.
Deposits	Absent	.
Specific Gravity	1.015	.
Reaction	Acidic	.
CHEMICAL EXAMINATION		
Albumin	Nil	.
Sugar	Nil	.
Ketones	Absent	.
Bile Pigments	Negative	.
Bile Salt	Negative	.
Hematuria	Negative	.
MICROSCOPIC EXAMINATION		
Pus Cells	1- 2 /hpf	.
Red Blood Cells	Nil/hpf	.
Epithelial Cell	1 - 2 /hpf	.
Crystals	Nil	.
Casts	Absent	.

Note :- All pathological tests have technical and biological limitations. Please correlate clinically as well as with other investigative findings.
A review should be requested in case of any disparity. This report is not valid for medicolegal purpose.

DR. POOJA PRAPANNA
DR. POOJA PRAPANNA
M.D.

4D SONOGRAPHY • COLOR DOPPLER • ECHO • PATHOLOGY • DIGITAL X-RAY & OPG • TMT • ECG • HOLTER

MR. AWADHESH AHIRWAR

28 Yrs./M

BOB

01st April, 2024

X-RAY CHEST PA VIEW

Bony cage is normal.

Trachea is central. C.P. angles are clear.

Cardiac contour and cardiothoracic ratio are normal.

Lung fields are clear.

DR.D.S.CHHABRA.
M.D.

MR. AWADHESH AHIRWAR

28 Yrs./M.

BOB

01st April, 2024

ABDOMINAL SONOGRAPHY

Liver is of normal size, shape, has smooth margins & regular contours & the parenchyma is normal in echostructure. No focal lesion.

Gall bladder is of normal size, shape, has thin walls & the contents are clear fluid. No evidence of any calculus. Biliary tree is undilated.

Pancreas is normal, no focal / diffuse pathology. Spleen is normal. The portal and splenic veins are normal in calibre.

Both Kidneys are normal in size [Rt.- measures about 9 cms. & Lt.- 10 cms. in length], shape and echostructure. No evidence of any calculus in both. The collecting system and ureter on both side are undilated.

Urinary bladder is normal in size, shape & has thin walls.

Prostate is of normal size (around 18 gms.) & is normal in echostructure.

There is no ascitis. No obvious abdominal lymphadenopathy. No sub / supra diaphragmatic pathology on either side.

IMPRESSION :

Normal study.



DR.D.S.CHHABRA.

M.D.



LABORATORY REPORT



Name : Mr AWADHESH AHIRWAR	Sex/Age : Male / 28 Years	Case ID : 40401600044
Ref. By :	Dis. At :	Pt. ID :
Bill. Loc. : UNIQUE DIAGNOSTIC CENTRE INDORE		Pt. Loc. :
Reg Date and Time : 01-Apr-2024 11:02	Sample Type : Serum	Mobile No. :
Sample Date and Time : 01-Apr-2024 11:02	Sample Coll. By : non	Ref Id1 :
Report Date and Time : 01-Apr-2024 12:35	Acc. Remarks : -	Ref Id2 :

TEST	RESULTS	UNIT	BIOLOGICAL REF RANGE	REMARKS
Thyroid Function Test				
Triiodothyronine (T3) CMIA	135.73	ng/dL	58 - 159	
Thyroxine (T4) CMIA	9.27	µg/dL	4.6 - 10.5	
TSH CMIA	3.02	µIU/mL	0.4 - 4.2	

INTERPRETATIONS

- Circulating TSH measurement has been used for screening for euthyroidism, screening and diagnosis for hyperthyroidism & hypothyroidism. Suppressed TSH (<0.01 µIU/mL) suggests a diagnosis of hyperthyroidism and elevated concentration (>7 µIU/mL) suggest hypothyroidism. TSH levels may be affected by acute illness and several medications including dopamine and glucocorticoids. Decreased (low or undetectable) in Graves disease. Increased in TSH secreting pituitary adenoma (secondary hyperthyroidism), PRTN and in hypothalamic disease thyrotropin (tertiary hyperthyroidism). Elevated in hypothyroidism (along with decreased T4) except for pituitary & hypothalamic disease.
- Mild to modest elevations in patient with normal T3 & T4 levels indicates impaired thyroid hormone reserves & incipient hypothyroidism (subclinical hypothyroidism).
- Mild to modest decrease with normal T3 & T4 indicates subclinical hyperthyroidism.
- Degree of TSH suppression does not reflect the severity of hyperthyroidism, therefore, measurement of free thyroid hormone levels is required in patient with a suppressed TSH level.

CAUTIONS

Sick, hospitalized patients may have falsely low or transiently elevated thyroid stimulating hormone. Some patients who have been exposed to animal antigens, either in the environment or as part of treatment or imaging procedure, may have circulating antianimal antibodies present. These antibodies may interfere with the assay reagents to produce unreliable results.

TSH ref range in pregnancy

First trimester
Second trimester
Third trimester

Reference range (microIU/ml)

0.24 - 2.00
0.43-2.2
0.8-2.5

Note:(LL-VeryLow,L-Low,H-High,HH-VeryHigh ,A-Abnormal)

Adawani

Dr Astha Dawani
Consultant Pathologist.

Dr. A Mishra
M.D. Microbiology

Dr. Soma Yadav
M.D. (Pathology)

Printed On : 01-Apr-2024 12:46



Dr. D. S. Chhabra
M.D. (S. M. I.)
Reg. No. 3007

 **बैंक ऑफ बड़ौदा**
Bank of Baroda

Name : Awadhesh Ahirwar

E.C. No. : 184032


जारीकर्ता प्राधिकारी



धारक के हस्ताक्षर



DR. PRIYANK JAIN

M.D.,D.M.

CONSULTANT CARDIOLOGIST

UNIQUE DIAGNOSTIC CENTRE

45-B, Jaora Compound,
Opp. M.Y.Hospital, M.Y.H. Road,
INDORE - 452 001. (M. P.).
Phone : 2704118. 4082228

ECHOCARDIOGRAPHY REPORT

NAME : **MR.AWADHESH AHIRWAR** **Age** : **28 Yrs./ M**
REFERRED BY : **BOB** **Date** : **01st April, 2024**

ECHOCARDIOGRAPHIC OPINION

INTERPRETATION :-

- ** No RWMA.
- ** Good biventricular function. LVEF : 60 %.
- ** Normal cardiac valves, healthy pericardium.
- ** Grade I diastolic dysfunction.

Dr. PRIYANK JAIN
M.D., D.M.
Reg. No. 19547



DR.PRIYANK JAIN. M.D.,D.M.

TWO DIMENSIONAL ECHOCARDIOGRAPHY

M Mode examination revealed normal movement of both mitral leaflets during diastole.

No SAM or mitral valve prolapse is seen.

Mitral valve opening is normal. No evidence of mitral valve prolapse is seen.

Tricuspid valve is normal, pulmonary valve is normal, aortic root is normal in size, dimensions of left atrium and left ventricle are normal.

Aortic cusps are not thickened and enclosure line is central.

Aortic valve has three cusps and its opening is not restricted.

2 - D imaging in PLAX, SAX and apical views revealed a normal sized left ventricle.

Movement of septum, anterior, posterior, inferior and lateral walls is normal. Global LVEF is 60 %.

Right atrium and right ventricle are normal in size.

Tricuspid valve leaflets move normally.

Pulmonary valve is normal.

Interatrial and interventricular septa are intact.

No intracardiac mass or thrombus is seen.

No pericardial pathology is observed.

MEASUREMENTS :

[C] DIMENSIONS	OBSERVED VALUES	Normal Values (For Adults)
1. Aortic Root diameter	: 2.9 cms.	2.0-3.7 cm < 2.2 cm / M ²
2. Aortic Valve Opening	: 2.7 cms.	1.5-2.6 cm
3. Right Ventricular Dimension	: --	
4. Left Atrial Dimension	: 3.2 cms.	1.9-4.0 cm < 2.2 cm / M ²
5. Left Ventricular ED Dimension	: 3.6 cms.	3.7-5.6 cm < 3.2 cm / M ²
6. Left Ventricular ES Dimension	: 2.3 cms.	2.2-4.0 cm
7. Inter Ventricular ED Septal thickness	: 1.2 cms.	0.6-1.2 cm
8. Left Ventricular ED PW thickness	: 1.3 cms.	0.5-1.0 cm
9. IVS / LVPW	: 01	< 1.3

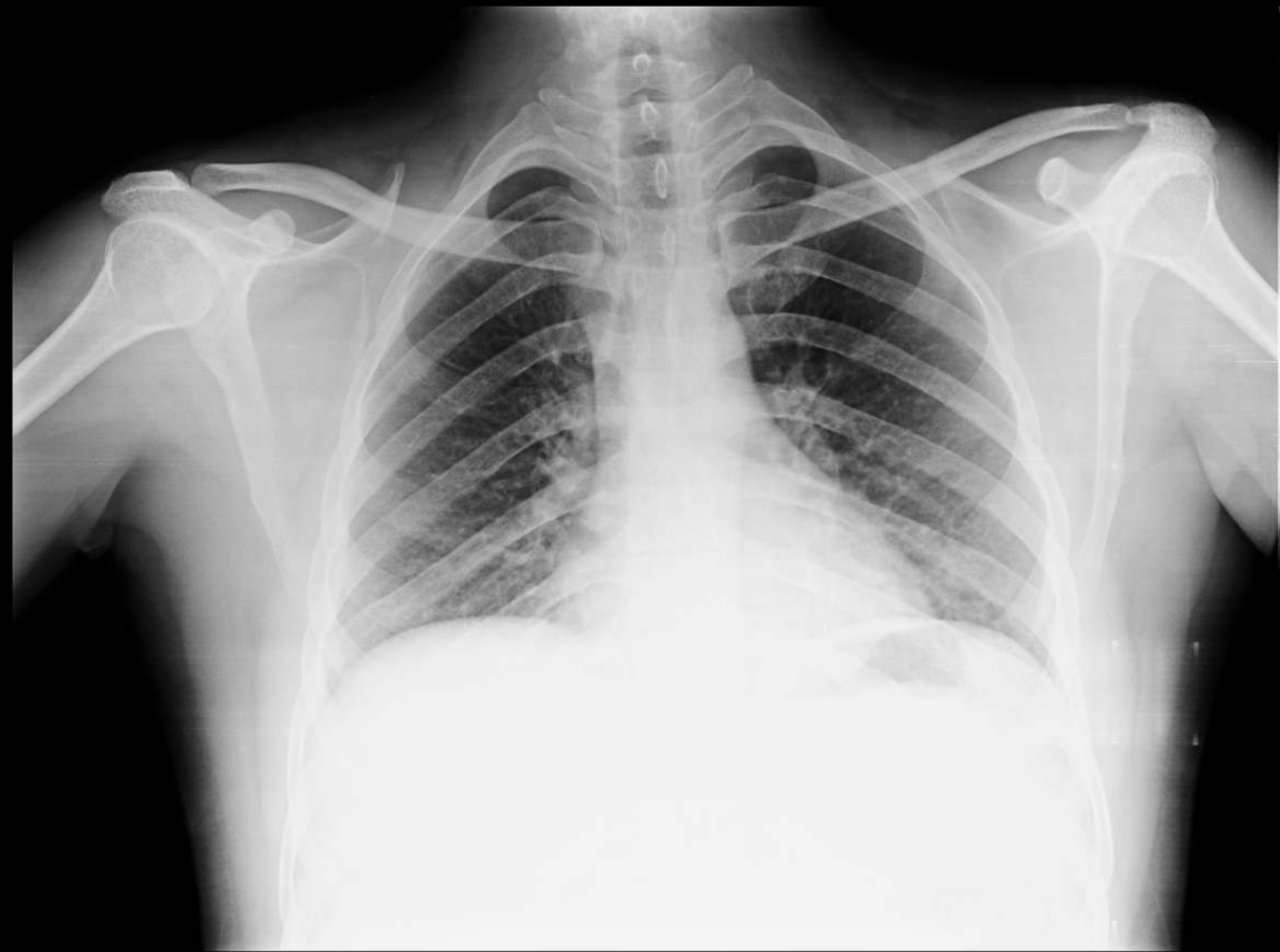[E] INDICES OF LEFT VENTRICULAR FUNCTION

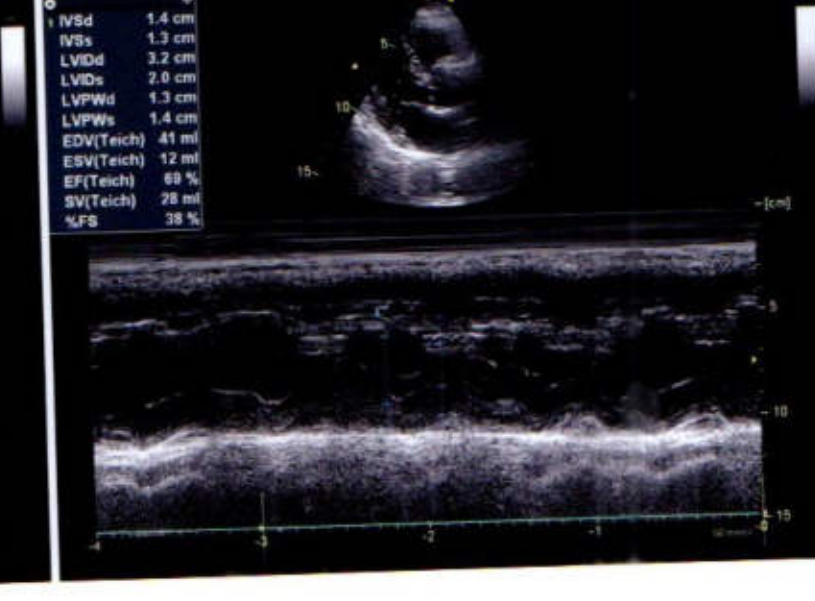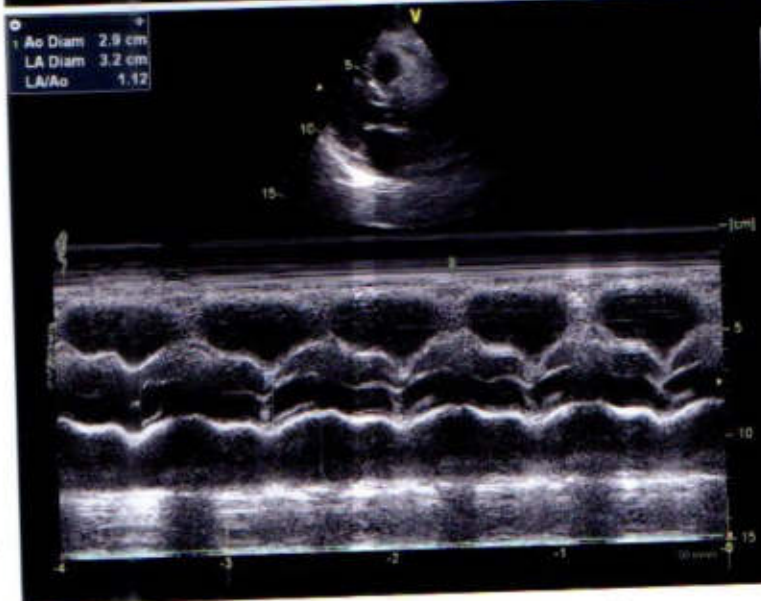
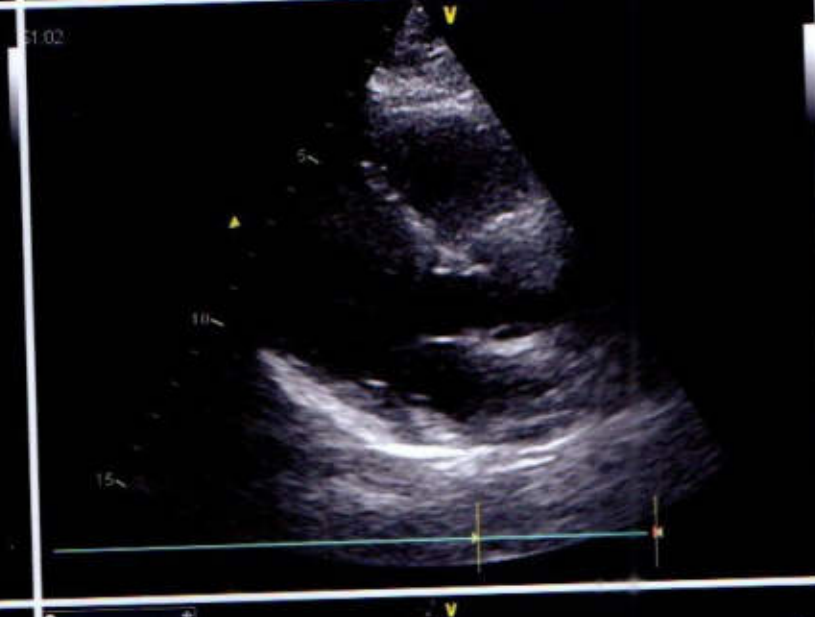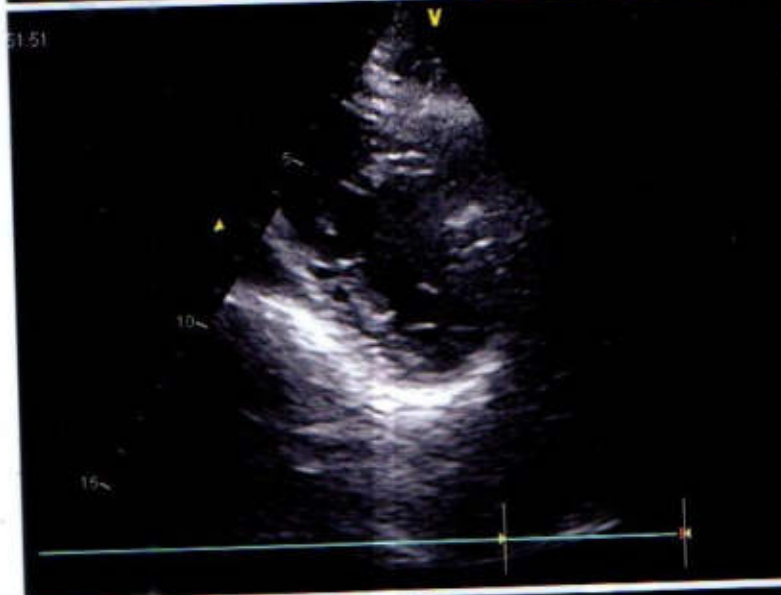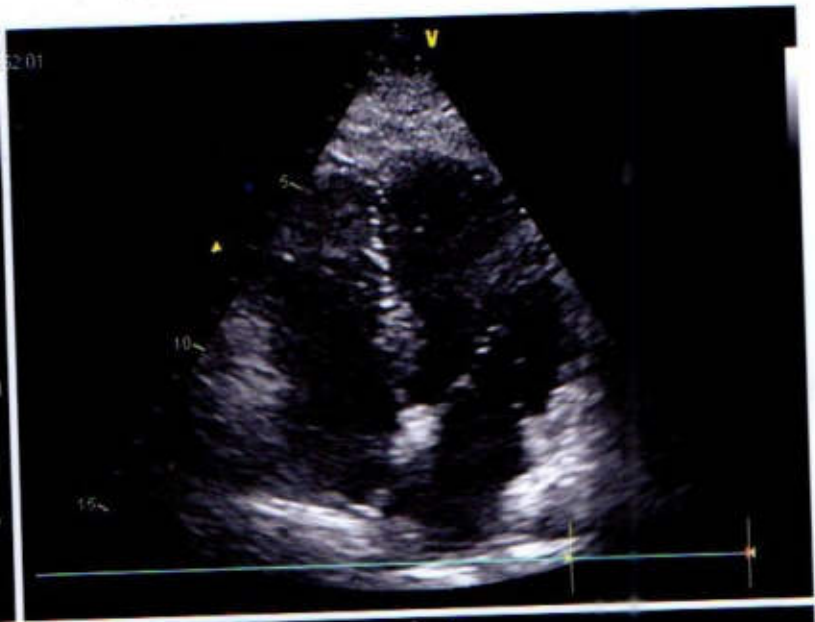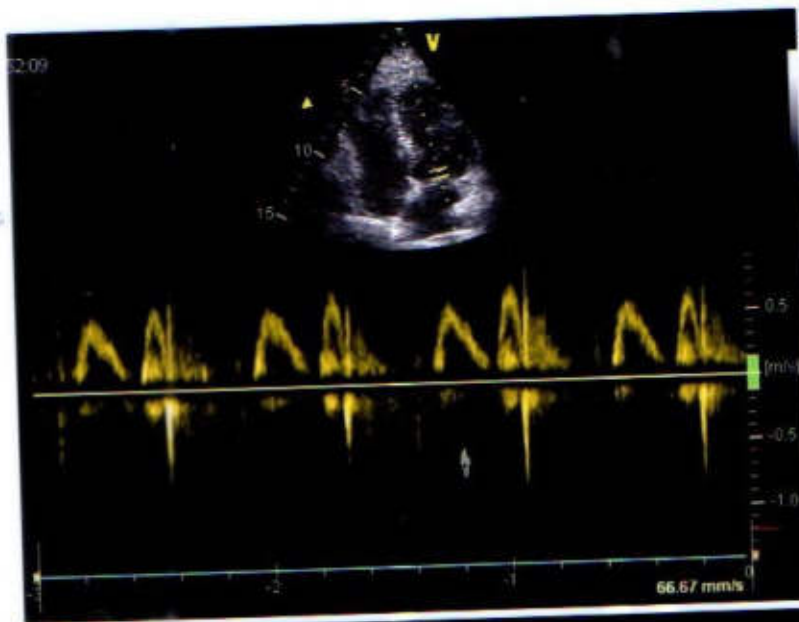
1. Mitral E - Septal Separation	: 0.5	< 0.9 - cm
2. Left Ventricular Ejection Fraction	: 60 %	60 - 80 %

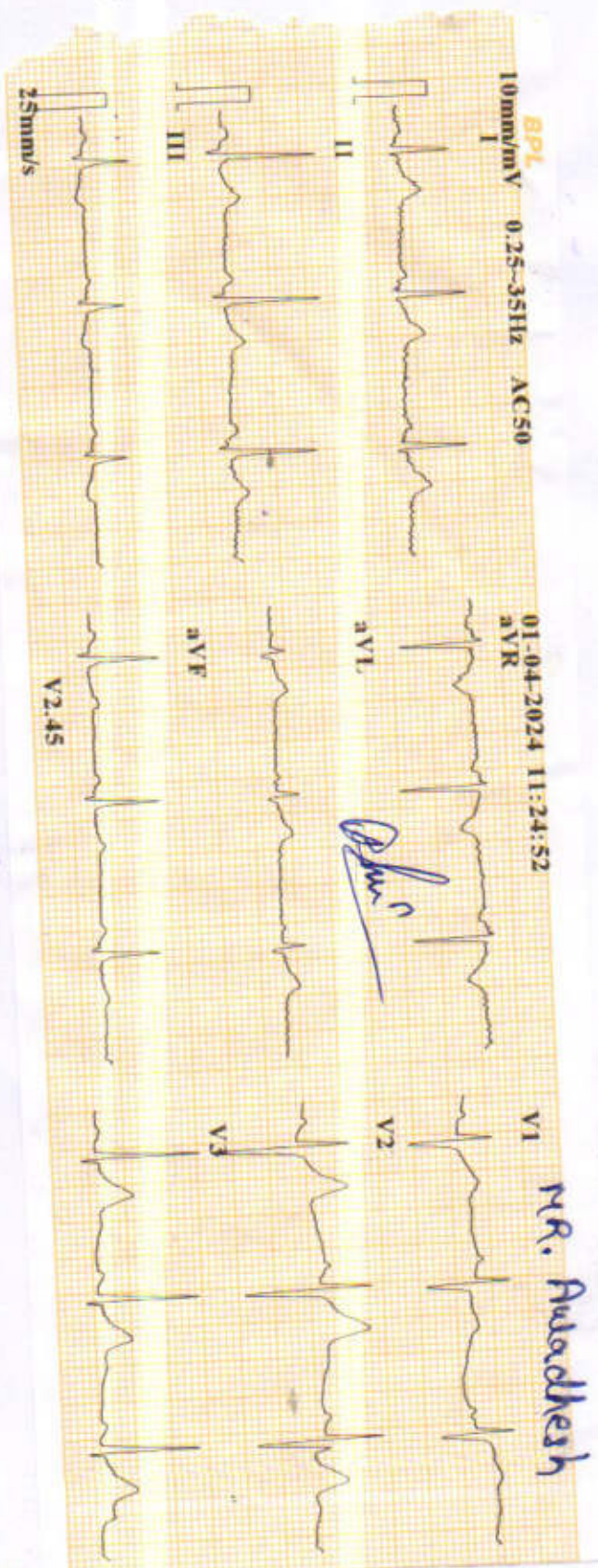
DOPPLER

	Peak Flow Velocity (M/Sec.)	Peak Gradient (mmHg.)	Regurgitation
MV	Normal	--	Normal
TV	Normal	--	Normal
AV	Normal	--	Normal
PV	Normal	--	Normal

PASP : Normal







BPL
10mm/mV 0.25-35Hz AC50

01-04-2024 11:24:52
aVR

V1
V.R. Awasthesh

ID	: 240401-1124	Minnesota Code:	9-4-1(V3)
Name	: 28 yr	Age	: 28 yr
Sex	: Male	Sex	: Male
BP	:	BP	: mmHg
Height	:	Height	: cm
Weight	:	Weight	: kg
HR	: 78 bpm	HR	: 78 bpm
P Dur	: 82 ms	P Dur	: 82 ms
PR int	: 126 ms	PR int	: 126 ms
QRS Dur	: 80 ms	QRS Dur	: 80 ms
QT/QTc int	: 333/380 ms	QT/QTc int	: 333/380 ms
P/QRS/T axis	: 53/53/19 °	P/QRS/T axis	: 53/53/19 °
RV5/SV1 amp	: 2.102/0.683 mV	RV5/SV1 amp	: 2.102/0.683 mV
RV6/SV2 amp	: 1.768/1.091 mV	RV6/SV2 amp	: 1.768/1.091 mV

CARDIAC

Diagnosis Information:
800: Sinus Rhythm
Normal ECG

Report Confirmed by:

Dr. PRIYANK JAIN
MBBS, MD, DM
Reg. No. 19547

(Handwritten signature and initials)

