

09/12/23

Mr. Kumar Sumit
351m

ophtha

	(R)	(L)
VA	6/6 (A)	6/6 (A)
	N ₈ (A)	N ₆ (A)
Color vn	(N)	(N)
A/sey	(N)	(N)
(F)	(N)	(N)
	(140) cone	

—→ eye



भारत सरकार
GOVERNMENT OF INDIA



सुमित कुमार
Sumit Kumar
जन्म तिथि / DOB: 28/01/1988
पुरुष / MALE
Mobile No.: 9594165136

4178 7771 7238

मेरा आधार, मेरी पहचान

Dr. Mahesh V. Padsalge
MD. (Medicine)
Consultant Physician
Reg. No. 91424 (MMC)



भारतीय विशिष्ट पहचान प्राधिकरण

UNIQUE IDENTIFICATION AUTHORITY OF INDIA

पता

पुत्र कृपलानी प्रसाद सिंह, वृन्दावन को-ऑप हसिंग सोसाइटी, फ्लॉट नं. एफ २, १/१, फर्स्ट फ्लोर, सानपेदा सेक्टर ४, सानपेदा रेलवे स्टेशन के पास, नवी मुंबई, ठाणे, महाराष्ट्र - 400705

Address:

S/O Kripalani Prasad Singh, Vrindavan Co-op Housing Society, Flat no. F2, 1/1, First floor, Sanpada Sector 4, Near Sanpada Railway Station, Navi Mumbai, Thane, Maharashtra - 400705



1947
1800 300 1947

help@uidai.gov.in

www.uidai.gov.in

P.O. Box No. 1947,
Bengaluru-560 001

09.12.2023 11:17.08
DIABECARE-DIABETES & ENDOCRINE
OPP. GRAND CENTRAL MALL
SEAWOOD

Male

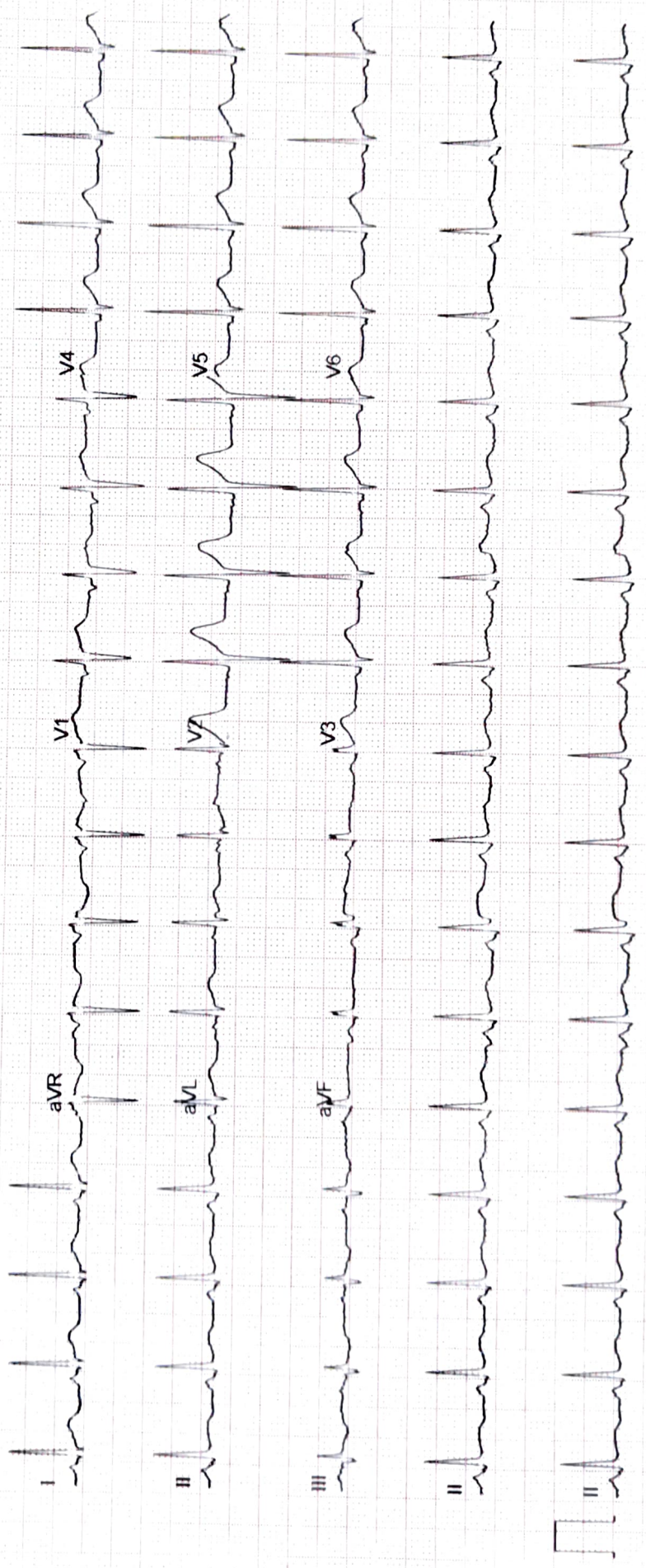
QRS : 80 ms
QT/QTcBaz : 344 / 446 ms
PR : 114 ms
P : 94 ms
RR/PP : 594 / 594 ms
P/ORS/T : 54 / 32 / 24 degrees

Sinus tachycardia
Nonspecific ST abnormality
Abnormal ECG

101 bpm
-- / -- mmHg

Sinm tachycardia stressor
within normal limit

CSH
Dr. Mafresh V. Padsalge
MD. (Medicine)
Consultant Physician
Reg. No. 91424 (MMC)



ECHO Report

Date: 09/12/2023

Patient Details

Patient ID –

Name- SUMIT KUMAR

Age- 35 YEARS

Gender- MALE

Referral BY - MEDI WHEEL

Doctor Incharge DR. MAHESH PADSALGE

Clinical Status of Patient -

Finding description -

- 1. Normal cardiac chambers dimensions.**
- 2. Normal LV systolic function.**
- 3. No RWMA.**
- 4. All cardiac valves are structurally normal.**
- 5. Trivial MR, Trivial PR, NO AR.**
- 6. No PAH.**
- 7. Normal RV systolic function.**
- 8. No clot/vegetation/pericardial effusion.**
- 9. No coarctation of aorta.**

Chamber Dimensions-M mode Findings

LVID (Diastole) 35-56(mm)	- 47.00	LVID (Systole) 24-42(mm)	- 32.00
IVS (Diastole) 8-12(mm)	- 11.00	IVS (Systole) 14-42(mm)	- 15.00
LVPWT (Diastole) 6-11(mm)	- 11.00	EPSS	- 4.00
LVEF (%)	- 60%	LVFS (%)	- 32.00

LV Volume (Diastolic)(mm³)
Meridional Wall Stress in System

LV Volume (Systolic)(mm³)
Cubed LV Volume in Diastole (mm³)

Cubed LV+ myocardial volume (mm³)

Velocity of circumferential
Shortening (mm)

Aortic root 22-37(mm)	- 33.00
Left Atrium Length (mm)	- 33.00
Left Atrium Volume (mm ³)	
RV size	Normal
Normal	
RV volume (mm ³)	
Normal	
Pericardium	Normal
Effusion	None
Resp Variation	Present
Predicted RV Systolic Pressure	

Left Atrium Width (mm)
Left Atrium Area (mm²)
RV Function

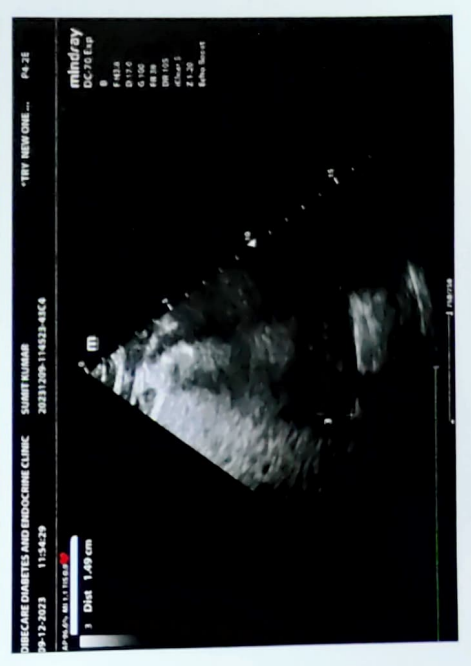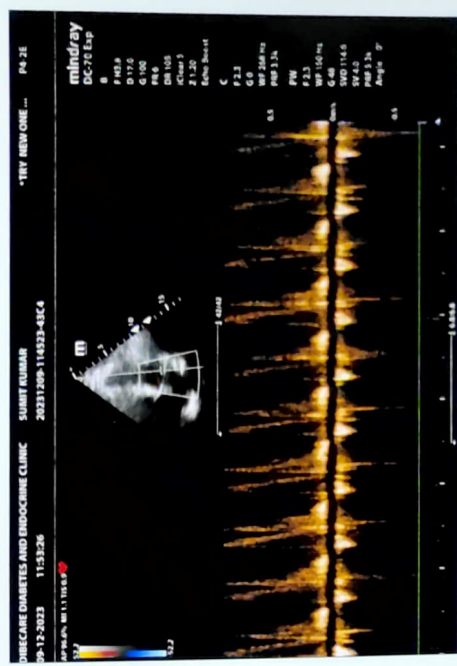
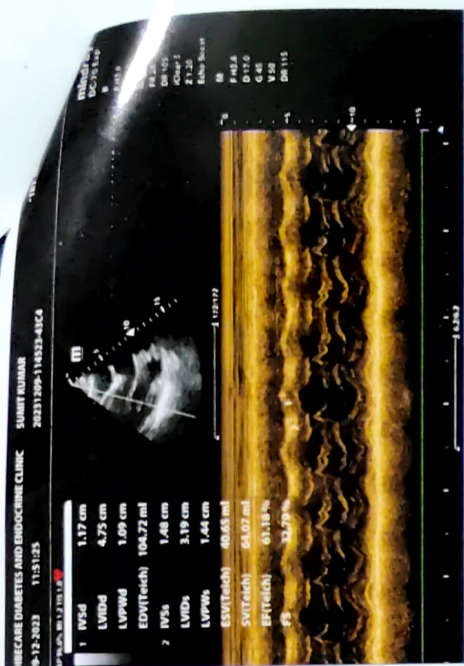
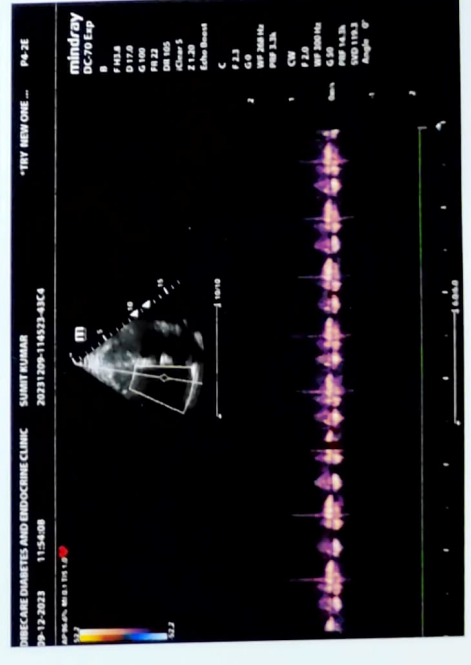
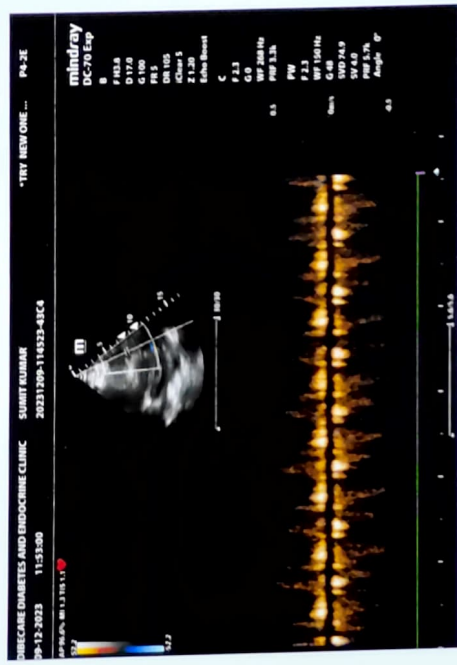
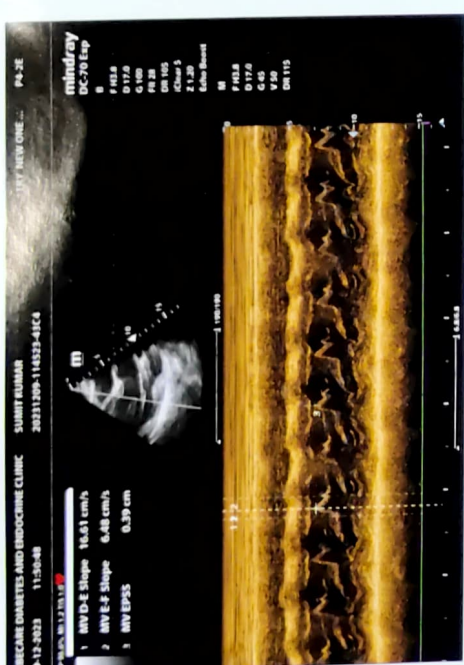
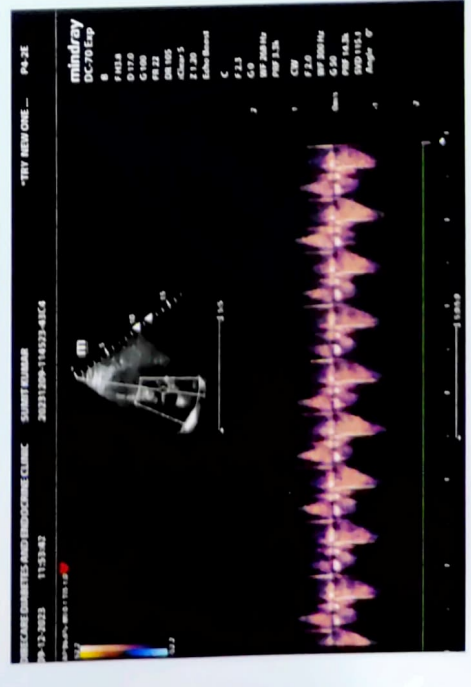
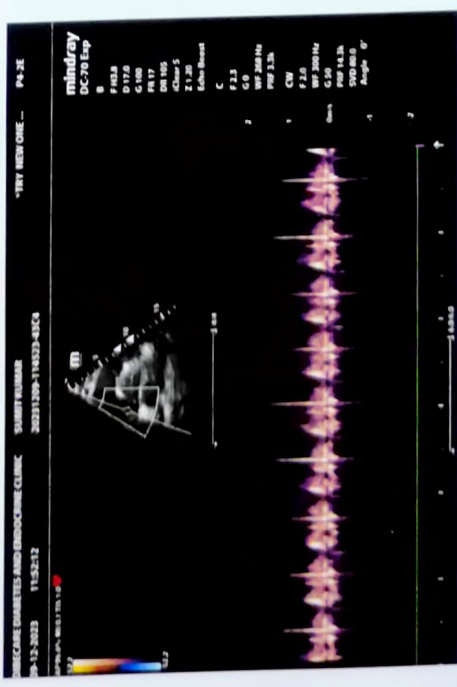
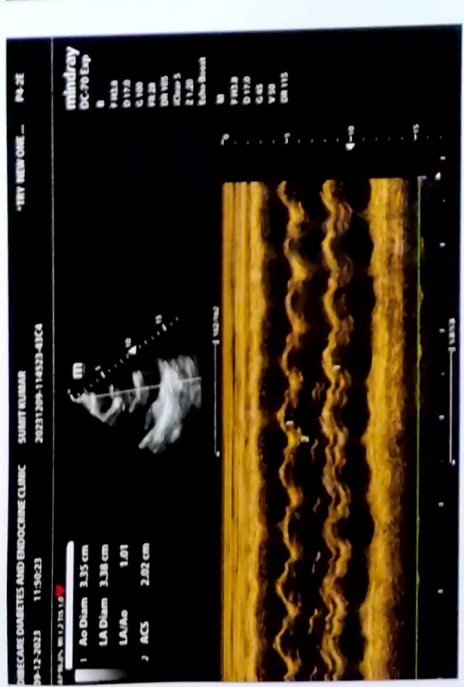RA Size

IVC Size (mm) – 15mm Collapsible

Doppler Findings- I


Dr. Mahesh Padsalge

Dr. Mahesh V. Padsalge
MD. (Medicine)
Consultant Physician
Reg. No. 91424 (MMC)





NAME- SUMIT KUMAR

DATE-9/12/2023

AGE- 35/M

X-RAY CHEST PA

The Bony Thorax is Normal.

Both The Costophrenic And Cardiophrenic Angles Are Clear.

Cardiac Shape And Size Appears Normal.

The Lung Field Appears Normal.

Both The Hila Are Normal In Density And Position.

Impression: - Normal Chest X-Ray.

For, Anal

DR.MRUDULA BABAR
CONSULTANT RADIOLOGIST

DR. MRUDULA BABAR
MBBS, MD, DMFE (RADIOLOGY)
CPS MUMBAI 2009
REG. NO. 2005/03/2139

Name : MR SUMIT KUMAR	Age/sex: 35 Yrs. /MALE
Ref by: HEALTH METER	Date: 09/012/2023

ULTRASOUND EXAMINATION OF ABDOMEN & PELVIS

Findings-

The Liver is mildly enlarged in size (15.5 cm), shape and raised echogenicity. No focal lesion is seen. The Hepatic veins appear normal. There is no IHBR dilatation. The portal vein appears normal.

The gall bladder is distended. The proximal C.B.D. is normal caliber

Visualized head of Pancreas appears normal in size and reflectivity. The pancreatic duct is not dilated. Rest of the pancreas and retro peritoneum is obscured by bowel gases

The spleen is normal in size (11.4 cm), No focal lesion is seen. Splenic vein is normal at hilum.

Both kidneys are normal in position and size. They show normal cortical reflectivity and cortico-medullary differentiation. There is no evidence of renal calculus, hydronephrosis or mass.

Right kidney measures 11.5 x 5.7 cm

Left kidney measures 10.7 x 6.7 cm

The Urinary bladder is well distended. No evidence of any intraluminal mass or calculi.

The visualized Prostate appears normal in size, shape and homogenous echotexture, its measures 2.1 x 2.4 x 2.6 cm-7.1 cc

There is no free fluid is seen in the pelvis. No probe tenderness in present study.

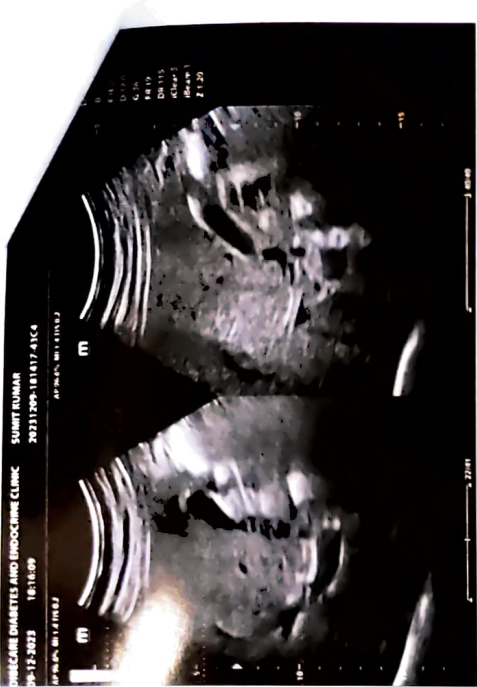IMPRESSION :-

- Mild hepatomegaly with grade 2 fatty infiltration .
- Adv : clinical correlation.

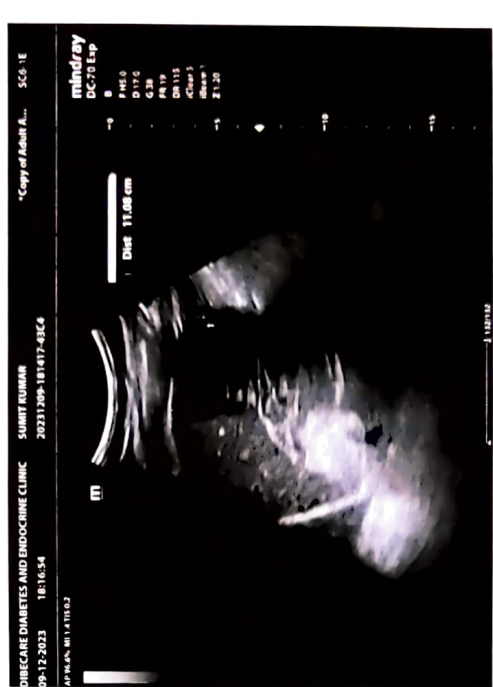

Dr. MRUDULA BABAR
CONSULTANT RADIOLOGIST

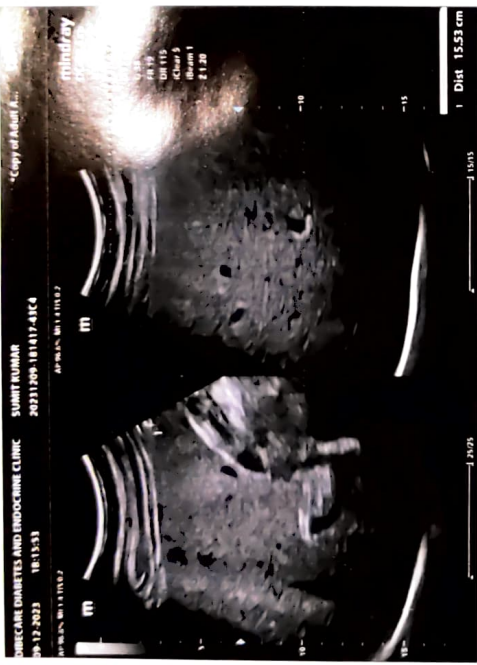DR. MRUDULA BABAR
M.B.S., MD, DMRE (RADIOLOGY)
CPS MUMBAI 2009
REG. NO. 2005/03/2139



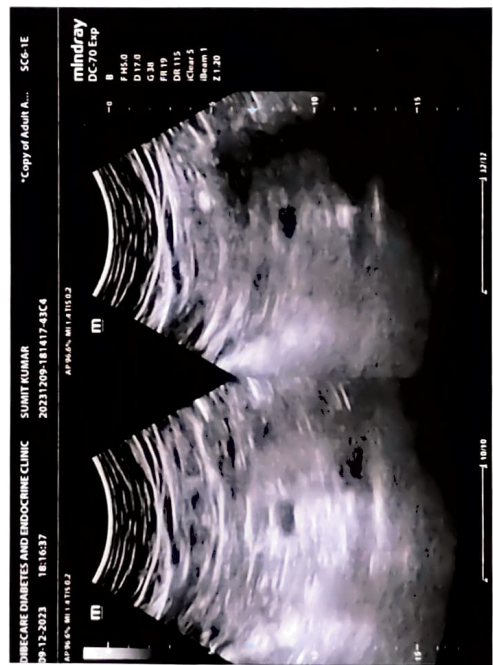
DIBICARE DIABETES AND ENDOCRINE CLINIC SUMIT KUMAR
 09-12-2023 18:16:09 20231209-181417-43C4
 AP 09-12-2023 18:16:09
 *Copy of Adult A... SC6-1E



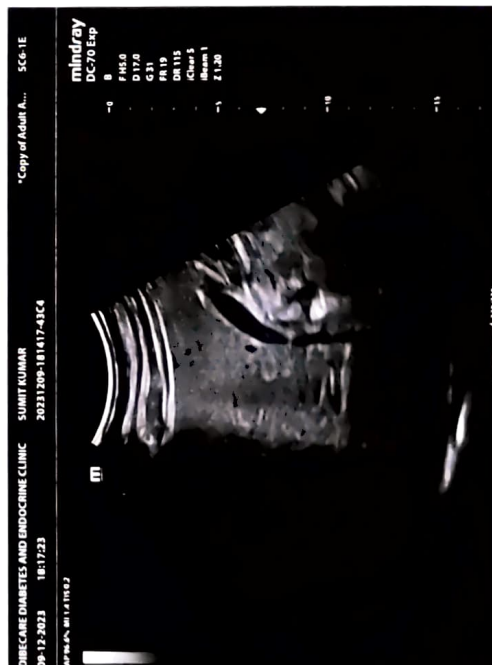DIBICARE DIABETES AND ENDOCRINE CLINIC SUMIT KUMAR
 09-12-2023 18:16:54 20231209-181417-43C4
 AP 09-12-2023 18:16:54
 mindray DC-70 Esp
 F 16.0
 D17.0
 G 3.8
 PR 19
 DR 115
 C-Scan 5
 Zoom 1
 2.1:30
 Dist 11.08 cm
 *Copy of Adult A... SC6-1E



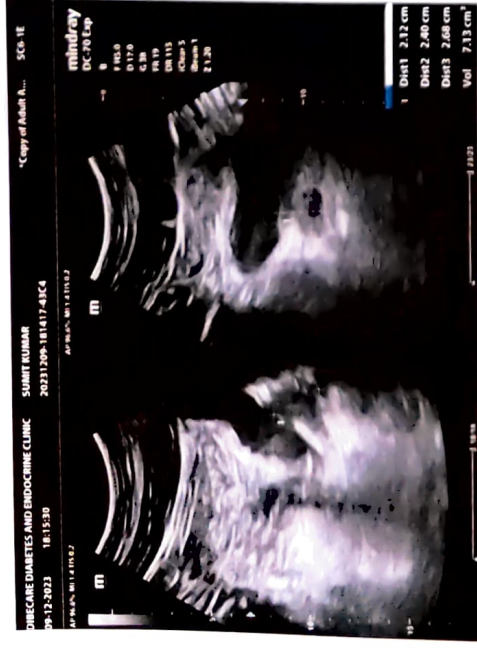DIBICARE DIABETES AND ENDOCRINE CLINIC SUMIT KUMAR
 09-12-2023 18:15:33 20231209-181417-43C4
 AP 09-12-2023 18:15:33
 *Copy of Adult A... SC6-1E



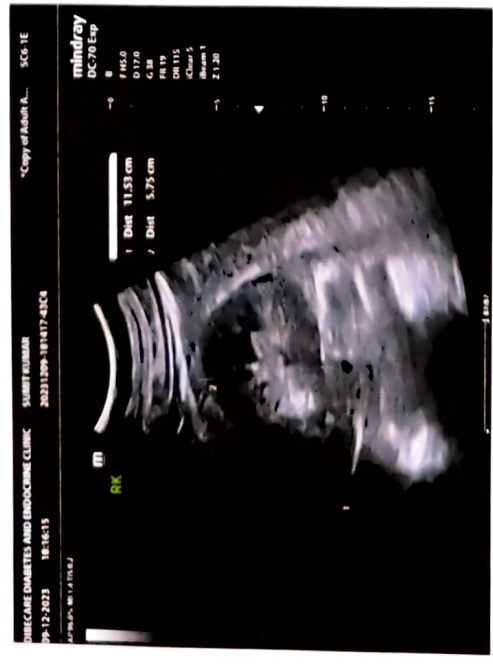DIBICARE DIABETES AND ENDOCRINE CLINIC SUMIT KUMAR
 09-12-2023 18:16:37 20231209-181417-43C4
 AP 09-12-2023 18:16:37
 mindray DC-70 Esp
 F 16.0
 D17.0
 G 3.8
 PR 19
 DR 115
 C-Scan 5
 Zoom 1
 2.1:30
 Dist 15.53 cm
 *Copy of Adult A... SC6-1E



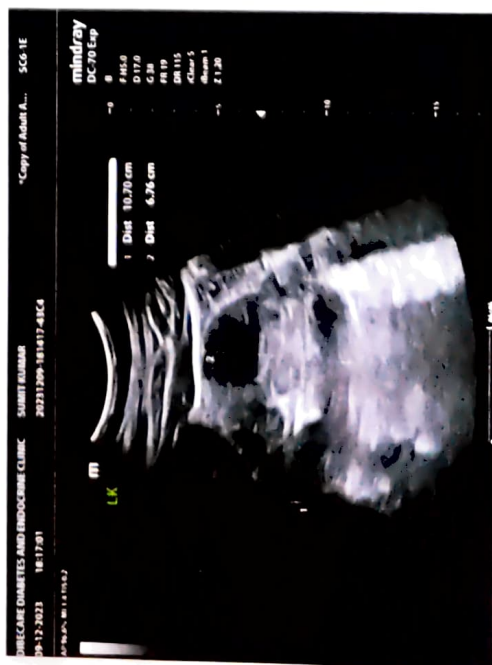DIBICARE DIABETES AND ENDOCRINE CLINIC SUMIT KUMAR
 09-12-2023 18:17:23 20231209-181417-43C4
 AP 09-12-2023 18:17:23
 mindray DC-70 Esp
 F 16.0
 D17.0
 G 3.1
 PR 19
 DR 115
 C-Scan 5
 Zoom 1
 2.1:30
 *Copy of Adult A... SC6-1E



DIBICARE DIABETES AND ENDOCRINE CLINIC SUMIT KUMAR
 09-12-2023 18:15:30 20231209-181417-43C4
 AP 09-12-2023 18:15:30
 *Copy of Adult A... SC6-1E



DIBICARE DIABETES AND ENDOCRINE CLINIC SUMIT KUMAR
 09-12-2023 18:16:15 20231209-181417-43C4
 AP 09-12-2023 18:16:15
 mindray DC-70 Esp
 F 16.0
 D17.0
 G 3.8
 PR 19
 DR 115
 C-Scan 5
 Zoom 1
 2.1:30
 Dist 11.55 cm
 Dist 5.75 cm
 *Copy of Adult A... SC6-1E



DIBICARE DIABETES AND ENDOCRINE CLINIC SUMIT KUMAR
 09-12-2023 18:17:01 20231209-181417-43C4
 AP 09-12-2023 18:17:01
 mindray DC-70 Esp
 F 16.0
 D17.0
 G 3.8
 PR 19
 DR 115
 C-Scan 5
 Zoom 1
 2.1:30
 Dist 10.70 cm
 Dist 6.76 cm
 *Copy of Adult A... SC6-1E