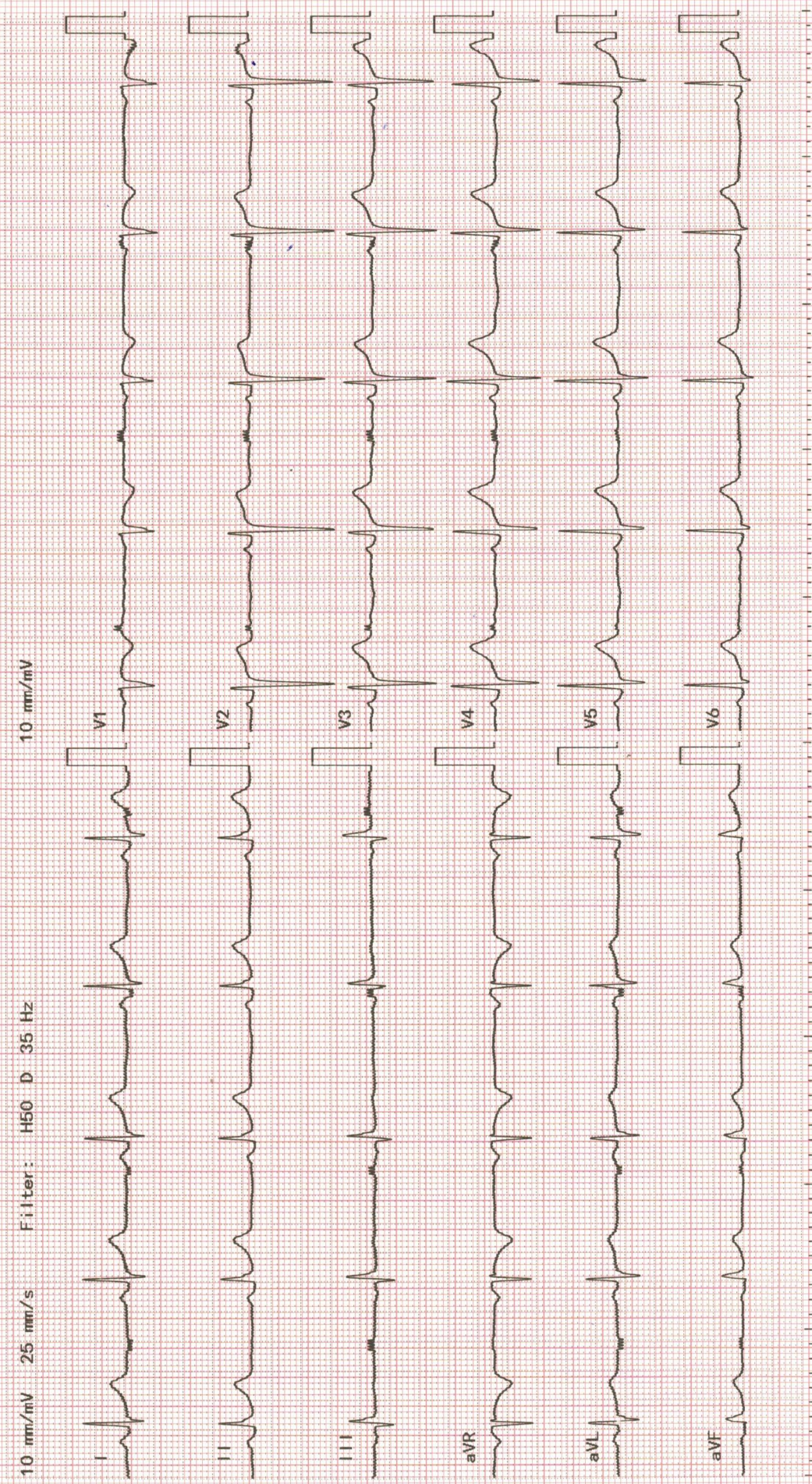


Name: mr. sridhara h v
 Birth date: / /
 Sex: M
 Weight: kg
 Height: cm
 Blood pressure: mmHg
 Age: 31 years
 Heart rate: 1100 bpm
 Rhythm: Sinus rhythm
 ECG: 9110 ** normal ECG **

Indication:
 Symptoms:
 History:
 Ent. rate: 59 bpm
 R int: 132 ms
 RS dur: 88 ms
 P/QTc(E) int: 398/397 ms
 P/QRS/T axis: 17/43/33 °
 M5/SV1 amp: 1.22/0.64 mV
 M5+SV1 amp: 1.87 mV

Unconfirmed Report
 Reviewed by:





NABH



NABL



No.1

**UNITED
HOSPITAL**Care Par Excellence
Jayanagar, Bangalore

Patient name :	Mr. SRIDHARA	Date :	24/02/24
Age :	31 years GENDER: MALE	Patient ID :	18997
Ref by :	DR.CMO	OP/IP :	HEALTH CHECK

2D- ECHOCARDIOGRAPHY**M - MODE AND DOPPLER MEASUREMENTS**

(c.m)	(c.m)	(cm/sec)		
AO : 2.5 (2.5-3.7)	LVIDD : 3.8 (3.5-5.5)	MV EV : 83.4	AV : 71.6	MR : TRIVIAL MR
LA : 3.3 (1.9-4.0)	LVIDS : 2.4 (2.4-4.2)	AV : 125		AR : NORMAL
RA : 2.0 (<4.4)	IVSD : 1.1 (0.6-1.1)	PV : 92.3		PR : NORMAL
RV : 2.2 (<3.5)	IVSS : 0.9 (0.9-1.2)	TV EV : -----	AV : -----	TR : TRIVIAL TR
TAPSE: 1.7 (>1.6)	LVPWD : 0.8 (0.6-1.1)	Diastolic Function : NO LVDD		
	LVPWS : 1.0 (0.9-1.2)			
	EF : 60%			

DESCRIPTIVE FINDINGS

Left Ventricle	: NORMAL
Right Ventricle	: NORMAL
Left Atrium	: NORMAL
Right Atrium	: NORMAL
Wall motion analysis:	NO RWMA
Mitral Valve	: NORMAL, TRIVIAL MR
Aortic Valve	: NORMAL
Tricuspid Valve	: NORMAL, TRIVIAL TR, PASP-30mmHg
Pulmonary Valve	: NORMAL
IAS	: INTACT
IVS	: INTACT
Pericardium	: NORMAL
Other Findings	: IVC NORMAL

IMPRESSION :

NORMAL CHAMBER DIMENSIONS
 NORMAL LV SYSTOLIC FUNCTION EF : 60%
 NORMAL LV DIASTOLIC FUNCTION
 NO PULMONARY HYPERTENSION
 NO REGIONAL WALL MOTION ABNORMALITIES
 NO CLOTS/ PERICARDIAL EFFUSION /VEGETATION

DR. RAHUL PATIL
CONSULTANT CARDIOLOGIST

R₁

Lubra Eye drops

1-97 x 1 month

Arumby



NABH



NABL



No.1



UNITED HOSPITAL

Care Par Excellence
Jayanagar, Bangalore

Out Patient Record

Patient Name : Mr.SRIDHARA M V

UHID : UHJA23018997

Age / Sex : 31 Years / Male

OP NO/Reg Dt : 24-02-2024 08:13 AM

Spouse / Father Name : VENKATESH

Department :

Address : # 50, Marappanahalli Devaramalluru Post
Shidlagada Taluq , BANGALORE CITY H O.

Referred By :

Consultant : Dr.Preventive Health Check Up

KMC No. : Dr. Anulekha

Complaints / Findings / Observations :

Regular health check up

Ht - 172

Wt - 82.9

Bp - 106/66 mmHg

SpO2 - 98

PR - 68 b/m

Investigations:

Treatment / Care of Plan / Provisional Diagnosis : ADD

- ① cap D - RISE for weekly once
- ② Tab ELOSINDE - MR cap x 2d (ATP)

Follow Up Advice :

Medically fit

[Signature]
Signature of the Doctor

DEPARTMENT OF RADIODIAGNOSIS

Name	Sridhara M V	Date	24/02/24
Age	31 years	Hospital ID	UHJA23018997
Sex	Male	Ref.	Health check

ULTRASOUND ABDOMEN AND PELVIS

FINDINGS:

Liver is normal in size and *shows mildly increased echopattern*. No intra or extra hepatic biliary duct dilatation. No focal lesions. **Portal vein** is normal in size, course and caliber. **CBD** is not dilated.

Gall bladder is normal without evidence of calculi, wall thickening or pericholecystic fluid.

Pancreas - Visualized part of the pancreatic head and body appears normal in size, contour and echogenicity. Rest of the pancreas is obscured by bowel gas.

Spleen is normal in size, shape, contour and echopattern. No focal lesion.

Right Kidney is normal in size (9.3 x 4.6 cms), position, shape and echopattern. Corticomedullary differentiation is maintained. No calculus or hydronephrosis.

Left Kidney is normal in size (10.1 x 4.1 cms), position, shape and echopattern. Corticomedullary differentiation is maintained. No calculus or hydronephrosis.

Retroperitoneum - Visualized aorta appeared normal. No obvious enlarged para-aortic nodes.

Urinary Bladder is minimally distended.

Prostate is normal in echopattern and size, measures ~ 12.7 cc.

No ascites or pleural effusion. Appendix could not be localized. No RIF probe tenderness.

IMPRESSION:

- **Mild fatty infiltration of liver (Grade I).**
- **No other definite sonological abnormality detected.**



Dr. Elluru Santosh Kumar
Consultant Radiologist



NABH



NABL



No.1



**UNITED
HOSPITAL**

Care Par Excellence
Jayanagar, Bangalore

DEPARTMENT OF RADIODIAGNOSIS

Name	Sridhara M V	Date	24/02/24
Age	31 years	Hospital ID	UHJA23018997
Sex	Male	Ref.	Health check

RADIOGRAPH OF THE CHEST (PA – VIEW)

FINDINGS:

Bilateral lung fields are normal.

Bilateral costo-phrenic angles are normal.

Cardia and mediastinal contours are normal.

The bony thorax is grossly normal.

IMPRESSION:

- No radiographic abnormality.

**Dr. Elluru Santosh Kumar
Consultant Radiologist**