



Patient's name : JHA RANJANA
Age/Sex : 42 Years/Female
Referred by : MEDI WHEEL
Collection Time : 09:14

Reg. ID : P-6502-23
Accession : 23575
Order Dt/time : 08/03/2024 09:14

Complete Blood Count

Sample Type: EDTA

Test Name	Result	Units	Biological Reference Interval
Blood Counts			
Haemoglobin :	11.4	Gms%	12.5 - 16.0
Total R.B.C. :	4.07	mill/c.mm	4.2 - 5.4
Total W. B. C. :	7750	/cu mm	4000 - 10500
Platelet Count :	162000	/cu.mm	1,50,000 - 4,50,000
Differential Count			
Neutrophils :	60	%	40 - 70
Lymphocytes :	35	%	20 - 40
Eosinophils :	03	%	1 - 4
Monocytes :	02	%	2 - 6
Basophils :	00	%	0 - 01
Blood Indices			
P. C. V :	35.0	%	37 - 47
M. C. V. :	86.0	fl	78 - 100
M.C.H :	28.1	pg	27 - 31
M. C. H. C :	32.7	%	32 - 36
R.D.W :	15.2	%	11.5 - 14.0
E.S.R.(Westergren Method)			
After one hour :	08	mm/hr	3 - 12

TESTS DONE ON FULLY AUTOMATED HEMATOLOGY ANALYZER.

Dr. Gayatri M. Mehta
M.D. (Pathol)
Reg. No. G-32215

DR GAYATRI MEHTA
MD(PATHOLOGY)

DR. ANAND D. PARIKH
MD(PATHOLOGY)

LAB USE ONLY (Entered by :GM Enter Date/Time:08/03/2024 17:02:00) (Verify by :GM Verify Date/Time:08/03/2024 17:02:00)



Vidhi Diagnostics | Pathology Department

L-86, Swatantra Senani Nagar, Opp. Akharnagar Petrol Pump, Nr. Akharnagar Circle, Nava-Vadaj, Ahmedabad - 380 013.

M. - Pathology : 8849893954, Ph. : 079-27621406, M. 98799 29406, 98250 09406, E-mail : vidhidiagnostics@gmail.com, Web. : www.vidhidiagnostics.com

Time (Pathology) : Mon. to Sat. 8.30 am to 8.00 pm, Sunday 9 am to 12 Noon

Pathology means science behind medicine

CT SCAN & CBCT FACILITY NOW AVAILABLE



Patient's name : JHA RANJANA
Age/Sex : 42 Years/Female
Referred by : MEDI WHEEL
Collection Time : 09:14

Reg. ID : P-6502-23
Accession : 23575
Order Dt/time : 08/03/2024 09:14

Blood Group

Sample Type: EDTA sample.

Test Name	Result
BG :	" O "
RH :	POSITIVE
Remarks	Done by forward grouping method.

Blood Glucose

Sample Type: Serum

Test Name	Result	Units	Biological Reference Interval
Fasting Blood Glucose :	107.3	mg/dl	70 - 110
Urine Sugar :	NIL		Absent
<i>GOD-POD Method.</i>			

Blood Glucose

Sample Type: Serum

Test Name	Result	Units	Biological Reference Interval
Post Prandial Blood Glucose After 2hr. :	138.4	mg/dl	80 - 140
Urine Sugar :	NIL		Absent
<i>GOD-POD Method.</i>			

Dr. Gayatri M. Mehta
M. D. (Pathol)

Reg. No. G-32215

DR GAYATRI MEHTA
MD(PATHOLOGY)

DR. ANAND D. PARIKH
MD(PATHOLOGY)

LAB USE ONLY (Entered by :GM Enter Date/Time:08/03/2024 17:03:00) (Verify by :GM Verify Date/Time:08/03/2024 17:03:00)



Vidhi Diagnostics | Pathology Department

L-86, Swatantra Senani Nagar, Opp. Akhbarnagar Petrol Pump, Nr. Akhbarnagar Circle, Nava-Vadaj, Ahmedabad - 380 013.

M. - Pathology : 8849893954, Ph. : 079-27621406, M. 98799 29406, 98250 09406, E-mail : vidhidiagnostics@gmail.com, Web. : www.vidhidiagnostics.com

Time (Pathology) : Mon. to Sat. 8.30 am to 8.00 pm, Sunday 9 am to 12 Noon

Pathology means science behind medicine

CT SCAN & CBCT FACILITY NOW AVAILABLE



Patient's name : JHA RANJANA
Age/Sex : 42 Years/Female
Referred by : MEDI WHEEL
Collection Time : 09:14

Reg. ID : P-6502-23
Accession : 23575
Order Dt/time : 08/03/2024 09:14

Lipid Profile

Sample Type: Serum

Test Name	Result	Units	Biological Reference Interval
S. Cholesterol : <small>Oxidase-esterase method.</small>	190	mg/dl	0 - 200
S. Triglyceride : <small>Enzymatic Colorimetry method</small>	249.5	mg/dL	0 - 200
S. HDL - Cholesterol : <small>Serum by Enzymatic method.</small>	48.8	mg/dL	35 - 65
S. LDL - Cholesterol : <small>Serum by Enzymatic method</small>	91.3	mg/dL	0 - 130
S. VLDL - Cholesterol :	49.9	mg/dL	0 - 30
S. Chole/HDL.Ratio :	3.89		1 - 6
S. LDL / HDL Cholesterol Ratio :	1.87		0 - 3.5

Dr. Gayatri M. Mehta
M. D. (Patho)
Reg. No. G-32215
DR. GAYATRI MEHTA
MD(PATHOLOGY)

DR. ANAND D. PARIKH
MD(PATHOLOGY)

LAB USE ONLY (Entered by :GM Enter Date/Time:08/03/2024 17:02:00) (Verify by :GM Verify Date/Time:08/03/2024 17:02:00)



Vidhi Diagnostics | Pathology Department

L-86, Swatantra Senani Nagar, Opp. Akhbarnagar Petrol Pump, Nr. Akhbarnagar Circle, Nava-Vadaj, Ahmedabad - 380 013.

M. - Pathology : 8849893954, Ph. : 079-27621406, M. 98799 29406, 98250 09406, E-mail : vidhidiagnostics@gmail.com, Web. : www.vidhidiagnostics.com

Time (Pathology) : Mon. to Sat. 8.30 am to 8.00 pm, Sunday 9 am to 12 Noon

Pathology means science behind medicine

CT SCAN & CBCT FACILITY NOW AVAILABLE



Pathology Department



Patient's name : JHA RANJANA
Age/Sex : 42 Years/Female
Referred by : MEDI WHEEL
Collection Time : 09:14

Reg. ID : P-6502-23
Accession : 23575
Order Dt/time : 08/03/2024 09:14

HbA1C

Sample Type: EDTA

Test Name	Result	Units	Biological Reference Interval
HbA1C :	5.3	%	Non-diabetic: 4.2-6.2 Pre-diabetic : 6.3-7.2 Diabetic : 7.3-8.2
Mean Blood Glucose of Last 03 months.	105	mg/dl	

Comment *As per the new 2009 update of American Diabetes Association regarding HbA1C & Mean Blood Glucose relationship.
NOTE: This test is used to monitor diabetic patients compliance with the therapeutic regimen and logo It's level is proportional to both the average blood glucose concentration and the life span of the red blood cells (RBC) in circulation. HbA1c values are free of day to day glucose fluctuations and are unaffected by exercise or recent food intake.

Dr. Gayatri M. Mehta
M. D. (Patho)
Reg. No. G-32215

DR GAYATRI MEHTA
MD(PATHOLOGY)

DR. ANAND D. PARIKH
MD(PATHOLOGY)

LAB USE ONLY (Entered by :GM Enter Date/Time 08/03/2024 17:02:00) (Verify by :GM Verify Date/Time 08/03/2024 17:02:00)



Vidhi Diagnostics | Pathology Department

L-86, Swatantra Senani Nagar, Opp. Akhbarnagar Petrol Pump, Nr. Akhbarnagar Circle, Nava-Vadaj, Ahmedabad - 380 013.

M. - Pathology : 8849893954, Ph. : 079-27821406, M. 98799 29406, 98250 09406, E-mail : vidhidiagnostics@gmail.com, Web. : www.vidhidiagnostics.com

Time (Pathology) : Mon. to Sat. 8.30 am to 8.00 pm, Sunday 9 am to 12 Noon

Pathology means science behind medicine

CT SCAN & CBCT FACILITY NOW AVAILABLE



Pathology Department



Patient's name : JHA RANJANA
Age/Sex : 42 Years/Female
Referred by : MEDI WHEEL
Collection Time : 09:14

Reg. ID : P-8502-23
Accession : 23575
Order Dt/time : 08/03/2024 09:14

BIOCHEMISTRY

Sample type :Serum

Test Name	Result	Units	Biological Reference Interval
Urea, (Serum by GLDH method) :	19.6	mg/dl	10 - 50
S.Uric acid, (Serum by Uricase method) :	7.0	mg/dl	2.6-6.0
Bun :	9.2	mg/dl	6-20
Creatinine, (Serum by Enzymatic reaction) :	0.53	mg/dl	0.5-1.2
S.G.P.T (ALT) : (Serum by IFCC method)	16.0	U/L	0 - 40
S.G.O.T (AST) : (Serum by IFCC method)	15.6	U/L	0 - 37
ALK.PHOSPHATASE : (Serum by PNP method)	113	U/L	35-104
G.G.T :	23.7	U/L	8 - 78
BILIRUBIN			
Total :	0.82	mg/dl	Up to 1.2
Direct :	0.35	mg/dl	0-0.7
Indirect :	0.47	mg/dl	0 - 0.5
SERUM PROTEINS			
Total Protein (Serum by Biuret method) :	7.12	gms/dl	6.4 - 8.5
Albumin (Serum by BCG method) :	3.94	gms/dl	3.97-4.94
Globulins :	3.18	gms/dl	2.3 - 3.5
A/G Ratio :	1.239		0.9 - 2.9

Dr. Gayatri M. Mehta
M.D. (Patho)
Reg. No. G-32215

DR GAYATRI MEHTA
MD(PATHOLOGY)

DR. ANAND D. PARIKH
MD(PATHOLOGY)

LAB USE ONLY (Entered by :GM Enter Date/Time 08/03/2024 17:02:00) (Verify by :GM Verify Date/Time:08/03/2024 17:02:00)



Vidhi Diagnostics | Pathology Department

L-86, Swatantra Senani Nagar, Opp. Akharnagar Petrol Pump, Nr. Akharnagar Circle, Nava-Vidaj, Ahmedabad - 380 013.

M. - Pathology : 8849893954, Ph. : 079-27621406, M. 98799 29406, 98250 09406, E-mail : vidhidiagnostics@gmail.com, Web. : www.vidhidiagnostics.com

Time (Pathology) : Mon. to Sat. 8.30 am to 8.00 pm, Sunday 9 am to 12 Noon

Pathology means science behind medicine

CT SCAN & CBCT FACILITY NOW AVAILABLE



Pathology Department



Patient's name : JHA RANJANA
Age/Sex : 42 Years/Female
Referred by : MEDI WHEEL
Collection Time : 09:14

Reg. ID : P-6502-23
Accession : 23575
Order Dt/time : 08/03/2024 09:14

Thyroid Function Test

Sample Type: Serum

Test Name	Result	Units	Biological Reference Interval
TOTAL T3 :	1.26	ng/ml	1.07 - 1.86
TOTAL T4 :	8.70	µg/dL	6.09 - 12.23
TSH(Ultra sensitive) :	3.98	µIU/mL	0.4001 - 4.049

Dr. Gayatri M. Mehta
M. D. (Pathol)
Reg. No. G-32215

DR GAYATRI MEHTA
MD(PATHOLOGY)

DR. ANAND D. PARIKH
MD(PATHOLOGY)

LAB USE ONLY (Entered by :GM Enter Date/Time:08/03/2024 17:05:00) (Verify by :GM Verify Date/Time:08/03/2024 17:06:00)



Vidhi Diagnostics | Pathology Department

L-86, Swatantra Senani Nagar, Opp. Akhbarnagar Petrol Pump, Nr. Akhbarnagar Circle, Nava-Vadaj, Ahmedabad - 380 013.

M. - Pathology : 8849893954, Ph. : 079-27621406, M. 98799 29406, 98250 09406, E-mail : vidhidiagnostics@gmail.com, Web. : www.vidhidiagnostics.com

Time (Pathology) : Mon. to Sat. 8.30 am to 6.00 pm, Sunday 9 am to 12 Noon

Pathology means science behind medicine

CT SCAN & CBCT FACILITY NOW AVAILABLE



Patient's name : JHA RANJANA
Age/Sex : 42 Years/Female
Referred by : MEDI WHEEL
Collection Time : 09:14

Reg. ID : P-6502-23
Accession : 23575
Order Dt/time : 08/03/2024 09:14

Urine Analysis

Sample Type: Urine

Test Name	Result	Units	Biological Reference Interval
<u>Physical Examination</u>			
Quantity :	30	ml	0 - 500 ml
Colour :	Pale Yellow		Pale Yellow
Transparency :	Slight Turbid.		Clear
Reaction :	Acidic		4.6 - 8.0
Specific Gravity :	1.025		1.016 - 1.022
Sediment :	Present		
<u>Chemical Examination</u>			
Albumin :	Present (Faint Trace)		Absent
Sugar :	NIL		Absent
Acetone :	Absent		Absent
Bile Salts :	Absent		Absent
Bile Pigments :	Absent		Absent
Urobilogen :	Absent		Absent
Nitrites :	Absent		Absent
<u>Microscopic Examination</u>			
Red blood Cells :	2-3	/h.p.f	Absent
Pus Cells :	1-2	/h.p.f	Absent
Epithelial Cells :	2-3	/h.p.f	< 10.0
Amorphous :	Absent	/h.p.f	Absent
Bacteria :	Absent	/h.p.f	Absent
Crystals :	Absent	/h.p.f	Absent
Casts :	Absent	/h.p.f	Absent
Fungus :	Not seen	/h.p.f	Absent

Dr. Gayatri M. Mehta

M. D. (Patho)

Reg. No. G-32215

DR GAYATRI MEHTA
MD(PATHOLOGY)

DR. ANAND D. PARIKH
MD(PATHOLOGY)



(Entered by :GM Enter Date/Time:08/03/2024 17:04:00) (Verify by :GM Verify Date/Time:08/03/2024 17:04:00)

Vidhi Diagnostics | Pathology Department

L-86, Swatantra Senani Nagar, Opp. Akhbarnagar Petrol Pump, Nr. Akhbarnagar Circle, Nava-Vadaj, Ahmedabad - 380 013.

M. - Pathology : 8849893954, Ph. : 079-27621406, M. 98799 29406, 98250 09406, E-mail : vidhidiagnostics@gmail.com, Web. : www.vidhidiagnostics.com

Time (Pathology) : Mon. to Sat. 8.30 am to 8.00 pm, Sunday 9 am to 12 Noon

Pathology means science behind medicine

CT SCAN & CBCT FACILITY NOW AVAILABLE



Patient's name : JHA RANJANA
Age/Sex : 42 Years/Female
Referred by : MEDI WHEEL
Collection Time : 09:14

Reg. ID : P-6502-23
Accession : 23575
Order Dt/time : 08/03/2024 09:14

Stool Examination

Sample Type: Stool

Test Name	Result	Units	Biological Reference Interval
-----------	--------	-------	-------------------------------

PHYSICAL EXAMINATION

Quantity	20 gms
Colour	Yellow
Consistency	Semi-Solid
Mucus	Nil
Occult Blood	Negative
Peroxidase Reaction with o-Dianisidine	
Reaction	Acidic
pH Strip Method	

MICROSCOPIC EXAMINATION

Pus Cells	1 - 2/hpf
RBCs	Nil
Vegetable Cells	Absent
Trophozoites	Nil
Cysts	Nil
Ova	Nil
Fat Globules	Nil

----- End Of Report -----

Dr. Gayatri M.
M. D. (Pathol)
Reg. No. G-32215

DR GAYATRI MEHTA
MD(PATHOLOGY)

DR. ANAND D. PARIKH
MD(PATHOLOGY)

LAB USE ONLY (Entered by :GM Enter Date/Time 08/03/2024 17:03:00) (Verify by :GM Verify Date/Time 08/03/2024 17:03:00)



Vidhi Diagnostics | Pathology Department

L-86, Swatantra Senani Nagar, Opp. Akhbaragar Petrol Pump, Nr. Akhbaragar Circle, Nava-Vadaj, Ahmedabad - 380 013.

M. - Pathology : 8849893954, Ph. : 079-27621406, M. 98799 29406, 98250 09406, E-mail : vidhidiagnostics@gmail.com, Web. : www.vidhidiagnostics.com

Time (Pathology) : Mon. to Sat. 8.30 am to 8.00 pm, Sunday 9 am to 12 Noon

Pathology means science behind medicine

CT SCAN & CBCT FACILITY NOW AVAILABLE

Health Check up Booking Request(bobS12660), Beneficiary Code-138693

1 message

Mediwheel <wellness@mediwheel.in>
To: vidhidiagnostics@gmail.com
Cc: customercare@mediwheel.in

2 March 2024 at 12:52



Mediwheel
...Your wellness partner

011-41195959

Dear **VIDHI DIAGNOSTICS**

We have received a booking request with the following details. Provide your confirmation by clicking on the Yes button.

You confirm this booking? Yes No

Name : MR. JHA PRAVIN KUMAR

Hospital Package Name : Mediwheel Full Body Health Checkup Female Above 40

Appointment Date : 08-03-2024


Member Information		
Booked Member Name	Age	Gender
Ranjana jha	42 year	Female

Tests included in this Package -

- Mammography
- Stool Test
- Gynae Consultation
- Thyroid Profile
- ESR
- Blood Glucose (Fasting)
- General Physician Consultation
- TMT OR 2D ECHO
- Blood Group
- Blood Glucose (Post Prandial)
- Chest X-ray
- ECG
- USG Whole Abdomen
- Eye Check-up consultation
- Urine Sugar Fasting
- Urine Sugar PP
- Dental Consultation
- Urine analysis
- CBC
- Lipid Profile
- Kidney Profile
- Liver profile

Thanks,
Mediwheel Team

Please Download Mediwheel App



You have received this mail because your e-mail ID is registered with **Arcofemi Healthcare Limited** This is a system-generated e-mail please don't reply to this message.

Please visit to our [Terms & Conditions](#) for more informaion. [Click here to unsubscribe.](#)



भारत सरकार
GOVERNMENT OF INDIA



जि रंजना
Jha Ranjana
जन्म तिथि/ DOB: 17/02/1987
स्त्री / FEMALE



2364 5682 6665

आधार-सामान्य भाषासंगी अधिष्ठा

Ranjana

Vidhi Diagnostics

L-55, Gandhinagar Terminal Nagar,
Opp. Gandhinagar Terminal
Jh. Gandhinagar Circle,
Now Vadaj, Ahmedabad-13.

2/5



Rotate

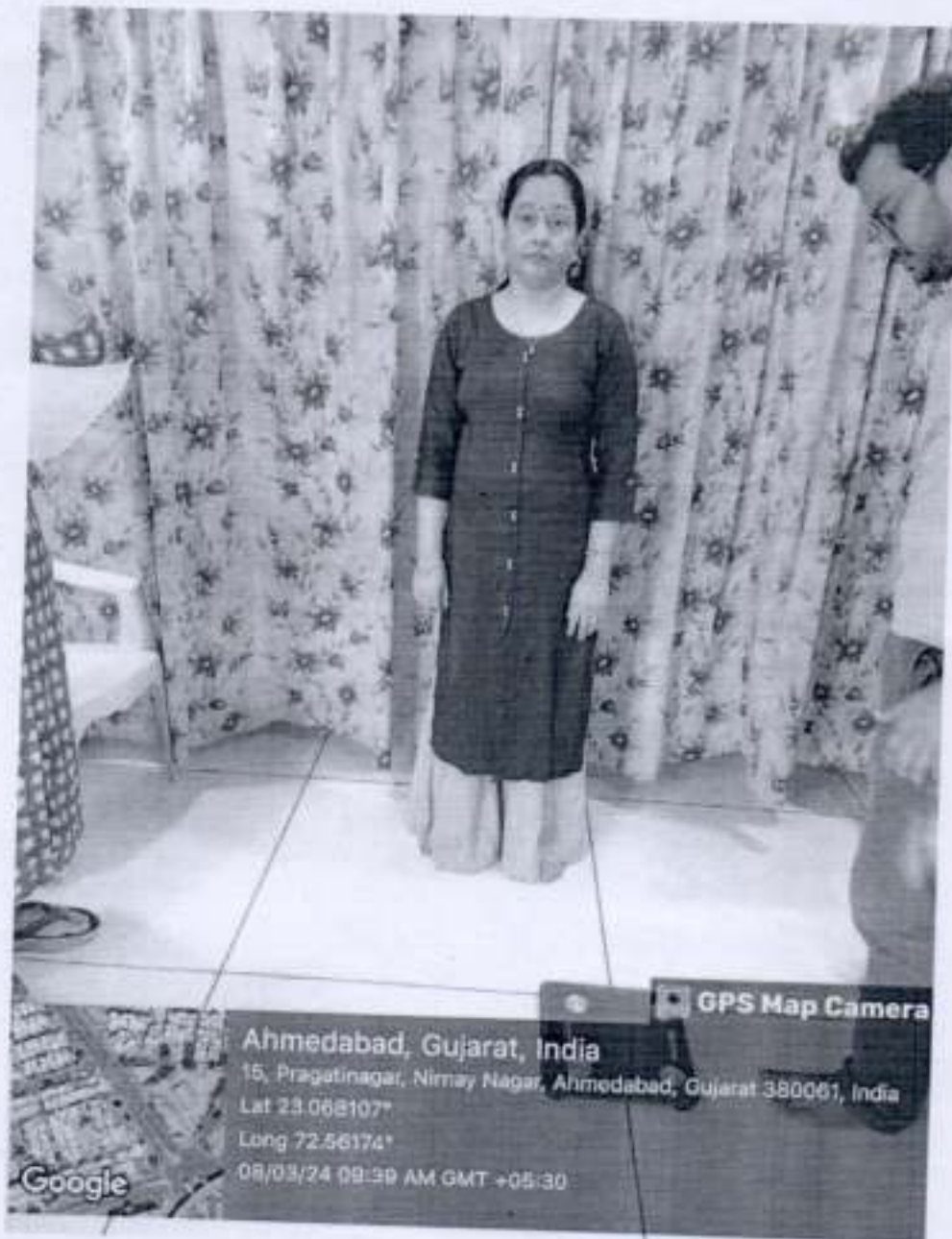

Recognize

PDF

Export Pdf

Ranjana Jha



Vidhi Diagnostics
I-39, Santantra Senani Nagar,
Opp. Ashbarnagar Bus Terminal,
Nr. Ashbarnagar Circle,
New Wadaj, Ahmedabad-13.

Dr. Dinesh S. Modh

M.D., D.M.R.E. (Radiodiagnosis)
Consultant Radiologist & Sonologist
Ex. Junior Lecturer, B.J. Medical College, Civil Hospital, Abar.



08/03/2024

Thee Ramsumar.

42 yrs / female

Height! - 156 cm

Weight! - 62 kg

BP! - 122/88 mmHg

Pulse : - 80 per min

T! - @

RS } @
CRS }

Spor! - 98

Asymptomatic

★ Eye checkup! -

→ Color vision! - Normal.

→ Distance! - N/G.

→ Near! - N/G with specs

★ Dental! -

→ Oral Hygiene normal

→ No H/O caries & Cavities
is seen.

No H/O DM, HTN, Thyroid or TB

Adv! - She is medically fit

Vidhi Diagnostics
L-86, Swatantra Senani Nagar,
Opp. Akhbarnagar Bus Terminal,
Nr. Akhbarnagar Circle,
New Market, Ahmedabad-380 013
ISO 9001:2015 Certified Diagnostics Center
Vidhi Imaging Center

Dr. Vidhi D. Modh
MBBS
Reg. No. 10540

L-86, Swatantra Senani Nagar, Opp. Indian Oil Petrol Pump, Akhbarnagar Circle, Nava Vada, Ahmedabad - 380 013.

Phone : (Radiology) 079-2762 1406 | M. 98799 29406, 98250 09406 | Time (Radiology) : Mon. to Sat. 9 am to 2 pm, 5 to 9 pm, Sunday 9 am to 12 Noon

E-mail : vidhidiagnostics@gmail.com, Website : www.vidhidiagnostics.com

Multislice CT Scan | CBCT-Dental Scan | Live 3D-4D Sonography | Colour Doppler | Echo Cardiography | Interventional Radiology | Maxillofacial Radiology | Fetal Medicine
Digital X-Ray | Digital Mammography | Digital OPG/TMJ | ECG/TMT/PFT/EEG/EMG | Audiometry | Pathology Laboratory | Health Check Up Plans | Pre Employment Check Up

CT SCAN & CBCT FACILITY NOW AVAILABLE

08-03-2024 09:19:25

<< Analysis Result >>

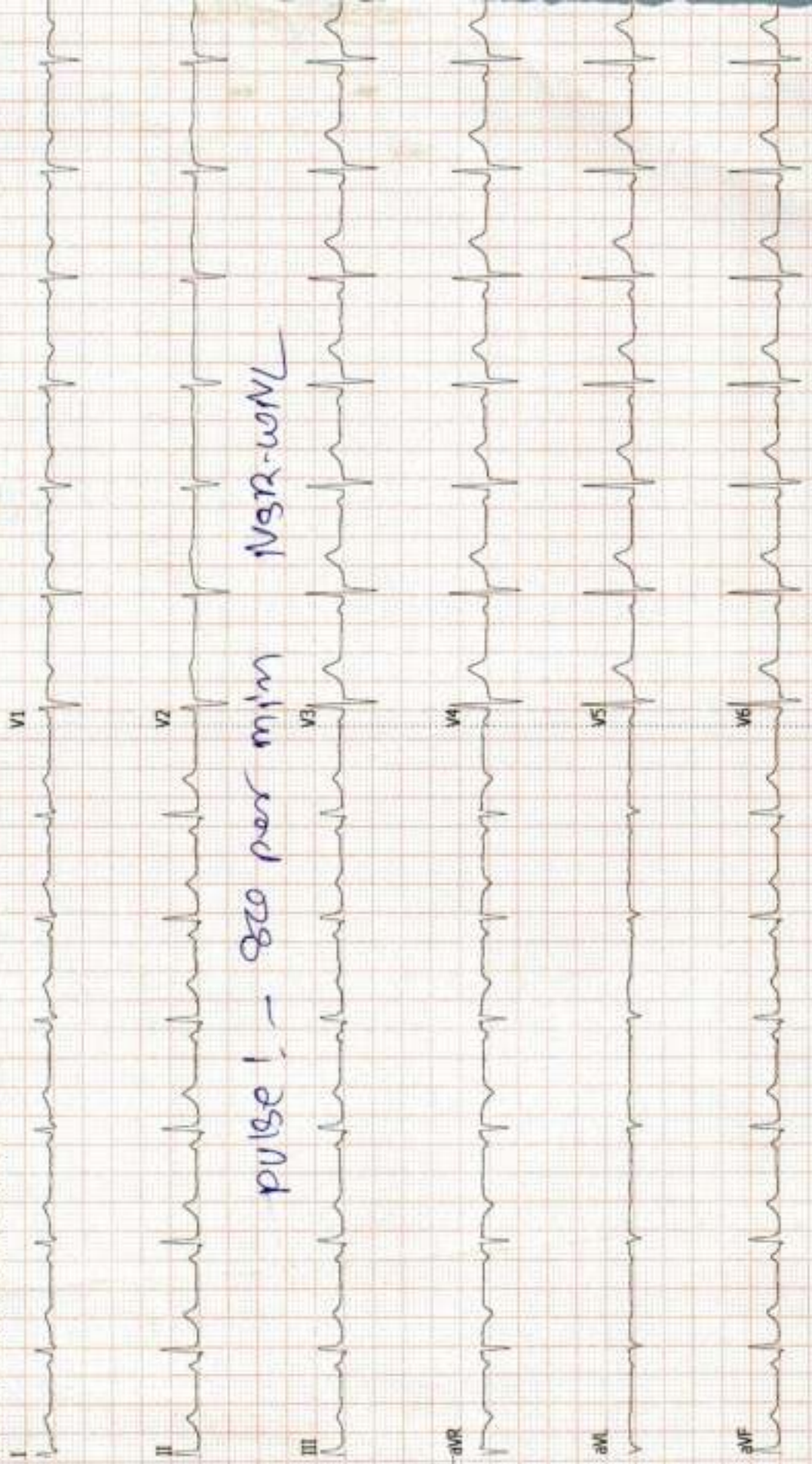
ID: 12885
 Name: Jha **Vinash Kumar**
 Age: 42yrs
 Sex: Female
 Hospital: **G-45946**

HR : 81 bpm
 PR : 126 ms
 QRS : 80 ms
 QT/QTc : 352/408 ms
 P/QRS/T : 66/67/50 deg
 RV5/SV1 : 0.903/-0.533 mv
 RV5+SV1 : 1.436 mv

Vidhi Diagnostics
 L-60, Cybercity-Sector 14
 C.P.O. Ashok Nagar Bus Terminal,
 Nr. Ashok Nagar Circle,
 New Wadaj, Ahmedabad-13

Need to be confirmed by doctor. Doctor Name: _____

0.67Hz - 35Hz AC 50Hz 25 mm/s 10 mm/mv



Dr. Dinesh S. Modh

M.D., D.M.R.E. (Radiodiagnosis)
Consultant Radiologist & Sonologist
Ex. Junior Lecturer, B.J. Medical College, Civil Hospital, A'bad.



Patient's name : RANJANA JHA
Reg. ID : R-14089-23
Referred by : MEDI WHEEL

Age/Sex : 41 Years/Female
Accession : 23590
Date : 08/03/2024

2D- ECHO REPORT

FINAL CONCLUSION:

LV IS NORMAL SIZE. GOOD LV SYSTOLIC FUNCTION NO RWMA.
LVEF - 60%. NO CONCENTRIC LVH.
NORMAL LV COMPLIANCE.
LA IS NORMAL SIZE. NO LA CLOT.
RV IS NORMAL SIZE. GOOD RV SYSTOLIC FUNCTION.
RA IS NORMAL SIZE.
MITRAL VALVE IS NORMAL. NO MS. NO MR. NO MVP.
AORTIC VALVE IS NORMAL. NO AS. NO AR.
TRICUSPID VALVE IS NORMAL. NO TR. RVSP-26 mmHg. NO PAH.

NO CLOT, NO VEGETATION, NO PERICARDIAL EFFUSION.

DIMENSIONS:

AORTA	2.6 C.M
LEFT ATRIUM	2.7 C.M
LVDD	4.1 C.M.
IVSD	1.0 C.M
PWD	1.0 C.M
LVDS	2.6 C.M.

COLOUR DOPPLER FINDING:

STRUCTURE	VELOCITY m/sec
	Max
PULMONARY VALVE	0.7
MITRAL VALVE	E : 0.7 A : 0.4
AORTIC VALVE	1.0

Dr. Avinash Bhaskar

G-49946

DR AVINASH BHASKAR
CLINICAL CARDIOLOGIST
9924836431

ISO 9001:2015 Certified Diagnostics Center

Vidhi Imaging Center

L-86, Swatantra Senani Nagar, Opp. Indian Oil Petrol Pump, Akharnagar Circle, Nava Vada, Ahmedabad - 380 013.

Phone : (Radiology) 079-2762 1406 | M. 98799 29406, 98250 09406 | Time (Radiology) : Mon. to Sat. 9 am to 2 pm, 5 to 9 pm, Sunday 9 am to 12 Noon
E-mail : vidhidiagnostics@gmail.com, Website : www.vidhidiagnostics.com

Multislice CT Scan | CBCT-Dental Scan | Live 3D-4D Sonography | Colour Doppler | Echo Cardiography | Interventional Radiology | Maxillofacial Radiology | Fetal Medicine
Digital X-Ray | Digital Mammography | Digital OPG/TMJ | ECG/TMT/PFT/EEG/ENG | Audiometry | Pathology Laboratory | Health Check Up Plans | Pre Employment Check Up

CT SCAN & CBCT FACILITY NOW AVAILABLE

Dr. Dinesh S. Modh

M.D., D.M.R.E. (Radiodiagnosis)

Consultant Radiologist & Sonologist

Ex. Junior Lecturer, B.J. Medical College, Civil Hospital, Abad.



Patient's name : RANJANA JHA
Reg. ID : R-14089-23
Referred by : MEDI WHEEL

Age/Sex : 41 Years/Female
Accession : 23590
Date : 08/03/2024

USG ABDOMEN

LIVER: - Liver appears normal in size & show normal echotexture. No evidence of diffuse or focal lesion is seen. Intrahepatic biliary radicals appear normal. Portal vein and CBD appear normal. No e/o calculus is seen in bile duct.

GALL BLADDER: - Gall bladder is not seen(h/o operation).

SPLEEN: - Spleen appears normal in size & shows normal echotexture. No evidence of diffuse or focal lesion is seen.

PANCREAS: - Pancreas appears normal size and echopattern. No e/o diffuse or focal lesion is seen. Main pancreatic duct appears normal.

KIDNEY:-Both Kidneys appear normal in size & echotexture.

No e/o calculus or hydronephrosis or hydroureter is seen in either side.

Cortico-medullary differentiation is maintained on either side.

Both suprarenal regions appear normal.

RIF & BOWEL LOOPS (By high frequency probe):-Normal.

No evidence of pre & para aortic lymphadenopathy is seen.

No evidence of free fluid is seen in abdomen.

No evidence of dilated or thickened bowel loops is seen.

Urinary bladder: - appears normal. No e/o calculus or mass lesion is seen in bladder.

Uterus appears normal in size and echopattern.

No evidence of diffuse or focal lesion is seen.

Cervical region appears normal.

Endometrial thickness is 6.4mm.

Both adnexal regions appear normal.

No e/o free fluid is seen in pouch of Douglas.

Thanks for reference.


Dr. Dinesh S. Modh
MD DMRE (Radiodiagnosis)
G-23826

DR DINESH S. MODH

M.D. DMRE(RADIODIAGNOSIS)

ISO 9001:2015 Certified Diagnostics Center

Vidhi Imaging Center

L-86, Swatantra Senani Nagar, Opp. Indian Oil Petrol Pump, Akhbarnagar Circle, Nava Vadaj, Ahmedabad - 380 013.

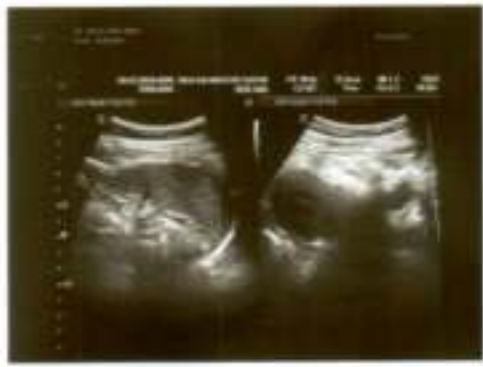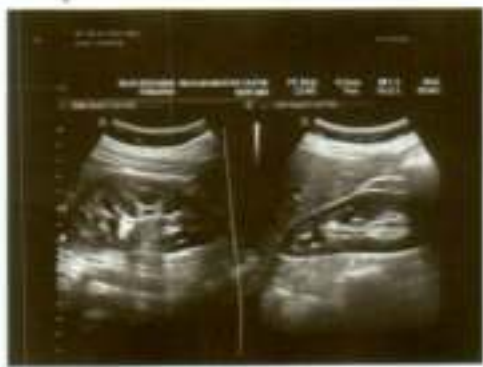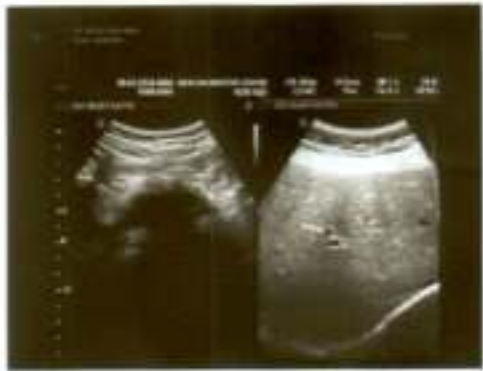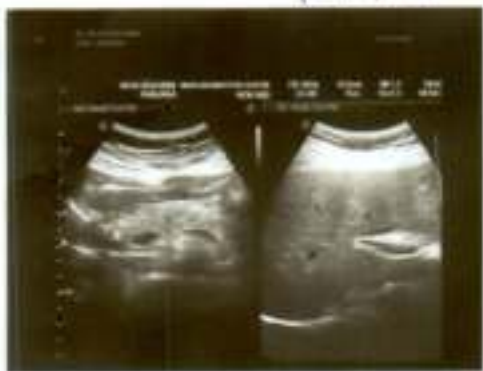Phone : (Radiology) 079-2762 1406 | M. 98799 29406, 98250 09406 | Time (Radiology) : Mon. to Sat. 9 am to 2 pm, 5 to 9 pm, Sunday 9 am to 12 Noon

E-mail : vidhidiagnostics@gmail.com, Website : www.vidhidiagnostics.com

Multislice CT Scan | CBCT-Dental Scan | Live 3D-4D Sonography | Colour Doppler | Echo Cardiography | Interventional Radiology | Maxillofacial Radiology | Fetal Medicine
Digital X-Ray | Digital Mammography | Digital OPG / TMJ | ECG / TMT / PFT / EEG / EMG | Audiometry | Pathology Laboratory | Health Check Up Plans | Pre Employment Check Up

CT SCAN & CBCT FACILITY NOW AVAILABLE

Amnion



Dr. Dinesh S. Modh

M.D., D.M.R.E. (Radiodiagnosis)

Consultant Radiologist & Sonologist

Ex. Junior Lecturer, B.J. Medical College, Civil Hospital, A'bad.



Patient's name : RANJANA JHA
Reg. ID : R-14089-23
Referred by : MEDI WHEEL

Age/Sex : 41 Years/Female
Accession : 23590
Date : 08/03/2024

DIGITAL MAMMOGRAPHY

Digital mammography was done on Siemens mammomat-3000.

Reason for exam: - Screening.

Bilateral digital cranio-caudal and medio-lateral oblique views were taken.
The breast tissue is homogeneously dense with fibro-fatty tissue on both sides.
No masses, no architectural distortion, no suspicious calcifications, no asymmetries or other abnormalities are seen.
No e/o radio-opaque or radiolucent mass lesion is seen.
No e/o skin thickening is seen.
Nipple and sub-areolar tissue appear normal.
Axillary tail appears normal.

USG:-Normal.

Assessment:-Negative (BI-RADS category-1)

BI-RADS category

- 0- incomplete
- 1- Negative
- 2- Benign
- 3- Probably benign
- 4- Suspicious abnormality.
- 5- Highly suggestive of malignancy
- 6- Known biopsy-proven malignancy.

The false negative mammography is approximately 10%. Management of palpable abnormality must be based upon clinical grounds.

Thanks for reference.

Dr. Dinesh S. Modh
DR. DINESH S. MODH
MD DMRE (Radiodiagnosis)
M.D. DMRE (RADIOLOGIST)
G-23825

Dr. Dinesh S. Modh
MD DMRE (Radiodiagnosis)
G-23825

ISO 9001:2015 Certified Diagnostics Center

Vidhi Imaging Center

L-86, Swatantra Senani Nagar, Opp. Indian Oil Petrol Pump, Akhbaragar Circle, Nava Vadaaj, Ahmedabad - 380 013.

Phone : (Radiology) 079-2762 1406 | M. 98799 29406, 98250 09406 | Time (Radiology) : Mon. to Sat. 9 am to 2 pm, 5 to 9 pm, Sunday 9 am to 12 Noon

E-mail : vidhidiagnostics@gmail.com, Website : www.vidhidiagnostics.com

Multislice CT Scan | CBCT-Dental Scan | Live 3D-4D Sonography | Colour Doppler | Echo Cardiography | Interventional Radiology | Maxillofacial Radiology | Fetal Medicine
Digital X-Ray | Digital Mammography | Digital OPG/TMJ | ECG/TMT/PFT/EEG/EMG | Audiometry | Pathology Laboratory | Health Check Up Plans | Pre Employment Check Up

CT SCAN & CBCT FACILITY NOW AVAILABLE

Dr. Dinesh S. Modh

M.D., D.M.R.E. (Radiodiagnosis)

Consultant Radiologist & Sonologist

Ex. Junior Lecturer, B.J. Medical College, Civil Hospital, A'bad.



Patient's name : RANJANA JHA
Reg. ID : R-14089-23
Referred by : MEDI WHEEL

Age/Sex : 41 Years/Female
Accession : 23590
Date : 08/03/2024

X-RAY CHEST (PA VIEW)

Both lung fields appear normal.
No e/o consolidation or cavitations is seen.
Both costo-phrenic angles appear clear.
Cardiac size is within normal limits.
Both domes of diaphragm appear normal.
Bony thoracic cage appears normal.

Thanks for reference.


Dr. Dinesh S. Modh
MD DMRE (Radiodiagnosis)

DR DINESH S. MODH

M.D. DMRE(RADIODIAGNOSIS)

ISO 9001:2015 Certified Diagnostics Center

Vidhi Imaging Center

L-86, Swatantra Senani Nagar, Opp. Indian Oil Petrol Pump, Akhbarnagar Circle, Nava Vadaj, Ahmedabad - 380 013.

Phone : (Radiology) 079-2762 1406 | M. 98799 29406, 98250 09406 | Time (Radiology) : Mon. to Sat. 9 am to 2 pm, 5 to 9 pm, Sunday 9 am to 12 Noon

E-mail : vidhidiagnostics@gmail.com, Website : www.vidhidiagnostics.com

Multislice CT Scan | CBCT-Dental Scan | Live 3D-4D Sonography | Colour Doppler | Echo Cardiography | Interventional Radiology | Maxillofacial Radiology | Fetal Medicine
Digital X-Ray | Digital Mammography | Digital OPG / TMJ | ECG / TMT / PFT / EEG / EMG | Audiometry | Pathology Laboratory | Health Check Up Plans | Pre Employment Check Up

CT SCAN & CBCT FACILITY NOW AVAILABLE