

DAKSH HOSPITAL

396 - 397, Gandhi Nagar, Scheme No. 8, ALWAR -301001

Ref. No.

Date.....

MEDICAL EXAMINATION REPORT
Mediwheel (BOB)

Name: Mr. Hitesh Yadav

Age: 33 yrs Sex: Male

Date: 26/01/2024

General Physical ExaminationHeight : 166 cm
Pulse : 78 /mt
Respiration : 18 /mtWeight : 80.8 kg
BP : 110/70 mm/hg
BMI : 29.3 kg/m²Systemic Exam:-

NORMAL

Dental Check up:-

NORMAL

Eye check-up:-

NORMAL

Skin Check up:-

NORMAL

ENT Check up:-

NORMAL

Impression:-' O/T/P - 55/73, ↑ TG 275, TC 170, Fatty Liver, LK Stone 4.5
' Father ~~DM~~ DM/CAD, mother HTN, BMS
LymphomaRecommendation:-

Life style modification, diet Kt. Reduce, Avoid Fat/Sugar

Dr. Mukesh Kumar Gupta
MD Gen. Medicine
Reg. No 5423/16262डॉ० मुकेश गुप्ता
M.D.F.C.C.S.
फिजिशियन एवं मधुमेह रोग विशेषज्ञ
दक्ष हॉस्पिटल, अलवर
रजि० नं०-5423/16262

Results

Run Date 26/01/2024 12:29:25 PM

Operator DAKSH

Last Name

Sample ID 8

First Name MR HITESH

Department

Gender Male

Age

Physician DR. MUKESH GUPTA M.D

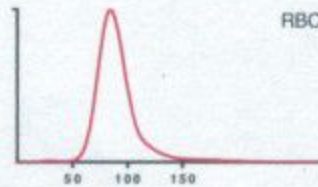
Patient ID AUTO_PID18984

Type Man


Date of birth

Sample comments

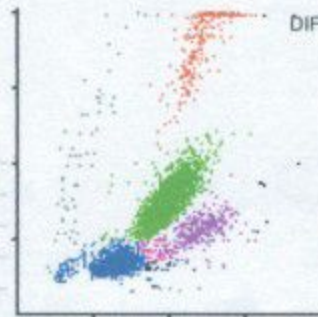
			Range
RBC	5.78 h	10 ⁶ /μL	3.80 - 5.50
HGB	17.2 h	g/dL	13.0 - 17.0
HCT	52.2 h	%	39.0 - 52.0
MCV	90.3	μm ³	76.0 - 100.0
MCH	29.8	pg	26.0 - 34.0
MCHC	33.0	g/dL	32.0 - 35.0
RDW-CV	15.0	%	11.0 - 16.0
RDW-SD	53.1 h	μm ³	37.0 - 49.0



			Range
PLT	282	10 ³ /μL	150 - 450
PCT	0.29	%	0.15 - 0.40
MPV	10.3	μm ³	8.0 - 11.0
PDW	17.4	μm ³	11.0 - 22.0
P-LCC	94	10 ³ /μL	44 - 140
P-LCR	33.2	%	18.0 - 50.0



			Range
WBC	7.73	10 ³ /μL	3.50 - 10.00
	#	Range	%
NEU	3.69	1.60 - 7.00	47.9
LYM	3.36 h	1.00 - 3.00	43.5
MON	0.17 l	0.20 - 0.80	2.3
EOS	0.40	0.00 - 0.50	5.2
BAS	0.09	0.00 - 0.15	1.1 h
LIC	0.02	0.00 - 0.10	0.3



Dr. R.S. Gupta

Dr. R.S. GUPTA
MD (Pathology) (MAHE)
RMC No. 7924/19778

Date :-26/1/2024

Name :- MR.HITESH YADAV

Age & Sex :- 33 Yrs/ male

Refd. :- Dr Mukesh Gupta M.D.

	TEST NAME	RESULT	REFERENCE RANGE	
		ESR	15	00 -20 mm/hrs
Blood Group & Rh Factor		B ⁺ POSITIVE		
HbA1C		4.95	4 - 5.6%	
Blood Sugar (F)		91.1	< 70 - 100 mg/dl	
Blood Sugar (PP)		102.1	< 140 mg/dl	
Urine Sugar (F)		NIL	-	
Urine Sugar (PP)		NIL	-	
LIVER		S.Bilirubin Total	1.3	0.30 - 1.20 mg/dl
	S.Bilirubin Direct	0.4	0.10 - 0.30 mg/dl	
	S.Bilirubin Indirect	0.9	0.30 - 0.90 mg/dl	
	S.G.O.T.	55	> 37 u/l	
	S.G.P.T.	73	> 40 u/l	
	S.Alk. Phosp.	239	80 - 306 u/l	
	G.G.T.	25	5 -40 u/l	
	Total Protein	6.9	6.5 - 8.5 gm/dl	
	Albumin	3.9	3.8 - 5.4 gm/dl	
	Globulin	3.0	2.3 - 3.5 gm/dl	
	A/G Ratio	1.2	-	
	AST/ALT Ratio	0.75	-	
KIDNEY	Blood Urea	29.1	15 -45 mg/dl	
	S.Creatinine	1.3	0.60 - 1.30 mg/dl	
	BUN	20.1	6 -24 mg/dl	
	S.Uric Acid	5.1	M 3.1 - 7.0, F 2.5 - 5.6 mg/dl	
	BUN/Creatinine Ratio	15.1	-	
LIPID PROFILE	Total Cholesterol	170.1	Up to 200 mg/dl	
	S.HDL	45.1	30 - 70 mg/dl	
	S.LDL	70.1	Up to 170 mg/dl	
	S.VLDL	55.1	5.0 - 40 mg/dl	
	S. Triglycerides	275.1	Up to 170 mg/dl	
	LDL/HDL Ratio	1.5	-	
THYROID	Total Cholesterol/ HDL Ratio	3.7	-	
	T3	95.1	40 - 181 ng/dl	
	T4	7.0	4.6 - 10.5 µg/dl	
TSH	2.99	0.30 - 5.0 mlu/l		
URINE EXAMINATION			Microscopic Examination:	
General/Chemical Examination:	Colour	Pale Yellow	RBC	Absent
	Reaction	Acidic	WBC	0 - 1
	Specific Gravity	QNS	Epithelial Cells	Absent
	Appearance	Clear	Cast	Absent
	Albumin	Nil	Crystal	Absent
	Sugar	Nil	Spermatozoa	Absent
			Amorphous Sediments	Absent
			Other	Absent
X-RAY CHEST	NORMAL STUDY			
STOOL EXAMINATION			Microscopic Examination:	
General/ Chemical Examination:	Colour	BRONISH	RBC	NIL
	Consistency	SOLID	WBC	NIL
			Ova & Parasites	NIL

Dr. R. S. GUPTA
MD (Pathology) (MAHE)
RMC No. 7924/19778

TECHNOLOGIST

All investigation have their own limitations regarding the sensitivity & specificity of individual assay procedures, Isolated laboratory investigations never confirm the final diagnosis of the disease. They only help in arriving at a diagnosis in conjunction with clinical presentation and other related investigations. Report is not valid for medico-legal purpose subject to ALWAR jurisdiction only.



दक्ष हॉस्पिटल

396, गाँधी नगर स्कीम नं.8, अलवर (राज०) ☎ 0144-2703340

Sonography / 2D Echo Cardiography / Doppler Report

2D/ ECHO REPORT

Name: - Mr. Hitesh Yadav

Age: - 33 Yrs

Date: - 26-Jan-24

Reg. No.: - Alw/2009/04

BOB health checkup

PROCEDURES:

M-MODE/2D/DOPPLER/COLOR/CONTRAST B.A.S. M²

MEASUREMENT:		DOPPLER:			
AOD	23.9	NORMAL (20- 37mm)	MV 0.7	NORMAL (cm/sec.) (0.8- 1.3)	MR No
LA	26.5	(19- 40mm)	AV 1.5	(1.2- 1.8)	AR No
AVO	16.2	(12- 25mm)	TV 0.6	(0.3- 0.8)	TR No
RVDd.	9.7	(03- 09mm)	PV 0.8	(0.7- 1.1)	PR No
LVDd	51.7	(37- 56mm)	MITRAL VALVE-		
LVDs	33	(22- 40mm)	AML	Normal	
IVS d	7.8	(06- 12mm)	PML	Normal	
IVS s	11.6		AORTIC VALVE		
PWd	4.5	(05- 10mm)	Normal		
LV FUNCTION		TV & PV are normal.			
M- E- S Separation		<0.9cm			
Minor		24.42%			
LV Ejection Fraction	66%	65 +/- 12%			

MITRAL E>A

LV WALL MOTION: NO RWMA

ALL CARDIAC CHAMBERS ARE NORMAL

ALL VALVES ARE NORMAL

NO CLOT, VEGETATION, PERICARDIAL EFFUSION

Adv: - Follow up/ review at higher center for confirmation

Note: - Please Correlate clinically. Due to technical limitations as well as inaccuracies inherent in the laboratory and statistical analysis of biological process. Diagnostic accuracy of ECHO is up to 95% only.
Report is not valid for medico-legal purpose.

DR. MUKESH GUPTA
PHYSICIAN

Dr. Mukesh Kumar Gupta

Physician & Sonologist

RM 5423/16262



श्रृण लिंग परीक्षण की शिकायत
104 टोल फ्री सेवा पर भी की
जा सकती है।
श्रृण लिंग परीक्षण की शिकायत 104 टोल फ्री सेवा पर भी की जा सकती है।



दक्ष हॉस्पिटल

396, गाँधी नगर स्कीम नं.8, अलवर (राज०) ☎ 0144-2703340

Sonography / 2D Echo Cardiography / Doppler Report

Name: MR. Hitesh Yadav /M/33 YRS

Date: 26-Jan-24

BOB HEALTH CHECK UP

U.S.G. OF ABDOMEN & PELVIS

LIVER

Liver is **15.2 cm vertically with moderate echo genicity**. Intra hepatic biliary radicals are not dilated.
No evidence of focal or diffuse lesion.

GALL BLADDER

Gall bladder is normal dilated. Lumen clear. Wall thickness normal. CBD normal

PANCREAS

Pancreas is normal in size, shape & echo-texture.

SPLEEN

9.5 cm in size with normal shape & echo- texture.

BOTH KIDNEY

Left kidney has 4.5 mm upper pole stone without hydronephrosis.
Right kidney appear normal size, shape & echo-texture

PROSTATE is normal shape, size & echo texture..

URINARY BLADDER is normally distended, visualized lumen appear clear. Wall thickness normal.

Impression:- Fatty liver Grade II
Left kidney stone.

Please correlate clinically. USG accuracy is 95 % due to technical limitations as well as inaccuracies inherent in the laboratory and statistical analysis biological process.

This report is not valid for medico-legal cases.


DR. MUKESH GUPTA
SONOLOGIST
Dr. Mukesh Kumar Gupta
Physician & Sonologist
RM 5423/16262



"भ्रूण लिंग परीक्षण की शिकायत
104 टोल फ्री सेवा पर भी की
जा सकती है"

भ्रूण लिंग परीक्षण की शिकायत 104 टोल फ्री सेवा पर भी की जा सकती है।

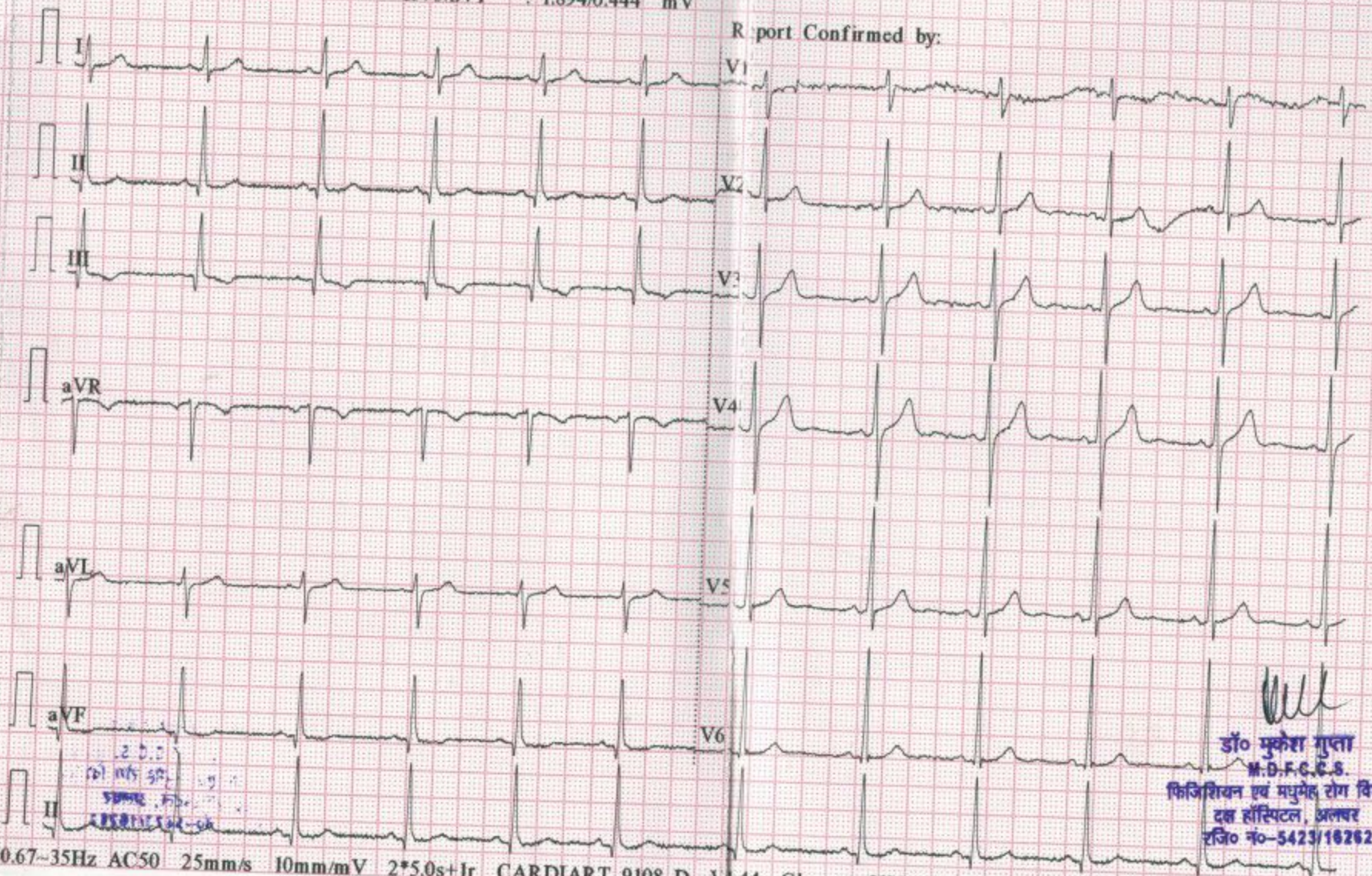
Female Years
Req. No. :

HR : 67 bpm
P : 86 ms
PR : 128 ms
QRS : 90 ms
QT/QTcBz : 374/395 ms
P/QRS/T : 46/73/-2 °
RV5/SV1 : 1.894/0.444 mV

Diagnosis Information:

Sinus arrhythmia
Inferior T wave abnormality is borderline for age and gender
Borderline ECG

Report Confirmed by:



20.2
को 11/5 502
5/20/2022
12:00 PM

डॉ० मुकेश गुप्ता
M.D.F.C.C.S.
फिजिशियन एवं मधुमेह रोग विशेषज्ञ
दक्ष हॉस्पिटल, अलवर
रजि० नं०-5423/16262

R

