

**DAKSH HOSPITAL**

396 - 397, Gandhi Nagar, Scheme No. 8, ALWAR -301001

Ref. No.

Date.....

MEDICAL EXAMINATION REPORT

Mediwheel (BOB)

Name: Mr. Neeraj Singh

Age: 35 yrs

Sex: Male

Date: 24/02/2024

General Physical Examination

Height : 166 cm

Pulse : 88 /mt

Respiration : 18 /mt

Weight : 83 kg

BP : 130/90 mm/hg

BMI : 30.1 kg/m<sup>2</sup>Systemic Exam:-

NORMAL

loss of strain -

Dental Check up:-

NORMAL

Eye check-up:-

NORMAL

Skin Check up:-

NORMAL

ENT Check up:-


NORMAL

Impression:-

NORMAL

Recommendation:-

urologist opinion

  
 Dr. Mukesh Kumar Gupta  
 MD Gen. Medicine  
 Reg. No 5423/16262

 डॉ० मुकुंदा गुप्ता  
 M.D.F.C.C.S.  
 फिजिशियन एवं मधुमेह रोग विशेषज्ञ  
 दक्ष हॉस्पिटल, अलवर  
 रजि० नं०-5423/16262

## Results

Run Date 24/02/2024 09:46:42 AM

Operator DAKSH

Last Name

Sample ID 4

First Name MR NEERAJ SINGH

Department

Gender Male

Age

Physician DR. MUKESH GUPTA M.D

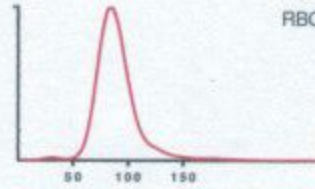
Patient ID AUTO\_PID19681

Type Man

Date of birth

Sample comments

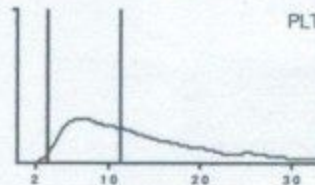
			Range
RBC	5.23	10 <sup>9</sup> /μL	3.80 - 5.50
HGB	15.2	g/dL	13.0 - 17.0
HCT	46.8	%	39.0 - 52.0
MCV	89.5	μm <sup>3</sup>	76.0 - 100.0
MCH	29.1	pg	26.0 - 34.0
MCHC	32.6	g/dL	32.0 - 35.0
RDW-CV	15.8	%	11.0 - 16.0
RDW-SD	55.2	H μm <sup>3</sup>	37.0 - 49.0



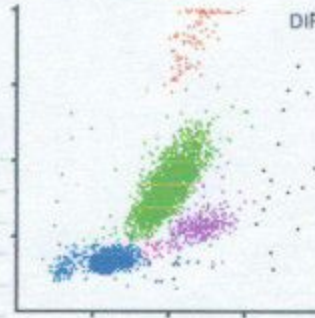
### Recommended actions

- Slide review
- Susp. Pathologies
- Macroplatelets

			Range
PLT	243	* 10 <sup>9</sup> /μL	150 - 450
PCT	0.31	* %	0.15 - 0.40
MPV	12.7	H* μm <sup>3</sup>	8.0 - 11.0
PDW	24.2	h* μm <sup>3</sup>	11.0 - 22.0
P-LCC	122	10 <sup>9</sup> /μL	44 - 140
P-LCR	50.1	h %	18.0 - 50.0



			Range
WBC	7.03	10 <sup>9</sup> /μL	3.50 - 10.00
	#	Range	%
NEU	4.37	1.60 - 7.00	62.3
LYM	2.31	1.00 - 3.00	33.1
MON	0.14	0.20 - 0.80	2.0
EOS	0.14	0.00 - 0.50	2.0
BAS	0.04	0.00 - 0.15	0.6
LIC	0.03	0.00 - 0.10	0.5



*Dr. R.S. Gupta*  
**Dr. R.S. GUPTA**  
 MD (Pathology) (MAHE)  
 RMC No. 7924/19778

Doctor

TECHNOLOGIST

All investigation have their own limitations regarding the sensitivity & specificity of individual assay procedures. Isolated laboratory investigations never confirm the final diagnosis of the disease. They only help in arriving at a diagnosis in conjunction with clinical presentation and other related investigations. Report is not valid for medico-legal purpose subject to ALWAR jurisdiction only.

Date :-24/02/2024

Name :- MR.NEERAJ SINGH

Age &amp; Sex :- 30 Yrs/ male

Refd. :- Dr Mukesh Gupta M.D.

	TEST NAME	RESULT	REFERENCE RANGE	
	ESR	15	00 -20 mm/hrs	
	Blood Group & Rh Factor	O <sup>+</sup> POSITIVE		
	HbA1C	4.2	4 - 5.6%	
	Blood Sugar (R)	96.3	< 150 mg/dl	
	Blood Sugar (PP)	-	< 140 mg/dl	
	Urine Sugar (F)	NIL	-	
	Urine Sugar (PP)	NIL	-	
<b>LIVER</b>	S.Bilirubin Total	1.3	0.30 - 1.20 mg/dl	
	S.Bilirubin Direct	0.4	0.10 - 0.30 mg/dl	
	S.Bilirubin Indirect	0.9	0.30 - 0.90 mg/dl	
	S.G.O.T.	36	> 37 u/l	
	S.G.P.T.	54	> 40 u/l	
	S.Alk. Phosp.	196	80 - 306 u/l	
	G.G.T.	26	5 -40 u/l	
	Total Protein	6.9	6.5 - 8.5 gm/dl	
	Albumin	3.7	3.8 - 5.4 gm/dl	
	Globulin	3.2	2.3 - 3.5 gm/dl	
A/G Ratio	1.1	-		
AST/ALT Ratio	0.6	-		
<b>KIDNEY</b>	Blood Urea	31.7	15 -45 mg/dl	
	S.Creatinine	1.0	0.60 - 1.30 mg/dl	
	BUN	20	6 -24 mg/dl	
	S.Uric Acid	5.5	M 3.1 - 7.0, F 2.5 - 5.6 mg/dl	
	BUN/Creatinine Ratio	20.0	-	
<b>LIPID PROFILE</b>	Total Cholesterol	160	Up to 200 mg/dl	
	S.HDL	45	30 - 70 mg/dl	
	S.LDL	86	Up to 170 mg/dl	
	S.VLDL	29	5.0 - 40 mg/dl	
	S. Triglycerides	145	Up to 170 mg/dl	
	LDL/HDL Ratio	1.9	-	
	Total Cholesterol/ HDL Ratio	3.5	-	
<b>THYROID</b>	T3	89.4	40 - 181 ng/dl	
	T4	6.8	4.6 - 10.5 µg/dl	
	TSH	5.12	0.30 - 5.0 mIU/l	
<b>URINE EXAMINATION</b>			<b>Microscopic Examination:</b>	
<b>General/Chemical Examination:</b>	Colour	Pale Yellow	RBC	Absent
	Reaction	Acidic	WBC	0 - 1
	Specific Gravity	QNS	Epithelial Cells	0- 1
	Appearance	Clear	Cast	Absent
	Albumin	Nil	Crystal	Absent
	Sugar	Nil	Spermatozoa	Absent
			Amorphous Sediments	Absent
<b>X-RAY CHEST</b>			Other	Absent
<b>NORMAL STUDY</b>				
<b>STOOL EXAMINATION</b>			<b>Microscopic Examination:</b>	
<b>General/Chemical Examination:</b>	Colour	-	RBC	-
	Consistency	-	WBC	-
			Ova & Parasites	-

  
**Dr. R.S. GUPTA**  
 MD (Pathology) (MAHE)  
 BMC No. 7924/19778  
 Doctor

**TECHNOLOGIST**

All investigation have their own limitations regarding the sensitivity & specificity of individual assay procedures. Isolated laboratory investigations never confirm the final diagnosis of the disease. They only help in arriving at a diagnosis in conjunction with clinical presentation and other related investigations. Report is not valid for medico-legal purpose subject to ALWAR jurisdiction only.



# दक्ष हॉस्पिटल

396, गाँधी नगर स्कीम नं.8, अलवर (राज०) ☎ 0144-2703340

## Sonography / 2D Echo Cardiography / Doppler Report

Name: MR. NEERAJ SINGH /M/36 YRS

Date: 24-Feb-24

BOB HEALTH CHECK UP

### U.S.G. OF ABDOMEN & PELVIS

#### LIVER

Liver is normal in size shape with normal echo-texture. Intra hepatic biliary radicals are not dilated. No evidence of focal or diffuse lesion.

#### GALL BLADDER

Gall bladder is normal dilated. Lumen clear. Wall thickness normal. CBD normal

#### PANCREAS

Pancreas is normal in size, shape & echo-texture.

#### SPLEEN

Normal in size with normal shape & echo- texture.

#### BOTH KIDNEY

**Right kidney has 1.6 cm mid pole cyst.**

Left kidney appear normal shape, size.

PROSTATE is normal shape, size(16 gm) & echo texture..

URINARY BLADDER is normal shape, size & echo texture..

**Impression:- Right kidney mid pole cyst.**

Please correlate clinically. USG accuracy is 95 % due to technical limitations as well as inaccuracies inherent in the laboratory and statistical analysis biological process.

This report is not valid for medico-legal cases.

**Dr. Mukesh Gupta**  
SONOLOGIST  
Physician & Sonologist  
RM 5423/16262



"भ्रूण लिंग परीक्षण की शिकायत  
104 टोल फ्री सेवा पर भी की  
जा सकती है"

भ्रूण लिंग परीक्षण की शिकायत 104 टोल फ्री सेवा पर भी की जा सकती है।



# दक्ष हॉस्पिटल

396, गाँधी नगर स्कीम नं.8, अलवर (राज०) ☎ 0144-2703340

## Sonography / 2D Echo Cardiography / Doppler Report

### 2D/ ECHO REPORT

Name: - MR. NEERAJ SINGH

Age: - 36 Yrs

Date: - 24-Feb-24

Reg. No.:- Alw/2009/04

BOB health checkup

PROCEDURES:

M-MODE/2D/DOPPLER/COLOR/CONTRAST B.A.S. M<sup>2</sup>

MEASUREMENT:		NORMAL		DOPPLER:		NORMAL (cm/sec.)	
AOD	25	(20- 37mm)		MV	0.6	(0.8- 1.3)	MR No
LA	25	(19- 40mm)		AV	1.4	(1.2- 1.8)	AR No
AVO	18	(12- 25mm)		TV	0.6	(0.3- 0.8)	TR No
RVDD.	12	(03- 09mm)		PV	0.8	(0.7- 1.1)	PR No
LVDd	44.6	(37- 56mm)		MITRAL VALVE-			
LVDs	27.8	(22- 40mm)				AML	Normal
IVS d	5	(06- 12mm)				PML	Normal
IVS s	13.6			AORTIC VALVE			
PWd	2.6	(05- 10mm)					Normal
LV FUNCTION				TV & PV are normal.			
M- E- S Separation		<0.9cm					
Minor		24.42%					
LV Ejection Fraction	68%	65 +/- 12%					

MITRAL A>E

LV WALL MOTION: NO RWMA

ALL CARDIAC CHAMBERS ARE NORMAL

ALL VALVES ARE NORMAL

NO CLOT, VEGETATION, PERICARDIAL EFFUSION

Adv: - Follow up/ review at higher center for confirmation

Note:- Please Correlate clinically. Due to technical limitations as well as inaccuracies inherent in the laboratory and statistical analysis of biological process. Diagnostic accuracy of ECHO is up to 95% only.  
Report is not valid for medico-legal purpose.

DR. MUKESH GUPTA

PHYSICIAN

Dr. Mukesh Kumar Gupta

Physician & Sonologist

RM 5423/16262



"भ्रूण लिंग परीक्षण की शिकायत

104 टोल फ्री सेवा पर भी की

जा सकती है"

भ्रूण लिंग परीक्षण की शिकायत 104 टोल फ्री सेवा पर भी की जा सकती है।

10-02-2024 08:03:04 PM  
ID: 5

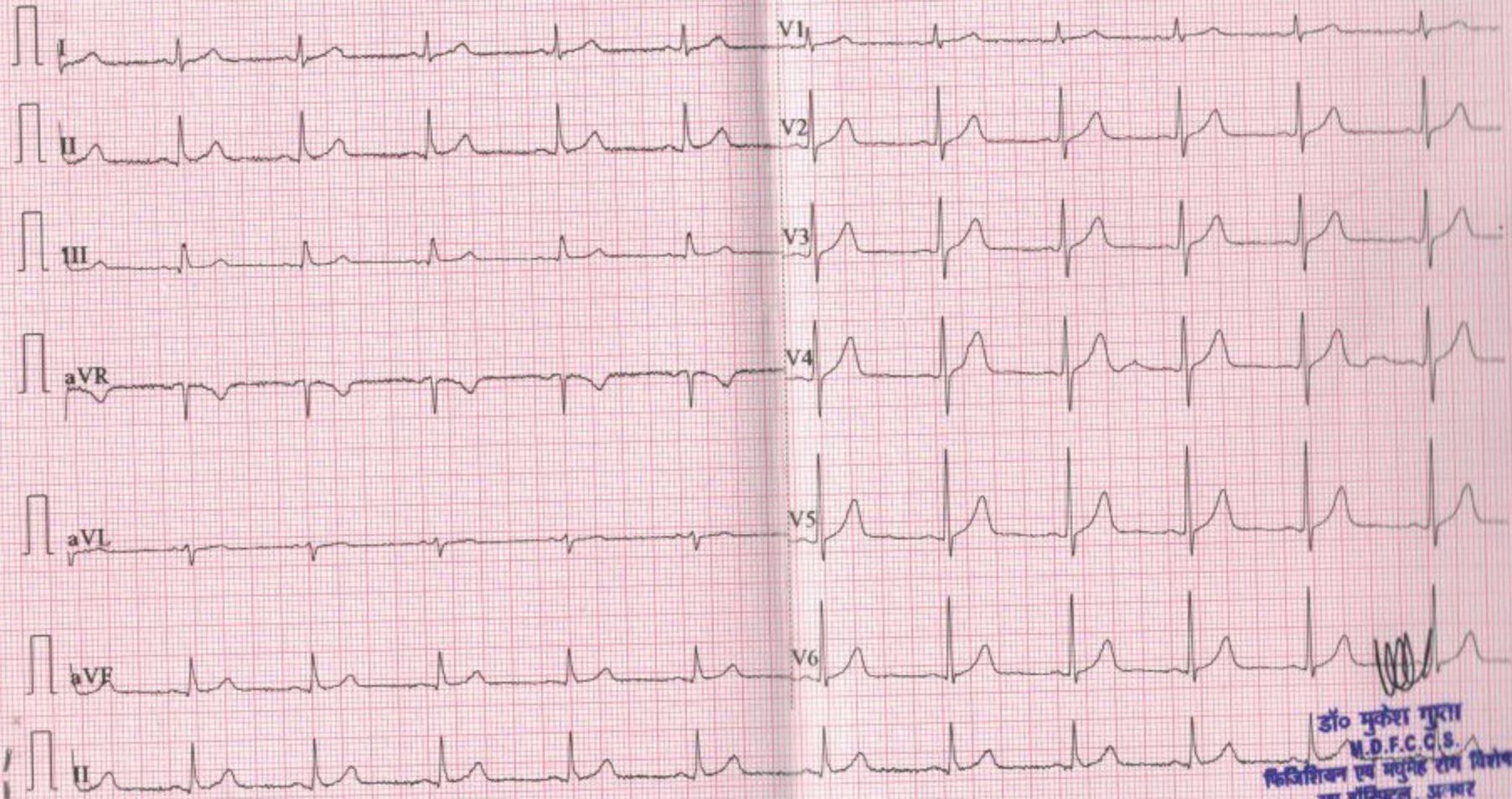
Female      Years

HR : 69 bpm  
P : 102 ms  
PR : 129 ms  
QRS : 84 ms  
QT/QTc : 362/389 ms  
P/QRS/T : 40/73/51 °  
RV5/SVI : 1.539/0.086 mV

BPL - 02

Diagnosis Information:  
Sinus Rhythm  
\*\*\*Normal ECG\*\*\*

Report Confirmed by:



डॉ० मुकेश गुप्ता  
M.D.F.C.C.S.  
किडिशिवन एव मुकुंद रोय विशाल  
दश हॉस्पिटल, अजमेर  
रजि० नं०-5423/16262

R

