

17

57

भारत सरकार  
Government of India

 Ram Chander Manjhi  
जन्म तिथि / DOB: 05/04/1966  
पुरुष / MALE  
Mobile No.: 9899812123



8726 1795 6793

मेरा आधार, मेरी पहचान

*Handwritten signature*

भारतीय विशिष्ट पहचान प्राधिकरण  
Unique Identification Authority of India

Address:  
C/O: Jitan Manjhi, H.NO-1103 11 TH  
FLOOR, AR REFLECTION, Raj  
Nagar Extension, Ghaziabad, Uttar  
Pradesh - 201017



8726 1795 6793

1947 help@uidai.gov.in www.uidai.gov.in

**MALIK RADIX HEALTH CARE PVT. LTD.**  
C-217, C-218, Nirman Vihar,  
Delhi-110092  
Ph.: 011-49287456, 011-61381379  
Regd. No. 607




## PHYSICAL EXAMINATION REPORT

NAME: Mr. Ravi  
Chander Manjhi AGE/GENDER: 57yrs/Male DATE 23/12/23

HEIGHT	167cm
WEIGHT	67kg
BMI	24.0
BLOOD PRESSURE	130/80 mmhg
OTHER	H/O-HTN from 10-15 yrs otherwise WNL

MALIK RADIX HEALTH CARE PVT. LTD.  
C-217, C-218, Nirman Vihar,  
Delhi-110092  
Ph.: 011-49287458, 011-61381379  
Regd. No. 607

  
Dr. SHEIKH NAZIR AHMED  
M.D. "Physician"  
PGDCC  
DMC-46499

### Facilities Available

- Multispeciality Hospital - 24 Hours Emergency - X-Ray/ ECG/ Ultrasound/ CT Scan - Dental - Fully Equipped Operation Theatre  
- Fully Functional Lab - 24/7 Casualty/ ICU-Nursery 24/7 Pharmacy - Labour Room - All Speciality OPD - Laproscopic Surgery -  
ECHO - Plastic Surgery



Mr. Ravi Chander Manjhi  
Age - 57 yr / Male

23/12/23

Refractive checkup

~~6/6~~  
~~6/9~~

Last seated  
by back

Near V. No  
No

Hyperve

Color V. WNL

DM - ve

Adm

9 HYPERMEL . . . . .

Dr. Nidhi Gupta  
MBBS, MS, DNB  
Casualty Ophthalmologist  
Malik Radix Healthcare Pvt. Ltd.  
DMC No. 121631

*(Signature)*  
Dr. Nidhi Gupta  
MBBS, MS, DNB  
Casualty Ophthalmologist

Facilities Available

- Multispecialty Hospital - 24 Hours Emergency - X-Ray/ ECG/ Ultrasound/ CT Scan - Dental - Fully Equipped Operation Theatre
- Fully Functional Lab - 24/7 Casualty/ ICU-Nursery 24/7 Pharmacy - Labour Room - All Speciality OPD - Laproscopic Surgery - ECHO - Plastic Surgery



**CONSULTANTS ON PANEL**

**PAEDIATRICS**

Dr. Ravi Malik (MBBS, MD)  
Dr. Anil Prasad (MBBS, MD) PNH  
Dr. Ravi Jain (MBBS, MD)

**Gynaecology**

Dr. Renu Malik (MBBS, MD)  
Dr. Meera Mahanta (MBBS, MD)  
Dr. Raju (MBBS, MD)  
Dr. Manu Gupta (MBBS, MD)  
Dr. Sushil Saxi (MBBS, DGO)  
Dr. Rajani Arora (MBBS, MD)

**DENTAL**

Dr. Shrut Malik (BDS, MDS)  
Dr. Annu Sam (BDS, MDS)  
Dr. Rishi Thakur (BDS, MDS)  
Dr. Mani Mangla (BDS, MDS)  
Dr. Jagan Mohan (BDS, MDS)  
Dr. Geetika Sharma (BDS)  
Dr. Shilpa Verma (BDS)

**CHILD GASTROENTEROLOGY**

Dr. I. K. Misra (MBBS, MD)

**MEDICINE**

Dr. A.S. Tewari (MBBS, MD)  
Dr. Sameer Uppal (MBBS, MD)  
Dr. Suresh Rajpal (MBBS, MD)

**RESPIRATORY MEDICINE/PULMONOLOGY**

Dr. Abhinav Shrivastava (MBBS, DNB)

**LAPAROSCOPIC SURGERY**

Dr. Ajay Jain (MBBS, MS)  
Dr. Deepak Sarin (MBBS, MS)  
Dr. Pradeep Saxi (MBBS, MS)  
Dr. I. S. Garg (MBBS, MS)

**ORTHOPAEDICS**

Dr. Vikas Bhatnagar (MBBS, MS, DOrtho, DNB)  
Dr. Prabhakar Aggarwal (MBBS, MS, DOrtho)  
Dr. K.R. Tiwari (MBBS, MS, DOrtho)  
Dr. Deepak Kumar Arora (MBBS, MS, DOrtho)

**EYE/OPTHALMOLOGY**

Dr. Nishi Gupta (MBBS, MS, DNB, FRCO) |  
Dr. Himanshu Singh-Pandey (MBBS, MS)

**ENT**

Dr. Shashi Kumar Singh (MBBS, MD)  
Dr. Pradeep Sharma (MBBS, MD)  
Dr. Anshu Singh (MBBS, MD)  
Dr. A.K. Labri (MBBS, MD)

**RADIOLOGY/ULTRASOUND**

Dr. K.K. Sarda (MBBS, DNB)  
Dr. T.K. Vohra (MBBS, MD)  
Dr. Rajesh Mahanta (MBBS, MD)  
Dr. Ashish Kumar (MBBS, MD)

**PATHOLOGY**

Dr. Neema Datta (MBBS, MD, PNH)  
Dr. Meenu Aggarwal (MBBS, MD, PNH)

**ANAESTHESIA**

Dr. Rajesh Dhill (MBBS, MD)  
Dr. Rakesh Arora (MBBS, MD)  
Dr. R.K. Arora (MBBS, MD)  
Dr. Geetika Garg (MBBS, MD)

**DERMATOLOGY**

Dr. Nitika Jha (MBBS, MD)

**PLASTIC & COSMETIC SURGERY**

Dr. Anshu Jain (MBBS, MS, MCh)

**PEDIATRIC SURGERY**

Dr. Dharmendra Singh (MBBS, MD, M.Ch)  
Dr. Satish Aggarwal (MBBS, MD, M.Ch)

**PEDIATRIC NEPHROLOGY**

Dr. A.S. Vasudevan (MD, Dip. in Paed.)

**NEPHROLOGY**

Dr. Javed (MBBS, MD, Nephro)

**CARDIOLOGY**

Dr. Nishant Tiwari (MBBS, MD)

**NEUROLOGY**

Dr. Anil Saxi (MBBS, MD)

**GASTROENTEROLOGY**

Dr. Deepak Lohar (MBBS, MD)  
Dr. Manish Aggarwal (MBBS, MD)

**UROLOGY**

Dr. Anurag Singh (MBBS, MD)

**PSYCHIATRY**

Dr. Mohit Sharma (MBBS, MD)

**PHYSIOTHERAPY**

Dr. Raj Kumar

**NUTRITIONIST**

Dr. Deepika Kati

Dr. Sakshi Bawa

**CLINICAL PSYCHOLOGIST**

Dr. Tanika Singh

## Dr. Shrut Malik

BDS, MDS (Endodontics)

(+91-9899561092)

Name : Ramchandra Naygi

Age/Sex : 57y / M

Date : 28/10/20

**Timings : 10:00 am. to 2:00 pm.  
6:00 pm. to 8:30 pm.**

**For Appointment**

011-45152510  
+91-9999254639

**CLINICAL EXAMINATION:-**

**1. TMJ:-**

Routine Checkup

**2. DENTAL STATUS:**

- a. Caries Teeth :
- b. Fracture Teeth :
- c. Root Stumps :
- d. Gingivitis :
- e. Periodontitis :
- f. Impacted Teeth :
- g. Malaligned Teeth :

o/e  
Calculus +  
Stains ++  
Missing 76 | 7

**3. ORAL LESIONS:-**

Mobile 2 | 56

**4. DIAGNOSIS:-**

R.S. | 7

**5. TREATMENT PLANNING:**

Gen. Periodontitis

**6. FOLLOW UP:-**

Referral To Other Consultant: Yes/ No Adm OPG

If Yes, please mention the Name: .....

Doctor's Signature Geetika

**Facilities Available :**

- \* MULTI-SPECIALITY HOSPITAL \* MODULAR FULLY EQUIPPED OT \* NURSERY \* LAPROSCOPIC SURGERY
- \* 24X7 EMERGENCY \* OPG \* DENTAL \* 24X7 DIAGNOSTICS \* LABOUR ROOM \* ECHO \* EEG \* DIGITAL X-RAY \* CT SCAN
- \* ECG \* ULTRASOUND \* RICU/ICU \* ALL SPECIALITY OPD \* PLASTIC & COSMETIC SURGERY \* DIALYSIS \* PHARMACY



Mr. Ram Chander Manjhi  
Age - 57yr/M

23/12/23

Bu em }  
nose } wall

Throat - compacted  
PPW

Dem  
→ fol & LA

long

Dr. Ashok Singh  
(ENT)

9871568301

DR. ASHOK SINGH  
MBBS, MS (ENT)  
Senior ENT & Head  
Neck Skull Base Surgeon  
Regn. No. DMC - 26962  
MALIK RADIX HEALTHCARE PVT. LTD.

Facilities Available

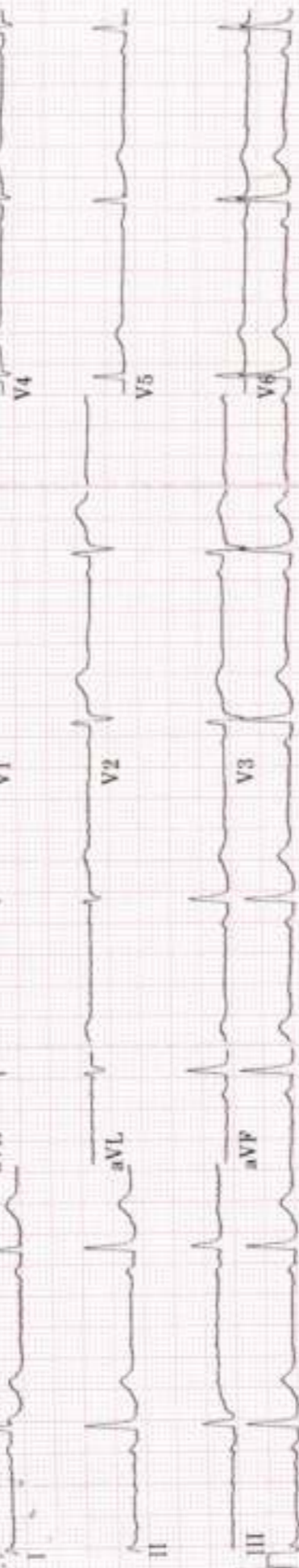
- Multispeciality Hospital - 24 Hours Emergency - X-Ray/ ECG/ Ultrasound/ CT Scan - Dental - Fully Equipped Operation Theatre
- Fully Functional Lab - 24/7 Casualty/ ICU-Nursery 24/7 Pharmacy - Labour Room - All Speciality OPD - Laproscopic Surgery - ECHO - Plastic Surgery

GE  
MAC600 1.02

ID: 9899812123

23-Dec-2023 11:26:20

ID: 9899812123



Auto gain applied  
25.0 mm/s  
0.16-20Hz

10.0||5.0 mm/mV

50Hz

53 bpm

4 by 2.5s + 1 rhythm ld

II

57years Male

Vent. rate 53 bpm  
QRS duration 80 ms  
QT/QTc 430/403 ms  
PR interval 148 ms  
P duration 66 ms  
RR interval 1132 ms  
P-R-T axes 46 60 36

MAC600 1.02

12SL™ v239

*Ramchander Manjhi*

# Malik Radix HealthCare.

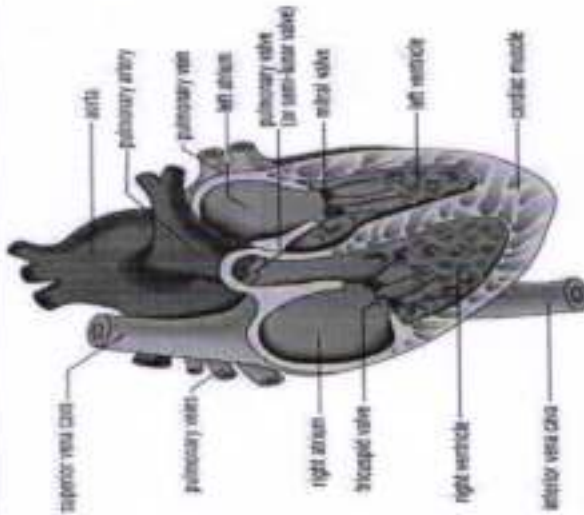
## ELECTROCARDIOGRAM

Name: MR. RAM CHANDER MANJHI

Age & Sex: 57YR/ MALE

Ref By: MEDIWHEEL

Date: 23/12/2023



### ECG FINDINGS:

Rate 53 bpm Rhythm Sinus Mechanism Normal

Axis Normal P Wave Normal PR Interval 0.14/Sec

QRS Complex Normal QT Interval Normal Q Wave Normal

ST Segment Normal T Wave Normal

Conclusion Sinus Bradycardia (HR- 53 bpm), Normal Axis, To be correlate.

Doctors Signature Dr. SHEIKH NAZIR AHMED  
M.D. - Physician  
PGDCC  
DMC-46498



**LAB REPORT**

Reg. Date	23/12/2023	Patient Id	2312230016	DOB.	
Name	MR. RAM CHANDER MANJHI	Gender	M	Perm. ID	
Age	57 Yrs.	Panel	MEDIWHEEL	Reported	23/12/2023 17:43:27
Ref. By	MEDIWHEEL				

Test Name	Result	Units	Ref. Range
<b>Full Body Plus Annual Check Advanced Mal</b>			
<b><u>HAEMATOLOGY</u></b>			
<b><u>COMPLETE HAEMOGRAM</u></b>			
HAEMOGLOBIN (HB%)	14.6	gm/dl	13 - 18
TOTAL LEUCOCYTE COUNT (TLC)	5,500	/cumm	4000 - 11000
<b><u>DIFFERENTIAL LEUCOCYTE COUNT (DLC)</u></b>			
NEUTROPHIL	52	%	40 - 80
LYMPHOCYTE	31	%	28 - 55
MONOCYTE	10	%	02 - 10
EOSINOPHIL	07	%	01 - 06
BASOPHIL	00	%	0 - 0
ESR (WESTEGREN'S METHOD)	10	mm/1st hr.	0 - 10
R B C COUNT	4.43	Millions/cmm	4.247 - 5.4
P.C.V / HAEMATOCRIT	45.8	%	40 - 54
M C V	103.4	f.	80 - 100
M C H	33.0	Picogram	27.0 - 31.0
M C H C	31.9	gm/dl	33 - 37
PLATELET COUNT	1.73	Lakh/cu mm	1.50 - 4.50
BLOOD GROUP ABO	" O "		
RH TYPING	Positive		
BLOOD SUGAR FASTING	98.02	mg/dl	70 - 100
BLOOD SUGAR PP	116.64	mg/dl	90 - 140
<b><u>THYROID PROFILE</u></b>			
Free T3 ELFA	3.72	ng/ml	02 - 04
Free T4 ELFA	1.06	ug/dl	0.8 - 2.7

Checked by : \_\_\_\_\_  
Page 1 Contd...2

If test results are alarming or unexpected, patient is advised to contact the laboratory immediately for possible remedial action.

**Facilities Available**

- Multispeciality Hospital - 24 Hours Emergency - X-Ray/ ECG/ Ultrasound/ CT Scan - Dental- Fully Equipped Operation Theatre  
- Fully Functional Lab - 24/7 Casualty/ ICU-Nursery 24/7 Pharmacy - Labour Room - All Speciality OPD - Laproscopic Surgery -  
ECHO - Plastic Surgery





**LAB REPORT**

Reg. Date	23/12/2023	Patient Id	2312230016	DOB.	
Name	MR. RAM CHANDER MANJHI	Gender	M	Perm. ID	
Age	57 Yrs.	Panel	MEDIWHEEL	Reported	23/12/2023 17:43:27
Ref. By	MEDIWHEEL				

Test Name	Result	Units	Ref. Range
TSH Serum/ELFA	2.090	uIU/ml	0.25 - 5.50 uIU/ml

**Interpretation**

**Clinical Use**

- Diagnose Hypothyroidism and Hyperthyroidism
- Monitor T4 replacement or T4 suppressive Therapy
- Quantify TSH levels in the subnormal range

Increased Levels : Primary Hypothyroidism Subclinical Hypothyroidism, TSH dependent, Thyroid Hormone Resistance.

Decreased Levels : Grave's Disease, Autonomous Thyroid Hormone Secretion, TSH Deficiency

**LIPID PROFILE**

TOTAL CHOLESTEROL	157.90	mg/dL	130.0 - 200.0 (<200)
TRIGLYCERIDES	116.20	mg/dL	80.5 - 150.0 (<150)
H D L CHOLESTEROL DIRECT	45.78	mg/dL	35.0 - 60.0 (<40->59)
V L D L	23.2	mg/dL	4.0 - 30. (23-45)
L D L CHOLESTEROL	88.9	mg/dL	50.0 - 150.0 (50-150)
TOTAL CHOLESTEROL / HDL RATIO	3.4		3.3 - 5.1
LDL / HDL CHOLESTEROL RATIO	1.9		1.5 - 3.5

**LIVER FUNCTION TEST (LFT)**

BILIRUBIN TOTAL	0.76	mg/dl	0.2 - 1.2
-----------------	------	-------	-----------

Checked by : \_\_\_\_\_  
 Page 2 Contd...3

If test results are alarming or unexpected, patient is advised to contact the laboratory immediately for possible remedial action.

**Facilities Available**

- Multispeciality Hospital - 24 Hours Emergency - X-Ray/ ECG/ Ultrasound/ CT Scan - Dental- Fully Equipped Operation Theatre  
 - Fully Functional Lab - 24/7 Casualty/ ICU-Nursery 24/7 Pharmacy - Labour Room - All Speciality OPD - Laproscopic Surgery -  
 ECHO - Plastic Surgery



**LAB REPORT**

Reg. Date	23/12/2023	Patient Id	2312230016	DOB.	
Name	MR. RAM CHANDER MANJHI	Gender	M	Perm. ID	
Age	57 Yrs.	Panel	MEDIWHEEL	Reported	23/12/2023 17:43:27
Ref. By	MEDIWHEEL				

Test Name	Result	Units	Ref. Range
CONJUGATED (D. BILIRUBIN)	0.26	mg/dl	0.00 - 0.3
UNCONJUGATED (I.D. BILIRUBIN)	0.50	mg/dl	0.2 - 0.9
SGOT / AST	39.70	IU/L	0 - 35
SGPT / ALT	28.1	IU/L	0 - 35
ALKALINE PHOSPHATASE	71.80	U/L	64 - 306
TOTAL PROTEIN	7.80	gm/dl	6.0 - 8.3
ALBUMIN	4.40	gm/dl	3.2 - 5.0
GLOBULIN	3.40	gm/dl	2.5 - 5.6
A/G RATIO	1.29		0.9 - 2.0
GAMMA GT	22.31	IU/L	0.0 - 45.0
SERUM CREATININE	1.10	mg/dl	0.7 - 1.4
SERUM URIC ACID	7.14	mg/dl	3.4 - 7.0
BLOOD UREA NITROGEN (BUN)	17.24	mg/dl	6.0 - 21.0
BUN/CREAT RATIO	15.6	mg/dl	
TOTAL PSA <small>Chemiluminescence</small>	1.02	ng/ml	

10 - 20

**INTERPRETATION :**

**Expected Values :**

99%	:	of Healthy males	0.0-4.0 ng/ml
80%	:	of Benign prostatic hypertrophy	0.0-4.0 ng/ml
81%	:	of Prostatic Carcinomas	Above 4.0 ng/ml

**PSA** is reliable tumour marker for already diagnosed prostatic carcinomas. It is uniquely associated only with prostatic tissue, and therefore is specific for it. Baseline levels measured prior to therapeutic intervention and followed later by serial periodical measurements will predict the outcome of therapy. It also helps in early discovery of recurrences, relapses and metastases.

Urine Routine Examination

Checked by : \_\_\_\_\_  
Page 3 Contd..4

If test results are alarming or unexpected, patient is advised to contact the laboratory immediately for possible remedial action.

**Facilities Available**

- Multispecialty Hospital - 24 Hours Emergency - X-Ray/ ECG/ Ultrasound/ CT Scan - Dental- Fully Equipped Operation Theatre
- Fully Functional Lab - 24/7 Casualty/ ICU-Nursery 24/7 Pharmacy - Labour Room - All Speciality OPD - Laproscopic Surgery - ECHO - Plastic Surgery



## LAB REPORT

Reg. Date	23/12/2023	Patient Id	2312230016	DOB.	
Name	MR. RAM CHANDER MANJHI	Gender	M	Perm. ID	
Age	57 Yrs.	Panel	MEDIWHEEL	Reported	23/12/2023 17:43:27
Ref. By	MEDIWHEEL				

Test Name	Result	Units	Ref. Range
<b>PHYSICAL EXAMINATION</b>			
QUANTITY	30	ml.	
COLOUR	Pale Yellow		Pale Yellow
TRANSPARENCY	Clear		
SPECIFIC GRAVITY	1.025		
PH	6.0		
<b>CHEMICAL EXAMINATION</b>			
ALBUMIN	Nil		
SUGAR	Nil		
<b>MICROSCOPIC EXAMINATION</b>			
RBC'S	Nil	/HPF	
CASTS	Nil		
CRYSTALS	NIL		
EPITHELIAL CELLS	1-2	/HPF	
BACTERIA	Nil		
OTHERS	Nil		

DR. REEMA DAHIYA

M.B.B.S, MD (Path)

Checked by

Page 4 of 4

Malik Radix Healthcare Pvt. Ltd.

DR. MEENU AGGARWAL  
M.B.B.S, MD (Path.)

If test results are alarming or unexpected, patient is advised to contact the laboratory immediately for possible remedial action.

## Facilities Available

- Multispeciality Hospital - 24 Hours Emergency - X-Ray/ ECG/ Ultrasound/ CT Scan - Dental- Fully Equipped Operation Theatre  
 - Fully Functional Lab - 24/7 Casualty/ ICU-Nursery 24/7 Pharmacy - Labour Room - All Speciality OPD - Laproscopic Surgery -  
 ECHO - Plastic Surgery



## Echocardiogram Report

<b>Patient Name</b>	<b>MR. RAM CHANDER MANJHI</b>
<b>Date of Test</b>	<b>23/12/2023</b>
<b>Age</b>	<b>57 YRS/ MALE</b>
<b>Ref. by</b>	<b>MEDIWHEEL</b>

<b>Dimensions</b>	<b>Result</b>	<b>Normal Range</b>
AO (ed)	3.1 cm	( 2.1 -3.7cm)
LA (es)	3.4 cm	(2.1 -3.7cm)
RVID (ed)	2.4 cm	(1.1-3.0cm)
LVID (ed)	5.2 cm	(3.6 – 5.5 cm)
LVID (es)	3.7 cm	(2.3-3.9cm)
IVS (ed)	1.2 cm	(0.6 – 1-2 cm)
LVPW (ed)	1.2 cm	(0.6 – 1-2 cm)
EF	56 %	
FS	29 %	(28 % - 42 %)

### Impression:

- NO REGIONAL WALL MOTION ABNORMALITY SEEN
- LVEF= 56 %
- MILD CONCENTRIC LV HYPERTROPHY.
- STAGE I LV DIASTOLIC DYSFUCTION.
- NORMAL COLOR FLOW.
- NO INTRA CARDIAC CLOT/MASS/ VEGETATION/PERICARDIAL EFFUSION SEEN.

Dr. Sheikh Nazie Ahmed  
M.D. "Physician" PGDCC  
(Consultant Non – Invasive Cardiologist)

### Facilities Available

- Multispeciality Hospital - 24 Hours Emergency - X-Ray/ ECG/ Ultrasound/ CT Scan - Dental - Fully Equipped Operation Theatre  
- Fully Functional Lab - 24/7 Casualty/ ICU-Nursery 24/7 Pharmacy - Labour Room - All Speciality OPD - Laproscopic Surgery -  
ECHO - Plastic Surgery



**LAB REPORT**

Reg. Date	23/12/2023	Patient Id	2312230016	DOB.	
Name	MR. RAM CHANDER MANJHI	Gender	M	Perm. ID	
Age	57 Yrs.	Panel	MEDIWHEEL	Reported	24/12/2023 12:01:09
Ref. By	MEDIWHEEL				

Test Name	Result	Units	Ref. Range
Full Body Plus Annual Check Advanced Mal			
HB A1C	5.7	%	

**Interpretation**

- Non Diabetic : 4-6%
- Good Diabetic Control : 6-8%
- Fair Control : 8-10%
- Poor Control : >10%

The Glycosylated haemoglobin assay has been validated as a reliable indicator Of mean blood glucose levels for a period of 8-12 week period. ADA recommended the testing twice a year in patients with stable blood glucose and quarterly. If treatment change, or if blood glucose levels are unstable.

**TO BE CORRELATED CLINICALLY.**

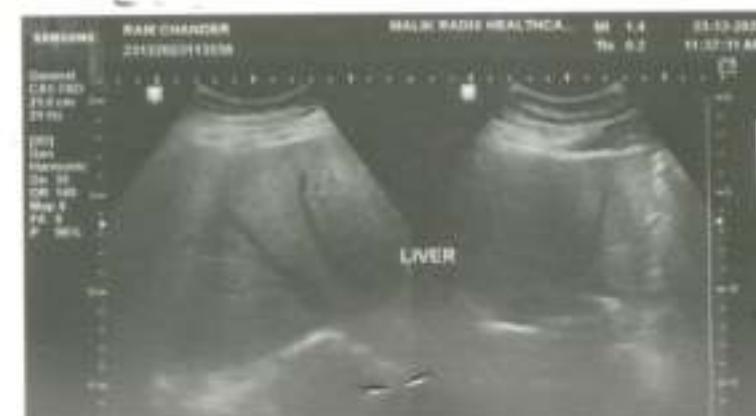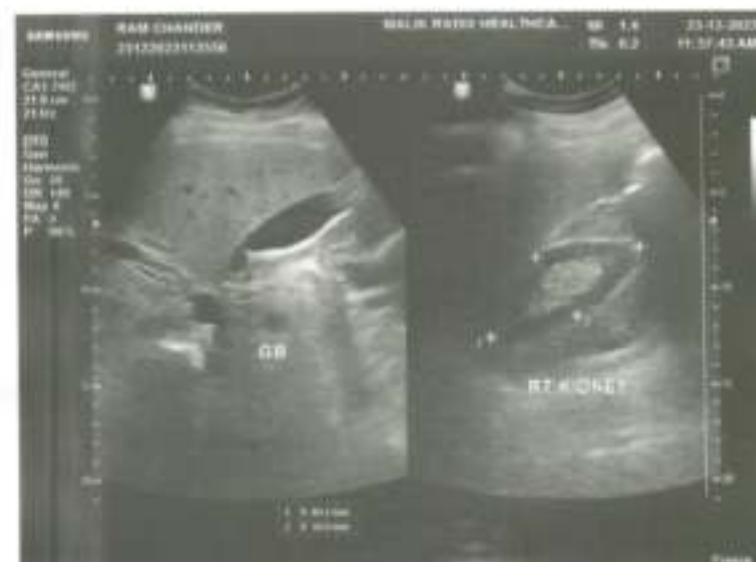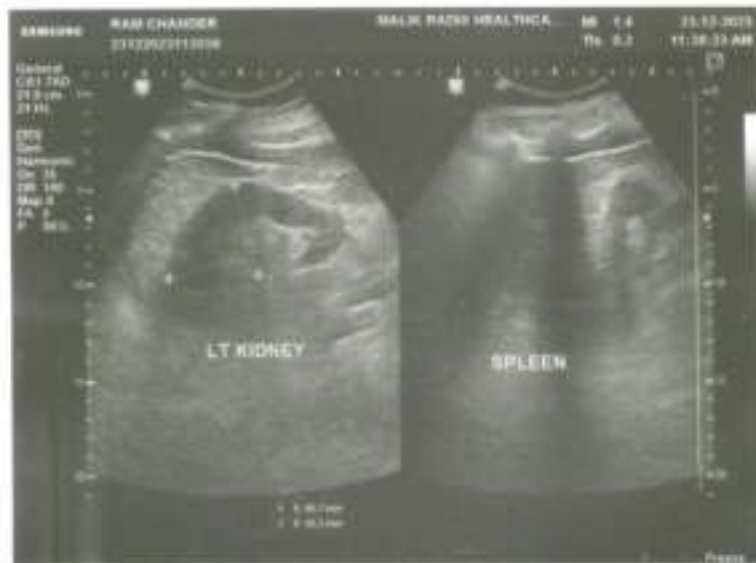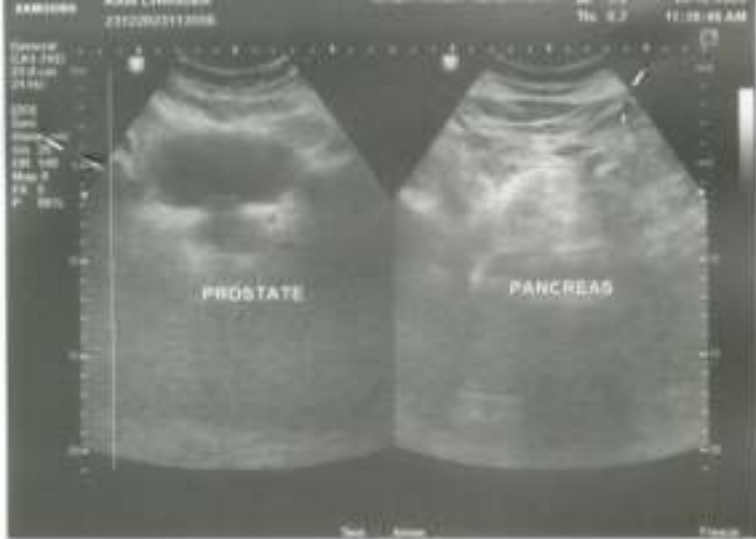*Dr. Rekha Dahiya*  
**DR. REKHA DAHIYA**  
 M.B.B.S, MD (Path.)  
 Checked by  
 Malik Radix Healthcare Pvt. Ltd.  
 Page 1 of 1

**DR. MEENU AGGARWAL**  
 M.B.B.S, MD (Path.)

If test result is alarming or unexpected, patient is advised to contact the laboratory immediately for possible remedial action.

**Facilities Available**

- Multispeciality Hospital - 24 Hours Emergency - X-Ray/ ECG/ Ultrasound/ CT Scan - Dental- Fully Equipped Operation Theatre
- Fully Functional Lab - 24/7 Casualty/ ICU-Nursery 24/7 Pharmacy - Labour Room - All Speciality OPD - Laproscopic Surgery - ECHO - Plastic Surgery





NAME	MR RAM CHANDER MANJHI	AGE	57 YRS/M
REFD. BY.	HELATH CHEK UP	DATE	23.12.23

**Ultrasound Examination of Whole Abdomen:**

**Liver:** Liver shows grade I fatty changes . No focal SOL. is seen in liver. IHBR & portal radicles are normal.

**Gallbladder:** Gallbladder shows normal anechoic pattern. No evidence of cholecystitis or cholelithiasis seen. Common bile duct is normal in course & caliber.

**Pancreas:** Pancreas shows normal size & echotexture.

**Spleen:** Spleen shows normal size, outline & echotexture.

**Kidneys:** Kidneys show normal size, shape, position & echotexture. No calculus, hydronephrosis or SOL. is seen in kidneys. Cortico- medullary differentiation and cortical thickness is normal on both sides.

No supra- renal mass seen.

Great abdominal vessels are normal.

Domes of diaphragm are seen to move normally & synchronously in respiration. No infra- or supradiaphragmatic collection seen.

No ascites or pericardial effusion seen.

No para aortic lymph nodes seen.

**Urinary bladder:** Urinary bladder shows normal anechoic pattern. No calculus, SOL or diverticulum seen.

**Prostate:** Prostate is normal in size & echotexture. Seminal vesicles are sonographically normal.

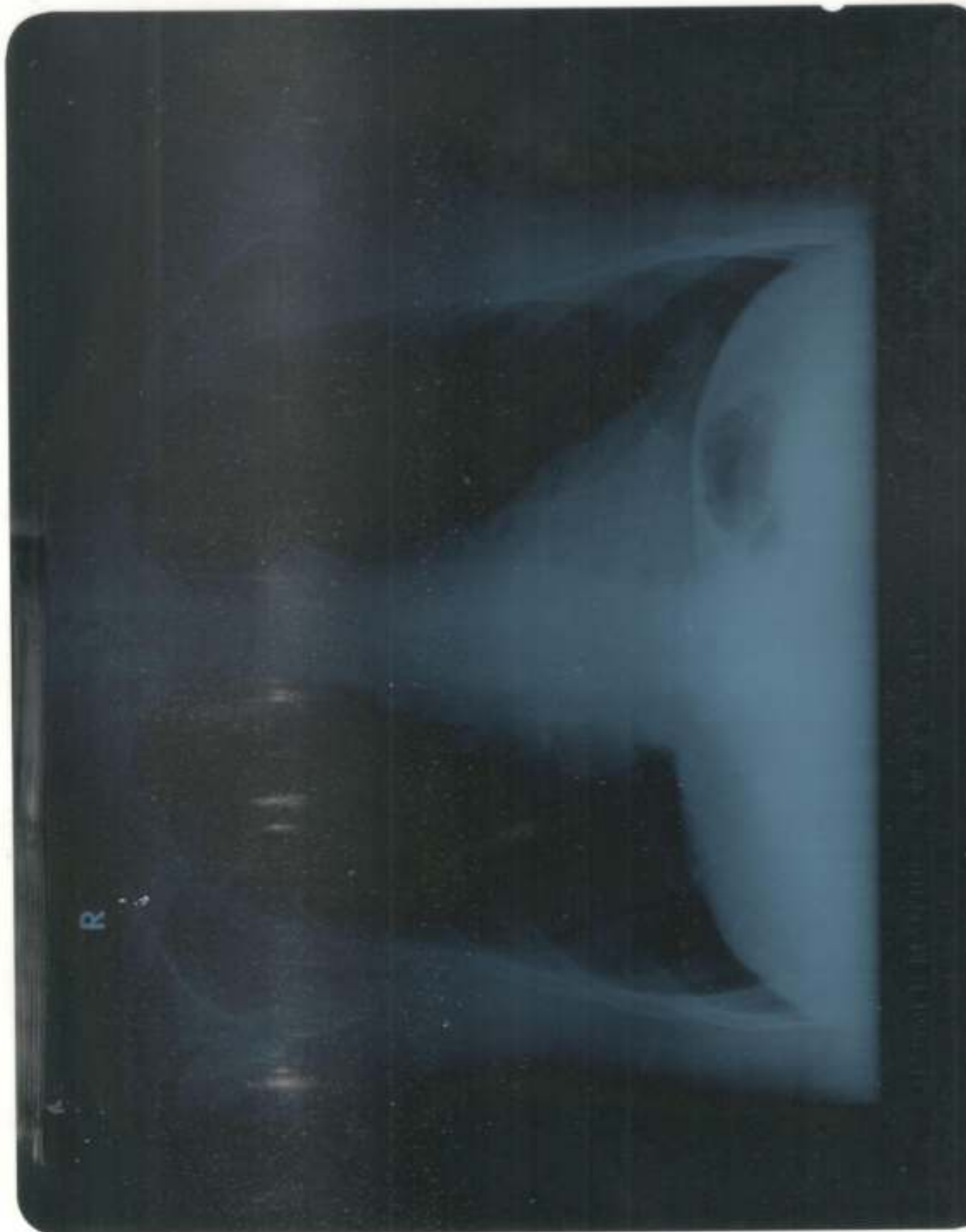Regards.

**Dr Mukesh Koshal MD ( Rad- diag)**  
Regn. No. DMC 10407

RADIOLOGIST :

Facilities Available

R







UHID	PT203447	LAB No.	XRY2308094
Name	Mr. RAM CHANDER MANJHI	Regn. No.	GEN2332839
Age / Sex	57 Yrs / M	Receiving Dt/Time	23-Dec-2023 10:51
		Reporting Dt/Time	23-Dec-2023 11:34 AM



## XRAY

CHEST (PA)

Both lung fields are normal.

Cp angles are clear.

Hila are normal...

Heart size appears within normal limits.

Soft tissue shadows and bony thorax are normal.

IMP- NORMAL CHEST X-RAY

Advised...please correlate clinically.

\*\*\*\*\* END OF REPORT \*\*\*\*\*

DR. K.K. SIMHA  
 M.B.B.S. D.M.R.D.  
 SENIOR CONSULTANT  
 Reg. No. 25457 (DMC)

DR. RAJESH MALHOTRA  
 MBBS, MD (RADIOLOGY)  
 CONSULTANT RADIOLOGY  
 Reg. No. DMC9299

DR. T. K. VOHRA  
 MD (RADIOLOGY)  
 SENIOR CONSULTANT  
 Reg. No. 3272 (DMC)

DR. MUKESH KOSHAL  
 MBBS, MD (RADIOLOGY)  
 CONSULTANT RADIOLOGY  
 Reg. No. DMC10407

DR. SHREYASH TIWARY  
 MBBS, MD (RADIOLOGY)  
 CONSULTANT RADIOLOGY  
 Reg. No. DMC85802

## Facilities Available