



LABORATORY REPORT



Name : **Mr GANESH KUMAR HELA** Sex/Age : **Male / 42 Years** Case ID : **4109300079**
 Ref. By : Self Reg Date : 16-Oct-2024 12:58 Pt. ID :
 Bill. Loc. : NDPL ARH Mob.No : 9883150795

Sample Date and Time : 16-Oct-2024 13:03 Sample Type : Whole Blood EDTA Ref Id1 :
 Report Date and Time : 16-Oct-2024 20:46 Ref Id2 :

TEST	RESULTS	UNIT	BIOLOGICAL REF RANGE	TEST REMARK
COMPLETE BLOOD COUNT				
Haemoglobin <i>Flowcytometry</i>	14.3	gm/dL	13 - 17	
RBC	4.79	millions/cumm	4.5 - 5.5	
PCV	45.5	Vol%	40.0 - 50.0	
MCV	95.0	fL	83 - 101	
MCH	29.9	pg	27 - 32	
MCHC	L 31.4	gm/dL	31.5 - 34.5	
RDW	14.1	%	11.6 - 14.6	
TOTAL AND DIFFERENTIAL WBC COUNT				
Total WBC Count	4900	/cumm	4000 to 10000	
Neutrophil	53	%	40 - 80	
Lymphocyte	40	%	20 - 40	
Eosinophil	02	%	1 - 6	
Monocytes	05	%	2 - 10	
Basophil	00	%	0 -	
Neutrophil	2597	/cumm	2000 - 7000	
Lymphocyte	1960	/cumm	1000 - 3000	
Eosinophil	98	/cumm	20 - 500	
Monocyte	245	/cumm	200 - 1000	
Basophil	0	/cumm	00 - 100	
Neut/Lympho Ratio (NLR)	1.32		0.78 - 3.53	
PLATELETS				
Platelet Count	165000	/cumm	1,50,000 - 4,10,000	
MPV	13.1	fL	7.50 - 12.0	
PDW	H 19.2		10.0 - 17.9	

Note:(LL-VeryLow,L-Low,H-High,HH-VeryHigh,A-Abnormal)

AUTO

Verified by



Supratik Biswas

DR Supratik Biswas
MBBS, MD
Consultant Biochemist
WBMC 64600



MC - 2167



LABORATORY REPORT



Name : Mr GANESH KUMAR HELA	Sex/Age : Male / 42 Years	Case ID : 4109300079
Ref. By : Self	Reg Date : 16-Oct-2024 12:58	Pt. ID :
Bill. Loc. : NDPL ARH		Mob.No : 9883150795
Sample Date and Time : 16-Oct-2024 13:03	Sample Type : Whole Blood EDTA	Ref Id1 :
Report Date and Time : 16-Oct-2024 20:46		Ref Id2 :

Note :

XN 1000, Sysmex

Method : FLOWCYTOMETRY

Note:(LL-VeryLow,L-Low,H-High,HH-VeryHigh,A-Abnormal)

AUTO

Verified by



Supratik Biswas

DR Supratik Biswas
MBBS, MD
Consultant Biochemist
WBMC 64600



MC - 2167



LABORATORY REPORT



Name : Mr GANESH KUMAR HELA	Sex/Age : Male / 42 Years	Case ID : 4109300079
Ref. By : Self	Reg Date : 16-Oct-2024 12:58	Pt. ID :
Bill. Loc. : NDPL ARH		Mob.No : 9883150795
Sample Date and Time : 16-Oct-2024 13:03	Sample Type : Whole Blood EDTA	Ref Id1 :
Report Date and Time : 16-Oct-2024 18:09		Ref Id2 :

TEST	RESULTS	UNIT	BIOLOGICAL REF RANGE	REMARKS
ESR	09	mm	0 - 10	

Method : Modified Westergren Method
Instrument - Automated Vescube - 30 touch

Note:(LL-VeryLow,L-Low,H-High,HH-VeryHigh,A-Abnormal)

Sudipta Halder

Verified by



Meenakshi

Dr Meenakshi Mohan
MD (Pathology)
Consultant Pathologist
WBMC 54631



MC - 2167

Page 3 of 20



LABORATORY REPORT



Name : Mr GANESH KUMAR HELA	Sex/Age : Male / 42 Years	Case ID : 4109300079
Ref. By : Self	Reg Date : 16-Oct-2024 12:58	Pt. ID :
Bill. Loc. : NDPL ARH		Mob.No : 9883150795
Sample Date and Time : 16-Oct-2024 13:03	Sample Type : Whole Blood EDTA	Ref Id1 :
Report Date and Time : 16-Oct-2024 20:46		Ref Id2 :

TEST	RESULTS	UNIT	BIOLOGICAL REF RANGE	REMARKS
Peripheral Smear Examination				
RBC Morphology	Normocytic Normochromic.			
WBC Morphology	Normal morphology.			
Platelet	Platelets are adequate.			

Note:(LL-VeryLow,L-Low,H-High,HH-VeryHigh,A-Abnormal)

Sudipta Halder

Verified by



Supratik Biswas

DR Supratik Biswas
MBBS, MD
Consultant Biochemist
WBMC 64600



MC - 2167



LABORATORY REPORT

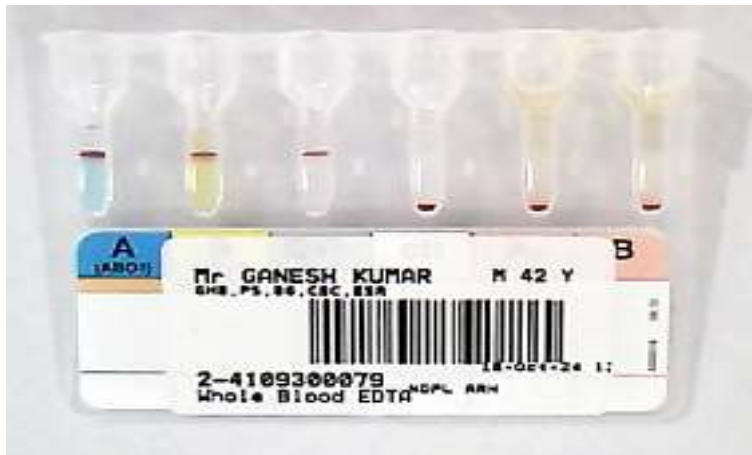

Name : Mr GANESH KUMAR HELA	Sex/Age : Male / 42 Years	Case ID : 4109300079
Ref. By : Self	Reg Date : 16-Oct-2024 12:58	Pt. ID :
Bill. Loc. : NDPL ARH		Mob.No : 9883150795
Sample Date and Time : 16-Oct-2024 13:03	Sample Type : Whole Blood EDTA	Ref Id1 :
Report Date and Time : 16-Oct-2024 20:46		Ref Id2 :

HAEMATOLOGY INVESTIGATIONS

Test	Result	Unit
BLOOD GROUP AND RH TYPING		
BLOOD GROUP	AB	
RH Type	POSITIVE	

Forward & Reverse Blood Groupin,
Gel Card By Bio-Rad



Note:(LL-VeryLow,L-Low,H-High,HH-VeryHigh,A-Abnormal)

Tamal Sarkar

Verified by



Supratik Biswas

DR Supratik Biswas
MBBS, MD
Consultant Biochemist
WBMC 64600



MC - 2167



LABORATORY REPORT



Name : **Mr GANESH KUMAR HELA** Sex/Age : **Male / 42 Years** Case ID : **4109300079**
 Ref. By : Self Reg Date : 16-Oct-2024 12:58 Pt. ID :
 Bill. Loc. : NDPL ARH Mob.No : 9883150795

Sample Date and Time : 16-Oct-2024 13:03	Sample Type : Plasma Fluoride F, Plasma Fluoride PP	Ref Id1 :
Report Date and Time : 16-Oct-2024 20:46		Ref Id2 :

TEST	RESULTS	UNIT	BIOLOGICAL REF RANGE	REMARKS
Plasma Glucose - F <i>Hexokinase</i>	105	mg/dL	70 - 99 : Non diabetic 100 - 125 : Pre diabetic >= 126 : Diabetic	
Plasma Glucose - PP <i>Hexokinase</i>	196	mg/dL	70 - 139 : Non diabetic 140 - 199 : Pre diabetic = / more than 200 : Diabetic	

Note:(LL-VeryLow,L-Low,H-High,HH-VeryHigh,A-Abnormal)

Pintu Manna

Verified by



Supratik Biswas

DR Supratik Biswas
MBBS, MD
Consultant Biochemist
WBMC 64600



MC - 2167



LABORATORY REPORT



Name : Mr GANESH KUMAR HELA	Sex/Age : Male / 42 Years	Case ID : 4109300079
Ref. By : Self	Reg Date : 16-Oct-2024 12:58	Pt. ID :
Bill. Loc. : NDPL ARH		Mob.No : 9883150795
Sample Date and Time : 16-Oct-2024 13:03	Sample Type : Whole Blood EDTA	Ref Id1 :
Report Date and Time : 16-Oct-2024 20:46		Ref Id2 :

TEST	RESULTS	UNIT	BIOLOGICAL REF RANGE	REMARKS
HbA1C <i>HPLC</i>	6.50	%	Normal : <5.7 Pre diabetes : 5.7-6.4 Diabetes : >6.5	
Average Plasma Glucose <i>Calculated</i>	140	mg/dL		

Interpretation :

HbA1C level reflects the mean glucose concentration over previous 8-12 weeks and provides better indication of long term glycemic control.
Levels of HbA1C may be low as result of shortened RBC life span in case of hemolytic anemia.
Increased HbA1C values may be found in patients with polycythemia or post splenectomy patients.
Patients with Homozygous forms of rare variant Hb(CC,SS,EE,SC) HbA1c can not be quantitated as there is no HbA.
In such circumstances glycemic control can be monitored using plasma glucose levels or serum Fructosamine.
The A1c target should be individualized based on numerous factors, such as age, life expectancy, comorbid conditions, duration of diabetes, risk of hypoglycemia or adverse consequences from hypoglycemia, patient motivation and adherence.

Note:(LL-VeryLow,L-Low,H-High,HH-VeryHigh,A-Abnormal)

Priya Manna

Verified by



Supratik Biswas

DR Supratik Biswas
MBBS, MD
Consultant Biochemist
WBMC 64600



MC - 2167

Page 7 of 20

Patient Data

Sample ID: 24109300079
 Patient ID: 24109300079
 Name: GANESH KUMAR HELA
 Physician:
 Sex: M
 DOB:

Analysis Data

Analysis Performed: 10/16/2024 18:08:07
 Injection Number: 1390
 Run Number: 51
 Rack ID: 0003
 Tube Number: 4
 Report Generated: 10/16/2024 18:12:52
 Operator ID:

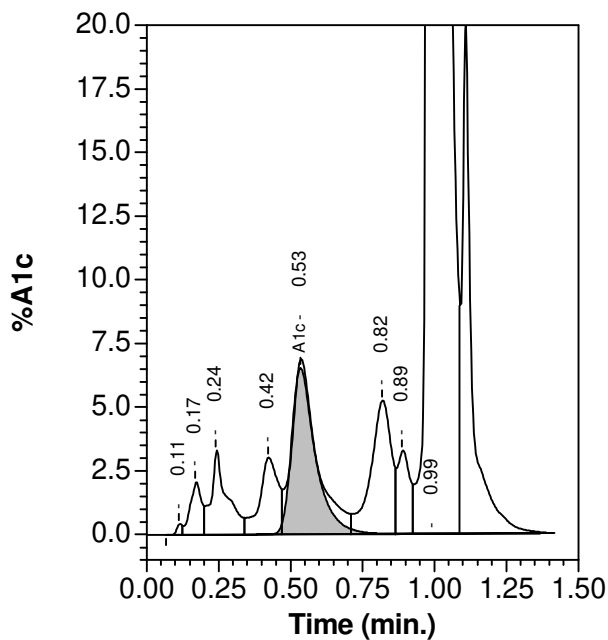
Comments:

Peak Name	NGSP %	Area %	Retention Time (min)	Peak Area
Unknown	---	0.1	0.111	2361
A1a	---	0.8	0.168	23431
A1b	---	1.8	0.240	52383
LA1c	---	1.8	0.423	51714
A1c	6.5*	---	0.535	155766
P3	---	3.6	0.816	105500
P4	---	1.4	0.887	40024
Ao	---	85.2	0.991	2484119

*Values outside of expected ranges

Total Area: 2,915,297

HbA1c (NGSP) = 6.5* %





LABORATORY REPORT



Name : Mr GANESH KUMAR HELA	Sex/Age : Male / 42 Years	Case ID : 4109300079
Ref. By : Self	Reg Date : 16-Oct-2024 12:58	Pt. ID :
Bill. Loc. : NDPL ARH		Mob.No : 9883150795
Sample Date and Time : 16-Oct-2024 13:03	Sample Type : Serum	Ref Id1 :
Report Date and Time : 16-Oct-2024 20:46		Ref Id2 :

TEST	RESULTS	UNIT	BIOLOGICAL REF RANGE	REMARKS
LIPID PROFILE				
Triglyceride <i>GPO-POD</i>	91	mg/dL	Normal: < 150 Borderline High: 150 -199 High: 200 - 499 Very High: >= 500	
Cholesterol <i>Colorimetric, CHOD-POD</i>	144	mg/dL	Desirable : < 200 Borderline High : 200 - 240 High Risk : > 240	
HDL Cholesterol <i>CHOD-POD</i>	45	mg/dL	Low HDL: < 40 High HDL : >= 60	
LDL Cholesterol (Direct) <i>CHOD-POD</i>	88	mg/dL	Optimal : <100 Above Optimal: 100 - 129 Borderline high : 130 - 159 High : 160 - 189 Very High : >190	
VLDL <i>Calculated</i>	11	mg/dL	10 - 40	
Non-HDL Cholesterol <i>Calculated</i>	99	mg/dL	<130	
Chol/HDL <i>Calculated</i>	3.20		1 - 5.2	
LDL/HDL Ratio	1.96			

***National Cholesterol Education Programme Adult Treatment Panel III Guidelines(US).**

Note:(LL-VeryLow,L-Low,H-High,HH-VeryHigh,A-Abnormal)

Pintu Manna

Verified by



Supratik Biswas

DR Supratik Biswas
MBBS, MD
Consultant Biochemist
WBMC 64600



MC - 2167



LABORATORY REPORT



Name : Mr GANESH KUMAR HELA	Sex/Age : Male / 42 Years	Case ID : 4109300079
Ref. By : Self	Reg Date : 16-Oct-2024 12:58	Pt. ID :
Bill. Loc. : NDPL ARH		Mob.No : 9883150795
Sample Date and Time : 16-Oct-2024 13:03	Sample Type : Serum	Ref Id1 :
Report Date and Time : 16-Oct-2024 20:46		Ref Id2 :

TEST	RESULTS	UNIT	BIOLOGICAL REF RANGE	REMARKS
------	---------	------	----------------------	---------

BIOCHEMICAL INVESTIGATIONS

Liver Function Test

Bilirubin Total <i>DPD</i>	0.48	mg/dL	0.3-1.2	
Bilirubin Conjugated <i>DPD</i>	H 0.21	mg/dL	0.0 - 0.2	
Bilirubin Unconjugated <i>Calculated</i>	0.27	mg/dL	0 - 0.8	
S.G.P.T. <i>IFCC</i>	29	U/L	0-50	
S.G.O.T. <i>IFCC</i>	26	U/L	0-50	
Alkaline Phosphatase <i>IFCC</i>	89	U/L	30-120	
Proteins (Total) <i>Biuret</i>	7.16	g/dL	6.6-8.3	
Albumin <i>Bromo Cresol Green</i>	4.46	g/dL	3.5-5.2	
Globulin <i>Calculated</i>	2.70	g/dL	1.80 - 3.60	
A/G Ratio <i>Calculated</i>	1.65		1.2 - 2.0	
Gamma Glutamyl Transferase <i>IFCC</i>	13	U/L	0-55	

Note:(LL-VeryLow,L-Low,H-High,HH-VeryHigh,A-Abnormal)

Pintu Manna

Verified by



Supratik Biswas

DR Supratik Biswas

MBBS, MD

Consultant Biochemist

WBMC 64600



MC - 2167

Page 10 of 20



LABORATORY REPORT



Name : Mr GANESH KUMAR HELA	Sex/Age : Male / 42 Years	Case ID : 4109300079
Ref. By : Self	Reg Date : 16-Oct-2024 12:58	Pt. ID :
Bill. Loc. : NDPL ARH		Mob.No : 9883150795
Sample Date and Time : 16-Oct-2024 13:03	Sample Type : Serum	Ref Id1 :
Report Date and Time : 16-Oct-2024 20:46		Ref Id2 :

TEST	RESULTS	UNIT	BIOLOGICAL REF RANGE	REMARKS
Thyroid Function Test				
Triiodothyronine (T3) <i>ECLIA</i>	1.15	ng/mL	0.58 - 1.59	
Thyroxine (T4) <i>ECLIA</i>	8.49	µg/dL	4.87 - 11.72	
TSH <i>ECLIA</i>	2.13	µIU/mL	0.27-4.20	

INTERPRETATIONS

- Circulating TSH measurement has been used for screening for euthyroidism, screening and diagnosis for hyperthyroidism & hypothyroidism. Suppressed TSH (<0.01 µIU/mL) suggests a diagnosis of hyperthyroidism and elevated concentration (>7 µIU/mL) suggest hypothyroidism. TSH levels may be affected by acute illness and several medications including dopamine and glucocorticoids. Decreased (low or undetectable) in Graves disease. Increased in TSH secreting pituitary adenoma (secondary hyperthyroidism), PRTN and in hypothalamic disease thyrotropin (tertiary hyperthyroidism). Elevated in hypothyroidism (along with decreased T4) except for pituitary & hypothalamic disease.
- Mild to modest elevations in patient with normal T3 & T4 levels indicates impaired thyroid hormone reserves & incipient hypothyroidism (subclinical hypothyroidism).
- Mild to modest decrease with normal T3 & T4 indicates subclinical hyperthyroidism.
- Degree of TSH suppression does not reflect the severity of hyperthyroidism, therefore, measurement of free thyroid hormone levels is required in patient with a suppressed TSH level.

Note:(LL-VeryLow,L-Low,H-High,HH-VeryHigh,A-Abnormal)

Pintu Manna

Verified by



Supratik Biswas

DR Supratik Biswas

MBBS, MD

Consultant Biochemist

WBMC 64600



MC - 2167

Page 11 of 20



LABORATORY REPORT



Name : Mr GANESH KUMAR HELA	Sex/Age : Male / 42 Years	Case ID : 4109300079
Ref. By : Self	Reg Date : 16-Oct-2024 12:58	Pt. ID :
Bill. Loc. : NDPL ARH		Mob.No : 9883150795
Sample Date and Time : 16-Oct-2024 13:03	Sample Type : Serum	Ref Id1 :
Report Date and Time : 16-Oct-2024 20:46		Ref Id2 :

TEST	RESULTS	UNIT	BIOLOGICAL REF RANGE	REMARKS
Prostate Specific Antigen (PSA)				
Prostate Specific Antigen <i>ECLIA</i>	0.86	ng/mL	0-2.0	

Use

The total PSA test and digital rectal exam (DRE) are used together to help determine the need for the prostate biopsy. The goal of screening is to minimize unnecessary biopsies and to detect clinically significant prostate cancer while it is still confined to the prostate. Clinical Significance of elevated levels of PSA are associated with prostate cancer, but they may also be seen with prostatitis and benign prostatic hyperplasia (BPH). Mild to moderately increased concentrations of PSA may be seen in those of African American heritage, and levels tend to increase in all men as they age. Prostate biopsy is required for the diagnosis of cancer.

Note:(LL-VeryLow,L-Low,H-High,HH-VeryHigh,A-Abnormal)

Pintu Manna

Verified by



Supratik Biswas

DR Supratik Biswas
MBBS, MD
Consultant Biochemist
WBMC 64600



MC - 2167



LABORATORY REPORT



Name : Mr GANESH KUMAR HELA	Sex/Age : Male / 42 Years	Case ID : 4109300079
Ref. By : Self	Reg Date : 16-Oct-2024 12:58	Pt. ID :
Bill. Loc. : NDPL ARH		Mob.No : 9883150795
Sample Date and Time : 16-Oct-2024 13:03	Sample Type : Urine F,Urine PP	Ref Id1 :
Report Date and Time : 16-Oct-2024 20:46		Ref Id2 :

TEST	RESULTS	UNIT	BIOLOGICAL REF RANGE	REMARKS
Urine Glucose (Fasting)	Absent		Absent	
Urine Glucose (Post Prandial)	Present (+++)		Absent	

Note:(LL-VeryLow,L-Low,H-High,HH-VeryHigh,A-Abnormal)

Kalol Sarkar

Verified by



Supratik Biswas

DR Supratik Biswas

MBBS, MD

Consultant Biochemist

WBMC 64600



RADIOLOGY REPORT



Name :	Mr GANESH KUMAR HELA	Patient ID :	4109300079
Gender / Age :	Male / 42 Years	Registration Date & Time :	16-Oct-2024 12:58
Ref Id :		Receiving Date & Time :	16-Oct-2024 15:20
B2b Name :	NDPL ARH	Report Date & Time :	28-Oct-2024 13:20
Ref By :	Self		

TMT (Tread Mill Test)

INDICATION	Evaluation of functional status.
SYMPTOMS	Asymptomatic
MEDICATIONS	Nil
RISK FACTOR	Age, Male Gender.
PROTOCOL USED	Bruce
STAGE REACHED	III
MAXIMUM WORK LOAD	8.5 METs.
EXERCISE TIME	7 min. 01 sec.
HR ACHIEVED	178/157 (88%)
REASON FOR TERMINATION	Target heart rate achieved
BLOOD PRESSURE RESPONSE	Normal
ST DEPRESSION	ST depression noted in inferior,lateral leads.
ARRHYTHMIA	Nil

Conclusion :

- Stress test is **POSITIVE** for the electrocardiographic evidence of provokable myocardial ischaemia.
- Fair exercise tolerance.

Abhinav



RADIOLOGY REPORT



Name :	Mr GANESH KUMAR HELA	Patient ID :	4109300079
Gender / Age :	Male / 42 Years	Registration Date & Time :	16-Oct-2024 12:58
Ref Id :		Receiving Date & Time :	16-Oct-2024 15:20
B2b Name :	NDPL ARH	Report Date & Time :	28-Oct-2024 13:20
Ref By :	Self		

Tanusree Sukla
Verified BY

Dr.Abhinay Tibdewal
MD, DM (Cardiologist)
WBMC 85811



LABORATORY REPORT



Name : Mr GANESH KUMAR HELA	Sex/Age : Male / 42 Years	Case ID : 4109300079
Ref. By : Self	Reg Date : 16-Oct-2024 12:58	Pt. ID :
Bill. Loc. : NDPL ARH		Mob.No : 9883150795
Sample Date and Time : 16-Oct-2024 13:03	Sample Type : Serum	Ref Id1 :
Report Date and Time : 16-Oct-2024 20:46		Ref Id2 :

TEST	RESULTS	UNIT	BIOLOGICAL REF RANGE	TEST REMARK
------	---------	------	----------------------	-------------

Kidney Function Test

Urea <i>GLDH</i>	26	mg/dL	17 - 43	
Creatinine <i>Jaffe - Kinetic</i>	0.75	mg/dL	<1.2	
Uric Acid <i>Uricase</i>	5.42	mg/dL	3.4 - 7.0	
BUN <i>GLDH</i>	12.1	mg/dL	8.90 - 20.60	
Calcium <i>BAPTA</i>	L 8.54	mg/dL	8.6-10	
Sodium <i>ISE, Indirect</i>	141	mmol/L	136.0 - 145.0	
Potassium <i>Ion Selective Electrode</i>	3.70	mmol/L	3.5 - 5.1	
Chloride <i>ISE, Indirect</i>	106	mmol/L	97 - 111	

Note:(LL-VeryLow,L-Low,H-High,HH-VeryHigh,A-Abnormal)

Pintu Manna

Verified by



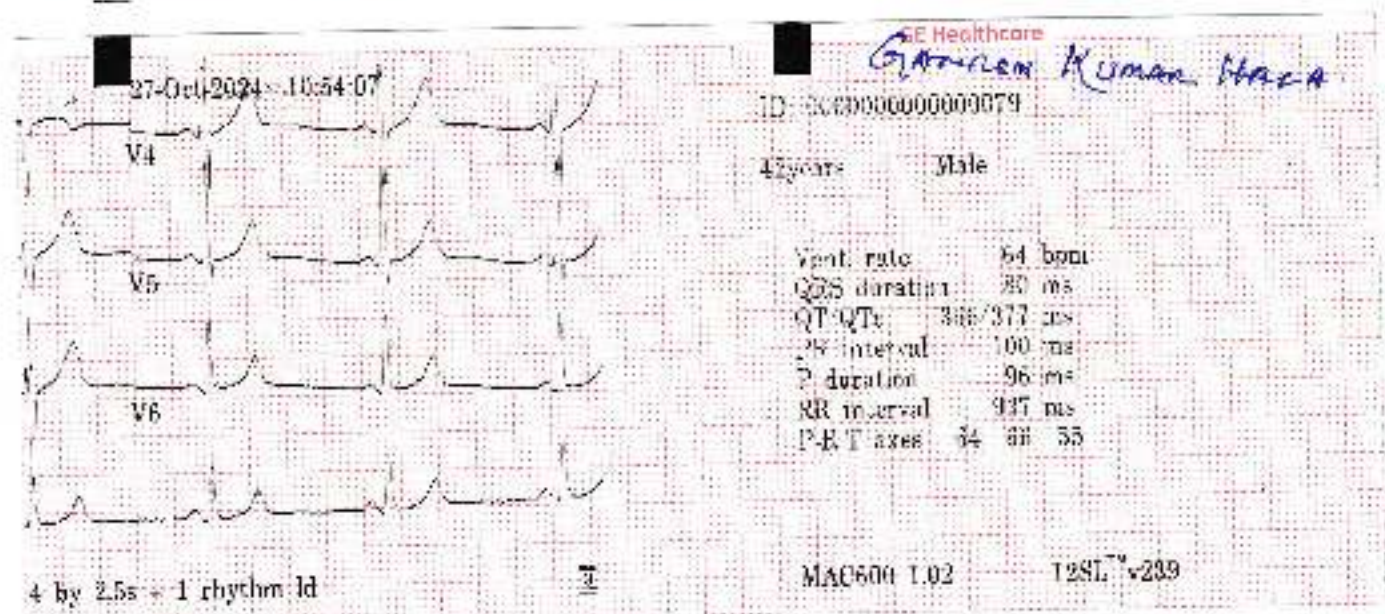
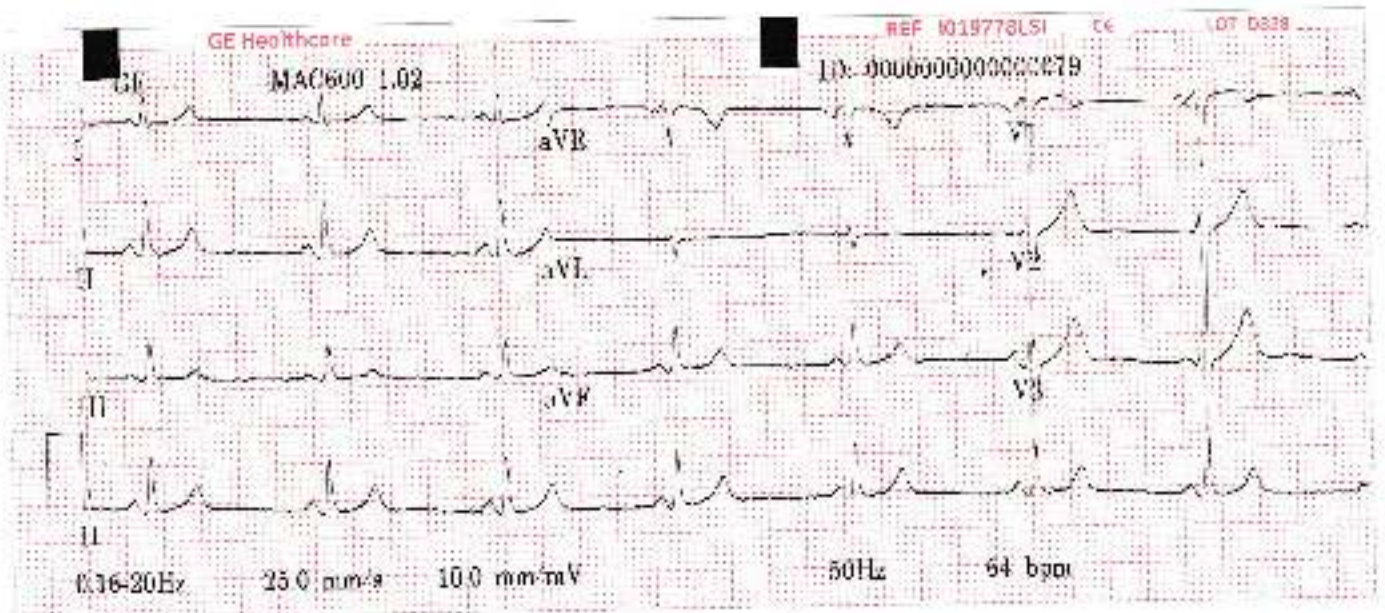
Supratik Biswas

DR Supratik Biswas

MBBS, MD

Consultant Biochemist

WBMC 64600



REF I019778LSI CE LOT D828

- Sinus rhythm with short PR
- Otherwise normal ECG

Dr. Abhiraj
20/10/24

Dr. Abhiraj Tibdewal
Consultant Cardiologist
MBBS, MD, DM (Cardio)

MAC600 1.02 12SL™ v239



RADIOLOGY REPORT



Name :	Mr GANESH KUMAR HELA	Patient ID :	4109300079
Gender / Age :	Male / 42 Years	Registration Date & Time :	16-Oct-2024 12:58
Ref Id :		Receiving Date & Time :	07-Nov-2024 10:08
B2b Name :	NDPL ARH	Report Date & Time :	07-Nov-2024 15:36
Ref By :	Self		

ULTRASONOGRAPHY OF WHOLE ABDOMEN

LIVER:

Is enlarged (151 mm) in size, normal in shape, position & outline with increased parenchymal echogenicity. Hepatic venous portal systems are normal. Intrahepatic biliary radicles are not dilated. Portal vein measures 10 mm in diameter.

GALL BLADDER :

Is normal in size, contour and wall thickness. A few calculi, largest one 10 mm noted in lumen of gall bladder.

CBD :

Common bile duct is not dilated and measures 4 mm in diameter.

PANCREAS :

Is normal in size, shape, and echopattern. Pancreatic duct is not dilated. No focal parenchymal lesion is seen.

SPLEEN :

Is normal in size, shape, position and echogenicity. No focal parenchymal lesion is seen. Spleen measures 96 mm. in long axis.

KIDNEYS :

Are normal in size, shape, position and outline showing normal cortico-medullary differentiation. No focal parenchymal lesion is seen. No hydronephrosis, calculi or any renal mass is seen.

Right kidney measures 98 mm in length.

Left kidney measures 93 mm in length.

URETERS:

Either ureter is not dilated.

URINARY BLADDER:

Is well distended with normal contour and wall thickness. No intraluminal lesion is seen.

Post-void residual urine volume 11 cc.

PROSTATE:

Is borderline enlarged in size, normal in shape, outline and echogenicity. No other sizeable lesion is seen in the prostatic gland. Prostate measures 47 mm x 38 mm x 28 mm. Prostatic weight is 26 grams.

PERITONEUM :

There is no free fluid in peritoneal cavity.



RADIOLOGY REPORT



Name :	Mr GANESH KUMAR HELA	Patient ID :	4109300079
Gender / Age :	Male / 42 Years	Registration Date & Time :	16-Oct-2024 12:58
Ref Id :		Receiving Date & Time :	07-Nov-2024 10:08
B2b Name :	NDPL ARH	Report Date & Time :	07-Nov-2024 15:36
Ref By :	Self		

RETROPERITONEUM :

There is no lymphadenopathy and no obvious retroperitoneal mass is seen. Retroperitoneal fat planes are normal.

LOWER PLEURAL SPACE:

There is no pleural effusion.

IMPRESSION:

- **Hepatomegaly with Grade - I fatty liver.**
- **Cholelithiasis.**
- **Borderline prostatomegaly.**

----- End Of Report -----

Devpriya Pradhan

Priyanka Chatterjee
Verified BY

Dr.Devpriya Pradhan
MD Radiodiagnosis
WBMC 81171



Patient Name :	GANESH KR. HELA	Patient ID :	0079
Modality :	DX	Sex :	M
Age :	042Y	Study :	CHEST PA
Reff. Dr. :	SELF	Study Date :	16-10-2024

X-RAY CHEST PA VIEW

Bilateral lung fields appear normal.
Bilateral costophrenic angles are unremarkable.
Bilateral hila and vascular markings are unremarkable.
Domes of diaphragm are normal in morphology and contour.
Cardiac size is within normal limits.
Bony thoracic cage appears normal.

IMPRESSION.

No significant abnormality detected.
No evidence of fracture or dislocation.

'Recommended clinical correlation with other investigation.'



Dr. Manish Kumar Jha
MBBS, MD (Radio-diagnosis)
Registration No. 77237 (WBMC)