



Pathology Department



Patient's name : SHAILEE SUNILBHAI PATEL
 Age/Sex : 32 Years/Female
 Referred by : MEDI WHEEL
 Collection Time : 09:31

Reg. ID : P-6507-23
 Accession : 23581
 Order Dt/time : 08/03/2024 09:31

Complete Blood Count

Sample Type: EDTA

Test Name	Result	Units	Biological Reference Interval
<u>Blood Counts</u>			
Haemoglobin :	12.3	Gms%	12.5 - 16.0
Total R.B.C. :	4.63	mill/c.mm	4.2 - 5.4
Total W. B. C. :	8230	/cu mm	4000 - 10500
Platelet Count :	309000	/cu.mm	1,50,000 - 4,50,000
<u>Differential Count</u>			
Neutrophils :	67	%	40 - 70
Lymphocytes :	28	%	20 - 40
Eosinophils :	03	%	1 - 4
Monocytes :	02	%	2 - 6
Basophils :	00	%	0 - 01
<u>Blood Indices</u>			
P. C. V :	37.5	%	37 - 47
M. C. V. :	81.0	fl	78 - 100
M.C.H :	26.5	pg	27 - 31
M. C. H. C :	32.7	%	32 - 36
R.D.W :	13.6	%	11.5 - 14.0

E.S.R.(Westergren Method)

After one hour : 10 mm/hr 3 - 12

TESTS DONE ON FULLY AUTOMATED HEMATOLOGY ANALYZER.

Dr. Gayatri M. Mehta
 M. D. (Patho)

DR. GAYATRI MEHTA
 MD(PATHOLOGY)

DR. ANAND D. PARIKH
 MD(PATHOLOGY)

LAB USE ONLY (Entered by :GM Enter Date/Time:08/03/2024 17:21:00) (Verify by :GM Verify Date/Time:08/03/2024 17:21:00)



Vidhi Diagnostics | Pathology Department

L-86, Swatantra Senari Nagar, Opp. Akharnagar Petrol Pump, Nr. Akharnagar Circle, Nava-Vadaj, Ahmedabad - 380 013.

M. - Pathology : 8849893954, Ph. : 079-27621406, M. 98799 29406, 98250 09406, E-mail : vidhidiagnostics@gmail.com, Web. : www.vidhidiagnostics.com

Time (Pathology) : Mon. to Sat. 8.30 am to 8.00 pm, Sunday 9 am to 12 Noon

Pathology means science behind medicine

CT SCAN & CBCT FACILITY NOW AVAILABLE



Pathology Department



Patient's name : SHAILEE SUNILBHAI PATEL
Age/Sex : 32 Years/Female
Referred by : MEDI WHEEL
Collection Time : 09:31

Reg. ID : P-6507-23
Accession : 23581
Order Dt/time : 08/03/2024 09:31

Blood Group

Sample Type: EDTA sample.

Test Name	Result
BG :	" O "
RH :	POSITIVE
Remarks	Done by forward grouping method.

Blood Glucose

Sample Type: Serum

Test Name	Result	Units	Biological Reference Interval
Fasting Blood Glucose :	95.8	mg/dl	70 - 110
Urine Sugar :	NIL		Absent
<i>GOD-POD Method.</i>			

Blood Glucose

Sample Type: Serum

Test Name	Result	Units	Biological Reference Interval
Post Prandial Blood Glucose After 2hr. :	98.6	mg/dl	80 - 140
Urine Sugar :	NIL		Absent
<i>GOD-POD Method.</i>			

Dr. Gayatri M. Mehta

M. D. (Patho)

Reg. No. G-32215

DR. GAYATRI MEHTA
MD(PATHOLOGY)

DR. ANAND D. PARIKH
MD(PATHOLOGY)

LAB USE ONLY (Entered by :GM Enter Date/Time:08/03/2024 17:22:00) (Verify by :GM Verify Date/Time:08/03/2024 17:22:00)



Vidhi Diagnostics | Pathology Department

L-86, Swatantra Senani Nagar, Opp. Akhbarnagar Petrol Pump, Nr. Akhbarnagar Circle, Nava-Vadaj, Ahmedabad - 380 013.

M. - Pathology : 8849893954, Ph. : 079-27621406, M. 98799 29406, 98250 09406, E-mail : vidhidiagnostics@gmail.com, Web. : www.vidhidiagnostics.com

Time (Pathology) : Mon. to Sat. 8.30 am to 8.00 pm, Sunday 9 am to 12 Noon

Pathology means science behind medicine

CT SCAN & CBCT FACILITY NOW AVAILABLE



Pathology Department



Patient's name : SHAILEE SUNILBHAI PATEL
Age/Sex : 32 Years/Female
Referred by : MEDI WHEEL
Collection Time : 09:31

Reg. ID : P-6507-23
Accession : 23581
Order Dt/time : 08/03/2024 09:31

Lipid Profile

Sample Type: Serum

Test Name	Result	Units	Biological Reference Interval
S. Cholesterol : Oxidase-esterase method.	143	mg/dl	0 - 200
S. Triglyceride : Enzymatic Colorimetry method	59.2	mg/dL	0 - 200
S. HDL - Cholesterol : Serum by Enzymatic method.	46.7	mg/dL	35 - 65
S. LDL - Cholesterol : Serum by Enzymatic method	84.46	mg/dL	0 - 130
S. VLDL - Cholesterol :	11.84	mg/dL	0 - 30
S. Chole/HDL.Ratio :	3.06		1 - 6
S. LDL / HDL Cholesterol Ratio :	1.81		0 - 3.5

Dr. Gayatri M. Mehta
M. D. (Pathology)
Reg. No. G-32215
DR GAYATRI MEHTA
MD(PATHOLOGY)

DR. ANAND D. PARIKH
MD(PATHOLOGY)

LAB USE ONLY (Entered by :GM Enter Date/Time:08/03/2024 17:22:00) (Verify by :GM Verify Date/Time:08/03/2024 17:22:00)



Vidhi Diagnostics | Pathology Department

L-86, Swatantra Senani Nagar, Opp. Akhbarnagar Petrol Pump, Nr. Akhbarnagar Circle, Nava-Vadaj, Ahmedabad - 380 013.

M. - Pathology : 8849893954, Ph. : 079-27621406, M. 98799 29406, 98250 09406, E-mail : vidhidiagnostics@gmail.com, Web. : www.vidhidiagnostics.com

Time (Pathology) : Mon. to Sat. 8.30 am to 8.00 pm, Sunday 9 am to 12 Noon

Pathology means science behind medicine

CT SCAN & CBCT FACILITY NOW AVAILABLE



Pathology Department



Patient's name : SHAILEE SUNILBHAI PATEL
Age/Sex : 32 Years/Female
Referred by : MEDI WHEEL
Collection Time : 09:31

Reg. ID : P-6507-23
Accession : 23581
Order Dt/time : 08/03/2024 09:31

HbA1C

Sample Type: EDTA

Test Name	Result	Units	Biological Reference Interval
HbA1C :	5.0	%	Non-diabetic: 4.2-6.2 Pre-diabetic : 6.3-7.2 Diabetic : 7.3-8.2
Mean Blood Glucose of Last 03 months.	97	mg/dl	

Comment *As per the new 2009 update of American Diabetes Association regarding HbA1C & Mean Blood Glucose relationship.
NOTE: This test is used to monitor diabetic patients compliance with the therapeutic regimen and logo It's level is proportional to both the average blood glucose concentration and the life span of the red blood cells (RBC) in circulation. HbA1c values are free of day to day glucose fluctuations and are unaffected by exercise or recent food intake.

Dr. Gayatri M. Mehta
M. D. (Patho)

DR. GAYATRI M. MEHTA G-32215
MD(PATHOLOGY)

DR. ANAND D. PARIKH
MD(PATHOLOGY)

LAB USE ONLY (Entered by :GM Enter Date/Time 08/03/2024 17:21:00) (Verify by :GM Verify Date/Time 08/03/2024 17:21:00)



Vidhi Diagnostics | Pathology Department

L-86, Swatantra Senani Nagar, Opp. Akhbarnagar Petrol Pump, Nr. Akhbarnagar Circle, Nava-Vadaj, Ahmedabad - 380 013.

M. - Pathology : 8849893954, Ph. : 079-27621406, M. 98799 29406, 98250 09406, E-mail : vidhidiagnostics@gmail.com, Web. : www.vidhidiagnostics.com

Time (Pathology) : Mon. to Sat. 8.30 am to 8.00 pm, Sunday 9 am to 12 Noon

Pathology means science behind medicine

CT SCAN & CBCT FACILITY NOW AVAILABLE



Pathology Department



Patient's name : SHAILEE SUNILBHAI PATEL
Age/Sex : 32 Years/Female
Referred by : MEDI WHEEL
Collection Time : 09:31

Reg. ID : P-6507-23
Accession : 23581
Order Dt/time : 08/03/2024 09:31

BIOCHEMISTRY

Sample type :Serum

Table with 4 columns: Test Name, Result, Units, Biological Reference Interval. Rows include Urea, S.Uric acid, Bun, Creatinine, S.G.P.T (ALT), S.G.O.T (AST), ALK.PHOSPHATASE, G.G.T, BILIRUBIN (Total, Direct, Indirect), and SERUM PROTEINS (Total Protein, Albumin, Globulins, A/G Ratio).

Dr. Gayatri M. Mehta

M. D. (Pathology)

Reg. No. G-32215

DR GAYATRI MEHTA
MD(PATHOLOGY)

DR. ANAND D. PARIKH
MD(PATHOLOGY)

LAB USE ONLY (Entered by :GM Enter Date/Time:08/03/2024 17:21:00) (Verify by :GM Verify Date/Time:08/03/2024 17:21:00)



Vidhi Diagnostics | Pathology Department

L-86, Swatantra Senani Nagar, Opp. Akhbarnagar Petrol Pump, Nr. Akhbarnagar Circle, Nava-Vadaj, Ahmedabad - 380 013.

M. - Pathology : 8849893954, Ph. : 079-27621406, M. 98799 29406, 98250 09406, E-mail : vidhidiagnostics@gmail.com, Web. : www.vidhidiagnostics.com

Time (Pathology) : Mon. to Sat. 8.30 am to 8.00 pm, Sunday 9 am to 12 Noon

Pathology means science behind medicine

CT SCAN & CBCT FACILITY NOW AVAILABLE



Pathology Department



Patient's name : SHAILEE SUNILBHAI PATEL
Age/Sex : 32 Years/Female
Referred by : MEDI WHEEL
Collection Time : 09:31

Reg. ID : P-6507-23
Accession : 23581
Order Dt/time : 08/03/2024 09:31

Thyroid Function Test

Sample Type: Serum

Test Name	Result	Units	Biological Reference Interval
TOTAL T3 :	1.44	ng/ml	1.07 - 1.86
TOTAL T4 :	7.33	µg/dL	6.09 - 12.23
TSH(Ultra sensitive) :	0.92	µIU/mL	0.4001 - 4.049

Dr. Gayatri M. Mehta

M. D. (Pathology)

Reg No. 32215
DR. GAYATRI MEHTA
MD(PATHOLOGY)

DR. ANAND D. PARIKH
MD(PATHOLOGY)

LAB USE ONLY (Entered by :GM Enter Date/Time 08/03/2024 17:23:00) (Verify by :GM Verify Date/Time 08/03/2024 17:23:00)



Vidhi Diagnostics | Pathology Department

L-86, Swatantra Senani Nagar, Opp. Akhbaragar Petrol Pump, Nr. Akhbaragar Circle, Nava-Vadaj, Ahmedabad - 380 013.

M. - Pathology : 8849893954, Ph. : 079-27621406, M. 98799 29406, 98250 09406, E-mail : vidhidiagnostics@gmail.com, Web. : www.vidhidiagnostics.com

Time (Pathology) : Mon. to Sat. 8.30 am to 8.00 pm, Sunday 9 am to 12 Noon

Pathology means science behind medicine

CT SCAN & CBCT FACILITY NOW AVAILABLE



Pathology Department



Patient's name : SHAILEE SUNILBHAI PATEL
Age/Sex : 32 Years/Female
Referred by : MEDI WHEEL
Collection Time : 09:31

Reg. ID : P-6507-23
Accession : 23581
Order Dt/time : 08/03/2024 09:31

Urine Analysis

Sample Type: Urine

Test Name	Result	Units	Biological Reference Interval
<u>Physical Examination</u>			
Quantity :	20	ml	0 - 500 ml
Colour :	Pale Yellow		Pale Yellow
Transparency :	Slight Turbid.		Clear
Reaction :	Acidic		4.6 - 8.0
Specific Gravity :	1.010		1.016 - 1.022
Sediment :	Present		
<u>Chemical Examination</u>			
Albumin :	Present (Faint Trace)		Absent
Sugar :	NIL		Absent
Acetone :	Absent		Absent
Bile Salts :	Absent		Absent
Bile Pigments :	Absent		Absent
Urobilogen :	Absent		Absent
Nitrites :	Absent		Absent
<u>Microscopic Examination</u>			
Red blood Cells :	2-3	/h.p.f	Absent
Pus Cells :	2-3	/h.p.f	Absent
Epithelial Cells :	1-2	/h.p.f	< 10.0
Amorphous :	Absent	/h.p.f	Absent
Bacteria :	Absent	/h.p.f	Absent
Crystals :	Absent	/h.p.f	Absent
Casts :	Absent	/h.p.f	Absent
Fungus :	Not seen	/h.p.f	Absent

Dr. Gayatri M. Mehta
M. D. (Patho)

Reg. No. G-32215

DR GAYATRI MEHTA
MD(PATHOLOGY)

DR. ANAND D. PARIKH
MD(PATHOLOGY)



Printed by : GM (Entered by :GM Enter Date/Time:08/03/2024 17:24:00) (Verify by :GM Verify Date/Time:08/03/2024 17:24:00)

Vidhi Diagnostics | Pathology Department

L-86, Swatantra Senani Nagar, Opp. Akhbaragar Petrol Pump, Nr. Akhbaragar Circle, Nava-Vadaj, Ahmedabad - 380 013.

M. - Pathology : 8849893954, Ph. : 079-27621406, M. 98799 29406, 98250 09406, E-mail : vidhidiagnostics@gmail.com, Web : www.vidhidiagnostics.com

Time (Pathology) : Mon. to Sat. 8.30 am to 8.00 pm, Sunday 9 am to 12 Noon

Pathology means science behind medicine

CT SCAN & CBCT FACILITY NOW AVAILABLE

Dr. Dinesh S. Modh

M.D., D.M.R.E. (Radiodiagnosis)

Consultant Radiologist & Sonologist

Ex. Junior Lecturer, B.J. Medical College, Civil Hospital, A'bad.



Shailee Sumilbhai Patel.

08/03/2024

I don't want to go for
stool sample.

ISO 9001:2015 Certified Diagnostics Center

Vidhi Imaging Center

L-86, Swatantra Senani Nagar, Opp. Indian Oil Petrol Pump, Akharnagar Circle, Nava Vada, Ahmedabad - 380 013.

Phone : (Radiology) 079-2762 1406 | M. 98799 29406, 98250 09406 | Time (Radiology) : Mon. to Sat. 9 am to 2 pm, 5 to 9 pm, Sunday 9 am to 12 Noon

E-mail : vidhidiagnostics@gmail.com, Website : www.vidhidiagnostics.com

Multislice CT Scan | CBCT-Dental Scan | Live 3D-4D Sonography | Colour Doppler | Echo Cardiography | Interventional Radiology | Maxillofacial Radiology | Fetal Medicine
Digital X-Ray | Digital Mammography | Digital OPG/TMJ | ECG/TMT/PFT/EEG/EMG | Audiometry | Pathology Laboratory | Health Check Up Plans | Pre Employment Check Up

CT SCAN & CBCT FACILITY NOW AVAILABLE

Health Check up Booking Request(bobE12340), Beneficiary Code-111036

1 message

Mediwheel <wellness@mediwheel.in>

29 February 2024 at 18:03

To: vidhidiagnostics@gmail.com

Cc: customercare@mediwheel.in



Mediwheel
...Your wellness partner

011-41195959

Dear VIDHI DIAGNOSTICS

We have received a booking request with the following details. Provide your confirmation by clicking on the Yes button.

You confirm this booking? Yes No

Name : MS. PATEL SHAILEE SUNIL BHAI

Hospital Package Name : Mediwheel Full Body Health Checkup Female Below 40

Name of Diagnostic/Hospital : VIDHI DIAGNOSTICS

Address of Diagnostic/Hospital- : L-86 Swatantra - Senani Nagar , Opp- Akhbarnagar Bus Terminals, New Wadaj , Ahmedabad -13

Appointment Date : 08-03-2024

Member Information		
Booked Member Name	Age	Gender
MS. PATEL SHAILEE SUNIL BHAI	32 year	Female

Tests included in this Package -

- Pap Smear
- Stool Test
- Gynae Consultation
- Thyroid Profile
- ESR
- Blood Glucose (Fasting)
- General Physician Consultation
- TMT OR 2D ECHO
- Blood Group
- Blood Glucose (Post Prandial)
- Chest X-ray
- ECG
- USG Whole Abdomen
- Eye Check-up consultation
- Urine Sugar Fasting
- Urine Sugar PP
- Dental Consultation
- Urine analysis

- CBC
- HbA1c
- Lipid Profile
- Kidney Profile
- Liver profile

Thanks,
Mediwheel Team

Please Download Mediwheel App



You have received this mail because your e-mail ID is registered with **Arcofemi Healthcare Limited** This is a system-generated e-mail please don't reply to this message.

Please visit to our [Terms & Conditions](#) for more informaion. [Click here](#) to unsubscribe.

© 2024 - 25, Arcofemi Healthcare Pvt Limited.(Mediwheel)


ભારત સરકાર
GOVERNMENT OF INDIA


 શ્રી સર્વજીત રાવ
 Employee Service Card
 જન્મ તારીખ / Year of Birth : 1991
 સેલ / Female


2364 5780 2911

સર્કાર - સમીક્ષા મંત્રાલય સર્કાર

(x) S. S. Patel

Vidhi Diagnostics
 1-28, Swasthtra-Senani Nagar,
 Opp. Akhbarnagar Bus Terminala,
 Nr. Akhbarnagar Circle,
 New Wadaj, Ahmedabad-13.

Sheilika



Vidhi Diagnostics
L-68, Swasthtra Samani Nagar,
Opp. Ambarnagar Bus Terminal,
Nr. Jakhnagar Circle,
New Wadoj, Ahmedabad-13.

Dr. Dinesh S. Modh

M.D., D.M.R.E. (Radiodiagnosis)
Consultant Radiologist & Sonologist
Ex. Junior Lecturer, B.J. Medical College, Civil Hospital, A'bad.



08/03/2024

Shaillee Sumilbhai Patel
32 yr Female

Height! - 150cm

Weight! - 66kg

BP! - 118/76mmHg

Pulse! - 88 per min

SpO2! - 98

T! - (N)

RS 2 (N)
CVS 4 (N)

Asymptomatic

No H/O DM, HIV, Tubercid or TB

Adv! - She is medically fit

★ Eye check-up! -

- Color vision! - Normal
- Distance! - 6/6 with specs.
- Near! - N/G.

★ Dental! -

- Oral Hygiene normal
- No H/O Caries & Cavities is seen.

Vidhi Diagnostics
I-85, Swatantra Senani Nagar,
Opp. Akhbarnagar Bus Terminal,
Nr. Akhbarnagar Circle,
New Wadaj, Ahmedabad-13.

Dr. Vidhi D. Modh
MBBS
Reg. No.: G-74540

ISO 9001:2015 Certified Diagnostics Center

Vidhi Imaging Center

L-86, Swatantra Senani Nagar, Opp. Indian Oil Petrol Pump, Akhbarnagar Circle, Nava Vada, Ahmedabad - 380 013.

Phone : (Radiology) 079-2762 1406 | M. 98799 29406, 98250 09406 | Time (Radiology) : Mon. to Sat. 9 am to 2 pm, 5 to 9 pm, Sunday 9 am to 12 Noon

E-mail : vidhidiagnostics@gmail.com, Website : www.vidhidiagnostics.com

Multislice CT Scan | CBCT-Dental Scan | Live 3D-4D Sonography | Colour Doppler | Echo Cardiography | Interventional Radiology | Maxillofacial Radiology | Fetal Medicine
Digital X-Ray | Digital Mammography | Digital DPG/TMJ | ECG/TMT/PFT/EEG/EMG | Audiometry | Pathology Laboratory | Health Check Up Plans | Pre Employment Check Up

CT SCAN & CBCT FACILITY NOW AVAILABLE

HR : 89 bpm
 PR : 136 ms
 QRS : 84 ms
 QT/QTc : 338/410 ms
 P/QRS/T : 54/68/22 deg.
 RV5/SV1 : 1.335/-0.683 mv
 RV5+SV1 : 2.018 mv

Need to be confirmed by doctor. Doctor Name:

ID: 12902

Name: shalika patel

Age: 32yr

Sex: Female

Hospital:

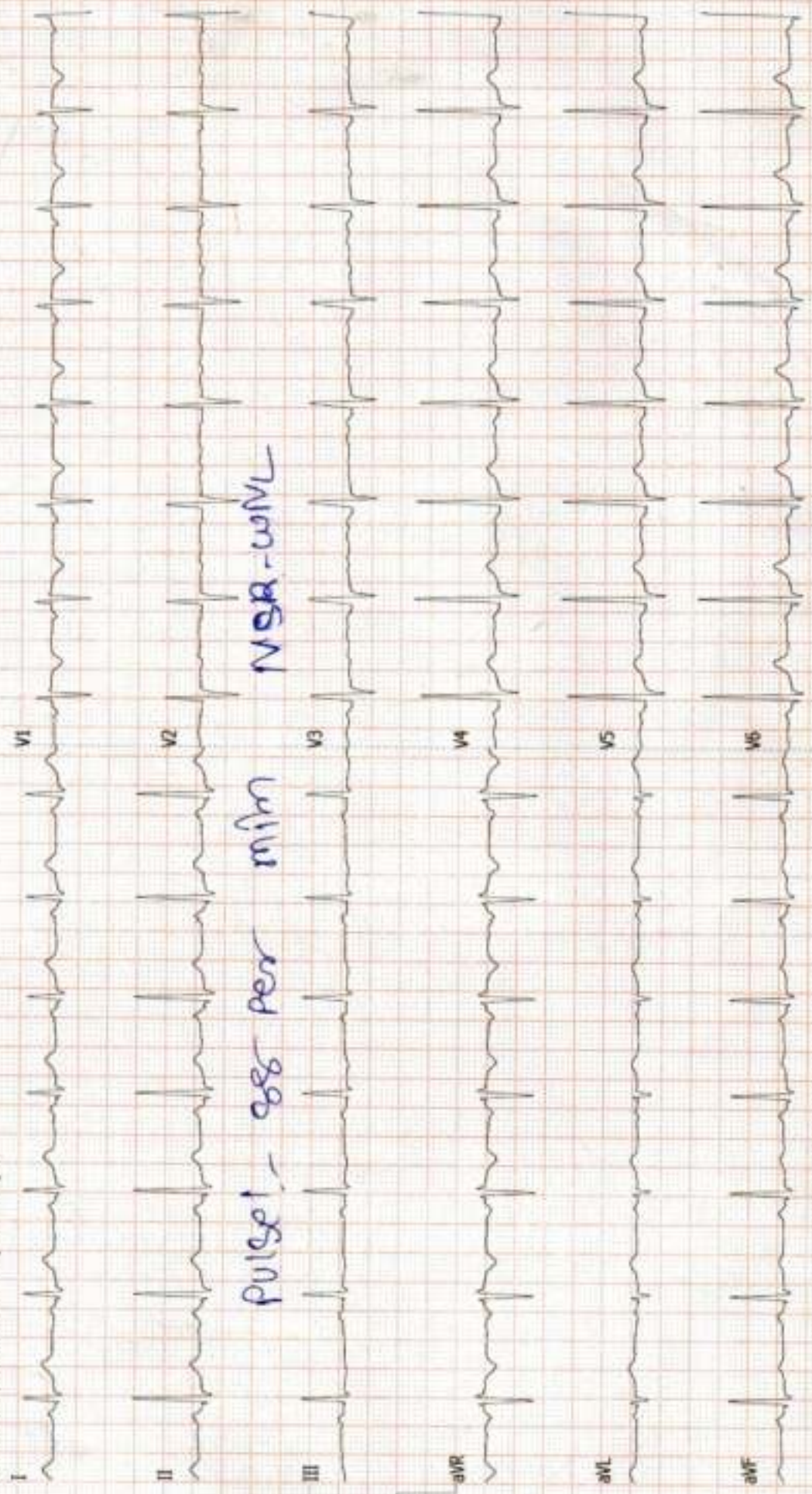
Department:

0.67Hz · 35Hz AC 50Hz 25 mm/s 10 mm/mv

Vidhi Diagnostics

156, Swastika-Ganesh Nagar,
 C-1, Ashburnagar Eas. Terminalis,
 Nr. Ashburnagar Circle,
 New Wadaj, Ahmedabad-13

Shalika Patel
 Dr. Ashish Chavhan
 MBBS D-Cardio
 G-5946



pulse! - 98 per min

NSR - wNL

Dr. Dinesh S. Modh

M.D., D.M.R.E. (Radiodiagnosis)

Consultant Radiologist & Sonologist

Ex. Junior Lecturer, B.J. Medical College, Civil Hospital, A'bad.



Patient's name : SHAILEE SUNILBHAI PATEL
Reg. ID : R-14101-23
Referred by : MEDI WHEEL

Age/Sex : 32 Years/Female
Accession : 23611
Date : 08/03/2024

2D- ECHO REPORT

FINAL CONCLUSION:

LV IS NORMAL SIZE. GOOD LV SYSTOLIC FUNCTION NO RWMA.
LVEF - 60%. NO CONCENTRIC LVH.
NORMAL LV COMPLANCE.
LA IS NORMAL SIZE. NO LA CLOT.
RV IS NORMAL SIZE. GOOD RV SYSTOLIC FUNCTION.
RA IS NORMAL SIZE.
MITRAL VALVE IS NORMAL. NO MS. MILD MR (15%). NO MVP.
AORTIC VALVE IS NORMAL. NO AS. NO AR.
TRICUSPID VALVE IS NORMAL. NO TR. RVSP-27 mmHg. NO PAH.

NO CLOT, NO VEGETATION, NO PERICARDIAL EFFUSION.

DIMENSIONS:

AORTA	2.8 C.M
LEFT ATRIUM	2.7 C.M
LVDD	4.2 C.M.
IVSD	1.0 C.M
PWD	1.0 C.M
LVDS	2.6 C.M.

COLOUR DOPPLER FINDING:

STRUCTURE	VELOCITY m/sec
	Max
PULMONARY VALVE	0.7
MITRAL VALVE	E : 0.9 A: 0.6
AORTIC VALVE	1.0

Dr. Avinash Bhaskar

M.B.B.S D-Cardio

G-45948

DR AVINASH BHASKAR
CLINICAL CARDIOLOGIST
9924836431

ISO 9001:2015 Certified Diagnostics Center

Vidhi Imaging Center

L-86, Swatantra Senani Nagar, Opp. Indian Oil Petrol Pump, Akhbarnagar Circle, Nava Vada, Ahmedabad - 380 013.

Phone : (Radiology) 079-2762-1406 | M. 98799 29406, 98250 09406 | Time (Radiology) : Mon. to Sat. 9 am to 2 pm, 5 to 9 pm, Sunday 9 am to 12 Noon

E-mail : vidhidiagnostics@gmail.com, Website : www.vidhidiagnostics.com

Multislice CT Scan | CBCT-Dental Scan | Live 3D-4D Sonography | Colour Doppler | Echo Cardiography | Interventional Radiology | Maxillofacial Radiology | Fetal Medicine
Digital X-Ray | Digital Mammography | Digital OPG/TMJ | ECG/TMT/PFT/EEG/EMG | Audiometry | Pathology Laboratory | Health Check Up Plans | Pre Employment Check Up

CT SCAN & CBCT FACILITY NOW AVAILABLE

Dr. Dinesh S. Modh

M.D., D.M.R.E. (Radiodiagnosis)

Consultant Radiologist & Sonologist

Ex. Junior Lecturer, B.J. Medical College, Civil Hospital, A'bad.



Patient's name : SHAILEE SUNILBHAI PATEL
Reg. ID : R-14101-23
Referred by : MEDI WHEEL

Age/Sex : 32 Years/Female
Accession : 23611
Date : 08/03/2024

USG ABDOMEN

LIVER: - Liver appears normal in size & show normal echotexture. No evidence of diffuse or focal lesion is seen. Intrahepatic biliary radicals appear normal. Portal vein and CBD appear normal. No e/o calculus is seen in bile duct.

GALL BLADDER: - Gall bladder is distended & appears normal. No evidence of calculus or cholecystitis is seen. No evidence of pericholecystic fluid is seen.

SPLEEN: - Spleen appears normal in size & shows normal echotexture. No evidence of diffuse or focal lesion is seen.

PANCREAS: - Pancreas appears normal size and echopattern. No e/o diffuse or focal lesion is seen. Main pancreatic duct appears normal.

KIDNEY: - Both Kidneys appear normal in size & echotexture.

No e/o calculus or hydronephrosis or hydroureter is seen in either side.

Cortico-medullary differentiation is maintained on either side.

Both suprarenal regions appear normal.

RIF & BOWEL LOOPS (By high frequency probe): - Normal.

No evidence of pre & para aortic lymphadenopathy is seen.

No evidence of free fluid is seen in abdomen.

No evidence of dilated or thickened bowel loops is seen.

Urinary bladder: - appears normal. No e/o calculus or mass lesion is seen in bladder.

Uterus appears normal in size and echopattern.

No evidence of diffuse or focal lesion is seen.

Cervical region appears normal.

Endometrial thickness is 6.4mm.

Both ovaries and adnexal regions appear normal.

No e/o free fluid is seen in pouch of Douglas.

Thanks for reference.


Dr. Dinesh S. Modh
MD DMRE (Radiodiagnosis)

G-23825

DR DINESH S. MODH

M.D. DMRE(RADIODIAGNOSIS)

ISO 9001:2015 Certified Diagnostics Center

Vidhi Imaging Center

L-86, Swatantra Senani Nagar, Opp. Indian Oil Petrol Pump, Akhbarnagar Circle, **Nava Vada**, Ahmedabad - 380 013.

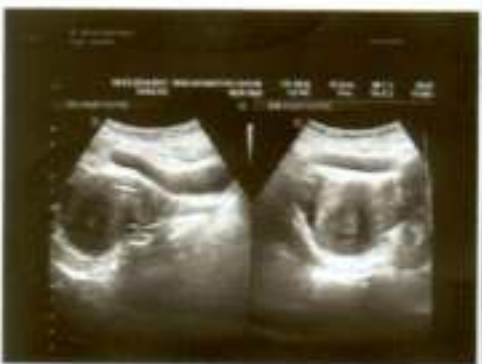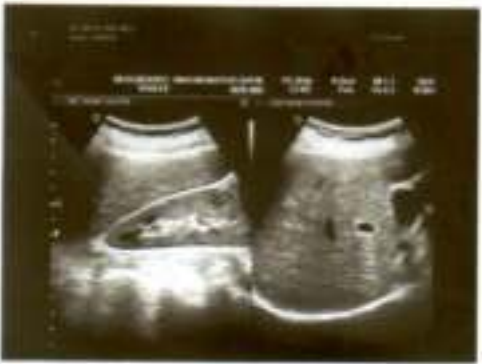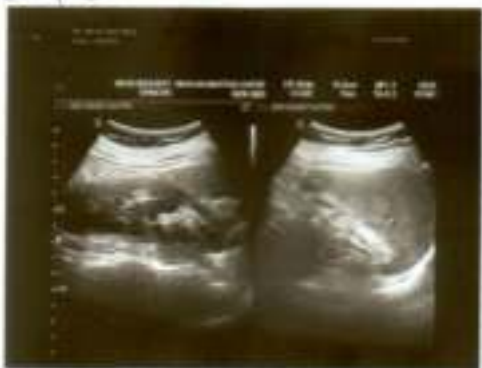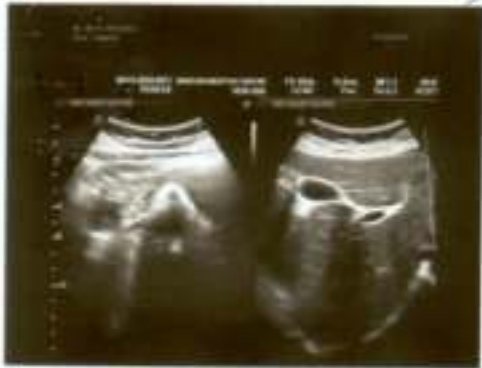Phone : (Radiology) 079-2762 1406 | M. 98799 29406, 98250 09406 | Time (Radiology) : Mon. to Sat. 9 am to 2 pm, 5 to 9 pm, Sunday 9 am to 12 Noon

E-mail : vidhidiagnostics@gmail.com, Website : www.vidhidiagnostics.com

Multislice CT Scan | CBCT-Dental Scan | Live 3D-4D Sonography | Colour Doppler | Echo Cardiography | Interventional Radiology | Maxillofacial Radiology | Fetal Medicine
Digital X-Ray | Digital Mammography | Digital DPG / TMJ | ECG / TMT / PFT / EEG / ENG | Audiometry | Pathology Laboratory | Health Check Up Plans | Pre Employment Check Up

CT SCAN & CBCT FACILITY NOW AVAILABLE

Study on



Dr. Dinesh S. Modh

M.D., D.M.R.E. (Radiodiagnosis)

Consultant Radiologist & Sonologist

Ex. Junior Lecturer, B.J. Medical College, Civil Hospital, A'bad.



Patient's name: SHAILEE SUNILBHAI PATEL
Reg. ID : R-14101-23
Referred by : MEDI WHEEL

Age/Sex : 32 Years/Female
Accession : 23611
Date : 08/03/2024

X-RAY CHEST (PA VIEW)

Both lung fields appear normal.
No e/o consolidation or cavitations is seen.
Both costo-phrenic angles appear clear.
Cardiac size is with in normal limits.
Both domes of diaphragm appear normal.
Bony thoracic cage appears normal.

Thanks for reference.


Dr. Dinesh S. Modh
MD DMRE (Radiodiagnosis)
G-23826

DR DINESH S. MODH
M.D. DMRE(RADIODIAGNOSIS)

ISO 9001:2015 Certified Diagnostics Center

Vidhi Imaging Center

L-86, Swatantra Senani Nagar, Opp. Indian Oil Petrol Pump, Akharnagar Circle, Nava Vadaj, Ahmedabad - 380 013.

Phone : (Radiology) 079-2762 1406 | M. 98799 29406, 98250 09406 | Time (Radiology) : Mon. to Sat. 9 am to 2 pm, 5 to 9 pm, Sunday 9 am to 12 Noon

E-mail : vidhidiagnostics@gmail.com, Website : www.vidhidiagnostics.com

Multislice CT Scan | CBCT-Dental Scan | Live 3D-4D Sonography | Colour Doppler | Echo Cardiography | Interventional Radiology | Maxillofacial Radiology | Fetal Medicine
Digital X-Ray | Digital Mammography | Digital DPG/TMJ | ECG/TMT/PFT/EEG/EMG | Audiometry | Pathology Laboratory | Health Check Up Plans | Pre Employment Check Up

CT SCAN & CBCT FACILITY NOW AVAILABLE