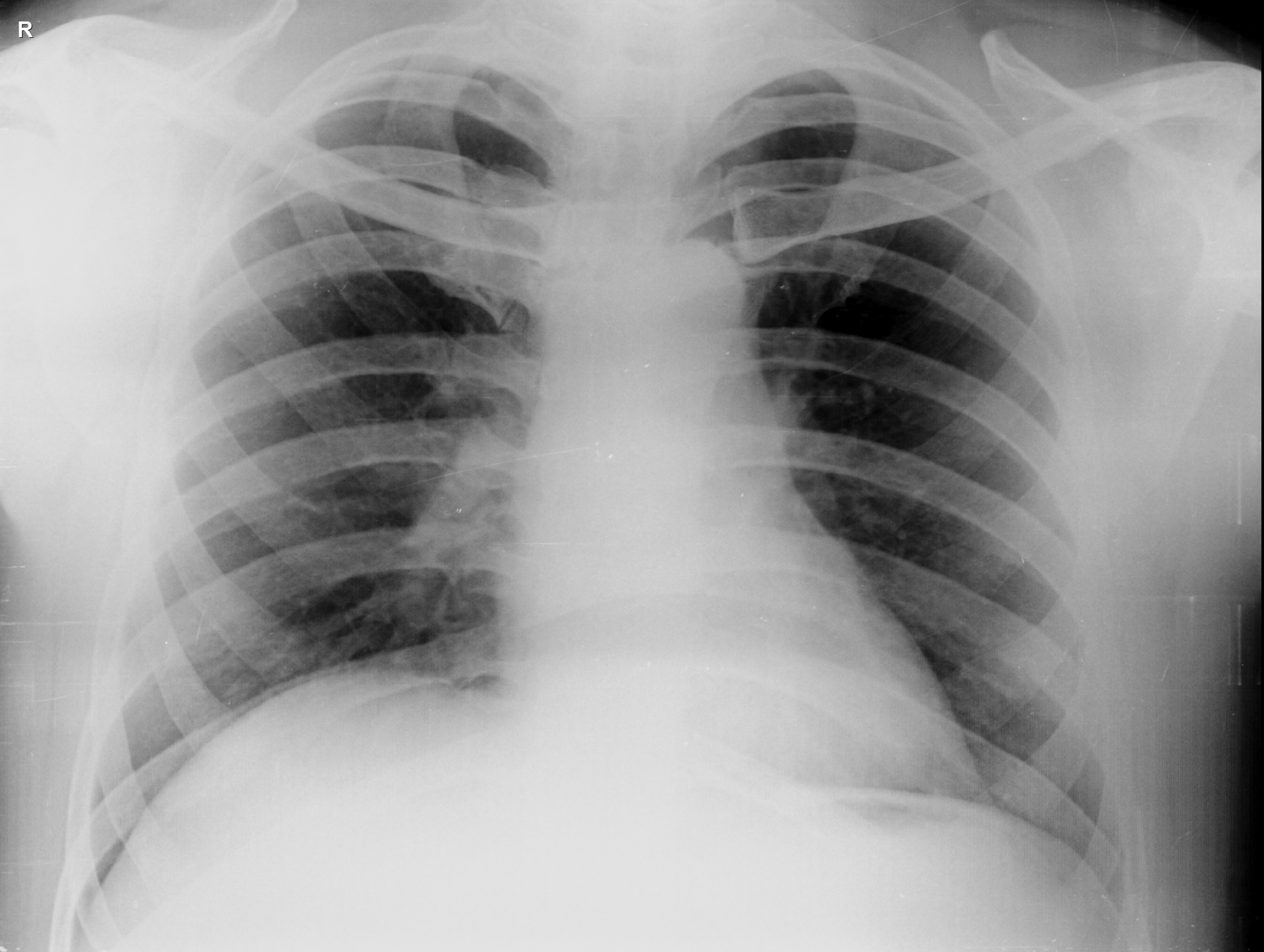


R



NABIN KUMAR SHAW 41Y M 2/19/2024 02:32 AM
OLIVE DIAGNOSTIC, SEAWOOD SEC 40

Name : MR NABIN SHAW	Age/sex: 41 Yrs. /MALE
Ref by: MEDI WHEEL	Date: 19/02/2024

ULTRASOUND EXAMINATION OF ABDOMEN & PELVIS

Findings-

The Liver is mildly enlarged in size (15.2cm), shape and raised echogenicity. No focal lesion is seen. The Hepatic veins appear normal. There is no IHBR dilatation. The portal vein appears normal.

The gall bladder is distended. The proximal C.B.D. is normal caliber

Visualized head of Pancreas appears normal in size and reflectivity. The pancreatic duct is not dilated. Rest of the pancreas and retro peritoneum is obscured by bowel gases

The spleen is normal in size (10.0cm), No focal lesion is seen. Splenic vein is normal at hilum.

Both kidneys are normal in position and size. They show normal cortical reflectivity and cortico-medullary differentiation. There is no evidence of renal calculus, hydronephrosis or mass.

Right kidney measures 10.7 x 6.9 cm

Left kidney measures 12.0 x 6.0cm

The Urinary bladder is well distended. No evidence of any intraluminal mass or calculi.

The visualized Prostate appears normal in size, shape and homogenous echotexture, its measures 2.2 x 2.8 x3.1 cm-10 cc


There is no free fluid is seen in the pelvis. No probe tenderness in present study.

IMPRESSION:-

- **Mild hepatomegaly with grade 2 fatty infiltration.**
- **Adv : clinical correlation.**




Dr. MRUDULA BABAR
CONSULTANT RADIOLOGIST



बैंक ऑफ़ बड़ोदा
Bank of Baroda


नाम : **Nabin Kumar Shaw**

कर्मचारी कूट. क्र. **E.C No. 72148**


 जारीकर्ता प्राधिकारी
 Issuing Authority: C.M. (Co-ord), KZ




 धारक के हस्ताक्षर
 Signature of Holder


Dr. Mahesh V. Padsalge
 MD. (Medicine)
 Consultant Physician
 Reg. No. 91424 (MMC)

मिलने पर निम्नलिखित को भेजें
 शाखाक महाराष्ट्र (पुणे), बैंक ऑफ़ बड़ोदा, बड़ोदा कॉर्पोरेट सेंटर
 सी-26, जी ब्लॉक, बंद्रा-कुर्ला कॉम्प्लेक्स, मुंबई 400 051, भारत
 फोन 91 22 6698 5196 फैक्स 91 22 2652 5747

K.Z.

If found please return to:
 Asst. General Manager (Security), Bank of Baroda, Baroda Corporate Centre
 C-26, G Block, Bandra-Kurla Complex, Mumbai 400 051, India
 Phone 91 22 6689 5196 Fax 91 22 2652 5747

जलित या नाम एवं दूरभाष निम्न आकाशवाणी से संपर्क करें
 Name & Ph./Person of emergency contact **Sudeshna Shaw Roy**

रक्त समूह/Blood Group : **A+ve** एलर्जी/Allergy **NII**

पहचान चिह्न/Identification mark

जारीकर्ता कार्यालय / Issuing Office
 BOB, Kolkata Zone, Plot No 38/2, Block - GN, Sector - V, Salt Lake City, Kolkata - 700 091

Nabin kumar shaw
ID. 41

19.02.2024 9:33:59
DIABECARE-DIABETES & ENDOCRINE
OPP. GRAND CENTRAL MALL
SEAWOOD

Male

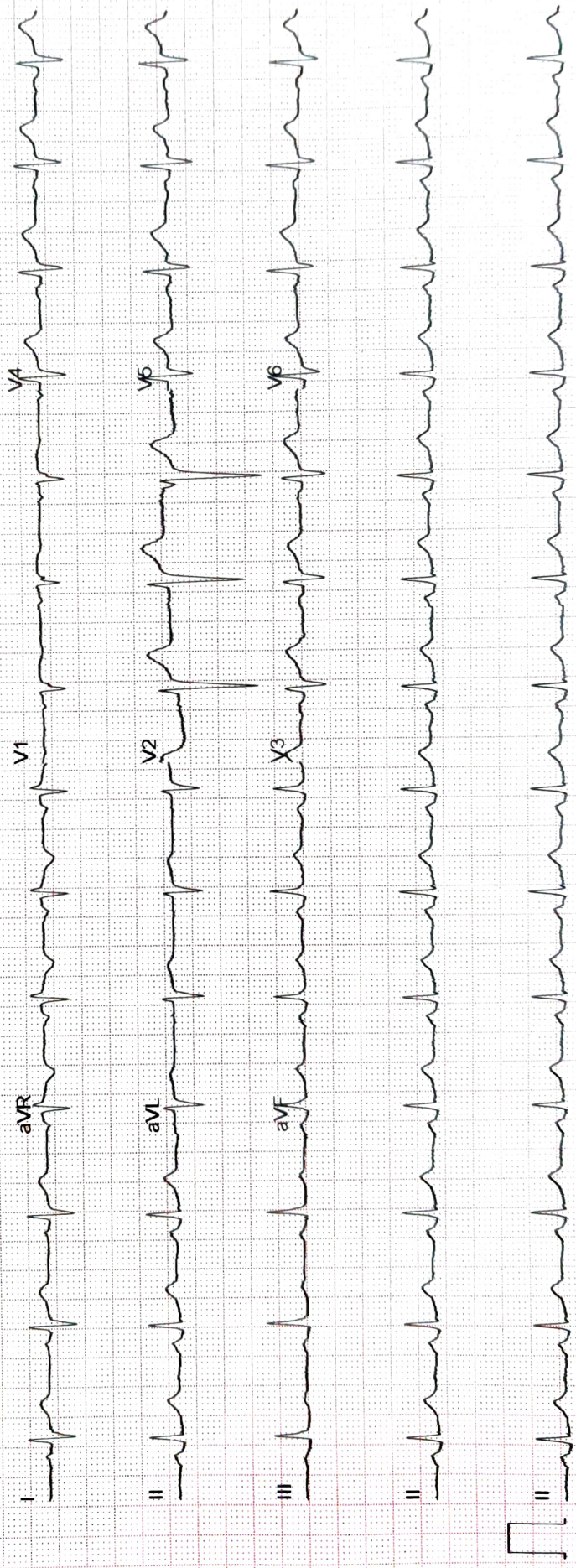
ECG normal limit

Normal sinus rhythm
Normal ECG

QRS	84 ms
QT / QTcBaz	370 / 437 ms
PR	144 ms
P	104 ms
RR / PP	710 / 714 ms
P / QRS / T	69 / 89 / 47 degrees

ESR

Dr. Mahesh V. Padsalghe
MD. (Medicine)
Consultant Physician
Reg. No. 91424 (MMG)



19/02/2024

Nabin Kumar Shetty

1M

Opium

(P)

(L)

VA

G/B

G/C

N₆ E/A

N₆ E/A

Colasun

(N)

(N)

D/S

(N)

(N)

(F)

NMD

NMD

(N) cont

es

ECHO Report

Date: 19/02/2024

Patient Details

Patient ID –

Name- MR NABIN KUMAR SHAW

Age- 41 YEARS

Gender- MALE

Referral BY - MEDIWHEEL

Doctor Incharge DR. MAHESH PADSALGE

Clinical Status of Patient -

Finding description -

- 1. Normal cardiac chambers dimensions .**
- 2. Normal LV systolic function.**
- 3. No RWMA.**
- 4. All cardiac valves are structurally normal.**
- 5. Trivial MR, Trivial PR, NO AR.**
- 6. No PAH (PASP -20 mmHg).**
- 7. Normal RV systolic function.**
- 8. No clot/vegetation/pericardial effusion.**
- 9. No coarctation of aorta.**

LVID (Diastole) 35-56(mm)	- 44.00	LVID (Systole) 24-42(mm)	- 29.00
IVS (Diastole) 8-12(mm)	- 10.00	IVS (Systole) 14-42(mm)	- 14.00
LVPWT (Diastole) 6-11(mm)	- 10.00	EPSS	- 2.00
LVEF (%)	- 63%	LVFS (%)	- 34.00

LV Volume (Diastolic)(mm³)
Meridional Wall Stress in System

LV Volume (Systolic)(mm³)
Cubed LV Volume in Diastole (mm³)

Cubed LV+ myocardial volume (mm³)

Velocity of circumferential
Shortening (mm)

Aortic root 22-37(mm)	- 29.00
Left Atrium Length (mm)	- 34.00
Left Atrium Volume (mm ³)	
RV size	Normal
Normal	
RV volume (mm ³)	
Normal	
Pericardium	Normal
Effusion	None
Resp Variation	Present
Predicted RV Systolic Pressure	

Left Atrium Width (mm)
Left Atrium Area (mm²)
RV Function
RA Size

IVC Size (mm) – 15mm Collapsible

Doppler Findings- I



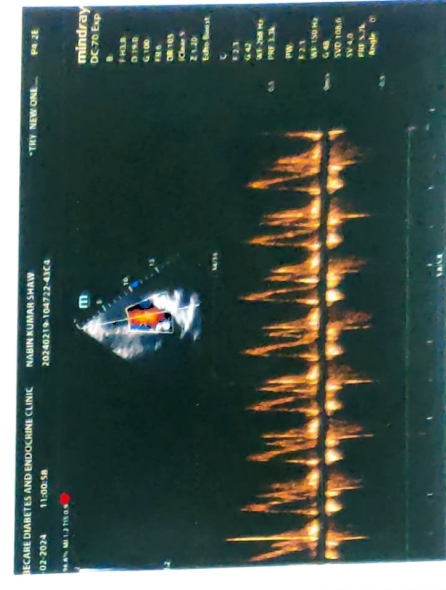
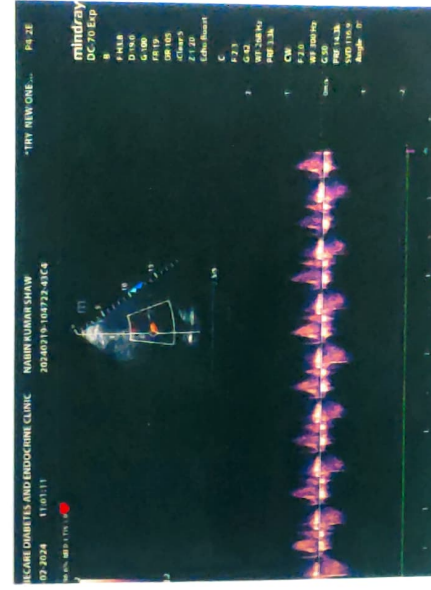
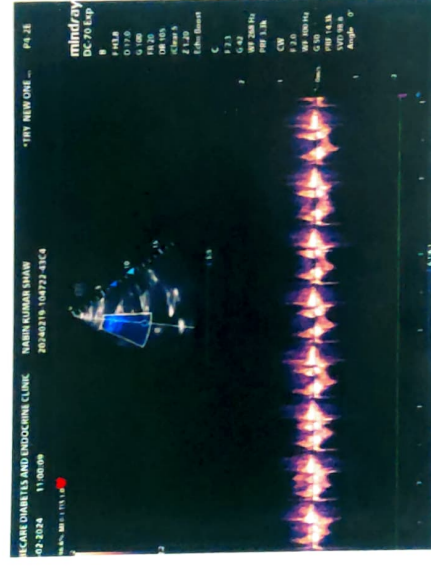
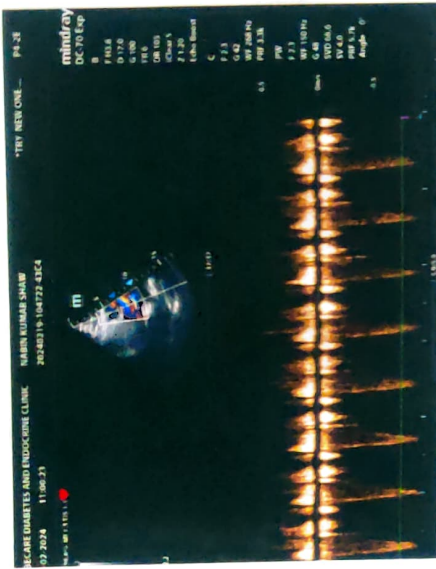
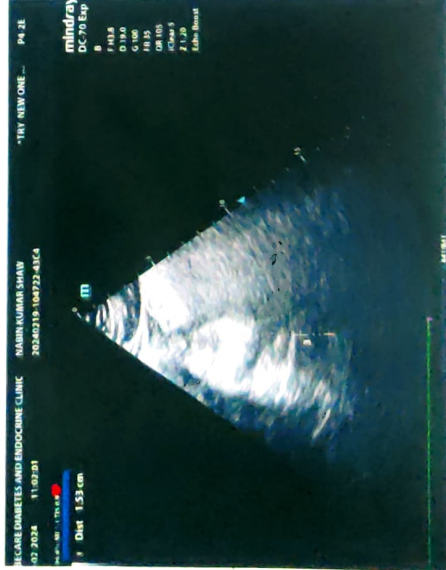
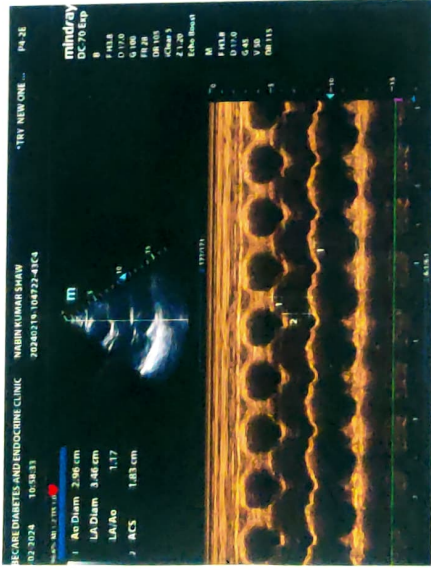
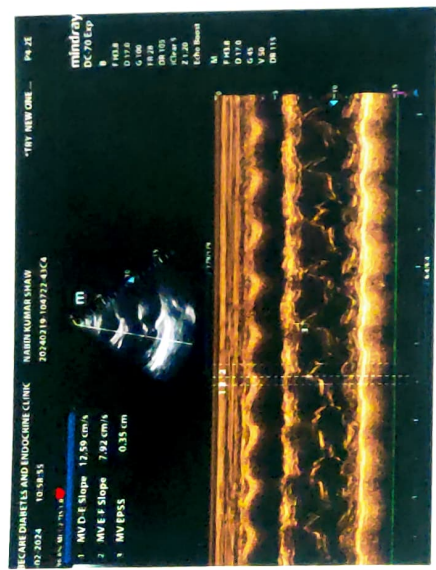
Dr. Mahesh Padsalge

Dr. Mahesh V. Padsalge

MD. (Medicine)

Consultant Physician

Reg. No. 91424 (MMC)



NAME- NABIN KUMAR SHAW

DATE-19/2/2024

AGE- 41/M

X-RAY CHEST PA

The Bony Thorax is Normal.

Both The Costophrenic And Cardiophrenic Angles Are Clear.

Cardiac Shape And Size Appears Normal.

The Lung Field Appears Normal.

Both The Hila Are Normal In Density And Position.

Impression: - Normal Chest X-Ray.

Foto Anar

DR.MRUDULA BABAR
CONSULTANT RADIOLOGIST