

Name	: Mr. ESHAAN SACHDEV	MR No	: UH038406
Age/Gender	: 21 Y/M	Visit ID	: OP050371
Admitting Doctor	:	Sample Collected on	: 29-06-2024 09:40
Lab ID No	: LAB067353	Sample Received on	:
		Report Released on	: 29-06-2024 13:41

Laboratory Report

Hematology

<u>Test Description</u>	<u>Result</u>	<u>Units</u>	<u>Ref Range</u>
Sample Type: EDTA			
BLOOD GROUP (ABO & RH TYPING)	"B" POSITIVE		
Sample Type: EDTA			
CBC WITH ESR			
HAEMOGLOBIN	15.4	gm/dL	13 - 18
TOTAL LEUCOCYTE COUNT	7,100	cell/cum	4000 - 11000
D.L.C = POLYMORPHS	63	%	40 - 75
LYMPHOCYTES	32	%	20 - 45
EOSINOPHILS	03	%	01 - 06
MONOCYTES	02	%	0 - 08
BASOPHILS	00	%	0 - 01
E.S.R (WINTROBE)	08	mm/1st	0 - 9
RED BLOOD CELLS	5.5	Millions	3.5 - 5.5
PLATELET COUNT	2.3	lakh/cum	1.5 - 4.5
P.C.V	45.8	%	35 - 50
M.C.V	82.4	fl	80 - 96
M.C.H	27.7	pg	27 - 32
M.C.H.C	33.6	%	32 - 36

End of the report

[Signature]

Checked By
Lab Technician

Verified By

[Signature]

UMKAL Hospital Pvt. Ltd

A-520, Sushant Lok-I, Gurugram- 122 002
Ph.: 0124-4 666 555 Mobile : 88600 77501
Emergency Ph No.: 0124 4100000

DR. PRIYAVART MEHARWAL
MBBS, MD
Pathologist



Name	: Mr. ESHAAN SACHDEV	MR No	: UH038406
Age/Gender	: 21 Y/M	Visit ID	: OP050371
Admitting Doctor	:	Sample Collected on	: 29-06-2024 09:40
Lab ID No	: LAB067353	Sample Received on	:
		Report Released on	: 29-06-2024 13:41

Laboratory Report

Biochemistry

<u>Test Description</u>	<u>Result</u>	<u>Units</u>	<u>Ref Range</u>
Sample Type: Serum BLOOD SUGAR - FASTING BLOOD SUGAR FASTING	103.3	mg/dl	70 - 110
Sample Type: Serum BLOOD SUGAR - PP 1465 BLOOD SUGAR PP 1465	124.0	mg/dl	70 - 140
Sample Type: Serum S.G.P.T 1475 S.G.P.T	24.2	IU/ML	upto - 45
Sample Type: Serum SERUM BILIRUBIN TOTAL 1456 S. BILIRUBIN (TOTAL)	1.29 *	mg/dl	0.1 - 1.2
Sample Type: Serum SERUM CREATININE	0.94	mg/dl	0.6 - 1.2
Sample Type: Serum BUN/SERUM CREATININE RATIO	19.5		10 - 20

End of the report

Rallen

Checked By
Lab Technician

Verified By

DR. PRIYAVART MEHARWAL

DR. PRIYAVART MEHARWAL
MBBS, MD
Pathologist


Name	: Mr. ESHAAN SACHDEV	MR No	: UH038406
Age/Gender	: 21 Y/M	Visit ID	: OP050371
Admitting Doctor	:	Sample Collected on	: 29-06-2024 09:40
Lab ID No	: LAB067353	Sample Received on	:
		Report Released on	: 29-06-2024 13:42

Laboratory Report

CLINICAL PATHOLOGY


<u>Test Description</u>	<u>Result</u>	<u>Units</u>	<u>Ref Range</u>
Sample Type: Urine			
URINE ROUTINE & MICROSCOPIC 1383			
COLOUR	P.YELLOW		
APPEARANCE	CLEAR		
SPEC.GRAVITY	1.020		
REACTION	6.0		
ALBUMINE	NIL		
SUGAR	NIL		
KETONE BODIES	NIL		
BLOOD	NIL		
LEUKOCYTES	NIL		
NITRITE	NIL		
UROBILINOGEN	NIL		
MICROSCOPIC EXAM	.		
PUS CELLS	2-3	/HPF	0 - 05
RBC CELLS	NIL	/HPF	0 - 02
EP CELLS	1-2	/HPF	0 - 05
CASTS	NIL		
CRYSTALS	NIL		
BACTERIA	NIL		
OTHER	NIL		

End of the report



Checked By
Lab Technician

Verified By



UMKAL Hospital Pvt. Ltd

A-520, Sushant Lok-I, Gurugram- 122 002
Ph.: 0124-4 666 555 Mobile : 88600 77501
Emergency Ph No.: 0124 4100000

DR. PRIYAVART MEHARWAL
MBBS, MD
Pathologist

APOLLO HEALTH CHECK-UP

NAME - Eshaan Sachdev · AGE - 21 / M DATE : 29.6 .2024

ADDRESS - Apollo

ON EXAMINATION

Height : 174 cm, Weight : 74 kg, Pulse : 73 min, BP: 126 / 73 mmhg,

SYSTEMS

- a) Respiratory - Normal vesicular breath sounds
- No adventitious sound
- b) Cardio Vascular - S1 S2 normal, No murmur
- c) Central Nervous - Normal
- d) Abdomen - Soft
Liver/Spleen - Not palpable
- e) Locomotor - Normal

ECG: Normal

X-Ray : Both hila appear prominent.

BIOCHEMICAL ANNLYSIS:

E.S.R 08*
HEMOGLOBIN 15.4*
S. BILIRUBIN TOTAL 1.28*

DR. ANUJ GOYAL
MBBS, MD (Internal Medicine)
Regn. No. DMCVR/23794
Umkal Hospital Pvt. Ltd.

REMARKS : Medically FIT/UNFIT

GENERAL PHSICIAN

UMKAL Hospital Pvt. Ltd

A-520, Sushant Lok-I, Gurugram- 122 002
Ph.: 0124-4 666 555 Mobile : 88600 77501
Emergency Ph No.: 0124 4100000

Review in OPD for.



29/06/23

Eshaan Sachdev | 27yr | male

Pt. came for regular annual health check-up.

C/C :- No. Been complaints.

Past history :- Not significant.

Personal history :- Mixed DM

ECG = T wave. \odot Resp.

Family history :- Grand father has diabetes mellitus.

Allergic history :- Not significant.

O/E :- Pt. is conscious & oriented.

PIA :- Soft & non-tender.

Ref :- All equal air entry.

CS :- \odot R & L.

CNS :- NAD.

UMKAL Hospital Pvt. Ltd

A-520, Sushant Lok-I, Gurugram- 122 002
Ph.: 0124-4 666 555 Mobile : 88600 77501
Emergency Ph No.: 0124 4100000

DR. ANUJ GOYAL
MBBS, MD (Internal Medicine)
Regn. No. 10000000000000000000
Umka Hospital Pvt. Ltd.

Eshaan Sachdev

M 29 624
21W

V 6/12
6/12

V 6/6
6/6

N 6
W-6

W 6
W 6

[Handwritten signature]

CERTIFICATE OF MEDICAL FITNESS

This is to certify that I have conducted the clinical examination

of Eshaan Sachdev on 29/6/24

After reviewing the medical history and on clinical examination it has been found that he/she is

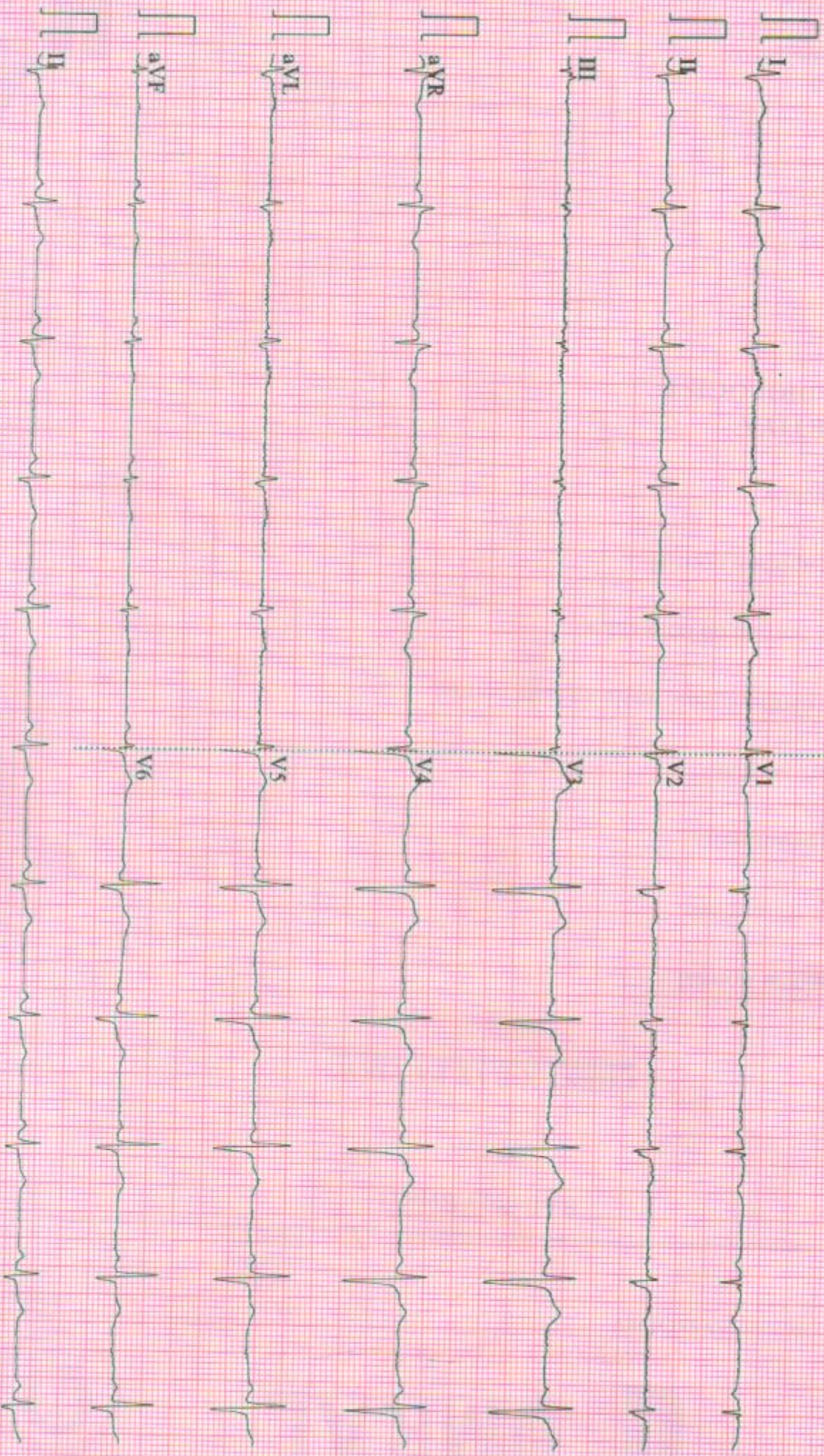
	Tick
<ul style="list-style-type: none">• Medically Fit	<input checked="" type="checkbox"/>
<ul style="list-style-type: none">• Fit with restrictions/recommendations <p>Though following restrictions have been revealed, in my opinion, these are not impediments to the job.</p> <p>1.....</p> <p>2.....</p> <p>3.....</p> <p>However the employee should follow the advice/medication that has been communicated to him/her.</p> <p>Review after _____</p>	
<ul style="list-style-type: none">• Currently Unfit. <p>Review after _____ recommended</p>	
<ul style="list-style-type: none">• Unfit	

DR. ANUJ GOYAL
MBBS, MS (Medical Medicine)
Regn. No. 5110/R/23794
Medical Officer
Umkal Hospital Pvt. Ltd.
Umkal Hospital Pvt. Ltd.

This certificate is not meant for medico-legal purposes

HR	: 62	bpm
P	: 96	ms
PR	: 140	ms
QRS	: 97	ms
QT/QTc/Bz	: 410/418	ms
P/QRS/T	: 49/36/21	°
RV5/SV1	: 0.698/0.330	mV

Report Confirmed by:



Name	: Mr. ESHAAN SACHDEV	MR No	: UH038406
Age/Gender	: 21 Y/M	Visit ID	: OP050371
Admitting Doctor	:	Order Date	: 29-06-2024 09:36
		Report Date	: 29-06-2024 10:56

Radiology Report

X-Ray

CHEST X-RAY PA VIEW

Finding -

Both lung fields appear normal.

Trachea appears in the midline.

Both hila appear prominent.

Cardiac size appears normal.

Both CP angle and cardiophrenic angle appears normal.

Diaphragm appears normal on both sides.

Visualized rib cage appears normal.

Please correlate clinically

DR ARUSHI BHARTIYA
CONSULTANT RADIOLOGIST